

Graft stabilization with cyanoacrylate decreases shrinkage of free gingival grafts

P Gümüş,* E Buduneli*

*Department of Periodontology, School of Dentistry, Ege University, İzmir, Turkey.

ABSTRACT

Background: The aim of this study was to comparatively evaluate three different stabilization methods with regards to the amount of shrinkage in free gingival graft.

Methods: Forty-five patients were included in three study groups: where stabilization was achieved with conventional technique, cyanoacrylate or microsurgery. In the conventional group standardized 5-0 sutures were used. In the microsurgery group grafts were stabilized with 7-0 sutures and loupe. In the third group, graft was stabilized with cyanoacrylate. Keratinized tissue width, graft area, gingival recession were calculated by a specific software on standard photographs at baseline, 1-, 3-, 6-month follow-ups. Duration of surgery was also recorded. Pain in recipient and donor sites was assessed using visual analogue scale within the first postoperative week.

Results: Change in keratinized tissue width was similar in the study groups at all times. Graft shrinkage was significantly less ($p < 0.05$) in the cyanoacrylate group than the other groups, whereas those in the conventional and microsurgery groups were similar. Significantly less pain in the recipient site was reported by the patients in the cyanoacrylate group ($p < 0.05$). Duration of surgery was significantly less in the cyanoacrylate group than the other groups ($p < 0.05$).

Conclusions: Less graft shrinkage in the free gingival graft, together with shorter surgery time and less pain in the recipient site obtained in the cyanoacrylate group, suggest that cyanoacrylate may be considered as an alternative for stabilization of free gingival grafts.

Keywords: Cyanoacrylates, gingiva, microsurgery, tissue grafts.

Abbreviations and acronyms: CAL = clinical attachment level; CEJ = cemento-enamel junction; FGG = free gingival graft; MGJ = mucogingival junction; PBI = papilla bleeding index; PD = probing depth; PI = Plaque index; VAS = visual analogue scale.

(Accepted for publication 5 June 2013.)

INTRODUCTION

Insufficient width of attached gingiva is a major mucogingival problem when the existing attached gingiva does not enable effective patient plaque control. One sign of insufficient width of attached gingiva is gingival inflammation localized to the particular site despite overall satisfactory oral hygiene. Existing clinical and histological data suggest that any dimensions which enable maintenance of healthy periodontium can be regarded as adequate rather than a certain width in millimetres.¹ Free gingival graft (FGG) is widely used to increase dimensions of attached gingiva.² Its autogenous character, maintenance of keratinization, predictability of surgical outcomes, ease of technique together with the possibility of implementation in a group of teeth lead FGG to be accepted as the golden standard to increase attached gingiva dimensions.³

Various amounts of graft shrinkage during the healing period have been reported.⁴⁻⁶ Factors disrupting continuity of graft nutrition play a major role in graft shrinkage. According to Sullivan and Atkins,⁷ graft thickness, atraumatic surgical technique and quick stabilization of the graft are vital to protect graft vessels from damage and dehydration, thereby decreasing shrinkage. Suture technique is also highly important for minimizing trauma to the graft tissue. Accordingly, it is recommended to keep the number of sutures to a minimum since each suture forms a localized haematoma under the graft which affect graft shrinkage. Factors, which act during stabilization of FGG, affect 'avasascular plasmatic circulation' and eventually graft shrinkage. Therefore, sutureless stabilization techniques may help to decrease or even prevent graft shrinkage and adhesives may be a method for reaching this goal.

Adhesives interact with different materials, merge and allow them to remain whole. Cyanoacrylates are

a group of simple, inexpensive and practical adhesives. Cyanoacrylates are used as tissue adhesives in paediatric surgery, general surgery and also dentistry.^{8–17} Butyl cyanoacrylate is a bacteriostatic, biodegradable, haemostatic cyanoacrylate with a long half-life and good tissue compatibility.¹⁸ It can adhere in moist environments and is available in a formulation appropriate to be used in the oral cavity.

Microsurgery is increasingly used in periodontology. Magnification glasses and small, specialized surgical instruments are used in microsurgery. Improved quality of view and reduced soft tissue trauma are major advantages of microsurgery contributing positively to the healing process.^{19,20}

Controlling potential factors related to healing complications may significantly decrease shrinkage. As yet, there have been no published studies comparatively evaluating various stabilization techniques with regard to the resultant graft shrinkage. Our hypothesis was that graft stabilization with cyanoacrylate and microsurgical technique may reduce graft shrinkage in free gingival graft application aimed solely at increasing the width of keratinized gingiva. Therefore, the present study was planned to compare three different stabilization techniques in regards to the changes in dimensions of free gingival graft and keratinized tissue, and to relate these changes to clinical periodontal conditions as well as pain levels in operation sites.

MATERIALS AND METHODS

Study population

This study was a randomized, controlled, clinical trial with an observation period of six months. A total of 45 patients were included in the present study between September 2008 and August 2010 (Table 1). The study was conducted in full accordance with ethical principles, including the World Medical Association's Declaration of Helsinki, as revised in 2008. The study was approved by the Ethics Committee of the Ege University with the protocol number 08-5/7. The study protocol was explained and written

Table 1. Demographic variables of groups

	Conventional group	Cyanoacrylate group	Microsurgery group
n	15	15	15
Gender (male/female)	1 / 14	1 / 14	1 / 14
Age range (year) median (min – max)	39 (32–48)	38 (20–50)	37 (24–48)
Age (year) (mean ± SD)	40.27 ± 4.83	37.60 ± 9.07	34.80 ± 7.28

All data are shown as mean ± standard deviation.

informed consent was received from each individual before clinical periodontal examination. Exclusion criteria were history of smoking, systemic diseases that require prescription of antibiotics, antibiotic treatment in the last six months, age <18 years, pregnancy or lactation. Inclusion criteria were presence of attached gingiva width <1 mm involving one or two lower anterior teeth, Miller Class III–IV recession. Moreover, sites requiring an increase in keratinized gingiva width without any attempt of root closure were included in the study.

Clinical measurements

Plaque index²¹ (PI), probing depth (PD), clinical attachment level (CAL) (at six sites; mesio-buccal, mid-buccal, disto-buccal, mesio-lingual, mid-lingual and disto-lingual locations) and papilla bleeding index²² (PBI) were recorded on each tooth present except third molars at baseline, 1-, 3-, and 6-month follow-ups. A Williams periodontal probe (Hu Friedy, Chicago, IL, USA) was used for clinical measurements.

CLINICAL PROCEDURES

Study groups

Initial periodontal therapy consisting of oral hygiene instruction, motivation, scaling and polishing was performed in all patients. Root planing, removal of iatrogenic factors and occlusal adjustment were also provided when necessary. All patients were examined two months after the completion of initial periodontal treatment to evaluate whether there was a need to increase attached gingiva dimensions in the mandibular anterior region. Full mouth plaque and bleeding scores were ≤20% at this recall visit. Presence of plaque and bleeding in the mandibular anterior region was regarded as questionable maintenance of periodontal health and indicated the need to increase attached gingiva width.

There were three study groups with 15 patients in each group. In Group 1, FGG was stabilized with conventional procedures; Group 2, FGG was stabilized with cyanoacrylate; Group 3, FGG was stabilized with a microsurgery technique. Patients were assigned to one of these study groups using a sealed-envelope randomization method. The treatment allocations were selected and concealed by a blinded investigator (EB) and envelopes were opened just before the operation. All surgical interventions were performed by the same experienced periodontist (PG). Before the operations, bioplast plaque was prepared for the upper jaw to control bleeding and to increase patient comfort during the healing period.

Recipient site preparation

A partial thickness flap was elevated following local anaesthesia by 2% lidocaine with 1:100 000 epinephrine. The flap design included a horizontal incision parallel to and below the mucogingival junction (MGJ) and passing the midpoint of adjacent teeth. Recipient bed was prepared for a graft size of 5 x 10 mm. Flap was sutured with three periosteal sutures to the apical border of the recipient site. In the conventional and cyanoacrylate groups, 15# scalpel (Swann-Morton Ltd, Sheffield, England) and 5-0 propylene (Doğsan, Trabzon, Turkey) suture material was used. In the microsurgery group, 15-c# scalpel (Swann-Morton Ltd, Sheffield, England), 7-0 propylene (Doğsan, Trabzon, Turkey) suture material and 2.5x magnification loupe (Seiler Instrument, St Louis, USA) was used for recipient bed preparation. After placing all sutures, gauze moistened with saline was placed over the recipient bed until the graft was placed.

Donor site preparation

Free gingival graft was obtained from the palatal mucosa between the first premolar and first molar at ≥ 2 mm distance from the gingival margins of the corresponding teeth.²³ Local anaesthetic (2% lidocaine with 1:100 000 epinephrine) was applied to the palatal area. Firstly, 5 x 10 mm sterile aluminium foil was prepared to standardize the graft size for all groups. The scalpel was moved horizontally and care was taken to harvest a FGG with a thickness, which allows reflection of the scalpel under it. Graft thickness was immediately assessed with a calliper at six points (ends and centre of the graft) and a standard thickness of 1–1.3 mm was achieved. Donor site was prepared with the scalpels used for recipient site preparation in each group.

Connective tissue surface of the graft was carefully inspected for removal of any adipose tissue. Dimensions of FGG were checked with a calliper and the graft was put on wet gauze and moistened with saline.

Graft stabilization

In the conventional group, a minimal number of sutures was used for stabilization of the FGG as

described previously by Sullivan and Atkins.⁷ Graft was stabilized with two sutures in the coronal portion of the two apico-coronal edges (Fig. 1a). After stabilization with 5-0 propylene sutures, gentle pressure was applied to the graft for five minutes.

In the cyanoacrylate group, FGG was stabilized with butyl cyanoacrylate (PeriAcryl[®], Glustitch, Delta, Canada). Gentle pressure was applied to the graft for five minutes and then cyanoacrylate was applied using its special 0.2 ml pipette so that there was an approximately 2 mm width of adhesive all along the graft borders (Fig. 1b). Excess drops flowing over were cleaned with gauze moistened with saline. It was then allowed to stand for 1–2 minutes to adhere the graft to the recipient site.

In the microsurgery group, FGG was fixed to the recipient site with 7-0 propylene sutures using 2.5x magnification loupe and special equipment for microsurgery (Fig. 1c). In addition to the two sutures in the coronal portion, two more sutures were used in the apical part of the apico-coronal edges. Finally, one more suture in the mid-point of the coronal border and one in the apical border were placed to prevent dead spaces. After stabilization, gentle pressure was applied to the graft for five minutes.

Clinical photographs

Clinical photographs were taken at baseline, 1-, 3-, and 6-month follow-ups. In the present study, the graft area, keratinized tissue and gingival recession was determined by a specific software on clinical photographs. To determine the exact values and standardize, 1 mm thick full-round wires were prepared in 4.0 mm length. This wire was placed on the soft tissue, close to the operation site and photographs were taken. Periodontal dressing was then applied over the graft in all the study groups.

Measurements were performed with Java-based analyse programme (ImageJ, National Institutes of Health, Bethesda, Maryland, USA). For evaluation of the graft area, graft borders were drawn and the area was coloured. Keratinized tissue width was measured from the gingival margin to the MGJ, for the baseline value graft bottom border was used as MGJ. Gingival recession was evaluated from the

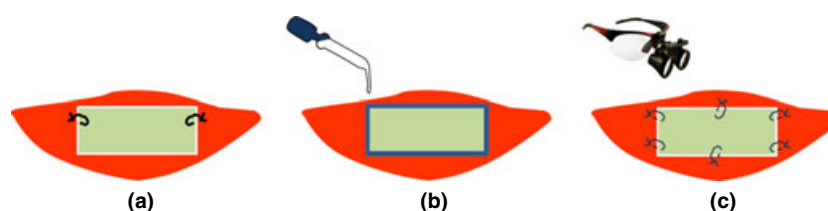


Fig. 1 Stabilization of free gingival graft in the study groups. (a) conventional group; (b) cyanoacrylate group; (c) microsurgery group. Whole graft was placed over the soft tissue so that no part of it was over the recessed root surface.

cemento-enamel junction (CEJ) to the gingival margin. All evaluations were repeated three times and the average value of these three measurements was calculated at 1-, 3-, and 6-month follow-ups. These measurements were made on clinical photographs of the graft area and therefore, the clinician was blinded to the study group.

The difference between the graft area at baseline, 1-, 3-, and 6-months was regarded as the amount of graft shrinkage, and the percentage of shrinkage was also calculated.

Determination of surgery duration

The exact time of starting the horizontal incision was noted for each patient. The time point just after graft stabilization was considered as the end of the operation and the exact time was recorded again. Operation duration was calculated in the same way in all study groups.

Postoperative protocol

Bioplast plaque was prepared for the maxilla to prevent postoperative complications such as bleeding and pain in the donor site and to provide patient comfort after surgery. These plaques were sterilized in autoclave before surgery. Patients were informed about the possibility of postoperative bleeding and taught how to use bioplast plaque. Toothbrushing activities in the operation sites were discontinued until sutures were removed. No mouthrinse or antibiotics were prescribed. Only analgesic pills (500 mg Acetaminophen) were recommended. All patients were asked to note the exact time and number of analgesic taken.

Visual analogue scale

Visual analogue scale (VAS) was used to evaluate pain during the postoperative period. A 10 cm VAS with 'none' at the left and 'unbearable' at the right end as verbal end points was prepared separately for the recipient and donor sites. Forms were given to patients after completion of the operation and they were asked to mark the pain value they felt at the end of each day. Forms were collected on the day of suture removal.

Periodontal dressing and sutures were removed on day 7 after the surgery. Operation sites were washed with sterile saline and cleaned gently with sterile gauze. Patients were asked to commence oral hygiene measures during the initial periodontal treatment.

Statistical analysis

The sample size was determined by a power analysis. A previous study⁵ reported average graft shrinkage in the 6-months as approximately 30% and the average standard deviation as approximately 25%. The sample size required to detect this graft shrinkage with an 80% power and $\alpha = 0.05$ was determined as 8–9 for intra-group and as 14 for inter-group comparisons to detect 8% difference.

Data were analysed by parametric tests as the variables distributed normally. Intra-group comparisons were performed by paired *t*-test, whereas inter-group comparisons were made by *t*-test. A statistical programme (SPSS 17.0 for Windows, SPSS Inc., Chicago, IL, USA) was used for statistical analysis of all parameters measured clinically or digitally, at baseline and during the after-surgery follow-up.

RESULTS

All measurements were performed by a single calibrated examiner (PG). The intra-examiner reliability was high as revealed by an intra-class correlation coefficient of 0.87 and 0.85 for PD and CAL measurements, respectively.

The study groups were similar in age and gender distribution (Table 1). In intra-group assessments plaque and bleeding scores decreased significantly from baseline to 6-months ($p < 0.01$) (Table 2). Intra-group assessment of PD, CAL values revealed significant decreases from baseline and 1-month to 3- and 6-months ($p < 0.01$). Plaque and bleeding scores, PD, CAL values were similar in the study groups at all time points.

There was no significant difference between the study groups in baseline graft area. The graft area at 1-, 3-, and 6-months reduced significantly compared to baseline in intra-group assessments ($p < 0.01$) (Table 3). In the conventional and microsurgery groups, graft areas were similar at all time points. The cyanoacrylate group had less change in graft area and less shrinkage than the other groups at all time points ($p < 0.05$). The cyanoacrylate group showed significantly lower percentage of shrinkage than the other groups ($p < 0.05$) (Fig. 2).

Keratinized tissue width decreased significantly from baseline to 6-months in intra-group assessments ($p < 0.01$) (Table 3). There was no significant difference between the study groups at any time point. Six-month gingival recession values were significantly lower than those at baseline in all study groups ($p < 0.01$).

Operation lasted for 37.33 ± 2.13 min, 26.87 ± 2.13 min, and 44.13 ± 3.46 min, respectively in the conventional, cyanoacrylate, and microsurgery groups.

Table 2. Measurements are in the anterior mandibular teeth

		Conventional group	Cyanoacrylate group	Microsurgery group
PI (Score 0 – 5)	Baseline	4 (3 – 4)	4 (3 – 4)	3 (3 – 4)
	1 month	2 (2 – 3) *	2 (2 – 3) *	2 (2 – 3) *
	3 month	0 (0 – 1) *†	0 (0 – 1) *†	0 (0 – 1) *†
	6 month	0 (0 – 1) *†	0 (0 – 1) *†	0 (0 – 1) *†
PBI (Score 0 – 4)	Baseline	3 (2 – 3)	3 (2 – 3)	3 (2 – 3)
	1 month	1 (1 – 2) *	1 (1 – 2) *	2 (1 – 2) *
	3 month	0 (0 – 1) *†	0 (0 – 1) *†	0 (0 – 1) *†
	6 month	0 (0 – 1) *†	0 (0 – 1) *†	0 (0 – 1) *†
PD (mm)	Baseline	2.47 ± 0.52	2.33 ± 0.49	2.53 ± 0.52
	1 month	2.27 ± 0.52	2.13 ± 0.49	2.23 ± 0.52
	3 month	1.93 ± 0.70 *†	1.73 ± 0.60 *†	2.11 ± 0.83 *†
	6 month	1.93 ± 0.70 *†	1.73 ± 0.70 *†	2.13 ± 0.83 *†
CAL (mm)	Baseline - 6 month	0.53 ± 0.52	0.60 ± 0.51	0.40 ± 0.51
	Baseline	6.13 ± 1.60	5.40 ± 1.64	5.60 ± 1.72
	1 month	6.13 ± 1.60	5.30 ± 1.63	5.60 ± 1.65
	3 month	4.80 ± 1.11 *†	4.07 ± 1.83 *†	4.53 ± 1.73 *†
	6 month	4.80 ± 1.21 *†	4.07 ± 1.83 *†	4.53 ± 1.73 *†
	Baseline - 6 month	1.33 ± 1.11	1.33 ± 0.25	1.07 ± 0.89

PI: plaque index; PBI: papilla bleeding index; PD: probing depth; CAL: clinical attachment level. Significant difference compared to baseline (* $p < 0.01$) and 1 month († $p < 0.01$).

PI and PBI are shown as median (Q1–Q3), PD and CAL are shown as mean ± standard deviation.

Table 3. Digital measurements on clinical photographs in the study groups

		Conventional group	Cyanoacrylate group	Microsurgery group
Graft area (mm ²)	Baseline	45.387 ± 11.388	45.837 ± 8.763	43.544 ± 11.788
	1 month	34.877 ± 7.262 *	41.711 ± 8.768 *†	33.452 ± 8.212 *
	3 month	32.811 ± 7.560 *	39.186 ± 9.029 *†	30.577 ± 8.004 *
	6 month	30.287 ± 7.288 *	37.575 ± 8.562 *†	29.362 ± 6.738 *
Shrinkage (mm ²)	Baseline -1 month	10.510 ± 5.877	4.125 ± 1.660 †	10.092 ± 5.547
	Baseline - 3 month	12.576 ± 5.767	6.651 ± 2.105 †	12.967 ± 5.696
	Baseline - 6 month	15.101 ± 6.552	8.261 ± 2.334 †	14.182 ± 6.738
Keratinized gingiva (mm)	Baseline	5.66 ± 1.00	5.55 ± 0.44	5.33 ± 1.13
	1 month	4.74 ± 0.89 *	4.92 ± 0.59 *	4.68 ± 1.12 *
	3 month	4.68 ± 1.01 *	4.76 ± 0.62 *	4.34 ± 1.03 *
	6 month	4.55 ± 1.01 *	4.77 ± 0.77 *	4.26 ± 0.97 *
Recession (mm)	Baseline	3.61 ± 1.40	3.33 ± 1.30	3.33 ± 0.85
	6 month	2.67 ± 1.10 *	2.42 ± 1.32 *	2.49 ± 0.92 *
	Baseline - 6 month	0.95 ± 0.74	0.92 ± 0.44	0.83 ± 0.43

There was no significant difference between the study groups in baseline graft area values ($p > 0.05$).

The graft area reduced significantly compared to baseline in intra-group assessment (* $p < 0.01$).

The graft area changes and amount of graft shrinkage was significantly lower in the cyanoacrylate group than the conventional and microsurgery groups at all time points († $p < 0.05$).

Significant changes compared to baseline in intra-group assessment (* $p < 0.01$).

All data are shown as mean ± standard deviation.

In the cyanoacrylate group, operation duration was significantly less than the other groups, whereas it was shorter in the conventional group than the microsurgery group ($p < 0.05$).

No postoperative complication such as bleeding was noted in any patient. One patient in each of the conventional and cyanoacrylate groups and two patients in the microsurgery group took analgesics in the first day after the operation. VAS score in the recipient site decreased in all groups from day 1 to day 6. In the cyanoacrylate group, VAS values were significantly lower than the other two groups during the first five days ($p < 0.05$) (Fig. 3a). In the donor site,

VAS scores decreased in all groups from day 1 to day 6. There was no significant difference between the study groups at any time point (Fig. 3b).

DISCUSSION

Blood supply between free gingival graft and recipient site is critical for the healing process, as is atraumatic graft stabilization for maintenance of plasmatic circulation. In the present study, three different graft stabilization techniques were used and postoperative graft shrinkage was compared at 1-, 3-, and 6-months.

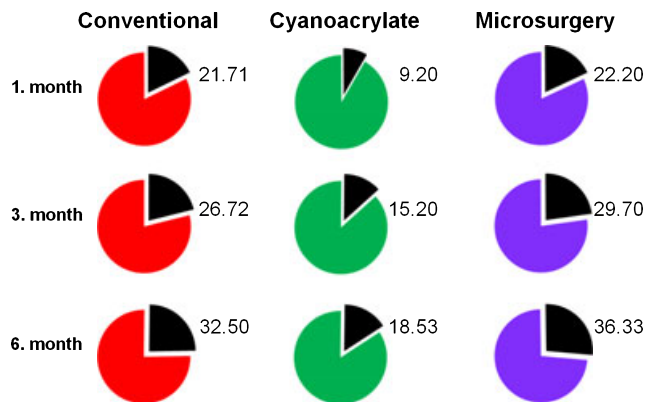


Fig. 2 Percentage of graft shrinkage (%) in the groups at 1-, 3-, and 6-month follow-up. Black slices are the amount of shrinkage (%) in the pie charts.

Plaque index, bleeding index, probing depth and clinical attachment level all decreased similarly during the follow-up period in the three study groups. An increase in keratinized tissue width improves patient’s plaque control^{24,25} and our findings provide further support for this fact. Furthermore, this improved plaque control may have enabled creeping attachment, which resulted in a decrease in attachment level.

No proportional value has been reported so far between the graft size and graft shrinkage but graft shrinkage is affected by the initial graft size. In the present study, graft dimensions were standardized at 5 x 10 mm to safely compare the study groups with regard to graft shrinkage. An insufficient amount of attached gingiva is most frequently seen in the mandibular anterior region. Therefore, we limited the recipient site to one or two mandibular anterior teeth. The mesio-distal width of mandibular incisive teeth and canine is 3.5–5.5 mm in the neck and 5–7 mm in the coronal part, therefore a mesio-distal length of 10 mm was appropriate for the graft to cover the recipient site.

Graft thickness is another factor affecting shrinkage.⁷ Therefore, standardized graft thickness is very

important when comparing the shrinkage between groups. In a pilot study of five patients, we harvested grafts so that the scalpel was under the graft tissue. Graft thickness was then immediately assessed with a calliper at six points (edges and centre of the graft) and found to be 1–1.3 mm thick. Previous studies^{7,26} reported adequate graft thickness to be 1–2 mm. Thus, adequate and standard graft thickness was a major concern in the present study.

The area of the graft is expected to be 50 mm² with 5 x 10 mm graft dimensions. After the stabilization, the graft area was determined by software, which calculates pixel numbers in the coloured graft area. This technique is more sensitive than calculation of graft area simply by measuring the distances with a periodontal probe or calliper. In the present study, the baseline graft area was calculated as 45 mm² by the software and there was no significant difference between the study groups. In previous studies,^{4-6,27} graft area was calculated by multiplying the longest apico-coronal dimension with mesio-distal width, which was measured by a periodontal probe or a calliper.

In our cyanoacrylate group, the graft shrinkage was significantly less than the other two groups. Moreover, graft stabilization in the recipient site with cyanoacrylate resulted in significantly shorter and atraumatic operation. All these factors may have a role in the significantly less graft shrinkage obtained in the cyanoacrylate group. In the cyanoacrylate group, gentle pressure was applied to the graft before it was stabilized in the recipient site. In the other two groups, pressure was applied after the stabilization. When dropped, cyanoacrylate is likely to stabilize the graft immediately after gentle pressure without any movement. This initial stabilization may have a significant role in maintenance of avascular plasmatic circulation, eventually resulting in less shrinkage. One can expect to find similar shrinkage values in our cyanoac-

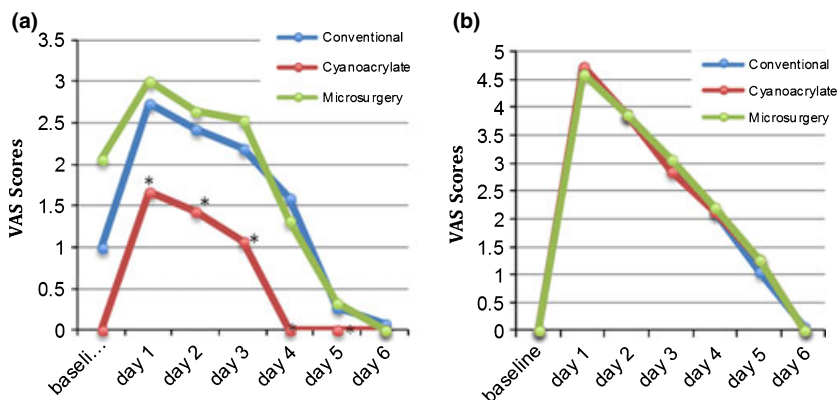


Fig. 3 VAS score assessment in the study groups from day 1 to day 6. Y-axis provides the VAS scores, whereas the X-axis stands for the days of evaluation. (a) recipient site VAS scores; (b) donor site VAS scores. Pain levels in the recipient site were significantly less in the cyanoacrylate group than the conventional and microsurgery groups (*p < 0.05).

rylate and microsurgery groups, which was not the case. The operation lasted significantly longer in the microsurgery group than in the conventional group and the number of sutures was four more than that in the conventional group. It may be speculated that the longer the operation lasts, the more is the graft shrinkage. Even with microsurgery the number of sutures is important to obtain less shrinkage.

No published study with similar study groups could be found to compare our findings. James and McFall⁴ reported 40% graft shrinkage in the third and 49% in the sixth months. Hatipoğlu *et al.*⁵ stated that graft shrinkage was 25% in the third week and 35% in the sixth month. The graft area was determined by a periodontal probe in both studies. Silva *et al.*⁶ detected approximately 37% shrinkage in the first month and 44% in the sixth month and used a calliper to calculate the graft area. We believe area calculation by software enabled us to make more sensitive assessments.

Barbosa *et al.*²⁷ stabilized free gingival graft with ethyl cyanoacrylate in one group and with silk mucoperiosteal sutures in the other. Graft area calculated by the calliper on day 30, day 45, and day 90 were 60.9 ± 15.1 , 54.5 ± 16.1 , 54.5 ± 16.1 and 59.0 ± 2.4 , 57.1 ± 1.3 , 57.1 ± 1.3 mm² in the cyanoacrylate and suture group, respectively. No significant difference was reported between the study groups for changes in graft area. The authors stated that the study groups were similar as no or minimal trauma was applied to the soft tissues. Our findings differ from those of Barbosa *et al.*²⁷ as the graft shrinkage in the present cyanoacrylate group was significantly less than that in the conventional group. This difference between the two studies may be explained by usage of mucoperiosteal sutures in the suture group of Barbosa *et al.*²⁷ providing atraumatic stabilization of the graft in both groups. Another likely explanation is the difference in graft area calculation technique between the two studies as the software-aided measurement improves the sensitivity and accuracy.

VAS score in the recipient site of our cyanoacrylate group was lower than those in the other groups during the first five days postoperatively. In this group, graft stabilization in the recipient site occurred in a significantly shorter time. We believe the shorter operation time relates to less inflammation and oedema and less pain during the postoperative period. Accordingly, Zucchelli *et al.*²⁸ reported that longer surgical time in the control group might have balanced the secondary intention wound healing experienced by the test group in terms of postoperative pain.

CONCLUSIONS

It can be suggested that stabilization of free gingival grafts with cyanoacrylate decreases operation time and

recipient site pain in the first week after the operation and results in less graft shrinkage. Therefore, cyanoacrylate may be a promising alternative for conventional and microsurgery techniques to stabilize free gingival grafts.

ACKNOWLEDGEMENTS

This study was funded solely by the authors' institution. The authors declare that they have no conflict of interest.

REFERENCES

- Hall WB, Lundergan WP. Free gingival grafts; current indications and techniques. *Dent Clin North Am* 1993;37:227–242.
- Cortellini P, Tonetti M, Prato GP. The partly epithelialized free gingival graft (pe-fgg) at lower incisors. A pilot study with implications for alignment of the mucogingival junction. *J Clin Periodontol* 2012;39:674–680.
- Karring T, Ostergaard E, Löe H. Conservation of tissue specificity after heterotopic transplantation of gingiva and alveolar mucosa. *J Periodontol Res* 1971;6:282–293.
- James WC, McFall W Jr. Placement of free gingival grafts on denuded alveolar bone. *J Periodontol* 1978;6:283–290.
- Hatipoğlu H, Keçeli HG, Güncü GN, *et al.* Vertical and horizontal dimensional evaluation of free gingival grafts in the anterior mandible: a case report series. *Clin Oral Investig* 2007;11:107–113.
- Silva CO, Ribeiro PE, Sallum AW, *et al.* Free gingival grafts: graft shrinkage and donor-site healing in smokers and non-smokers. *J Periodontol* 2010;81:692–701.
- Sullivan HC, Atkins JH. Free autogenous gingival grafts. 1. Principles of successful grafting. *Periodontics* 1968;6:5–13.
- Dennison JB, Meyer JM, Birnholtz SB, *et al.* Initial leakage under pit and fissure sealants assessed by neutron activation. *J Dent Res* 1974;53:1439–1444.
- Levin MP, Cutright DE, Bhaskar SN. Cyanoacrylate as a periodontal dressing. *J Oral Med* 1975;30:40–43.
- Brauer GM, Jackson JA, Termini DJ. Bonding of acrylic resins to dentin with 2-Cyanoacrylate esters. *J Dent Res* 1979;58:1900–1907.
- Barkhordar RA, Javid B, Abbasi J, *et al.* Cyanoacrylate as a retro filling material. *Oral Surg Oral Med Oral Pathol Oral Radiol Endod* 1988;65:468–473.
- Mattick A. Use of tissue adhesives in the management of paediatric lacerations. *J Emerg Med* 2002;19:382–385.
- Miller NA. Sutureless gingival grafting. A simplified procedure. *J Clin Periodontol* 1982;9:171–177.
- Singer AJ, Quinn JV, Clark RE, *et al.* Closure of lacerations and incisions with octylcyanoacrylate: a multicenter randomized controlled trial. *Surgery* 2002;131:270–276.
- Singer AJ, Quinn JV, Hollander JE. The cyanoacrylate topical skin adhesives. *Am J Emerg Med* 2008;26:490–496.
- Azevedo CL, Marques MM, Bonbana AC. Cytotoxic effects of cyanoacrylates used as retrograde filling materials. An *in vitro* analysis. *Braz Oral Res* 2003;17:113–118.
- Negri MR, Panzarini SR, Poi WR, *et al.* Use of a cyanoacrylate ester adhesive for splinting of replanted teeth. *Dent Traumatol* 2008;24:695–697.
- Bonutti PM, Weiker GG, Andrish JT. Isobutyl cyanoacrylate as a soft tissue adhesive. An *in vitro* study in the rabbit Achilles tendon. *Clin Orthop Relat Res* 1988;229:241–248.

19. Burkhardt R, Lang NP. Coverage of localized gingival recessions: comparison of micro- and macrosurgical techniques. *J Clin Periodontol* 2005;32:287–293.
20. Gargallo J, Rubio E, Gutiérrez Pérez J, *et al.* New dental simulator for microsurgical training preliminary overview. *Med Oral Patol Oral Cir Bucal* 2007;12:E582–584.
21. Quigley GA, Hein JW. Comparative cleaning efficiency of manual and power brushing. *J Am Dent Assoc* 1962;65:26–31.
22. Saxer UP, Mühlemann HR. [Motivation and education.] *Schweiz Monatsschr Zahnheilkd* 1975;85:905–919.
23. Müller HP, Schaller N, Eger T, *et al.* Thickness of masticatory mucosa. *J Clin Periodontol* 2000;27:431–436.
24. Dorfman HS, Kennedy JE, Bird WC. Longitudinal evaluation of free autogenous gingival grafts. *J Clin Periodontol* 1980;7:316–324.
25. Orsini M, Orsini G, Benlloch D, *et al.* Esthetic and dimensional evaluation of free connective tissue grafts in prosthetically treated patients: a 1-year clinical study. *J Periodontol* 2004;75:470–477.
26. Mörmann W, Schaer F, Firestone AR. The relationship between success of free gingival grafts and transplant thickness. Revascularization and shrinkage—a one-year clinical study. *J Periodontol* 1981;52:74–80.
27. Barbosa FI, Correa DS, Zenobio EG, *et al.* Dimensional changes between free gingival grafts fixed with ethyl cyanoacrylate and silk sutures. *J Inter Acad Periodontol* 2009;11:170–176.
28. Zucchelli G, Melel M, Stefanini M, *et al.* Patient morbidity and root coverage outcome after subepithelial connective tissue and de-epithelialized grafts: a comparative randomized-controlled clinical trial. *J Clin Periodontol* 2010;37:728–738.

Address for correspondence:
Dr Pınar Gümüş
Ege University
School of Dentistry
Department of Periodontology
35100 Bornova, İzmir
Turkey
Email: pinar.gumus@ege.edu.tr