

# A systematic approach

**Dr Steven Harris** shares his systematic approach to non-surgical facial rejuvenation

**A**s aesthetic practitioners, we are often introduced to specific non-surgical treatments for specific areas of the face; for example, hyaluronic acid filler injections for the periorbital area. In practice, however, it is essential to develop a systematic approach to the face as a whole when considering non-surgical facial rejuvenation. This approach involves assessment of the skin, facial shape and the upper, middle and lower thirds of the face followed by treatment to create lift and restore volume and shape. The main aim is to create a natural fresh look.

## ASSESS THE SKIN, FACIAL SHAPE, UPPER THIRD, MIDDLE THIRD AND LOWER THIRD OF THE FACE.

### SKIN

Is the skin smooth? Are there deep pores? Is there scarring? Are there areas of hyper or hypopigmentation? Is there inflammation (acne, rosacea)? Are there skin spots (age spots, or suspicious moles)? Is the skin loose?

Always consider a skin tightening procedure prior to fillers for an enhanced filler effect (my preferred procedure is fractional medical needling with a Dermalpen).

### SHAPE

Is the face oval (ideal shape for both women and men), or heart shaped (women) or more square (men)?

Look at the thirds of the face and remember the ratio upper:mid:lower = 1:1:1

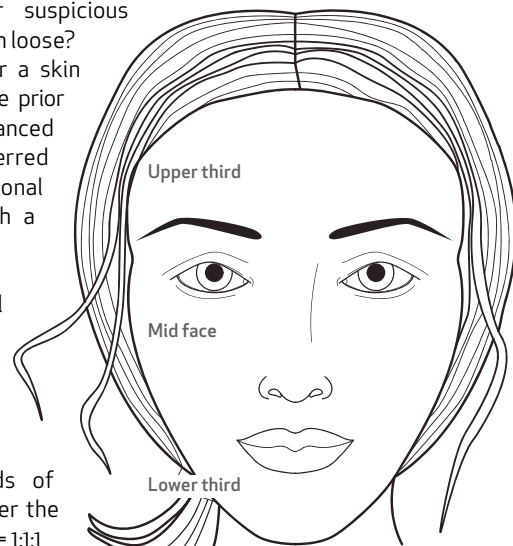
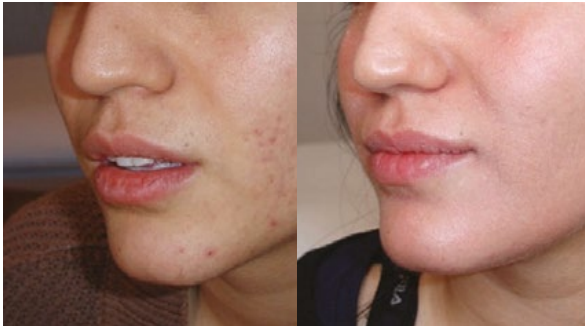
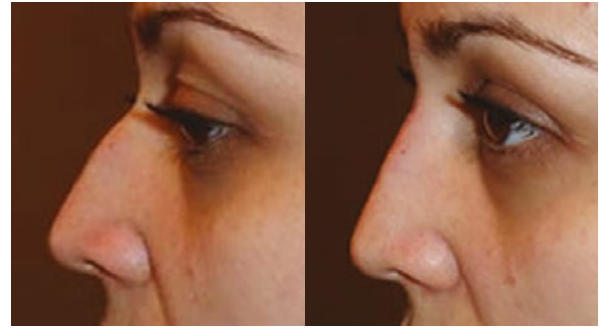
Figure: The facial thirds



Before and after Dermapen, by Dr Steven Harris



Before and after non-surgical rhinoplasty, by Dr Steven Harris

### UPPER THIRD

The ideal curvature of the forehead is between 12-14 degrees (look from the side). With age, the forehead flattens on the lower half and becomes more curved on the upper half.

Are there lines related to movement (dynamic), or fixed lines (static)? Ask the patient to raise eyebrows and frown. Dynamic lines respond better to Botulinum Toxin Type A (BTA); static lines respond better to fillers, such as Hyaluronic Acid gel (HA).

Are the temples hollow? In women a little hollowing is acceptable, but too much hollowing disrupts the shape of the face and the shape of the eyebrows. Full temples look masculine, so be careful not to overcorrect during treatment.

### MIDDLE THIRD

This is where fat is lost early (first around the eyes and then the middle of the cheek) and this is the most common area for volume replacement.

Are the patient's cheeks hollow or full? Ask the patient to bend their head down while looking upward (to emphasise areas of volume loss) and also to look to the sides.

Ask her to smile and note changes in shape and volume in the middle third. Does the patient have any missing teeth causing the cheek to sink? Does she look tired or 'droopy'?

Less is more. Don't over-treat and don't take unnecessary risks. You can always add more at the time of review

Do the cheek bones look flat or curved? Does the patient have the 'Ogee curve'?

Do the eyes have the ideal almond shape? Are the eyebrows curved or flat? Does the eyebrow start in line with the medial canthus of the eye? Is the arch of the eyebrow at the correct place? Line up a pen with one end at the corner of the patient's nostril going over the centre of the pupil. The arch of the eyebrow should be at the other end of the pen.

Is the patient showing early signs of skeletal change with hollowing

around the eyes? Are the lids heavy and 'droopy'? Are there deep tear troughs?

Does the patient have 'malar mounds' (the 'no-go area' for injections)?

Does the nose appear too long, or too wide? Is the nose straight, or 'hooked' and is it pointing downward?

### LOWER THIRD

A lot of the problems in the lower third are the result of volume loss and descent from the middle third. Does the patient have jowls? Does the patient have marionette lines? How are the lips – are they full and well defined? Do they follow the golden ratio upper:lower=1:1.618? Does the upper lip protrude slightly more than the lower lip? Ask the patient to smile; does she have a gummy smile? Ask her to make a kissing pose; are there dynamic and static 'smokers lines'? Is the philtrum elongated? How are the patient's teeth; are they affecting the shape of the lips?

Is the ratio between the nose and the upper lip : lower lip and chin = one third : two thirds? Is the chin strong and well defined? For women the chin is pointier (same distance between the alae of the nose); for men the chin is more square (same distance between the corners of the mouth). Take a pen and place one end on the tip of the nose and the other end on the chin (Riedel's plane). Are the nose, upper lip, lower lip and chin aligned? Does the patient have a protruding jaw (prognathism)?

Does the patient have bulging masseter muscles? Injecting the masseters with BTA can restore an oval shape (and can help with teeth grinding - bruxism).

Does the patient have a protruding jaw (prognathism)?

Does the patient have bulging masseter muscles? Injecting the masseters with BTA can restore an oval shape (and can help with teeth grinding - bruxism).

### TREATMENT

**Less is more.** Don't over-treat and don't take unnecessary risks. You can always add more at the time of review (two weeks). Gauge the reaction of the patient as you are treating (ensure she can regularly check with a mirror). Stop treatment if the patient is fully satisfied. If treating with HA, explain to the patient that there is some swelling associated with injections and that there will be a reduction in fullness by 10-30% as this settles.

**Manage expectations** from the start. Keep expectations on the lower side of the spectrum in order to avoid disappointment. Keep in mind that the number one complaint from patients is that expectations have not been met.

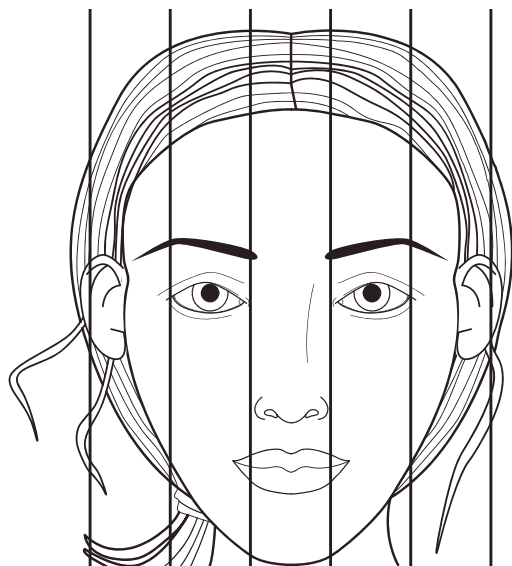



Figure: The facial fifths (each equal to the width of one eye)



**Always take Before photos** (frontal/anterior, sides/lateral, anterolateral, bending head downward while looking upward, raising eyebrows and frowning, smiling and kissing). Often patients will forget what they looked like before the procedure. They may feel there has been 'no change' after treatment or blame you for things that 'were not there before the procedure.'

**Touch the patient's face** at the time of assessment to show them what you propose. Touch wins over trust. Remember, the most common treatment strategy involves lifting and reshaping. Use your fingers to demonstrate this on the patient while she looks in a mirror.

During both the assessment and the treatment, ensure the patient is in the upright position (to assess the effects of gravity) and that they can frequently refer to a hand held mirror. Involve the patient at every stage of assessment and treatment. Treat only with the patient's consent.

**Listen carefully** to what treatment the patient would like. Allow them to talk and explain fully without interruption. Once they have finished, ask them if you may give your opinion. Share with them the value of lifting and reshaping and explain that treating a little line is like going to a house to fix a small back window and that first the house as a whole needs a strong foundation. Explain the ageing process and how you want to lift and restore volume and shape.

Symmetry is important, but there is no such thing as perfect symmetry. **A perfectly symmetrical face does not look human.**

Explain this to your patient. Improving symmetry can help the patient's overall appearance, but perfect symmetry should not be a goal.

Studies show that patients don't necessarily want to look 10 years younger. They want to look the best they can for their age. They want a less tired and fresh look. Agree with the patient that this is the goal of treatment.

**Avoid words like perfection.** Explain to the patient that you are not in the business of perfection (and that there is no such thing). Do not treat a patient who is demanding a perfect result. Watch out for other signs of **Body Dysmorphic Disorder (BDD)**: Does the patient have an imagined defect? Has she had multiple previous procedures and is she never satisfied? Is she depressed? Is she unhealthily preoccupied with her looks? Do not treat patients with BDD.

**Know your anatomy and remember the danger areas.** Danger areas are the glabella, temples, mid-cheek, tear-trough, naso-labials, lateral area to mouth and jaw-line at the entrance of the facial artery (just anterior to masseter) and the angle of the jaw, however, **any area may give rise to complications.**

**Ensure you are familiar with all the muscles of the face.** Know your 'elevators' and 'depressors' and treat accordingly with BTA to help create lift and shape.

**As a general rule,** inject depressor muscles with BTA to create lift and elevator muscles to depress. Keep injections superficial (30 gauge needle just under the skin), except in the glabella (30 gauge needle insert half length into Procerus muscle and up to full length into the Corrugators). Avoid treating compensatory muscle activity, for example, forehead lines as a result of lifting to compensate for lid ptosis (consider treating with HA as an alternative option).

**When using HA, ensure you are at the correct level and always aspirate before injecting.** Ensure the syringe is held steadily and aspirate slowly until a bubble is clearly visible. If there is no aspirate, then proceed to inject slowly. If the aspirate shows blood, then withdraw the needle and apply pressure. Do not proceed to inject in the same area for at least one week.

**Know the 8-point lift (Dr Mauricio de Maio), but never follow any formula blindly.** Learn to trust what you see. Remember, "we look with our eyes, but we see with our brains" (Dr Arthur Swift). We all have the ability to recognise and restore beauty using BTA and HA. For women we emphasise cheeks more on the sides to restore cheek bones (lateral projection); for men we emphasise cheeks more on the front (anterior projection). Always start treatment on the weaker side of the face and never treat an area in isolation. Inject only a small amount of filler at a time; take a step

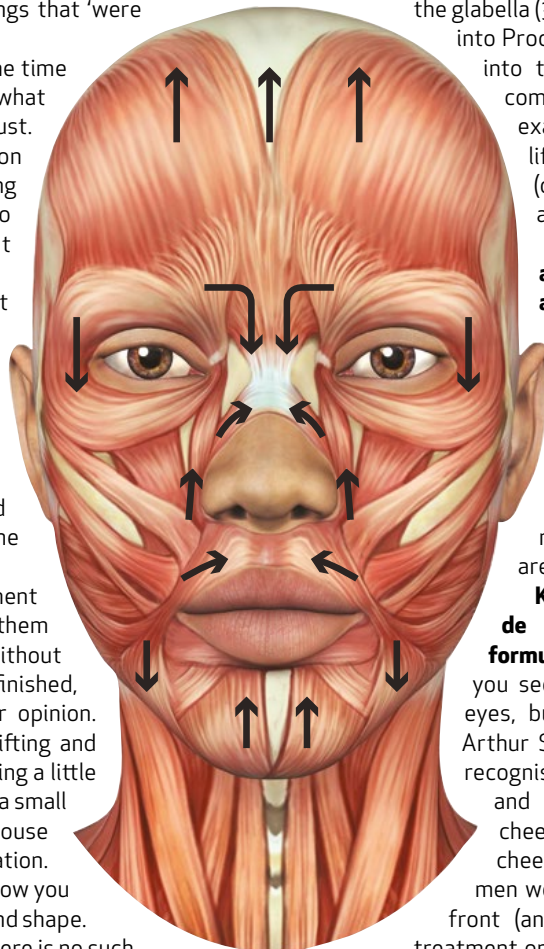


Figure: Elevator and Depressor muscles of the face.

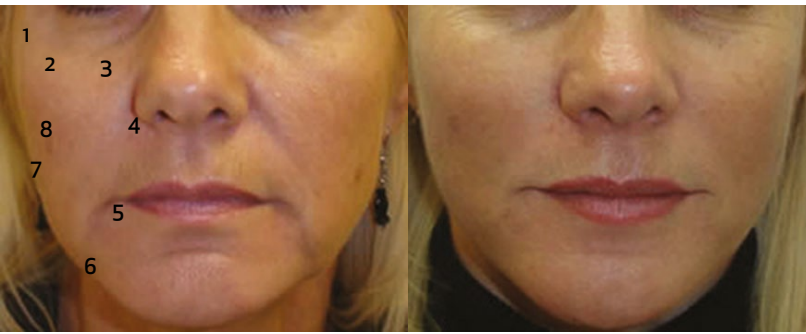

Figure: Before and After 8-point lift, by Dr Steven Harris

back in between each injection in order to assess the effects on the face as a whole.

**Keep safe and learn to identify a potential complication early.** Blanching of the skin and pain indicate vascular compromise. If this has been caused by HA, then immediately dissolve the filler with **Hyalase** and follow all the other steps for management. For a comprehensive management guide, please refer to Expert Consensus on Complications of Botulinum Toxin and Dermal Filler Treatment, Second Edition, by Inglefield et al. Do not ignore blanching and pain as this can lead to avascular necrosis.

**Know your HA fillers.** The Juvederm Ultra range (Ultra 2-4) are good all-round fillers. In my experience, Juvederm Ultra 4 may be used at all eight points of the 8-point lift. The vycross range are excellent for lifting. In general, use volbella in the forehead, Voluma in the temples; Voluma at point 1 (zygomatic arch) and point 2 (cheekbone); Volift at point 3 (mid-cheek), point 4 (nasolabials) and point 5 (marionette lines); Voluma at point 6 (pre-jowl area), point 7 (jawline) and point 8 (cheek region). For the lips, use Volbella, Volift, or Juvederm Ultra 3.

**Treat indirectly where possible.** Treating the cheek (points 1, 2 and 3) will often address the tear-trough as well as the nasolabials (and will also improve the marionette lines and the jowls).

**For maximum safety and effect, inject at the correct level:**

**Upper third:** Stay in the dermal layer (superficial) in the glabellar area (to avoid the supratrochlear and supraorbital arteries) and move to

injections on the periosteum (deep) further away on the forehead (to avoid the superficial arteries). Inject deep in the temple area (keep to the point 1cm back along the temporal line and 90 degrees 1cm down).

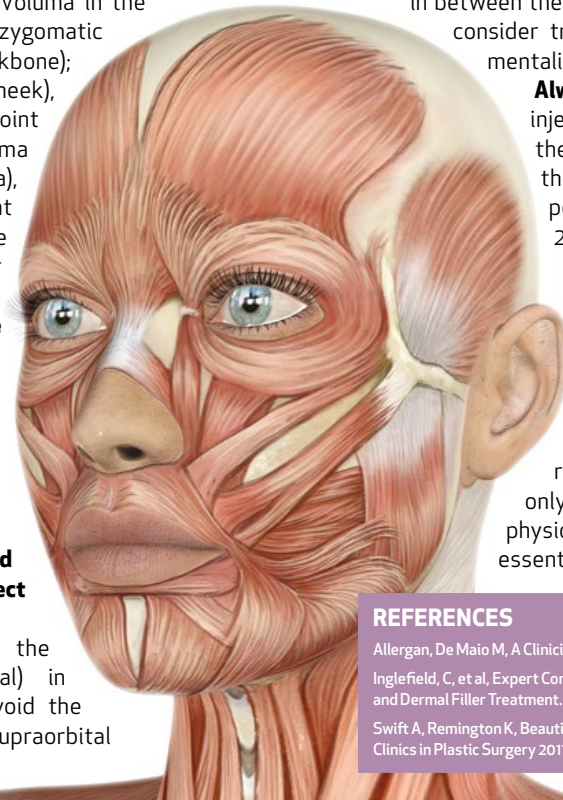
**Middle third:** Inject deep at points 1 and 2 (beware the transverse facial artery under the cheek); inject medium depth at point 3 (beware the infraorbital artery). Inject deep at point 4, the nasolabials (beware the facial artery); **Avoid the 'malar mound'**: injecting into this area attracts water. Injecting points 1, 2 and 3 will help correct the malar mound.

**Lower third:** Inject superficially at point 5 (beware the superior labial and inferior labial arteries); inject superficial to deep as you move down from point 5 to point 6 along the marionette lines; inject superficially at point 7 (beware the parotid gland); inject superficially at point 8 (beware the parotid gland, the parotid duct and the transverse facial artery). For the **lips**, inject below the vermillion border (injecting into the vermillion border can give a 'ducky look', or 'troutpout'). Respect the ratio of the lips upper:lower=1:1.618. The upper lip should have slight anterior projection and this can be achieved by a very fine injection of the cupid's bow. The upper lip can also be elevated by injecting the philtrum (may be useful to shorten an elongated philtrum).

For the **chin**, inject deep to create the desired shape and projection. In women use a one point injection in the midline and in men two point injections (in line with the corners of the mouth) to create the desired shape and length (vertical or horizontal projection, or most commonly, in between these two planes at 45 degrees). Always consider treatment with BTA as well to relax mentalis muscle.

**Always massage** immediately after injecting HA. Massage in the direction of the desired lift and shape. Also ensure the patient is given verbal and written post-care instructions and booked for a 2 week review appointment.

**In conclusion**, a systematic approach involving assessment and treatment is recommended for non-surgical facial rejuvenation. It is very important to educate the patient in this respect and emphasise treatment of the face as a whole rather than focusing on specific areas only. An intimate knowledge of anatomy, physiology and the ageing process are essential to this end. **AM**



#### REFERENCES

- Allergan, De Maio M, A Clinician's Guide to the 8-point lift. 2014 May  
 Inglefield, C, et al, Expert Consensus on Complications of Botulinum Toxin and Dermal Filler Treatment. 2nd ed. AMEG 2014 June.  
 Swift A, Remington K, BeautiPHllication: A Global Approach to Facial Beauty. Clinics in Plastic Surgery 2011 July; 38(3): 347-377



>> Dr Steven Harris, MB BCH MSc BCAM is an Aesthetic Doctor who specialises in medical procedures involving Botulinum Toxin Type A (BTA) and Hyaluronic Acid fillers (HA) to restore natural beauty in his patients. Dr Harris is a full member of the British College of Aesthetic Medicine (BCAM). He founded the Harris Clinic 12 years ago and has since performed over fifteen thousand procedures. Dr Harris is rated in the top five biggest single users of BTA and HA in the UK and has gained an international reputation for his entirely natural looking results. The Harris Clinic is based at Beauty Works in Crouch End, London.