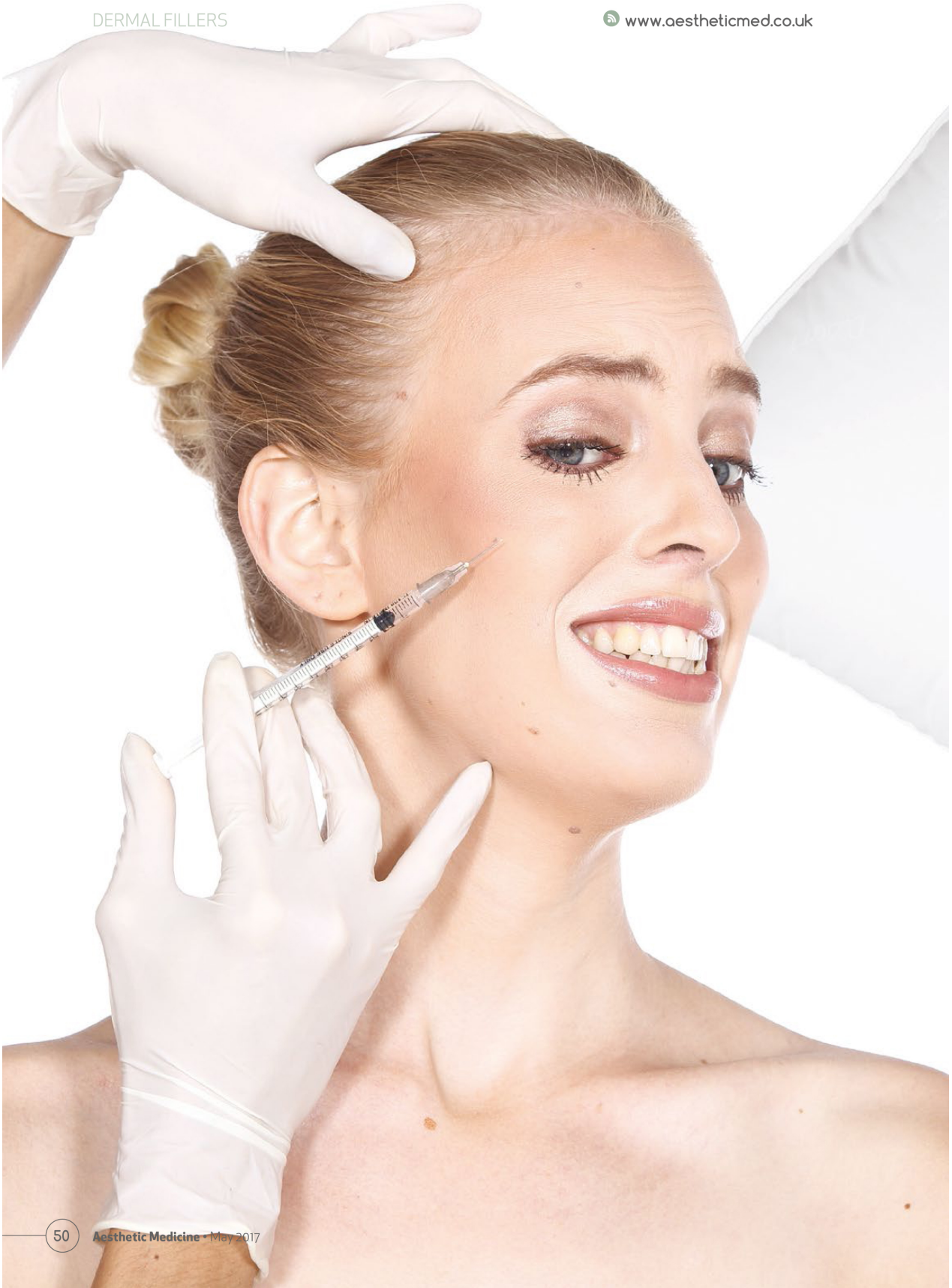

INJECTABLES

DERMAL FILLERS

[www.aestheticmed.co.uk](http://www.aestheticmed.co.uk)



# Pillow talk

Dr Steven Harris discusses the rise of the pillow face

**M**odern treatments involving fillers usually start with the mid-face as this area tends to show the earliest signs of ageing, due to loss of volume and redistribution of fat. As a result of these changes, the female face loses its ideal oval or heart-shape to become more square. Patients may also come to us complaining that they look "tired" and "saggy". In order to address these problems, the usual approach is to replace the lost malar fat and lift the ptotic soft tissues. More recently, however, there seems to be a trend towards "looking done" where an increasing number of patients (and indeed practitioners) appear to have been over-treated, resulting in the so-called "pillow face". The rising number of people with these exaggerated features is a worrying trend because it gives the aesthetics industry a bad reputation and prevents many people from seeking

treatment for fear of looking the same. Worse than that, it is also creating a new "standard of beauty" that is detached from reality and is victimising vulnerable patients, such as the young and those with Body Dysmorphic Disorder (BDD).

As aesthetic doctors, we are at the forefront of the industry and, as such, are very well-positioned to put an end to this trend, which is threatening the integrity of our profession.

We need to start communicating with colleagues and patients by sharing experiences and raising awareness at our clinics, educational meetings and conferences. We need to push for regulations to be implemented in order to restrict the practice of medical procedures to those who are medically qualified and set guidelines for the management of vulnerable patients and practitioners.

## IDENTIFYING THE "PILLOW FACE"

Sadly, the pillow face appears to be on the rise. More patients are requesting exaggerated features and over-treated practitioners are commonly seen at professional meetings and conferences.

The pillow face is easily identified (Figure 1). It is characterised by overfilling of the mid-face, especially the malar region and may involve the lips, which gives a "trout pout". The upper third of the face is also often over-treated with botulinum toxin type A (BTA) so that the patient looks constantly surprised.

There are many reasons for this trend. It is strongly linked to BDD, which is present in 1-2% of the general population, but has been reported in up to 15-20% of aesthetic patients and appears to also be common amongst aesthetic practitioners. The lack of regulation in the aesthetic industry means patients are being treated by unqualified or inexperienced practitioners, who have no awareness of the condition, have little artistic acumen, or themselves have BDD. Finally, the manufacturers and distributors are fuelling the trend by indiscriminately supplying and encouraging the use of more BTA and fillers.

## TAKE A STEP BACK

In terms of aesthetic procedures, we need to take a step back and consider the face as a whole rather than focus on isolated parts and trust our innate senses, rather than formulations, to restore the patient's ideal facial shape. This is a good place to start as it forces us to look at the "bigger picture". >



Figure 1: The Pillow Face

The ideal facial shapes have been described as oval to heart-shaped in women and oval to square in men. However, there is much variation here for example, some women with square-shaped faces can appear very attractive.

Once we have a sense of the patient's ideal shape, then we can decide how to restore the outline using a "less is more" approach. This encourages us to focus on the weakest areas. There is no logic in treating the strong areas first as the weak areas then appear weaker, and this should be explained to the patient. Once the weakest part is identified, then this may be corrected directly or indirectly. For example, jowls are corrected at the mid-face but hollowing temples, or an inherited retracted chin require direct treatments. The latter helps define the cheeks and makes the nose appear smaller (Figure 2), while treating the cheek itself opens the eye and raises the corner of the eyebrow by inhibiting the contraction of orbicularis oculi (Figure 3).

The zygomatic arches are extremely important in restoring the patient's ideal facial shape; they help reshape the eyebrows and define the jaw and chin. They are often ignored in treating the mid-face where there is an obsession with filling the malar region. High cheekbones are pronounced zygomatic arches, causing the upper part of the cheeks to form defined lines at the sides of the face (commonly seen in fashion models). In women they are linked to fertility; in men they represent high levels of testosterone (along with other prominent facial features). As a result, both men and women with high

**Before and after filler treatment of the chin (Juvederm Voluma 2mls), by Dr Steven Harris**

Before



Figure 2a

Figure 2b

After

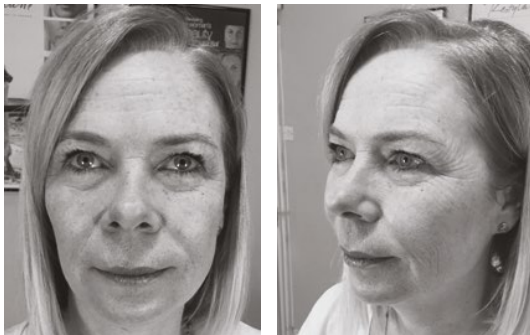

Figure 2c

Figure 2d

**Before and after treatment of the zygomatic arch (opening the eye and elevating the lateral brow) and chin with Juvederm Voluma 2mls, by Dr Steven Harris**

Before

After

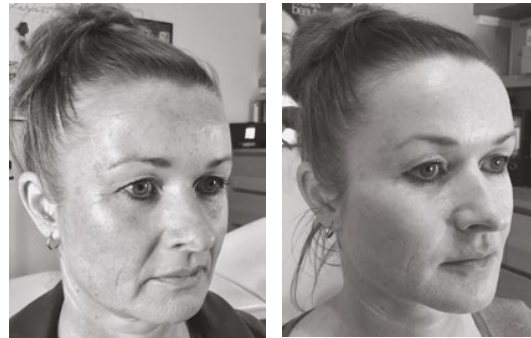

Figure 3

cheekbones are considered more attractive and this appears to be true across different cultures. The zygomatic arch is formed by the zygomatic process and the temporal process of the zygomatic bone, meeting at the zygomaticotemporal suture. The upper border of the arch gives attachment to the temporal fascia; the lower border and medial surface give origin to the masseter muscle (Figure 4).

When treating the zygomatic arches, it is important to practice safe and effective injection techniques with the correct filler type to restore the ideal shape. Only hyaluronic acid (HA) fillers should ever be used as these are considered relatively safe and are fully reversible. The ideal HA filler for this treatment would include a combination of low molecular and high molecular weight chains to facilitate shaping (moldability) and maximise lifting. Safety is of paramount importance; danger areas should be avoided and aspiration

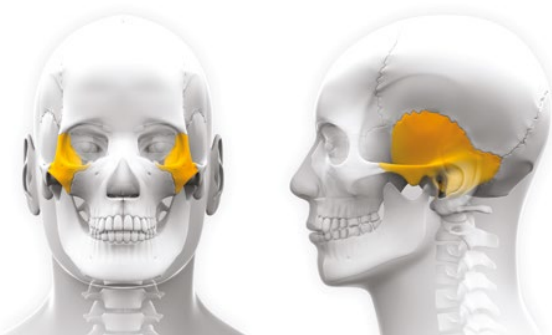


Figure 4: Zygomatic bone (left) and temporal bone (right)

should always be practiced when injecting with needles. The filler is placed deeply onto the periosteum using a needle as this is far more precise and economical than the use of a cannula. One or two injections (around 0.1-0.2mls each) on the zygomatic arch 1cm above the palpable border, and a single injection into the tip of the chin (around 0.2-0.5mls deeply in the midline) may be all that is required (Figure 5, 6). In addition to the zygomatic arches and the chin, other areas along the outline may require attention, such as hollowing temples, or bulging masseters. These may be treated with filler and BTA respectively in order to restore the desired shape.



The shapes of the eyebrows play an important role in the overall facial shape; in women they are more arched; in men they are flatter. The corners may be lifted by treating the zygomatic arches, or the hollowing temples. A more direct approach is to lift the eyebrow manually at the arch position and inject a small bolus (0.1-0.2ml) of filler deeply with a needle just below to hold position. The eyebrows may also be treated with small amounts of BTA into the depressor muscles (procerus, corrugators and orbicularis oculi) for medial elevation along with a 'V' shape pattern of injections

**Before and after treatment of zygomatic arch and chin with Juvederm Voluma 2mls, by Dr Steven Harris**

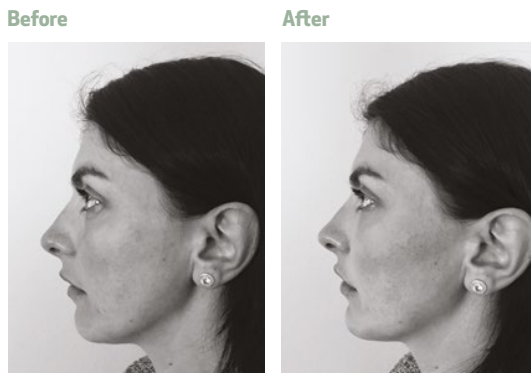

Figure 5

**Before and after treatment of zygomatic arch and chin with Juvederm Voluma 2mls, by Dr Steven Harris**

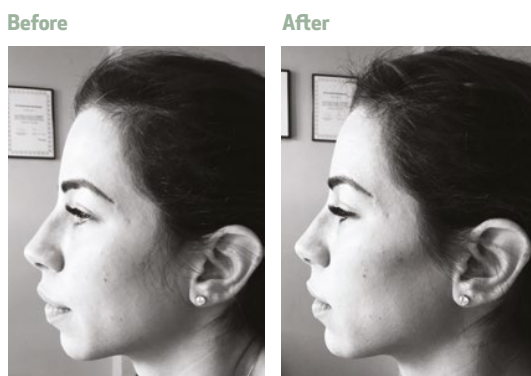

Figure 6

into the elevator muscle (frontalis) for lateral elevation. The pillow face involves over-treatment with BTA; the upper third of the face is 'frozen' and the patient looks surprised with medial collapse of the brow and exaggerated lateral elevation (Figure 1).

In conclusion, the aesthetic industry is facing a crisis; there is a complete lack of regulations meaning that it is a "free for



all" market and anyone can inject BTA and fillers. The result is that vulnerable people, especially the young and those with image disorders such as BDD present as easy targets for exaggerated treatments and they are the real victims in the equation. The pillow face represents all that is wrong with our industry; regulations are desperately needed to help save all those who are vulnerable, as well as the integrity of our own profession. As aesthetic doctors we are well-positioned to initiate the necessary changes by opening communication channels with colleagues, patients and key players in the industry, such as the manufacturers and distributors. With respect to aesthetic procedures, we need to take a step back, consider the face as whole and use our innate senses to restore the patient's ideal facial shape. **AM**

**REFERENCES**

1. Harris S, Body Dysmorphic Disorder. *Aesthetic Medicine* 2007 February: 20-22
2. Harris S, A Systematic Approach to Nonsurgical Facial Rejuvenation. *Aesthetic Medicine* 2015 June: 34-37



>> **Dr Steven Harris** MB BCh, MBCAM, MSc completed his medical studies in Johannesburg in 1997. He has been practising aesthetic medicine at his clinic in North London since 2004 and has gained a reputation for producing entirely natural looking results. Dr Harris also completed an MSc in Cognitive Behaviour Therapy in 2005 and specialises in the management of patients with Body Dysmorphic Disorder. He publishes and lectures regularly in both areas of aesthetic medicine and clinical psychology.