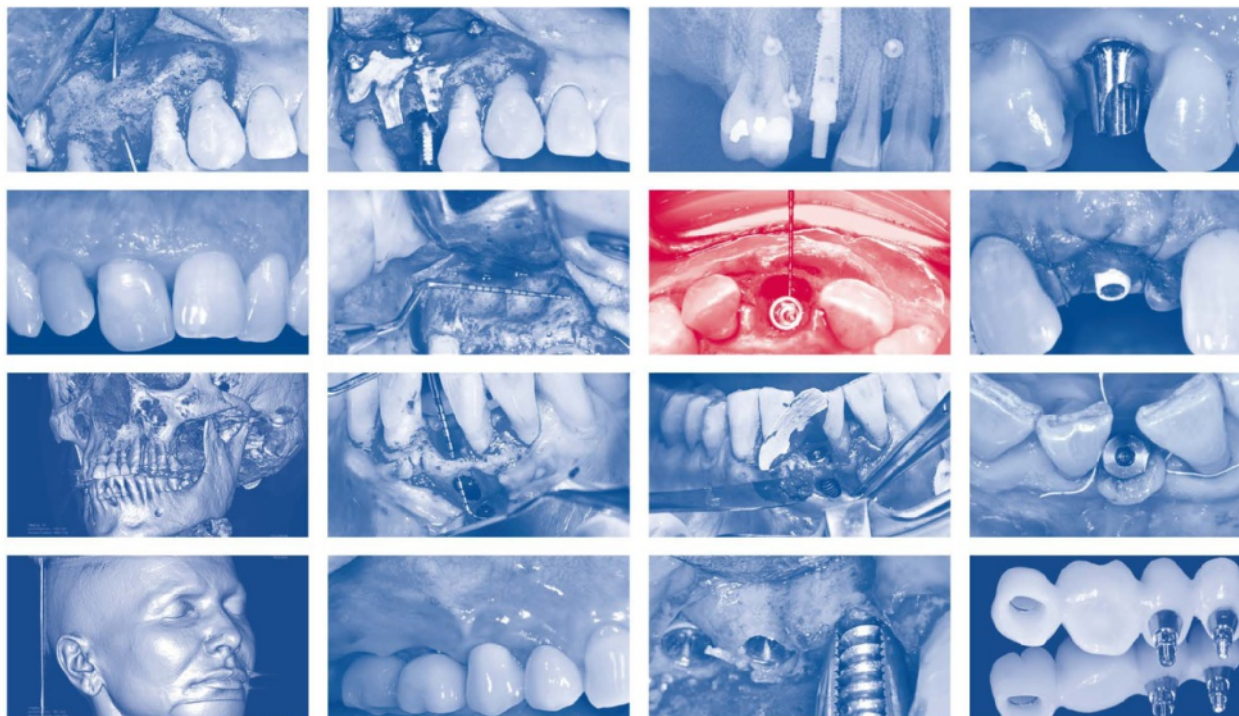

GIORGIO **TABANELLA**

copyright by
not for publication

Retreatment of Failures in Dental Medicine — A Surgical Atlas

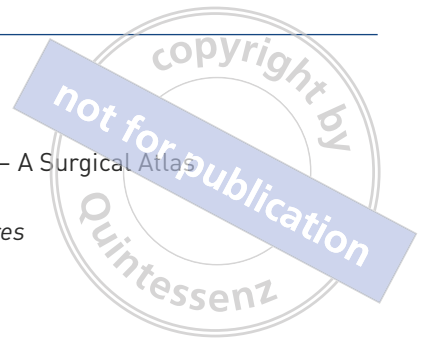Step-by-Step Clinical Procedures



Giorgio Tabanella

Retreatment of Failures in Dental Medicine — A Surgical Atlas

Step-by-Step Clinical Procedures



GIORGIO **TABANELLA**



Retreatment of Failures in Dental Medicine — A Surgical Atlas

Step-by-Step Clinical Procedures

 **QUINTESSENZ PUBLISHING**

Berlin, Barcelona, Chicago, Istanbul, London, Milan, Mexico City,
Moscow, Paris, Prague, Seoul, Tokyo, Warsaw

For Lorena, Edoardo, and Alice



A CIP record for this book is available from the British Library.
ISBN: 978-1-78698-094-6



Quintessenz Verlags-GmbH
Ifenpfad 2-4
12107 Berlin
Germany
www.quintessenz.de

Quintessence Publishing Co Ltd,
Grafton Road, New Malden,
Surrey KT3 3AB,
United Kingdom
www.quintpub.co.uk

© 2019 Quintessenz Verlags-GmbH, Berlin

All rights reserved. This book or any part thereof may not be reproduced, stored in a retrieval system, or transmitted in any form or by any means, whether electronic, mechanical, photocopying, or otherwise, without prior written permission of the publisher.

Editing: Natalie Ward, Quintessence Publishing Co Ltd, London, UK
Project Management: Anne B. Kappeler, Quintessenz Verlags-GmbH, Berlin, Germany
Layout and Production: René Kirchner, Quintessenz Verlags-GmbH, Berlin, Germany

Printed and bound in Croatia by Graficki Zavod Hrvatske d.o.o., Zagreb

FOREWORD

Altered macro and micro designs of oral implants have resulted in increased primary stability (tapered implants) and faster jaw-bone response (moderately rough implant surfaces), which have facilitated and hastened the process of osseointegration. In turn, implant surgery procedures have been adjusted to take advantage of these improvements in terms of immediate implant placement after extraction, one-stage surgery with early or immediate non-functional/functional loading and implants concurrently inserted with bone augmentation procedures. Reported outcomes have shown similar implant survival figures in selected patients compared with the more time-consuming traditional techniques.

The elegant images and videos in the present publication illustrate these procedures and are accompanied by well-presented anamnestic data, radiographic examinations and proper treatment plans. The publication shows how compromised teeth that may be

due to a patient's mishaps, poor compliance or less-successful previous dentistry are professionally handled through careful extractions, immediate implant placement and augmentation with mainly bovine bone material. By reducing the number of surgical procedures, the total treatment time is significantly shortened and patients are left with healthy tissue and esthetic implant/tooth-supported restorations. The positive psychological impact of this for many of them cannot be emphasised enough.

In conclusion, this case series may serve as a guideline for many dental surgeons involved in implant dentistry.

Göteborg, 16 June 2019
The Brånemark Clinic

Bertil Friberg, DDS, MDS, PhD



ACKNOWLEDGMENTS

The author would like to express his deepest gratitude to Lorena Bordi for offering her assistance during this challenging project and Dr Emanuele Nicolini for his technical support during the shooting of the surgeries.



INTRODUCTION

Complications or failures are unfavourable consequences of a disease, a health condition or a therapy. They can also be iatrogenic and might affect the prognosis of a disease. Complications or failures can occur at the level of the organization, objective, team or work environment and can have a strong negative emotional impact on the practitioners who experience them. However, patient harm can occur even when a physician is knowledgeable and skilled and follows the best practice with excellent execution. Furthermore, failures may be related to patient behaviour, as not only doctors and medical staff but also patients play a major role in the success of a therapy. In fact, poor patient compliance such as smoking habits, poor oral hygiene or non-compliance with postoperative instructions can lead to failure.

There is a general idea in the community that any medical issue can be solved with medication or doctors' interventions. This is not always valid: failure is part of the medical profession.

On the opposite, a medical error is a preventable adverse effect that harms patients. It can occur at different stages of the treatment process: diagnosis, prognosis, treatment or technique. In the medical profession, these types of errors are generally considered to be human errors. Medical errors are associated with various factors including inexperienced clinicians, new procedures, patient age, complex or urgent treatments, poor communication, improper documentation, inadequate assistance, poorly designed treatment and errors of judgement. Practitioner risk factors include prejudiced thinking, sleep deprivation, fatigue, depression and burnout.

Cost-cutting measures may also compromise treatment outcomes. Many medical achieve-

ments have been obtained after significant investment and at a very high cost. As a result, some therapies may not be affordable for some patients, who could find themselves excluded from the benefits of the most advanced treatments.

Some failures may be related to the limitations of the medical profession; others may occur when doctors are mainly focused on their own ego rather than on defining the best treatment for their patients. This is a risk that may also cause a loss of trust in the medical profession.

Few doctors can claim that they have gone through their entire career without failing at something. However, the best doctors are those who have experienced fewer failures and who have been also able to manage their failures. In fact, medicine may have some limitations as regards to the treatment of certain pathologies.

Positive thinking after a complication or failure is the key. It is tremendously useful to admit when things go wrong; it is especially important to think about what could have been done to avoid the failure. Furthermore, complications and failures are an intrinsic part of many competitive professional environments. The best approach is to try to learn from an adverse event so that one can be more successful in the future.

In general, physicians are embarrassed to talk about their mistakes. However, sharing failures with colleagues can make the discussion about them feel normal. Medicine revolves around a culture of perfectionism and this is certainly also what medical professionals want. Being able to cope with failures is not a problem unique to the medical field. However, compared with other professions, medicine blends work life with real life. In fact, most

doctors do not describe what they do as a job because being a doctor is what they are and not only what they do. A doctor's need to be successful in medicine is almost like a reflection of his or her personal success in life.

Considering failures as part of medicine in general would help doctors to share their negative experiences and turn them into positive ones. This idea should be incorporated into medical education as a first step towards normalizing the culture of failure in medicine. Doctors need to be less hard on themselves; in fact, most adverse events are caused not by negligence or carelessness but by inevitable human error. Doctors ought to strive to do things better, yet they also need to acknowledge their fallibility and implement approaches to reduce the aspect of human error. The acceptance of this concept would represent a change of attitude and would create a more productive and positive atmosphere. Adverse events should be analyzed and measured so that changes can be introduced to prevent their recurrence. Writing and talking as well as lecturing about failures would help to reduce medical errors in the long term and increase patient safety. The goal of this project is to share critical information for the retreatment of failures in dental medicine. Human performance, optimization of the diagnostic and therapeutic process, access to technology and state-of-the-art treatment are all beneficial in the drive to expand medical knowledge.

The perception of failure is quite common in trainees and trainers. We consciously judge ourselves against internal criteria. The only people who can remedy a failure are those responsible for it. The point is to recognize the nature of the failure and research the problem. Many of most successful doctors have recovered from a failure by focusing on the medical work. To remedy a failure, a doctor essentially needs to prepare for the next treatment as he

should have prepared for the last. We all experience good and bad days, but luck should have nothing to do with a successful treatment. The preparation for treating a patient should include skills, attitude, knowledge, training, decision making and common sense. Trainees should be seen to demonstrate a progressive acquisition of knowledge, skills and experience. Also, senior doctors should periodically be checked by their peers to evaluate whether their knowledge and practice is up to date.

Medicine is linked to other sciences, but at the same time is independent and isolated in the sense that it deals with diseases and patients and could therefore be considered unique. First, it is important to define the disease and ask specific questions: What is a medical doctor supposed to do? Treat the symptoms? The pathology? Or both? If we have the tendency to treat what we hear, see and feel rather than the disease itself, we are not doing the right thing. The patient and the disease should be treated simultaneously. Apart from this, the patient's health ought to be restored by avoiding 'false' methods of treatment. Doctors need to be aware that, as medical professionals, they could be influenced in their clinical decision making by their morals, values and judgements as well as by their mental or emotional status. This reality may have an influence on the analytical evaluation of patients.

An accurate system of diagnosis must be considered the main pillar of all treatments. Nevertheless, failure is part of medicine and must be considered as such in order to properly treat and hopefully cure patients. Furthermore, 'fashions' in medicine such as new drugs or technologies need to be considered carefully. A calm and judicious summing up must be based on evidence.

In order to better guide us in our clinical decision making, every decision about the care

of any individual should be based on explicit, conscientious and judicious use of current best evidence. This approach, known as evidence-based medicine, leads to improvements in medical knowledge, provides a valid framework for teaching, contributes to decision making, allows for better communication with patients and enables doctors to treat patients more successfully. However, evidence-based medicine does not necessarily ensure that better decisions are made. It is not entirely clear how doctors incorporate evidence into their final decisions, since it seems that the practice of medicine is never entirely free of personal judgement. This difficulty is mainly related to the fact that many treatment outcomes cannot be properly identified or measured. It is also unclear which parameters should be considered when determining the outcomes of a specific treatment, and some conclusions could also be considered unethical from a different point of view, for example, the treatment of a failing dentition in a young versus an elderly patient. Defining an esthetic outcome or a patient's quality of life during and after treatment may be very difficult, especially if these variables are not quantifiable. Evidence-based medicine often rejects the opinion of experts who are mainly doctors who have interpreted research findings and objectives. Meta-analyses are generally considered the most precise statistical methods to evaluate the efficacy of a treatment. However, they might not include some studies that could be of clinical relevance but have low statistical power. Therefore, evidence-based medicine may be interpreted as biased, since it is based on those treatments for which there is evidence, yet without considering the efficacy of individual treatments. It is obvious that complex issues cannot be solved with simplistic solutions and decision making seems, then, to be a reasoning process that is partially based on personal values.

The nature of error in medicine is mainly related to the lack of expertise and training. It is also evident that accidents and mistakes generally do not have a single cause but result from a string of latent flaws. It is also true that there is a trend to underestimate the role of social, relational and organizational factors as well as patient compliance. There is a strong link between poor communication, errors and adverse events.

There is an urgent need in medicine to increase attention to errors, adverse outcomes, quality of treatment and results. The more treatments performed, the higher the risk of failure. However, few studies focus on the cause of adverse effects, and those that do are mainly in a hospital setting. The cause may lie in the combination of several human factors such as a lack of communication, an excessive workload or inadequate training. However, doctors' personalities also play a role, including overconfidence. Human decisions are responsible for almost all failures, including those related to patient compliance. Some failures also occur as a result of motivational problems or inadequate management. Lack of experience, inadequate knowledge, a stressful environment and inadequate equipment are other important considerations when assessing complications and failures, as are the economic context and personal characteristics of the patient, such as the language spoken, the patient's personality and the level of compliance.

A patient's disease is the most powerful predictor of the clinical outcome. As there is very little if any research on the aspects discussed here, it is of extreme value to share the re-treatment of complications and failures with colleagues. The ultimate goal is to acknowledge the potential for error and to finally help doctors improve the safety and overall quality of care of their patients.

TABLE OF CONTENT

Foreword	___	V
Acknowledgments	___	VI
Introduction	___	VII

Chapter 1

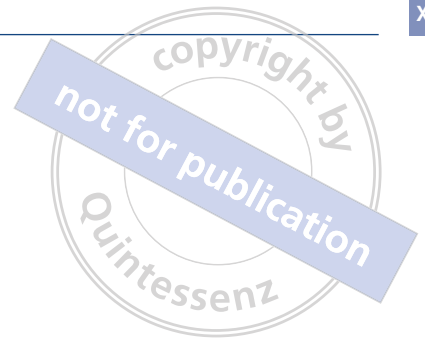Endo failure – Tooth loss and perforation of the buccal plate | **1**

Introduction	___	4
Anamnesis/medical history	___	4
Dental history	___	4
Chief complaint	___	5
Radiographic findings	___	5
Clinical findings	___	7
Diagnosis	___	7
Prognosis	___	8
Indications and objectives	___	8
Criteria for decision making	___	8
Treatment planning	___	9
Instruments and techniques	___	9
Treatment results	___	26
Take-home message	___	37
References	___	40

Chapter 2

Diagnostic failure – Mistreated trauma associated with periapical chronic lesions and anatomical bone deformities | **43**

Introduction	___	46
Anamnesis/medical history	___	46
Dental history	___	46
Chief complaint	___	46
Radiographic findings	___	49
Clinical findings	___	52
Diagnosis	___	53
Prognosis	___	53
Indications and objectives	___	53
Criteria for decision making	___	53
Treatment planning	___	54
Instruments and techniques	___	54
Treatment results	___	92
Take-home message	___	96
References	___	98



Chapter 3

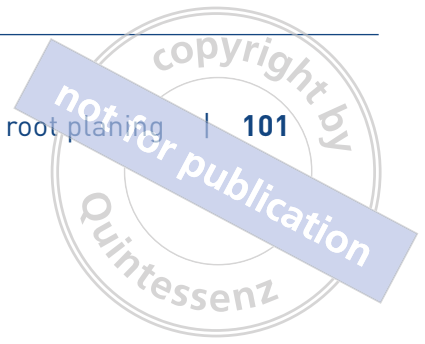Perio failure – Recurrent and excessive scaling and root planing | 101

Introduction	104
Anamnesis/medical history	105
Dental history	105
Chief complaint	105
Radiographic findings	105
Clinical findings	108
Diagnosis	109
Prognosis	109
Indications and objectives	109
Criteria for decision making	109
Treatment planning	110
Instruments and techniques	110
Treatment results	126
Take-home message	133
References	136

Chapter 4

Implant failure – Iatrogenic bone grafting and implant placement: Ailing dental implants associated with oroantral communication | 139

Introduction	142
Anamnesis/medical history	142
Dental history	142
Chief complaint	143
Radiographic findings	143
Clinical findings	144
Diagnosis	144
Prognosis	144
Indications and objectives	145
Criteria for decision making	145
Treatment planning	147
Instruments and techniques	147
Treatment results	181
Take-home message	183
References	184

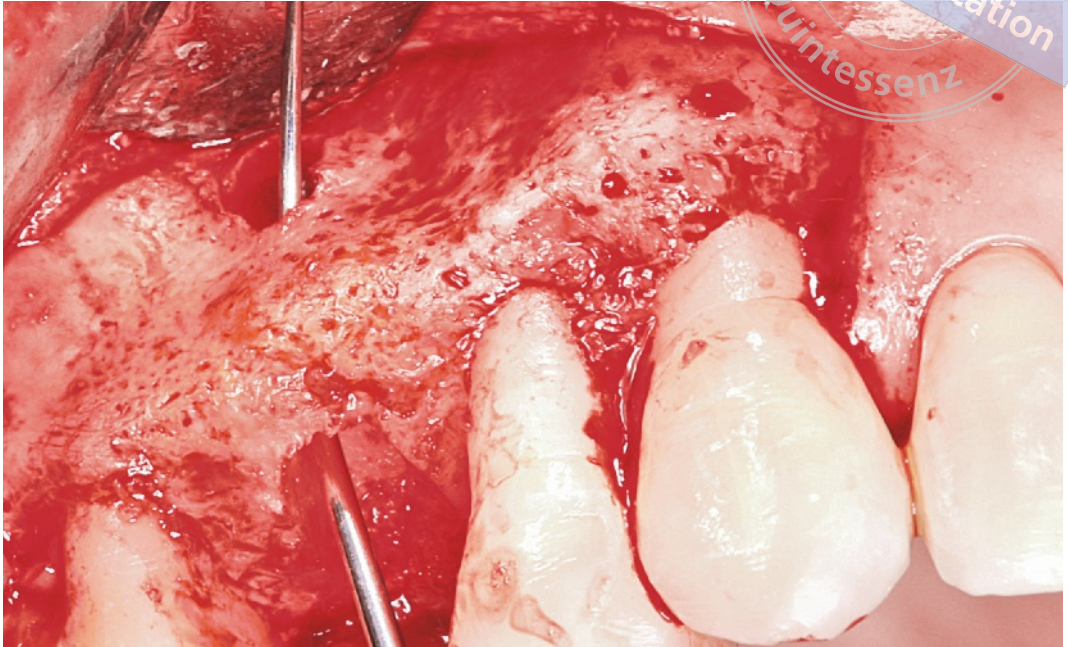


CHAPTER 1

ENDO FAILURE

Tooth loss and perforation
of the buccal plate





For more in-depth information on the clinical case, please check out the video by scanning the QR code (runtime: 20 min.).



Endodontic failures represent the etiology of about one-third of tooth extractions. When a periapical lesion is left in the socket it is well known this could lead to a lack of osseointegration, thus reducing the implant success rate when the implant is simultaneously inserted. However, the increased demand for reducing healing time is forcing modern periodontists and surgeons to challenge traditional surgi-

cal protocols. The purpose of presenting this clinical case is to demonstrate a step-by-step surgical approach to diminish treatment time, while still minimizing the chance of complications: immediate placement and loading, and also a simultaneous bone grafting inside and outside the alveolus enabled this presented case to be completed in only 4 months of healing time.

1.1 INTRODUCTION

The risk of treating patients who have been through iatrogenic treatment must be properly calculated, since a minor complication during treatment may cause a tremendous amount of bone loss and soft tissue deformities. These complications can also be higher in numbers and more severe when a medical mistake has previously occurred. Furthermore, the psychological aspect of these patients who, in case of complications would need multiple surgeries and treatments, may effect the treatment itself. In any case, the treatment focus is to achieve a peri-implant positive bony architecture that will support and stabilize the surrounding mucosa. Soft and hard tissue manipulation will help to create a stable peri-implant sealing that will maintain the esthetic treatment results over time. The presented philosophy of work can lead implantology to a different level, since patients' desires and quality of life during treatment could be significantly improved. Thus, factors crucial to achieve a biomimetic and long-lasting result will also be emphasized.

Patients who have been unlucky enough to experience complications resulting from treatment have a unique approach towards the new specialist who is going to cure them: they are doubtful, as well as reluctant, but still willing to be treated. Their emotions are predominant and they have lost respect and confidence for medical discipline and doctors. In general, this type of patient does not have a positive or cooperative approach towards the new team of specialists. It is therefore imperative to first define a correct diagnosis and then visualize the final desirable results. Modern technology can help to envisage what the patient and surgeon would like to achieve, however digital tools need to be supported by biological principles. Only biology, anatomy, vascularization, type of defect, potential for tissue regenera-

tion, surgical skills, and experience will confirm if what was visualized during the diagnostic phase is achievable or not.

Another important point is to approach these retreatment cases with advanced techniques and modified protocols in order to reduce the overall healing time, since these patients are drained of all energy after previous treatment.

Therefore, a reduced timing is an important parameter to avoid patients opting for the easiest and fastest treatment, such as a fixed or removable partial denture: this particular treatment will then force patients to face further retreatments, especially those who were young at the time of the first treatment.

Once the diagnosis has been defined and a patient's chief complaint registered, the final treatment planning can be executed.

1.2 ANAMNESIS/MEDICAL HISTORY

A 45-year-old female patient presented with pain and no suppuration on the inferior border of the right zygomatic bone (Figs 1 to 8). Her medical history reported no significant systemic diseases except for a mild hypotension. The patient, at the time of treatment, was not under any medication.

1.3 DENTAL HISTORY

The patient reported to have received dental treatment for almost all her life. In her childhood she received orthodontic treatment and minor caries were treated mainly with amalgam and only a few with composite restorations on teeth #17, 16, 26, 27, 37, 45 and 46. After this initial phase of dental treatment she had no further decay. At about the age of 25 she lost the first mandibular left molar (#36) and after a few years, tooth #47. Both mandibular molars were mobile at the time of extrac-

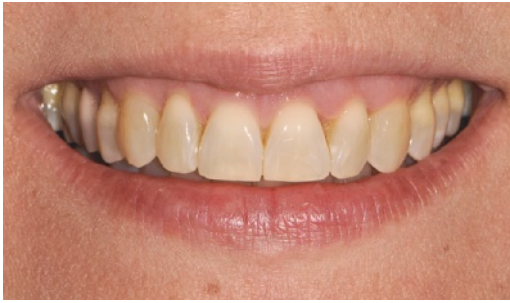

Fig 1 The preclinical picture shows a gummy smile and papillae collapse due to a progressive aggressive periodontitis, which shifted towards a chronic adult periodontal disease. The interproximal black triangles represent the complete loss of the mesial and distal bony peaks.

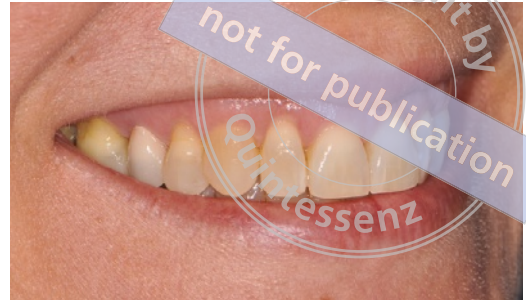

Fig 2 The three-quarter view presents a fixed partial denture on tooth #15. The presence of a gummy smile extending up to the second maxillary molar is a risk factor to be evaluated properly for the final esthetic result.

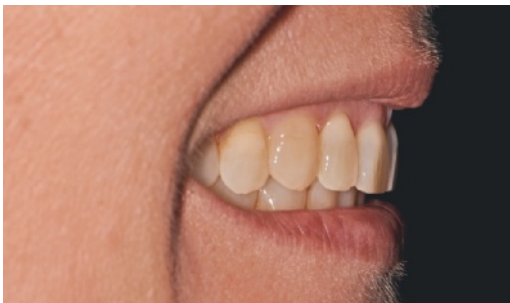

Fig 3 The traditional lateral view does not show the esthetic issue that could decrease the success rate of treating this clinical case: the gummy smile.

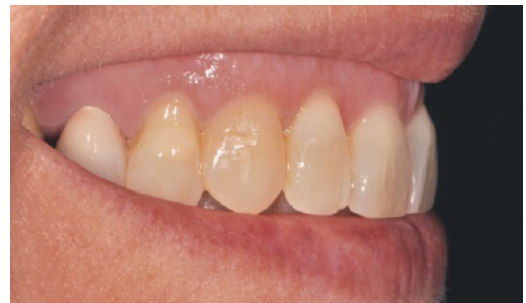

Fig 4 The exaggerated smile in the lateral view shows some of the difficulties in treating this iatrogenic clinical case: the presence of chronic adult periodontal disease and a damaged periodontium of the neighboring dentition.

tion, but the patient could not remember the reason for their removal. A few months after the extraction a dental implant was inserted and then loaded in area #36. As an adult, the patient was treated with root canals, post and core on teeth #15, #45 and #46. Only teeth #15 and #37 were restored after endodontic treatment.

1.4 CHIEF COMPLAINT

“I have a terrible pain on my upper right that also reaches my right eye. I would like to get rid of the pain and also understand if these empty spaces between the teeth can be eliminated.”

1.5 RADIOGRAPHIC FINDINGS

Full mouth radiographs (Fig 9) reported a periapical lesion on tooth #15, deep decay on the distal aspect of tooth #27, and a generalized advanced horizontal bone loss with deep intrabony defect in areas #27, and 45. Advanced bone loss was registered also distal to #17 and #27. A furcation involvement on teeth #37 and #46 was present. Furthermore, a tri-dimensional reconstruction showed a buccal plate perforation due to the periapical lesion on #15 (Figs 10 to 13).

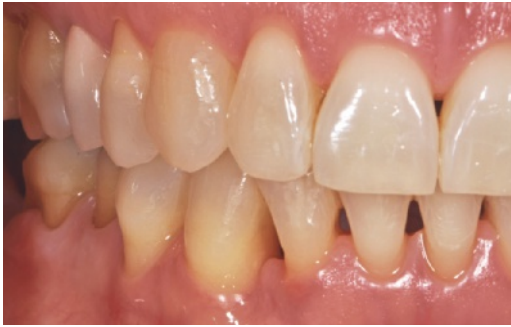

Fig 5 A wider view of the posterior and anterior sextants reveals the presence of advanced periodontitis and plaque-induced mucogingival recessions.

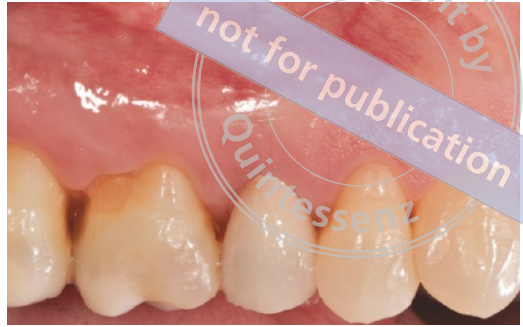

Fig 6 The patient reported localized pain at the apical area of the second maxillary premolar adjacent to the frenum insertion. No suppuration or fistula is present.

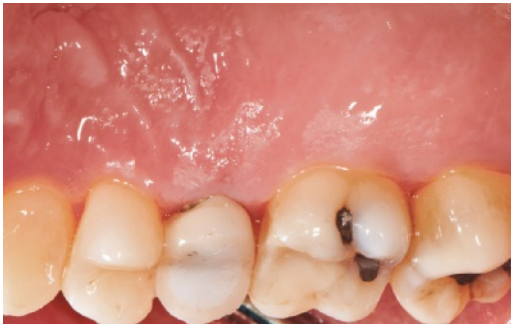

Fig 7 The palatal aspect shows an overhang restoration and an open margin on the mesial of tooth #15.

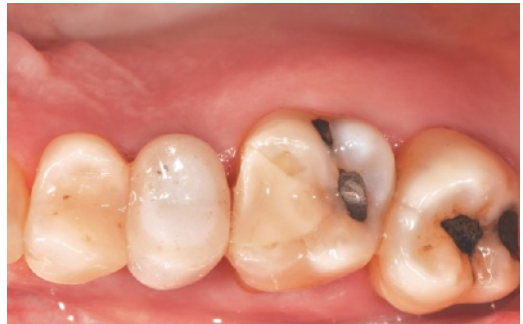

Fig 8 The occlusal view shows inflamed gingival tissue associated with wide embrasures due to advanced periodontal disease.

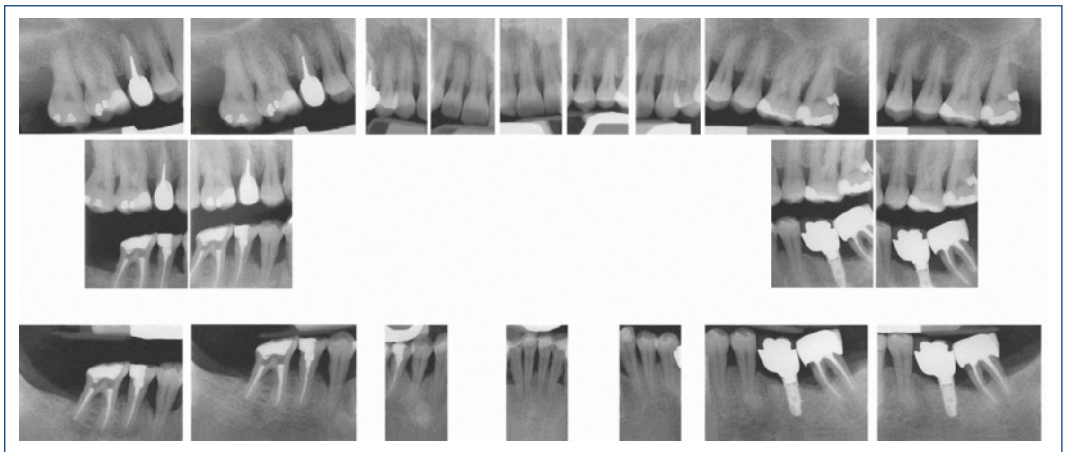


Fig 9 The full-mouth radiograph reports a generalized advanced horizontal bone loss, deep caries, perio-endo lesions, intrabony defects, a chronic periapical lesion on the symptomatic site, and an overall progressive iatrogenic dental treatment associated with a diagnostic failure and an advanced periodontal disease.

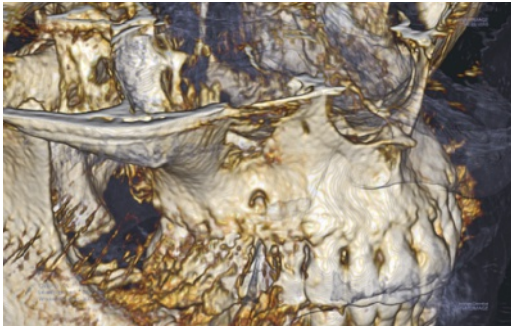


Fig 10 The 3D reconstruction better describes the periapical lesion on the second maxillary premolar.

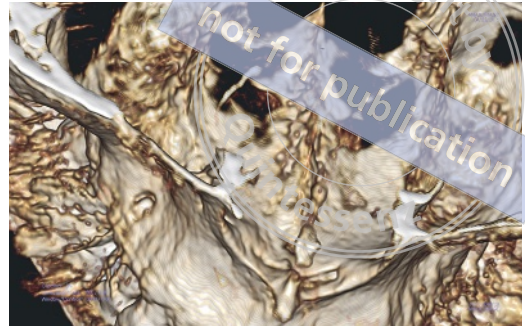


Fig 11 The chronic endodontic lesion, due to an iatrogenic treatment, perforated the buccal plate, creating a fenestration. The patient was able to clearly point to the symptomatic site. Only the 3D reconstruction can describe the extension and morphology of the periapical pathosis.

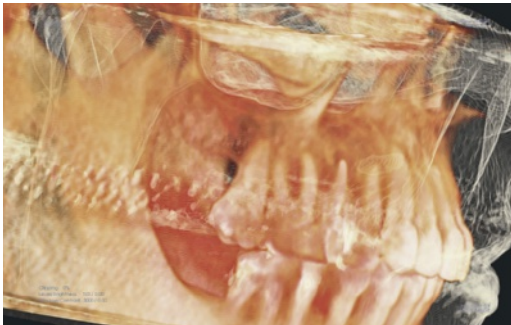

Fig 12 Different filters can be utilized to better define and study the defect.

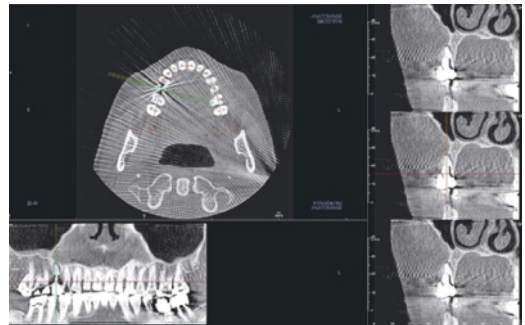


Fig 13 A panorex view with a thickness of 0.1mm allows the lesion to be analyzed in the buccal-palatal direction.

Pocket		5 2 4 7 5 5	4 2 4 5 4 5	4 2 3 4 3 3	3 2 3 4 2 4	3 2 4 3 2 4	4 2 4 4 2 3	5 2 3 3 2 3	3 2 4 3 3 5	4 2 5 5 3 5	5 2 4 5 3 4	5 2 5 3 5 5	5 2 5 5 5 3	5 3 4 4 2 7	4 3 8 5 3 10	
	18	17	16	15	14	13	12	11	21	22	23	24	25	26	27	28
	48	47	46	45	44	43	42	41	31	32	33	34	35	36	37	38
Pocket		5 3 7 6 3 4	7 3 5 5 3 5	4 3 7 5 3 5	7 2 5 4 3 7	7 2 3 7 3 4	2 2 4 3 3 4	4 3 2 5 3 3	3 2 7 3 2 7	7 2 3 6 2 3	4 3 4 3 2 5	5 3 5 5 2 4	0 0 0 0 0 0	8 7 7 7 6 6		

Fig 14 Periodontal probings clearly revealed a generalized advanced chronic adult periodontal disease.

1.6 CLINICAL FINDINGS

The clinical examination reported overall mucogingival deformities and recessions of class I, II and III. The periodontal probings showed generalized advanced attachment loss (Figs 14 and 15).

1.7 DIAGNOSIS

Progressive generalized advanced aggressive periodontitis; generalized advanced adult chronic periodontal disease; mucogingival deformities; partial edentulism of teeth #36 and 47; advanced decay on tooth #27; overhang

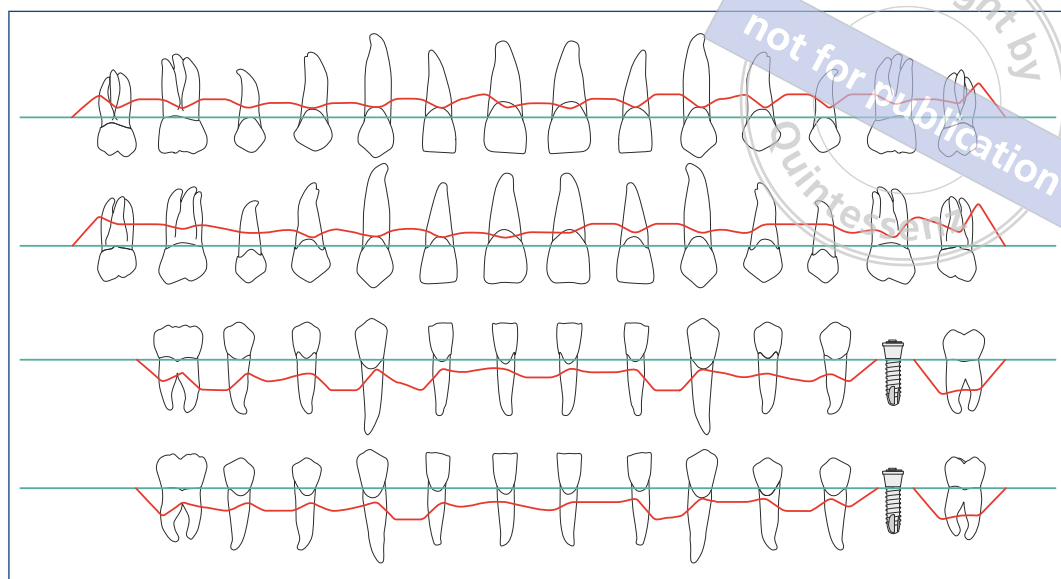


Fig 15 The overall advanced horizontal peri-dental bone loss is associated with larger intrabony defects in the posterior regions.

restorations on teeth #15 and 37; endodontic failure on tooth #15, and periapical pathosis.

1.8 PROGNOSIS

Fair:	#16, #14-26, and #35-34
Guarded:	#26, and #45-33
Poor:	#17, #15, #27, #37, and #46
Overall:	fair

1.9 INDICATIONS AND OBJECTIVES

Radiographic and periodontal examination revealed clearly the presence of generalized advanced chronic periodontitis on a reduced and diseased periodontium that was previously affected by aggressive periodontitis. The shift of the microbiota from aggressive perio-pathogens to a plaque-induced chronic periodontitis is supported by the patient's dental history since she reported caries for a short period of time. Thus, it is likely that the patient had aggressive periodontitis in her early 20s,

then a shift of the microbiota towards caries pathogens, and finally a plaque-induced periodontitis that is chronic periodontitis. It is quite obvious the patient was never diagnosed for periodontal disease and that poor dental treatment was executed.

The overall treatment was based on a periodontal approach, but because of the symptomatic site on tooth #15, the surgical phase started from the first sextant. It was imperative to discuss with the patient the need for a full mouth eradication of periodontal disease, since a possible implant placement in area #15 could have led to future complications, such as peri-implantitis. It was crucial to assess the periodontal status, but also the risk of retreating this clinical case. All the surgical variables were analyzed prior to surgical phase.

1.10 CRITERIA FOR DECISION MAKING

Traditional treatment planning of this clinical case would have included:

- 1) Extraction of all teeth with a poor prognosis and delivery of a provisional;
- 2) Non-surgical treatment of periodontal disease;
- 3) Re-evaluation at between 4 and 6 weeks;
- 4) Periodontal surgery in areas with a residual pocket of more than 5 mm in depth;
- 5) Bone augmentation in atrophic areas;
- 6) Healing time of approximately 6 months;
- 7) Endosseous implant placement;
- 8) An average healing period of 4 months;
- 9) Second-stage surgery;
- 10) A de-epithelialized connective tissue graft;
- 11) Healing of the soft tissue for at least 3 months for its maturation;
- 12) Provisional phase;
- 13) Definitive implant-supported fixed partial denture.

According to the above treatment planning, the overall healing time would have lasted more than 2 years. This traditional approach would have not considered the patient's emotional status. It was felt of value for the patient to develop a novel protocol to speed up the overall healing period: performing all the surgical steps in only one surgical phase and immediately loading the implant. It is the author's opinion that the patient's desires and feelings should be included as variables in driving clinicians to the best treatment option. This is of importance, especially when patients who have been mistreated need to build trust in a new team of specialists. Timing for these "special" patients is crucial for treatment planning acceptance. Furthermore, it is relevant to consider that this type of approach, if not well controlled and designed, could lead to major failures and bone loss around the neck of the implant, or even implant failure. However, giving the patient the chance to finalize the case in only 4 months would have increased the risks, but also increased the acceptance

rate. A meticulous analysis had to be done before sharing the treatment planning with the patient herself since it was evident that there was no room for error: any patient that has been mistreated in the past would never accept any adverse event.

The criteria for decision making are initially based on a patient's periodontal status. A long list of variables must then be addressed.

1.11 TREATMENT PLANNING

- 1) Full mouth scaling and root planing;
- 2) Re-evaluation at 4 weeks and final treatment planning;
- 3) Extraction of teeth #17 and #15;
- 4) Simultaneous immediate placement;
- 5) Guided bone regeneration;
- 6) Immediate loading;
- 7) Delivery of final restoration after 4 months of tissue maturation and loading;
- 8) Follow up, maintenance and supportive therapy.

1.12 INSTRUMENTS AND TECHNIQUES

No osseous resective surgery was necessary to treat the residual periodontal pockets since after the non-surgical phase all the defects were localized in area #17-16. By extracting #17, because of the class III furcation involvement, the crater distal to #16 was spontaneously eliminated. The extraction of #15 due to endodontic failure allowed the crater mesial to #16 to be leveled and the implant to be simultaneously inserted. The premolar was gently extracted, paying attention to preserving the thin buccal plate. A 15C blade was inserted into the sulcus to dissect the gingival fibers and an ultrasonic device then used to create a narrow space to insert the elevator and luxate the natural tooth. The blood that reached

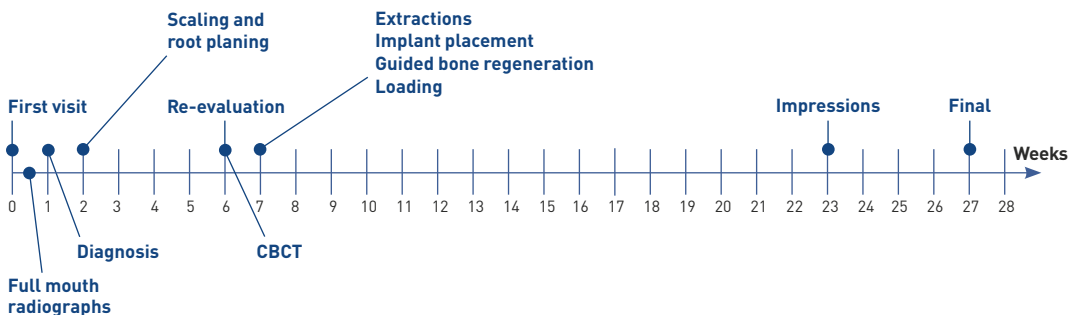
the “artificial circumferential bony defect” allowed easy removal of the tooth without breaking the buccal plate (Figs 16 to 21). After extraction (Figs 22 to 27), an underprepared osteotomy site was executed (Figs 28 and 29). The osteotomy was slightly palatal so that the majority of the empty socket could be left on the buccal aspect: this also allowed a better management of the most critical area to reach a natural looking esthetic. After the extraction, the granulation tissue was removed from the socket. Through a combination of precision drill, twist drill, osteotomes, and tapered drill, the osteotomy site was created. A screw-tap was used on the most coronal part of the osteotomy in order to release the cortical stress around the neck of the implant. An endosseous dental implant (Nobel Replace Groovy CC, 3.5 mm × 13.0 mm) was then inserted and stabilized (Figs 30 to 32).

A non-cross-linked resorbable collagen membrane (Figs 33 to 37) was then trimmed to simulate a “butterfly shape” and fixed by pins on the depth of the vestibule leaving the

entrance of the “artificial five-wall infrabony defect” coronal. By stabilizing the membrane using this approach, it was possible to have better visibility and bleeding control, as well as condensation of the bone particles both inside the socket and outside the buccal plate. This approach also significantly reduces the natural bucco-lingual bone loss that occurs after tooth extraction.

A demineralized bovine bone was packed into the defect to fill up the gap and reduce the buccal-lingual collapse of the alveolar bone. Finally, the membrane was stabilized on the mesial and distal aspect of the implant. An immediate abutment was screwed on the implant platform and the implant simultaneously loaded with a temporary crown (Figs 38 to 45). After only 4 months of tissue healing and maturation (Figs 46 to 63), a final impression was registered. A CAD/CAM titanium abutment and a CAD/CAM full ceramic crown were delivered. Simultaneously, tooth #16 was restored with a CAD/CAM full ceramic restoration (Figs 65 to 78).

Timeline



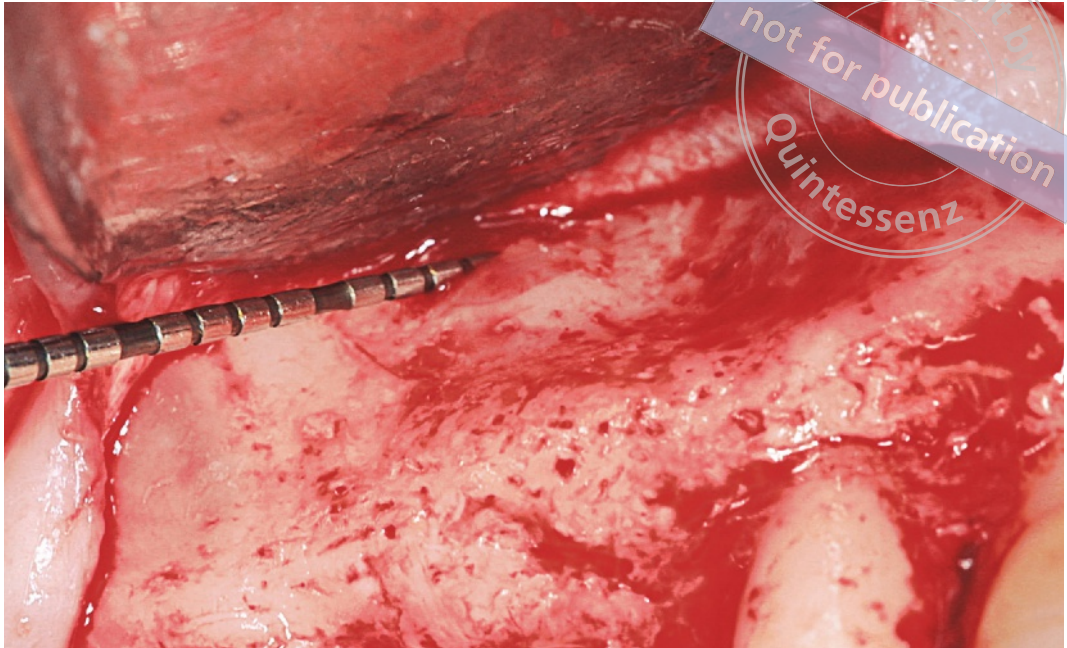


Fig 16 A large full thickness flap is elevated mesial to the cuspid and distal to the second maxillary molar. After having gently raised the flap, the endodontic lesion can be seen. The deep buccal concavity is clearly a predisposing factor for the bony perforation since a poor bone thickness is not sufficient to limit the lesion itself.

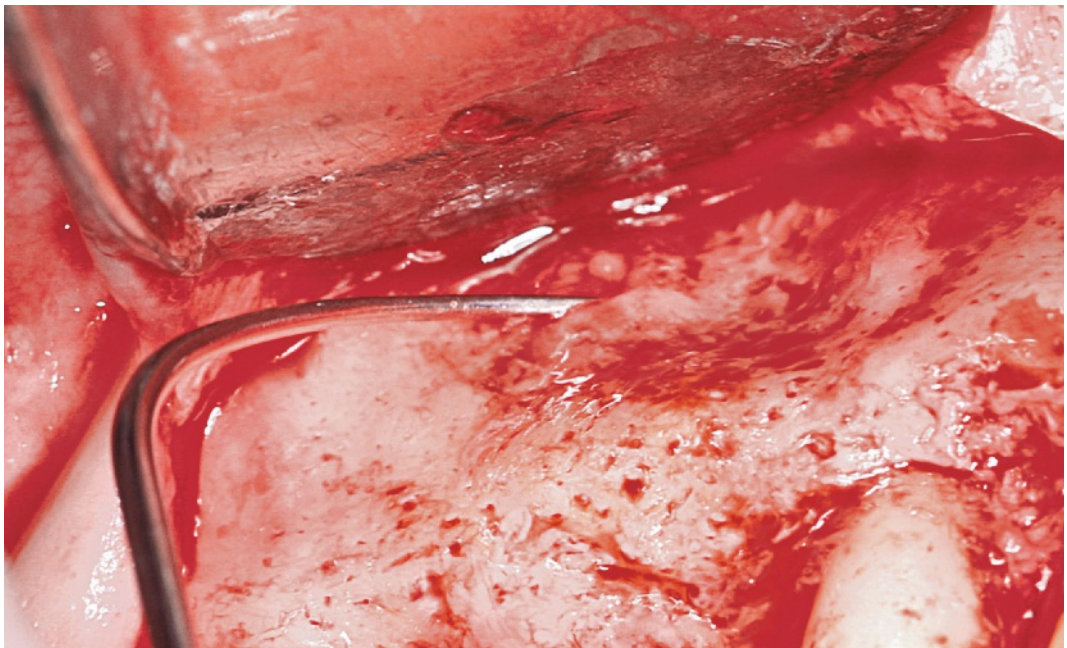


Fig 17 A periodontal explorer is initially utilized to understand the depth and the dimension of the lesion.

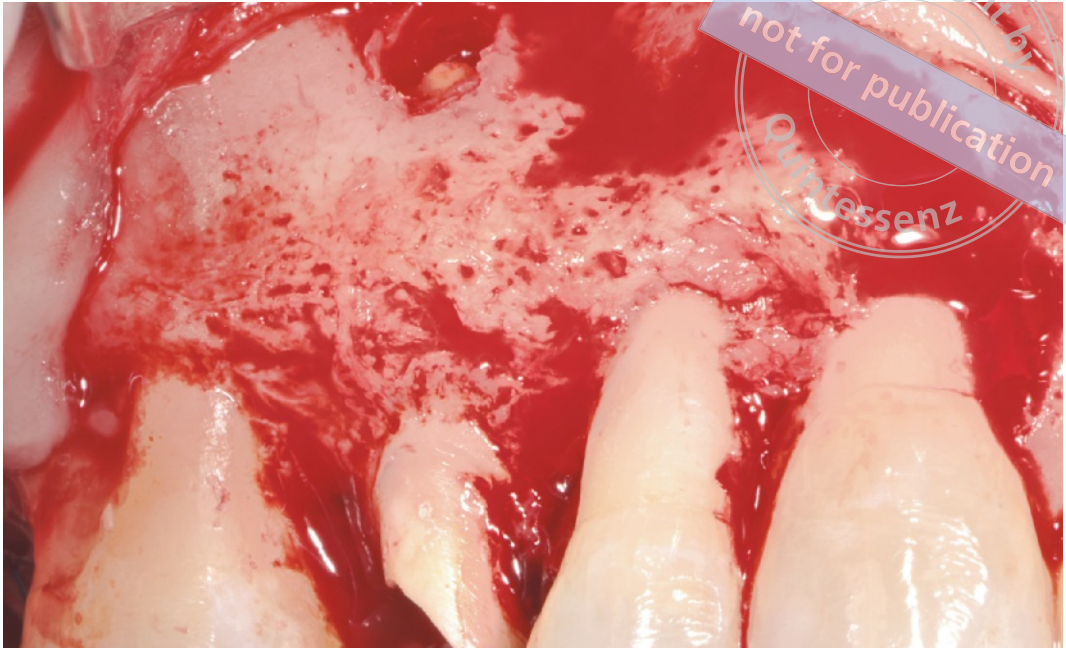


Fig 18 A small vertical incision is performed only mesial since the horizontal extension of the flap is acting as a vertical incision. It is also possible to visualize the class II furcation involvement on the buccal aspect of the first maxillary molar.

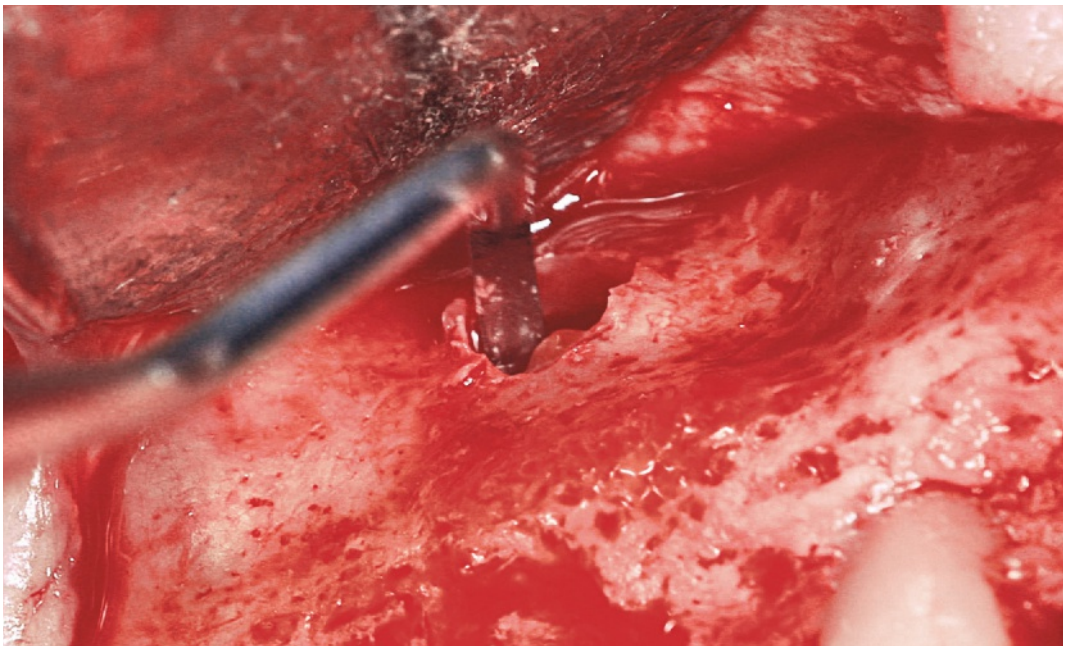


Fig 19 Before extracting the tooth, a special universal instrument, the TABANELLA 2, is inserted into the soft granulation tissue to remove it. Although an apicoectomy was evaluated prior to the surgery, an exploratory surgery using the TABANELLA 2 was executed to again evaluate the feasibility of an endodontic retreatment. However, the coronal extension of the lesion and the presence of a large post did not guide the clinician to a new endodontic retreatment. In fact, in order to properly remove the lesion, a root cut of several millimeters would have been necessary, thus leaving an unfavorable crown-to-root ratio.

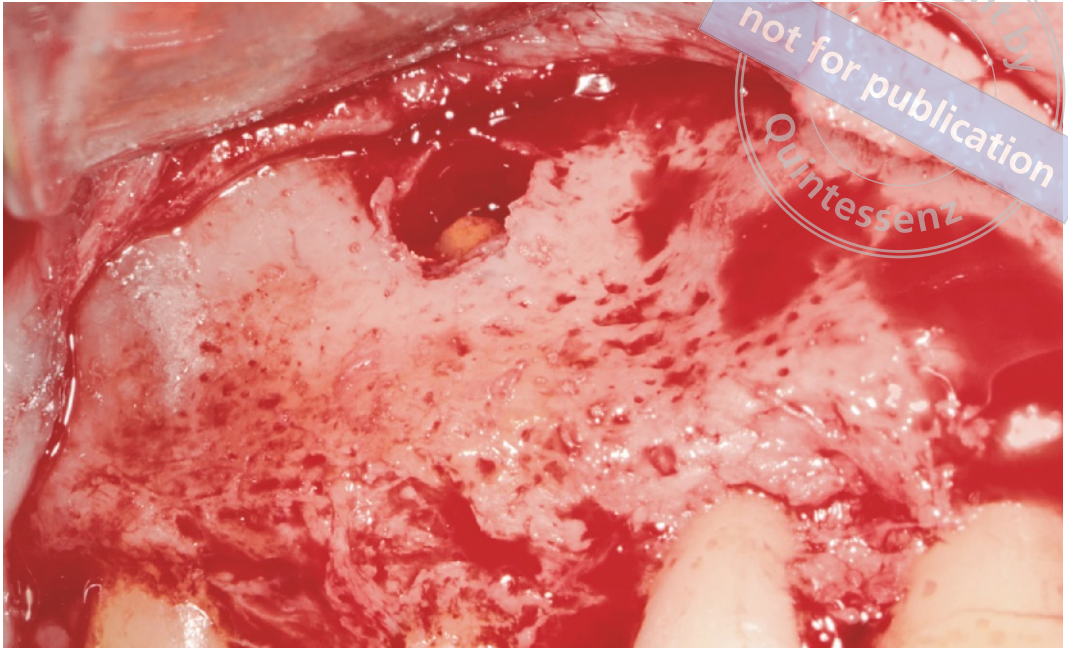

Fig 20 After removing the lesion it is possible to check the apicoronal extension of the residual bony defect with a periodontal probe or explorer and confirm the poor prognosis of the failing premolar.

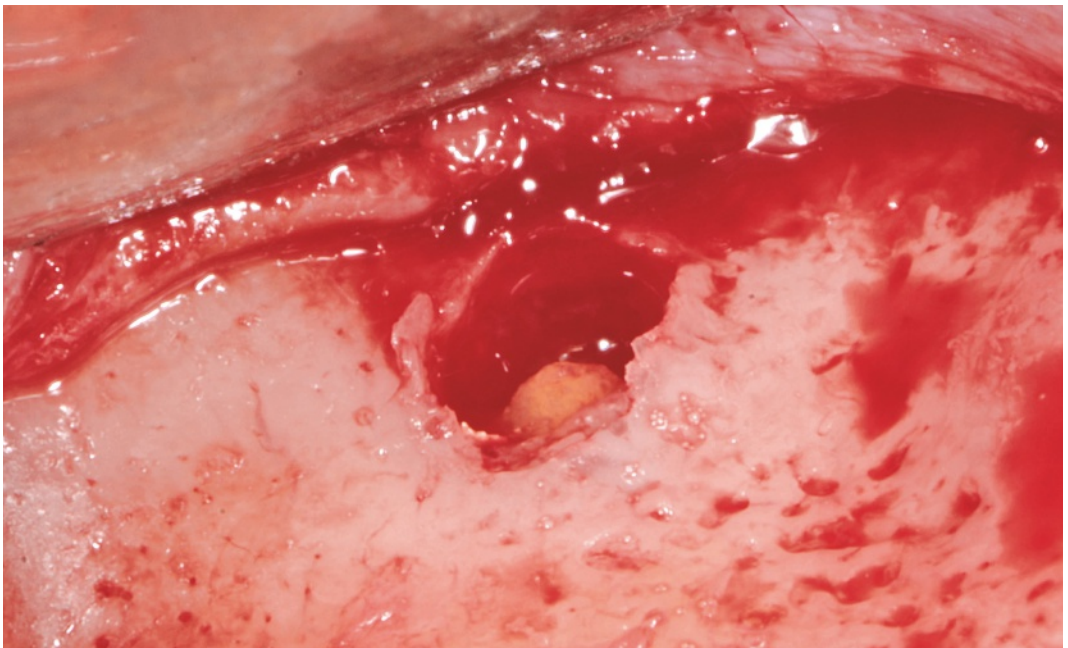


Fig 21 Close-up of the endodontic lesion.

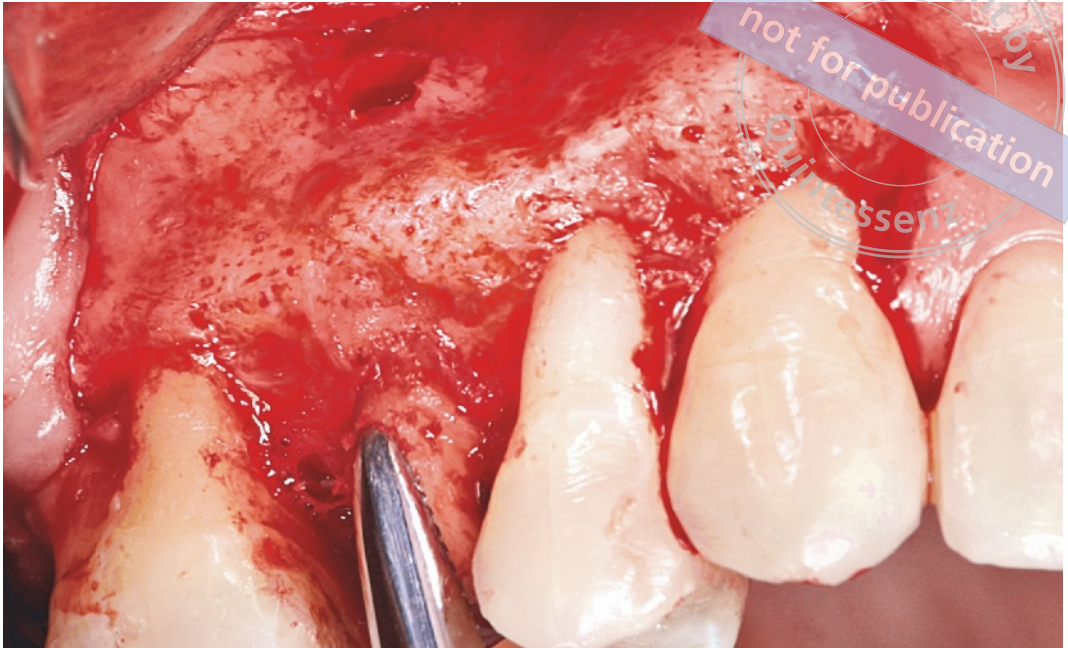


Fig 22 A gentle extraction of the premolar is performed afterwards using an ultrasonic device to gently create a circumferential osteotomy. This approach allows the clinician to increasingly luxate the tooth while still preserving the buccal plate.

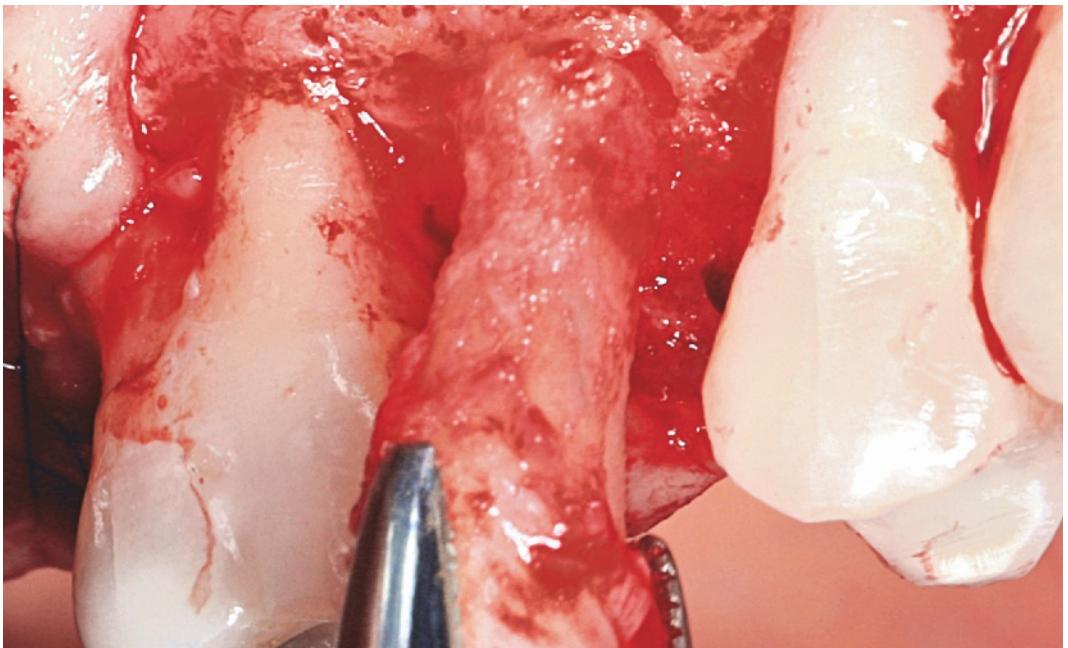


Fig 23 The second maxillary molar is extracted for advanced periodontal disease associated with class III furcation involvement. The second premolar is simultaneously removed.

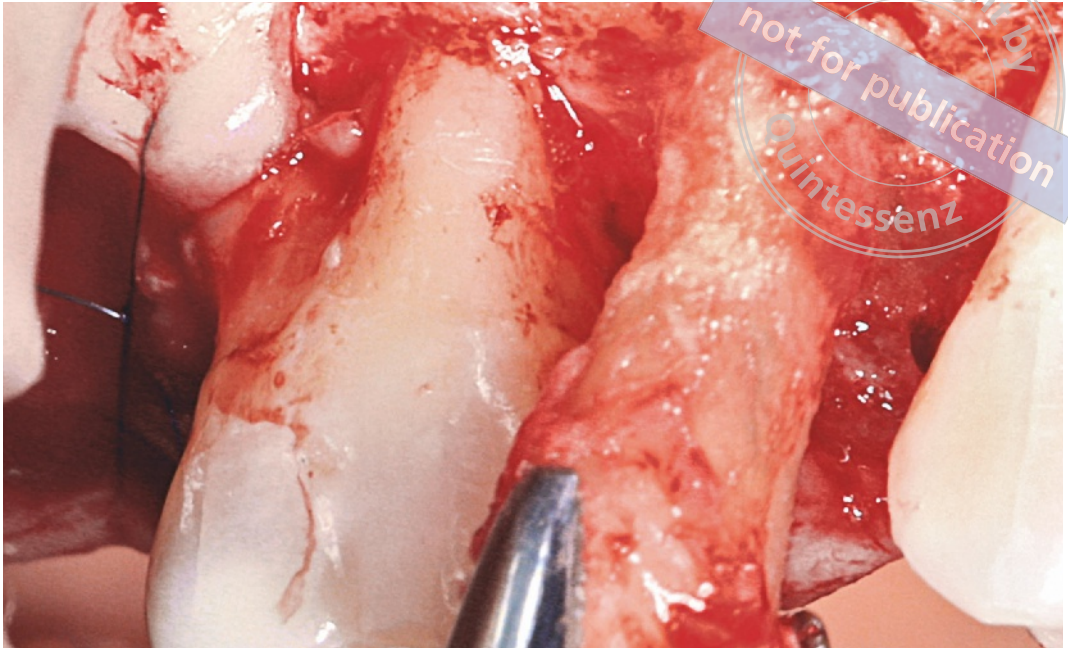


Fig 24 The extracted premolar also shows an external root resorption due to the ongoing endodontic failure.

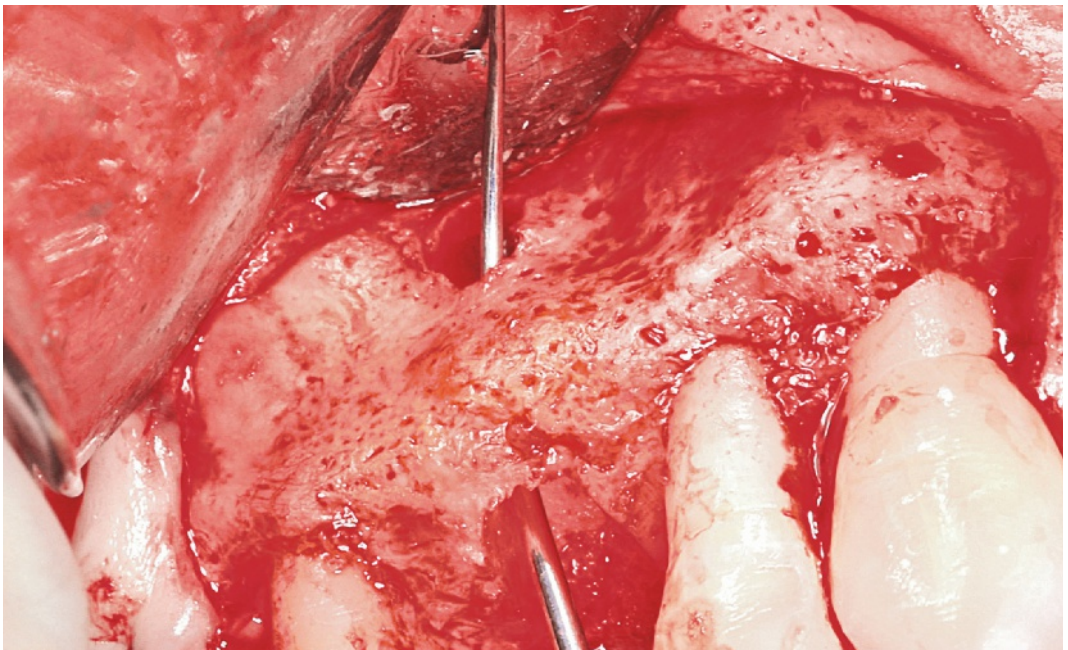


Fig 25 The periodontal explorer is used to check the integrity of the buccal plate and the remnants of granulation tissue.

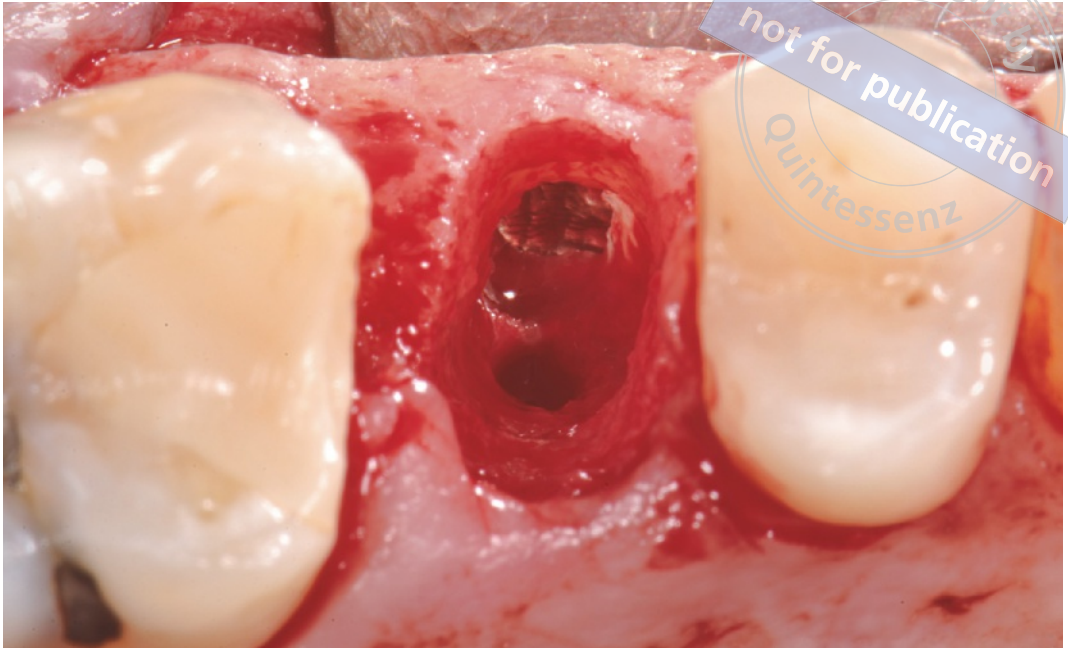


Fig 26 The occlusal close-up of the alveolus shows the vestibular perforation, as well as the residual bone left.

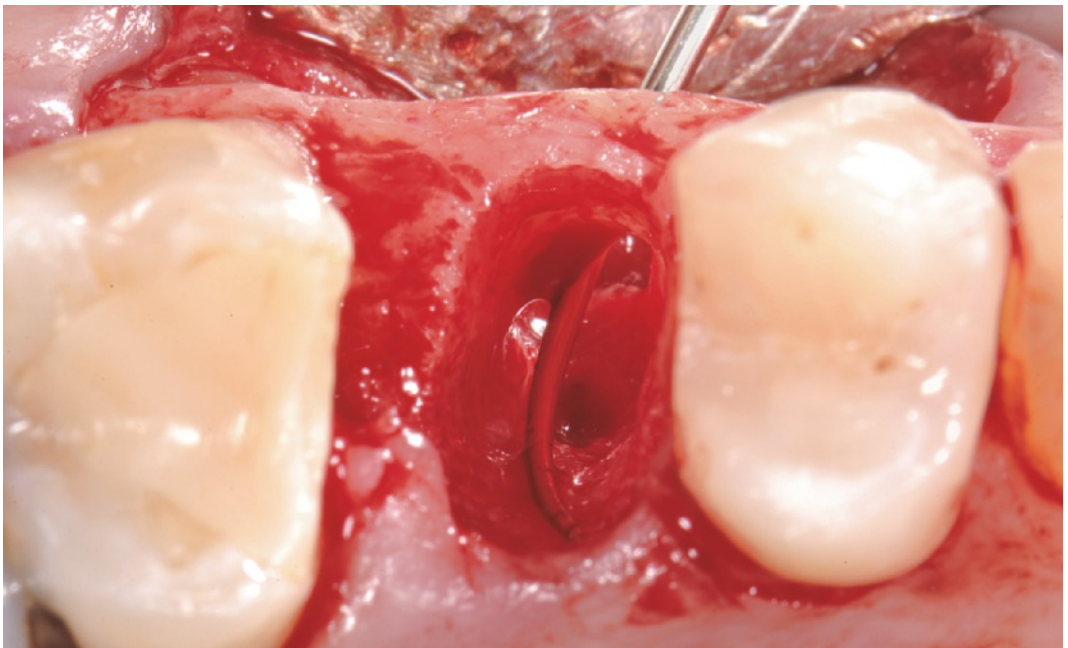


Fig 27 A small and thin bony bridge extends mesial to distal separating the apical portion of the socket. This bridge will then be expanded for simultaneous implant insertion. The ability to keep this bridge is key for implant stabilization and reducing the overall healing time.

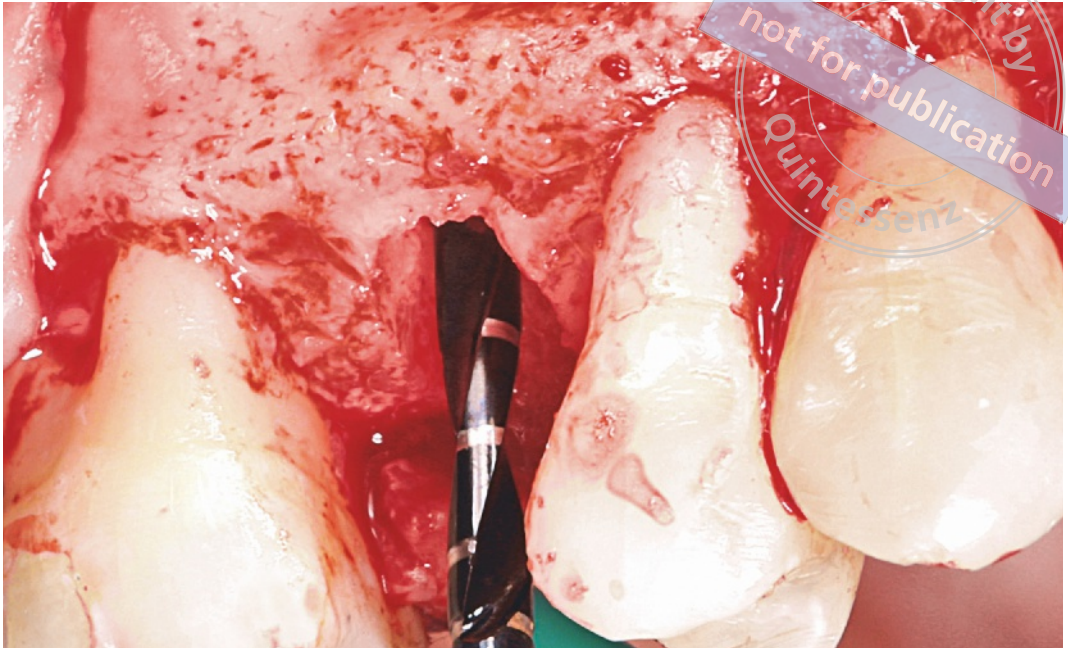


Fig 28 A twist drill is first used to prepare the bone apical to the base of the socket.

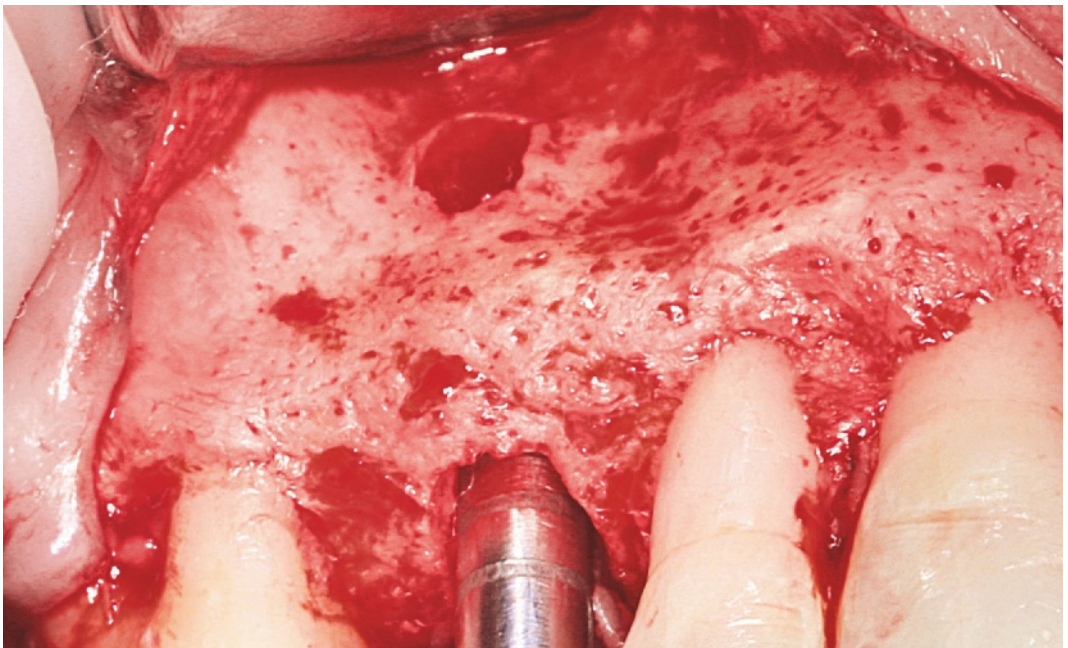


Fig 29 A series of osteotomes is then utilized to expand and compress the bone to improve the bone quality and then gently preserve the buccal plate.

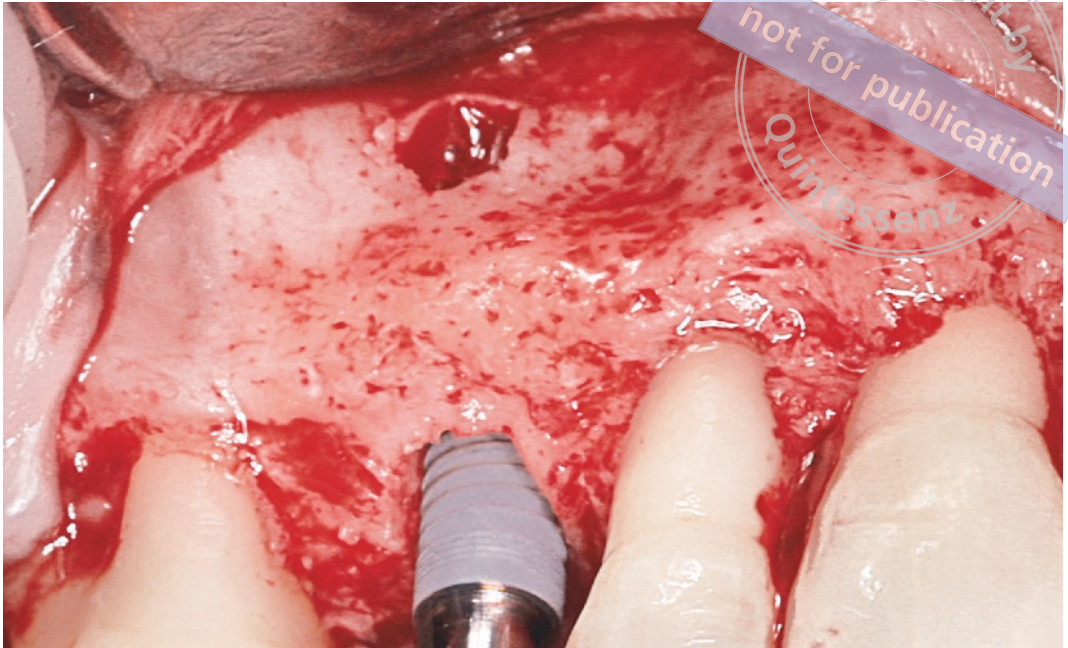


Fig 30 An endosseous tapered dental implant of 3.5 mm × 13 mm is gently inserted into the underprepared osteotomy.

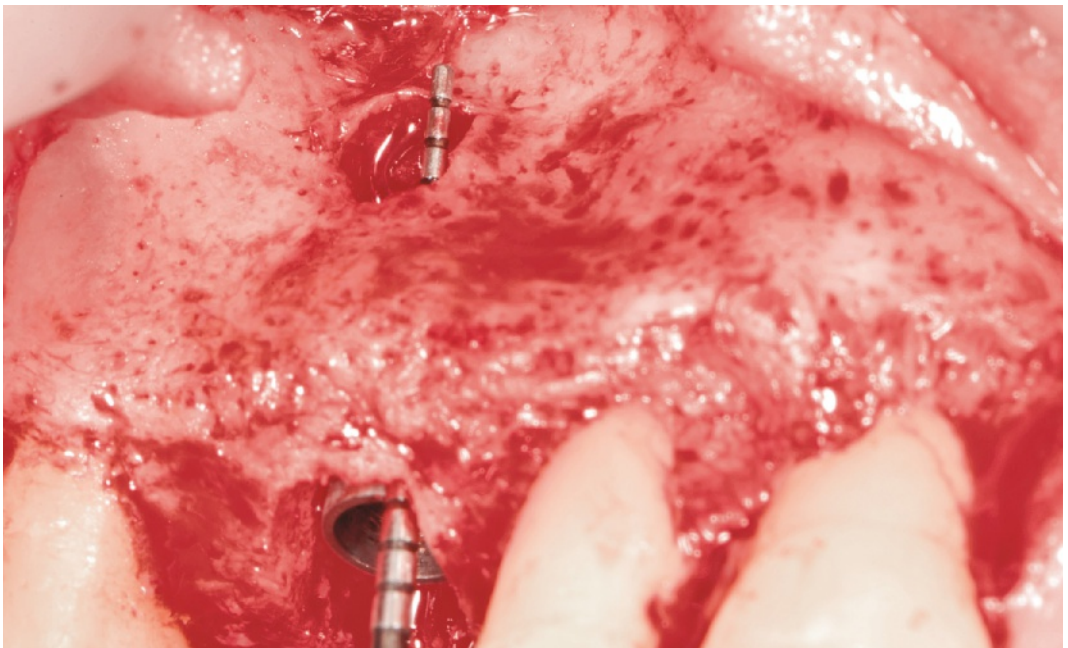

Fig 31 A gap is circumferential to the implant, but intentionally left buccally so that the thin buccal plate can be grafted inside and outside.

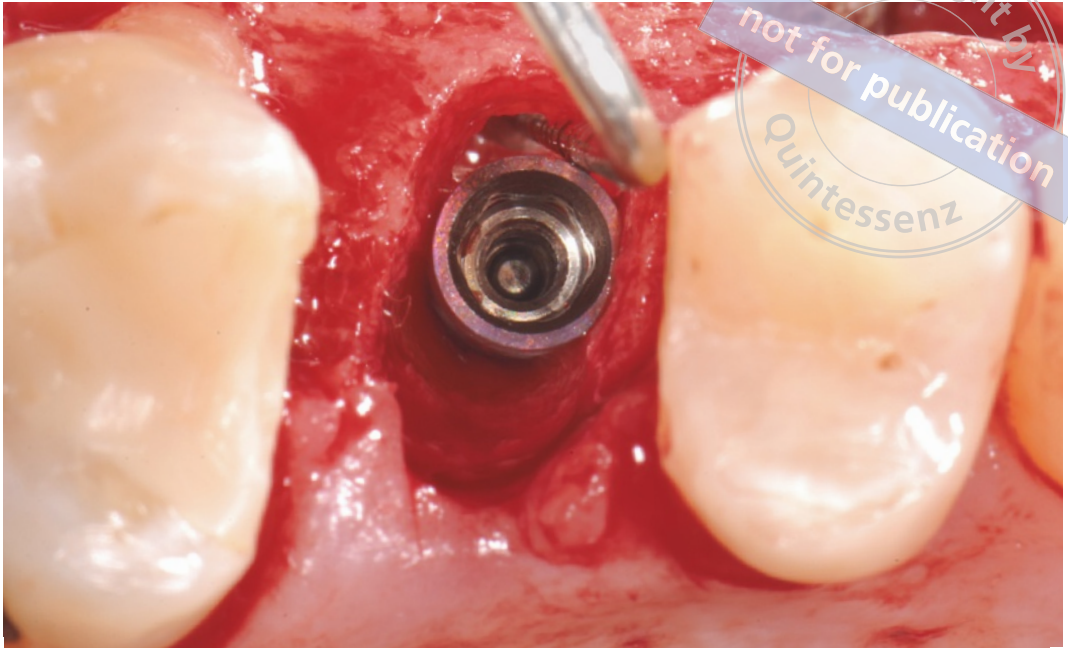


Fig 32 The occlusal view shows an implant completely surrounded by empty spaces. The primary stability is achieved only through the basal bone.

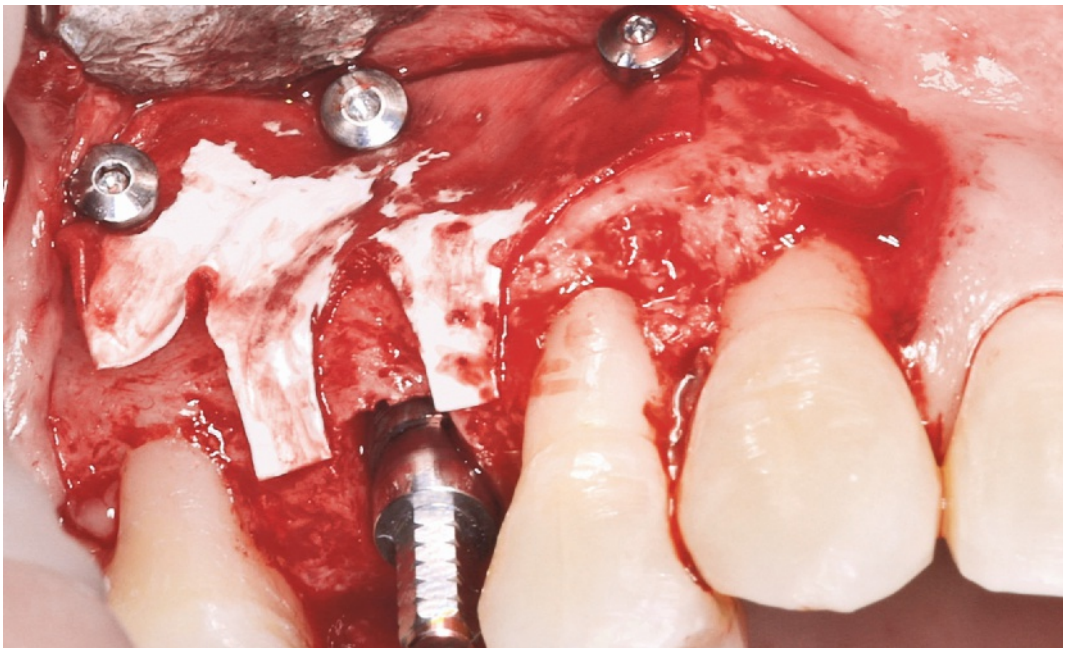


Fig 33 An immediate abutment is manually screwed. A resorbable non-cross-linked porcine collagen membrane is stabilized with three titanium tacks at the apical part of the target area after being "pants shape" trimmed.

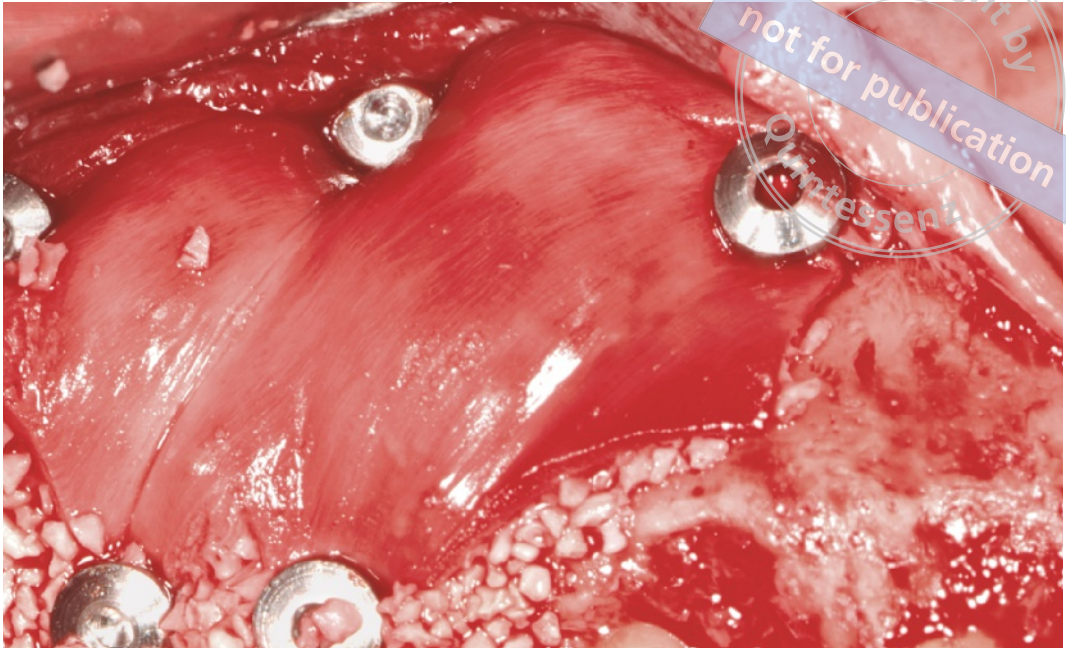

Fig 34 A demineralized bovine bone is packed and compressed with the TABANELLA 1. Two pins then fix the membrane on its narrowest mesial and distal coronal extensions.

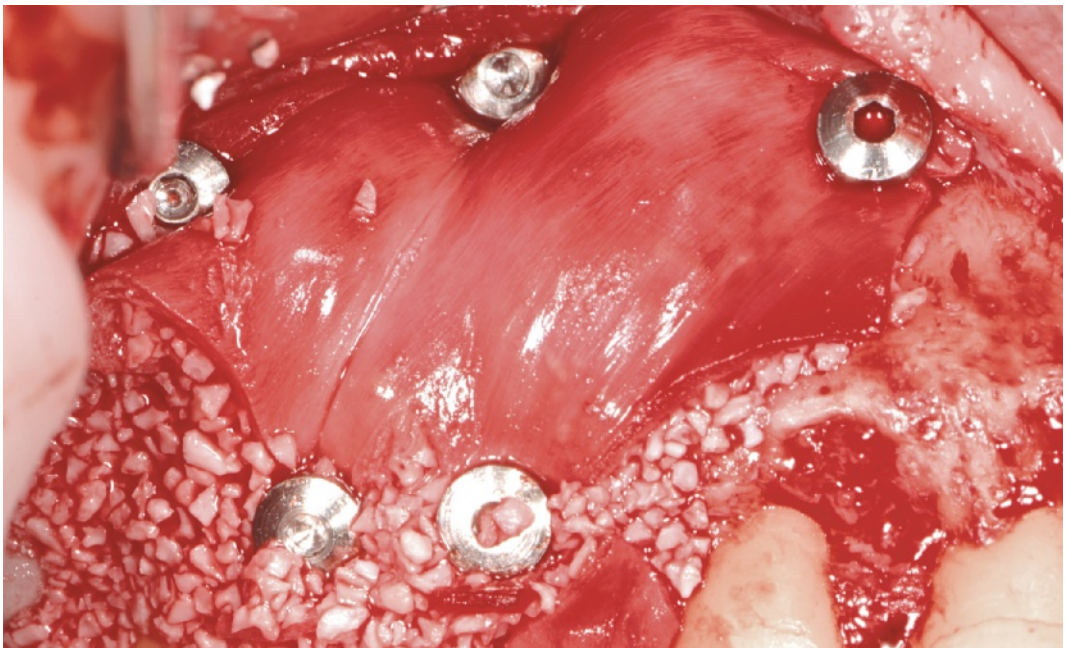


Fig 35 The guided bone regeneration allows for overbuilding of the site and tridimensionally reconstructing the missing bone.

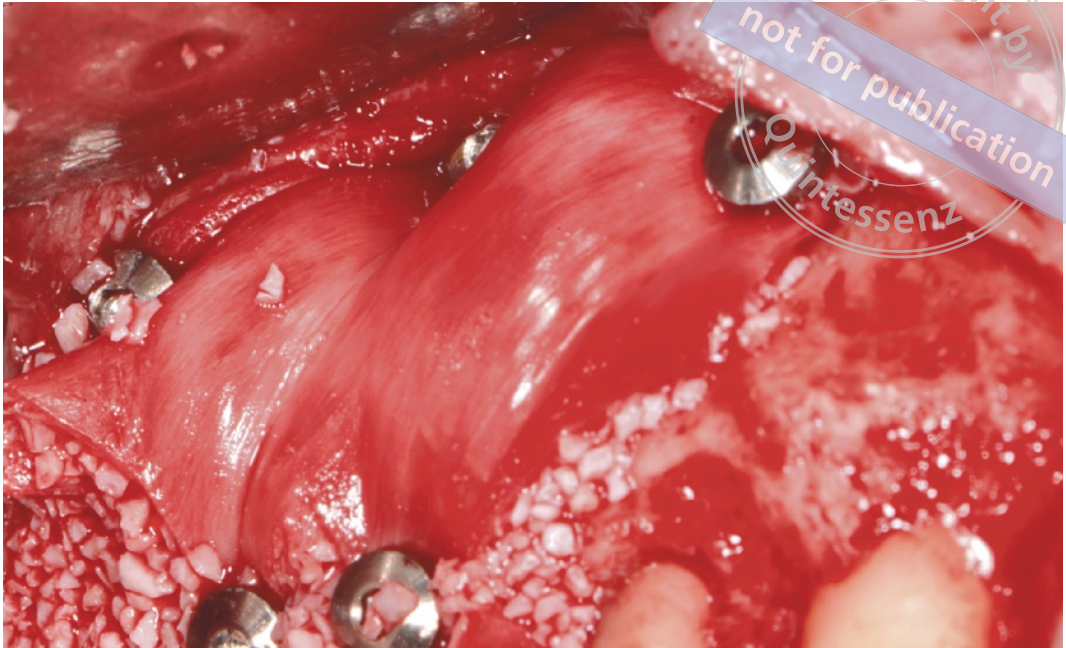


Fig 36 The site is over-treated by about 20% compared with the desired bone volume in order to compensate for a natural bone remodeling that will occur during the healing period. The 3D shape of the membrane and the packed bone particles, as well as their stabilization, will create the "buccal bone balcony".

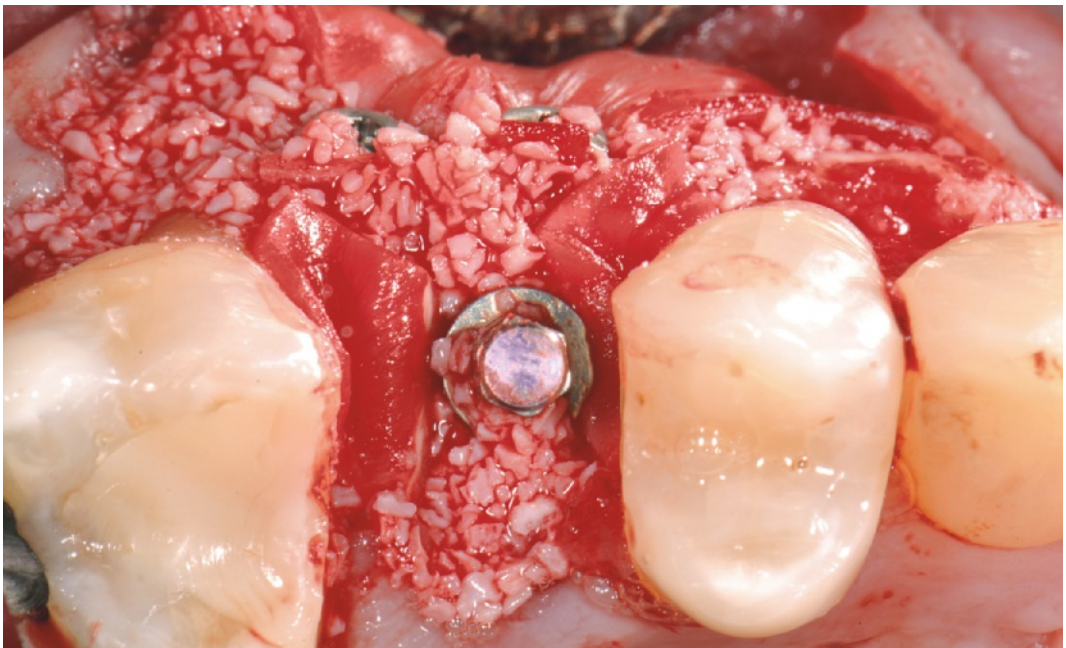

Fig 37 Bovine bone particles are also inserted inside the socket so that a double layer of graft is stabilized inside and outside the alveolus. Only spongy collagen is used to protect the particles on the mesial and distal aspect of the socket.

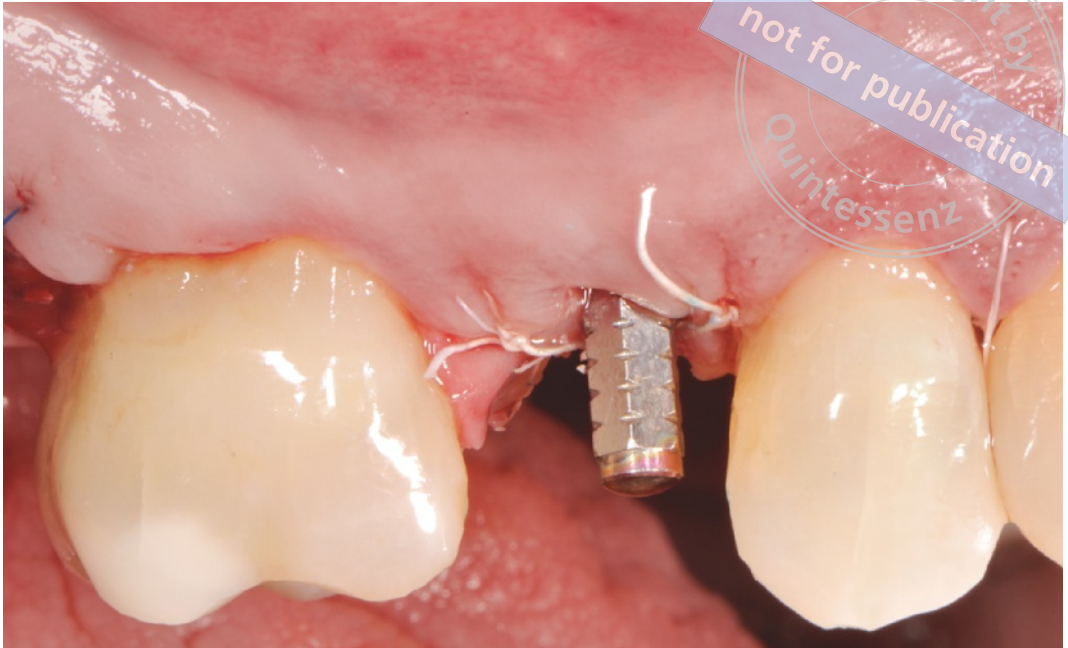


Fig 38 E-PTFE 5.0 and 6.0 sutures are used to close the wound around the abutment. Continuous sling sutures are performed on the neighboring dentition.

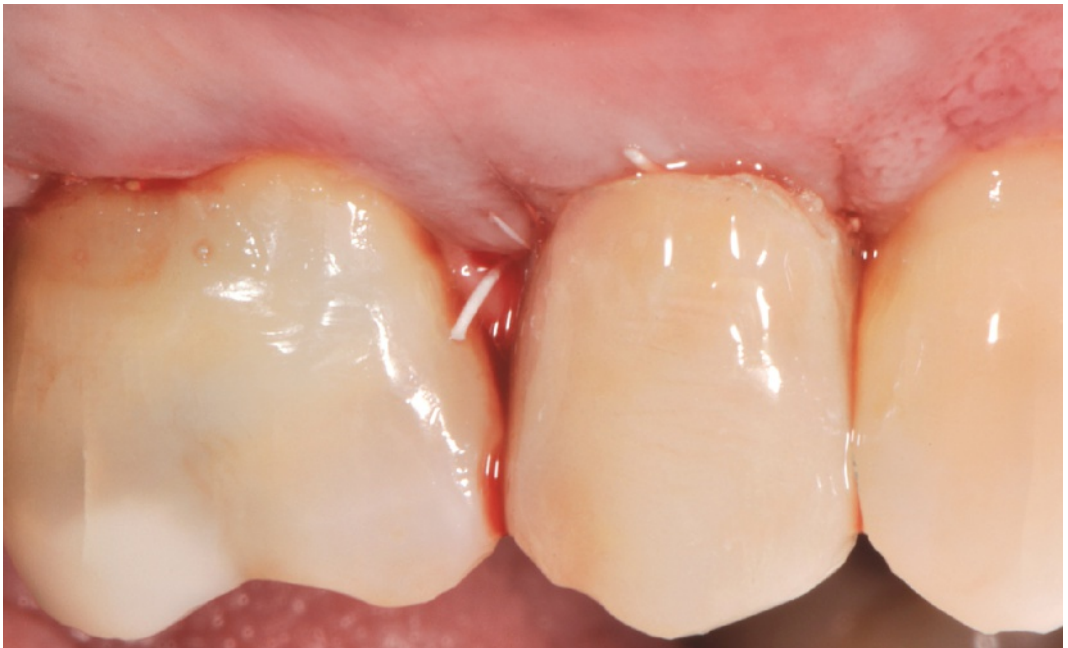

Fig 39 An immediate single provisional is cemented on the abutment.

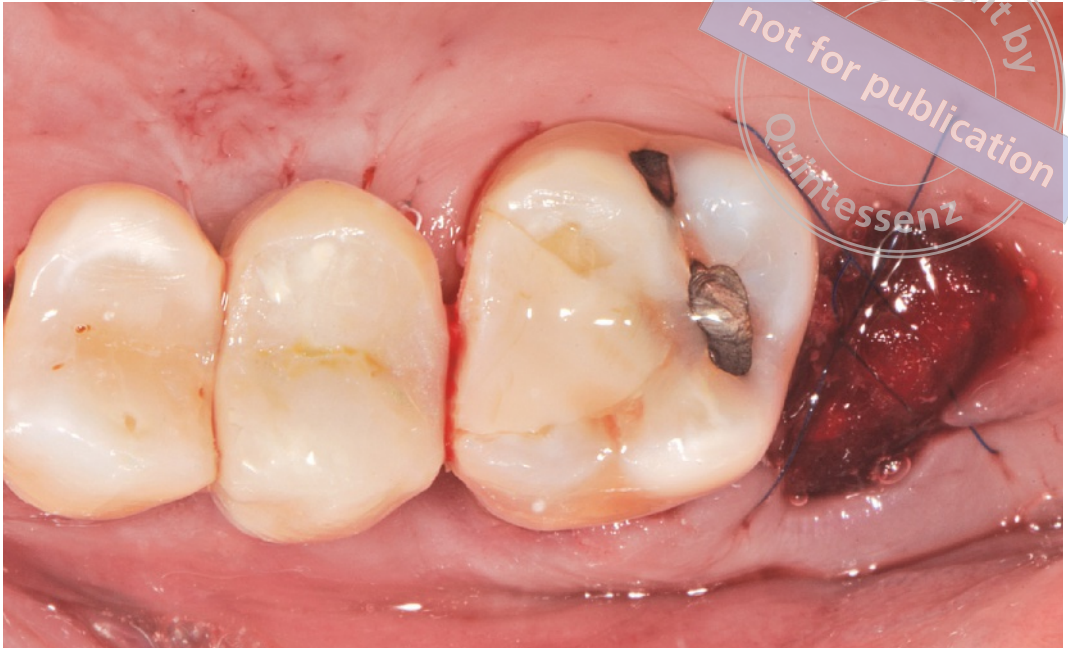

Fig 40 Occlusal view of the sutured sextant

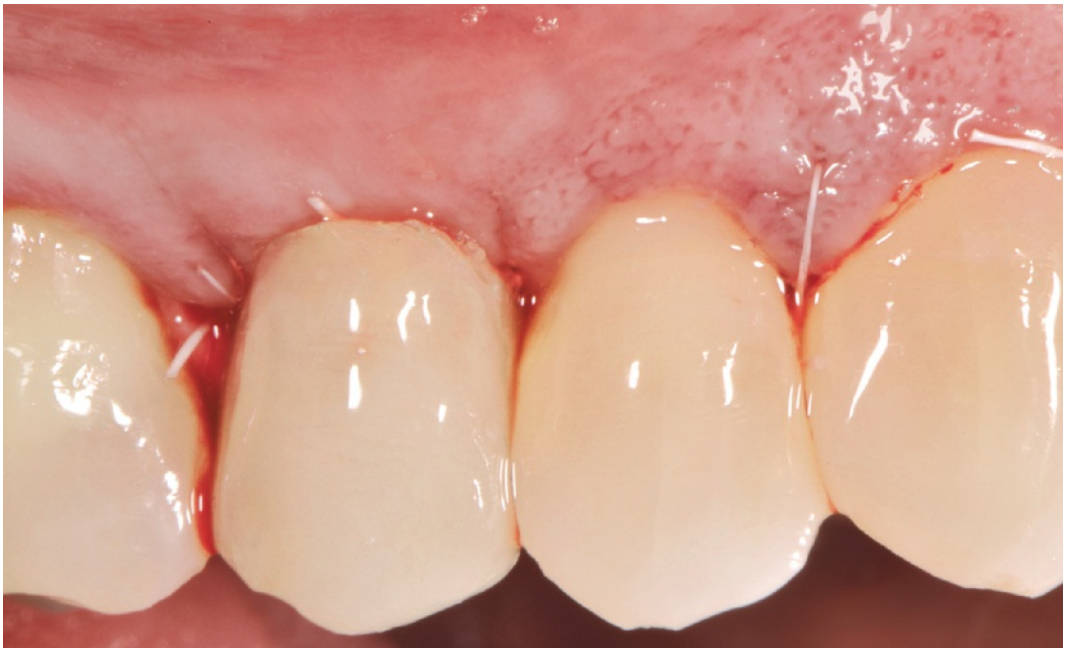

Fig 41 Lateral view of the treated sextant.

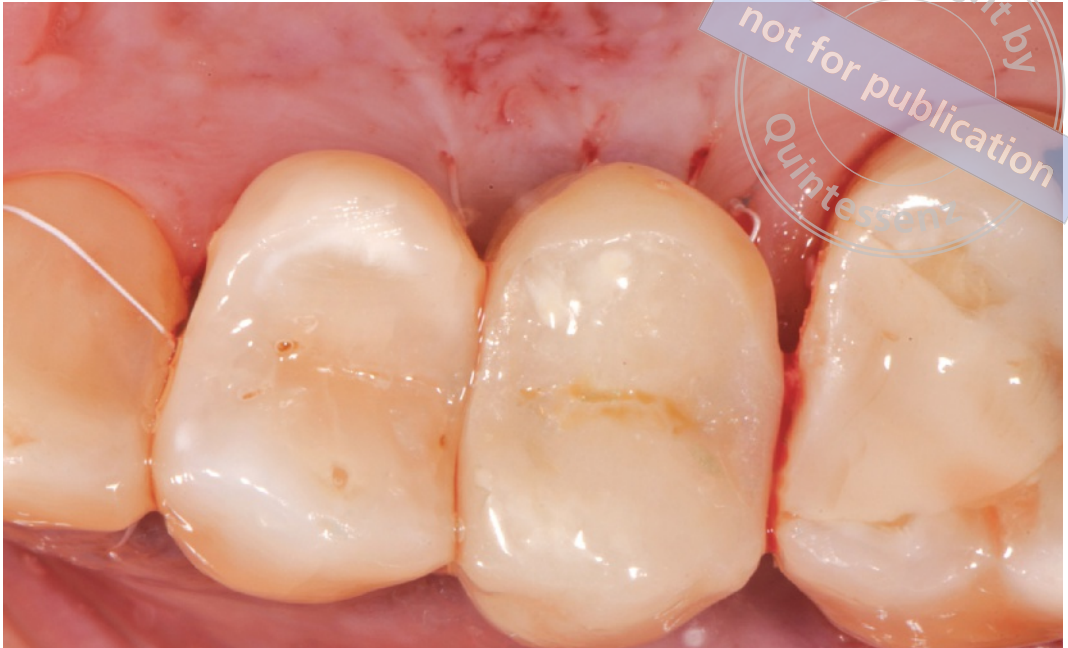

Fig 42 Close-up of the surgical site.

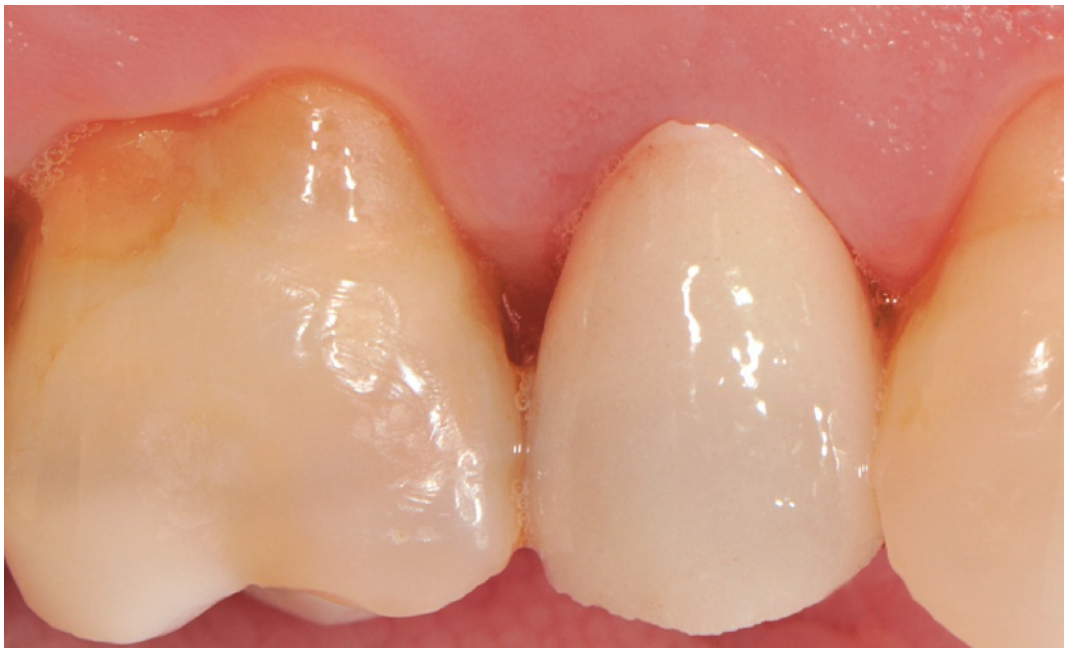

Fig 43 Preoperative picture.

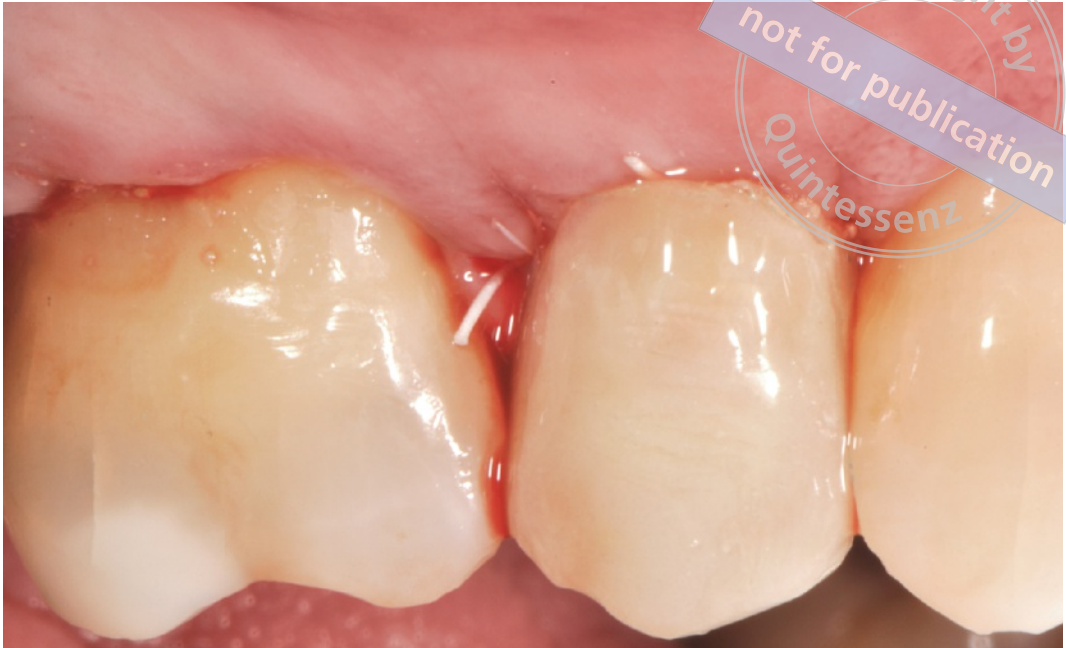

Fig 44 Postsurgical picture.

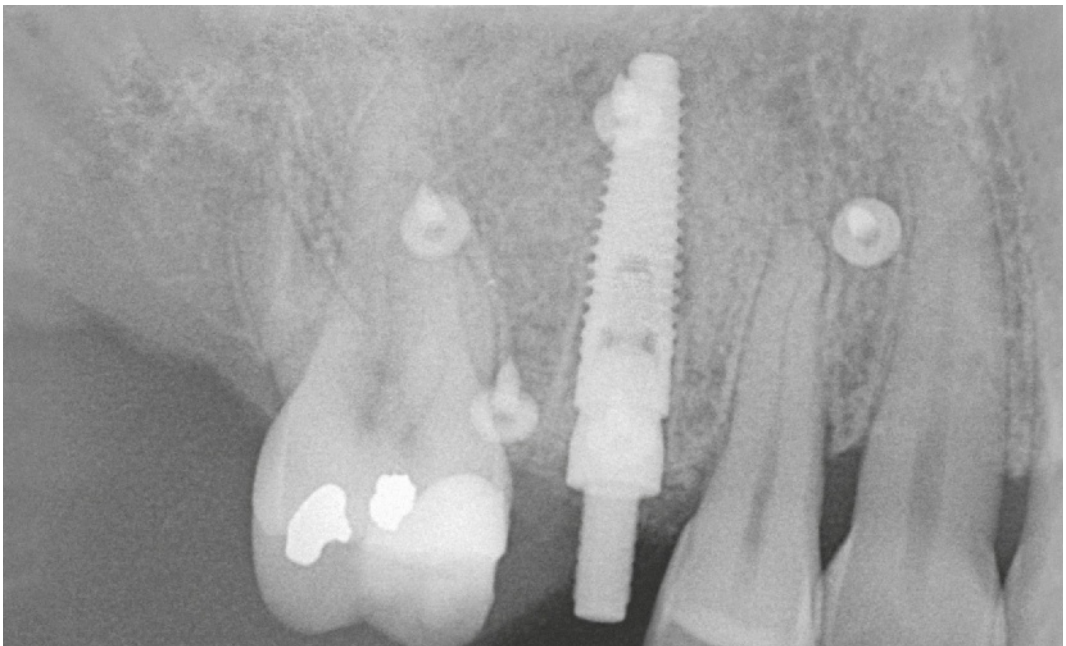


Fig 45 Postoperative periapical radiograph showing the grafted site, the implant and the pins used to treat this clinical case. The shape of the alveolus is still visible.

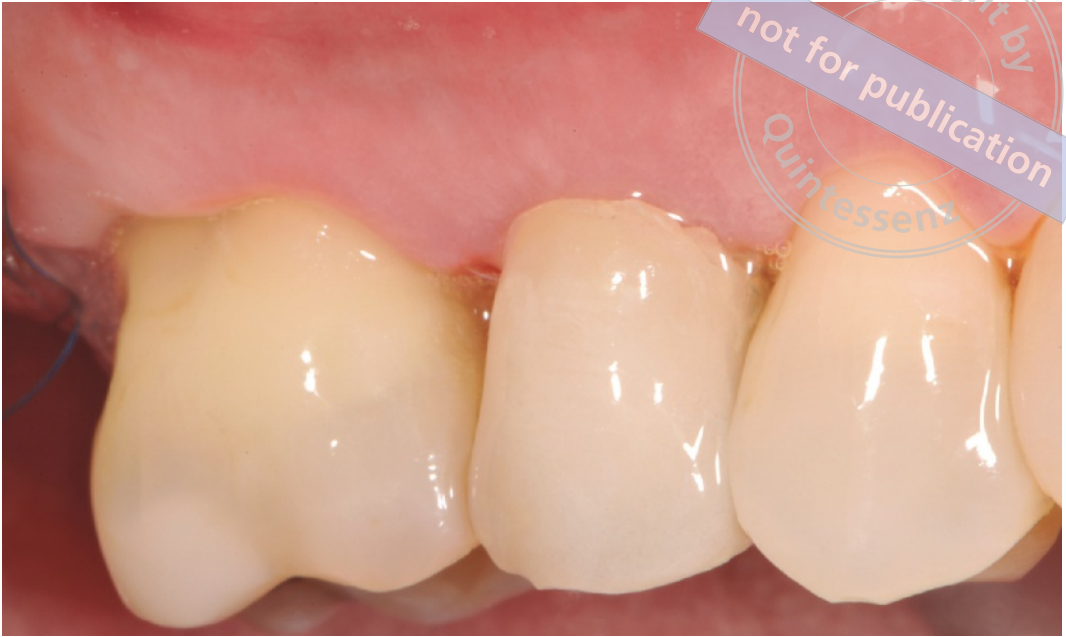

Fig 46 Lateral view 5 days after surgery.

1.13 TREATMENT RESULTS

This novel surgical approach allowed the timing of the patient's rehabilitation to be significantly reduced, thus increasing the patient's comfort, avoiding the delivery of a removable provisional during the healing phase, as well as the morbidity of multiple surgical interventions. Furthermore, the biomimetic results achieved clearly demonstrate how timing can be reduced while still securing a natural soft tissue contour and thickness.

Increasingly, modern dentistry face mistreatments, complications, failures, and even iatrogenic damages. It is therefore deemed valuable for colleagues and patients to share protocols, techniques, instruments, materials, and innovations developed to retreat these clinical cases with no room for error. All clinical cases described in this book have only one parameter in common: a medical mistake. Retreating these "special patients" requires passion, ethics, and the willpower to help patients who present with very high expectations and an exacting psychological makeup.

Endo failure – Tooth loss and perforation of the buccal plate

A 45-year-old female patient presented with pain and no suppuration on the inferior border of the zygomatic right bone. Clinical examination and three-dimensional (3D) cone beam computed tomography (CBCT) revealed the presence of an endodontic lesion associated with a fenestration of the buccal bone. Simultaneous extraction, bone augmentation, implant insertion, and immediate loading were performed in one surgical phase to reduce the healing period. Only 4 months post-loading, the case was finalized after the pins that were visible through the mucosa were removed. Only two 1 mm incisions were performed to remove the pins without raising a new flap. The pins inserted next to the zygomatic bone were not removed, thus allowing for a minimally invasive surgical approach.

Diagnostic failure – Mistreated trauma associated with periapical chronic lesions and anatomic bone deformities

A 57-year-old male patient presented with a discolored right maxillary central incisor due to a trauma he received about 20 years earlier. He reported that the tooth had been endodontically treated at the time. Since then, neither orthodontic nor prosthetic treatment had been performed. The patient's chief wish was to improve esthetics, although he had been told that not much could be done. The periapical radiograph, followed by a three-dimensional (3D) reconstruction, revealed the presence of an endodontic lesion, an atrophic basal bone, and an unusually large nasopalatine canal. A novel approach performing advanced tissue grafting to speed up the healing process is presented.

Perio failure – Recurrent and excessive scaling and root planing

A 78-year-old male patient presented with a crown fracture of a mandibular central incisor. The clinical examination and radiographic analysis showed the presence of multiple teeth with deep abrasions on the mesial and distal aspects. The patient reported that he had undergone nonsurgical periodontal therapy every 3 months as a supportive therapy, after having received periodontal surgery more than 20 years before. The periapical radiograph of the mandibular incisor showed a chronic periapical lesion due to the necrotic pulp, which was traumatically induced by recurring scaling and root planing. The endodontic lesion perforated the buccal plate so that an implant placement with a simultaneous guided bone regeneration (GBR) procedure was necessary.

Implant failure – Iatrogenic bone grafting and implant placement: Ailing dental implants associated with oroantral communication

A 41-year-old female patient had undergone an implant treatment about 2 years previously. She presented with purulent exudate coming from the right nostril and from one of the dental implants placed after a maxillary sinus elevation. An endodontic lesion was also present next to the infected implant. The implant was mobile and painful. The treatment comprised only two surgical phases: the first phase aimed to eradicate the infection by removing the infected implant and endodontically treated tooth and closing the oroantral communication; the second phase was based on simultaneous implant removal, sinus elevation, simultaneous implant placement, guided bone regeneration (GBR), and immediate loading to reduce the healing time. This clinical case shows the potential for tissue regeneration even after iatrogenic implant dentistry.

ISBN: 978-1-78698-094-6



9 781786 980946

www.quintessenz.de