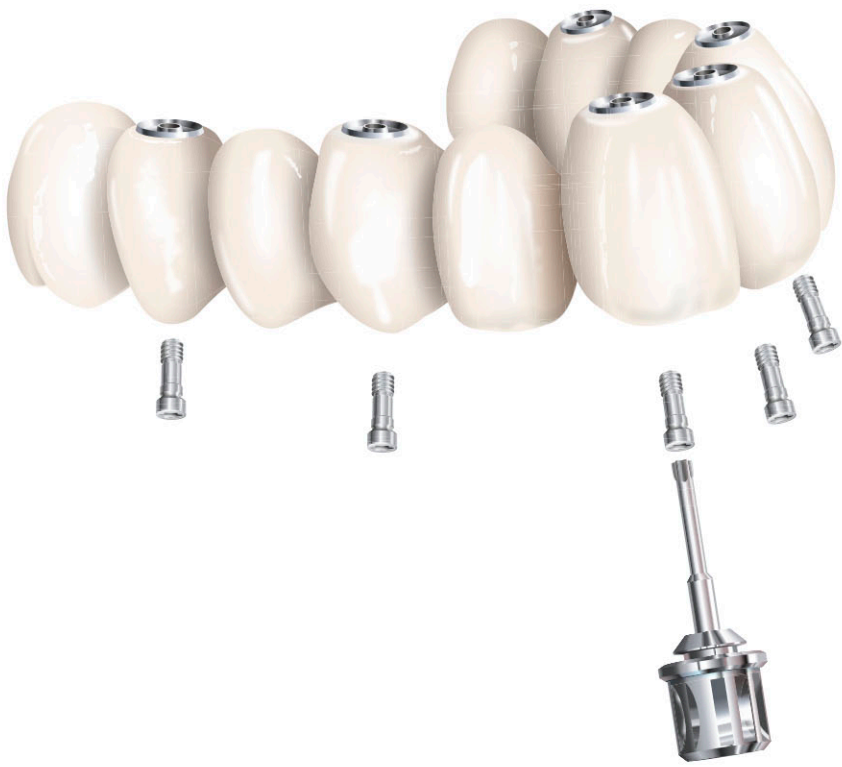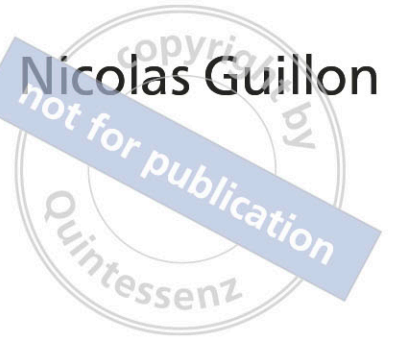


Hervé Buatois | Nicolas Guillon



The Quokka protocol

Immediacy in
modern implantology

The Quokka protocol

Immediacy in modern implantology

Hervé Buatois | Nicolas Guillon

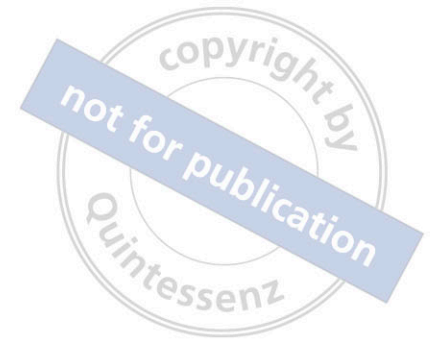 QUINTESSENCE PUBLISHING

Berlin | Chicago | Tokyo

Barcelona | London | Milan | Mexico City | Paris | Prague | Seoul | Warsaw

Beijing | Istanbul | Sao Paulo | Zagreb





Hervé Buatois

*Doctor of Dental Surgery,
Claude-Bernard University, Lyon 1.*

*Postgraduate in implantology,
New York University (NYU), USA.*

*Co-director of CampusHB continuing
education center, Grenoble.*

*Private practice in implantology and esthetic
prosthetic rehabilitation, Grenoble.*

*Author of the book "L'implantologie
supra crestale" published in 2016
by Editions Quintessence.*

Nicolas Guillon

*Doctor of Dental Surgery,
Claude-Bernard University, Lyon 1.*

Postgraduate in implantology, EAO (2025).

*Co-director of CampusHB continuing
education center, Grenoble.*

*Private practice in implantology and esthetic
prosthetic rehabilitation, Grenoble.*

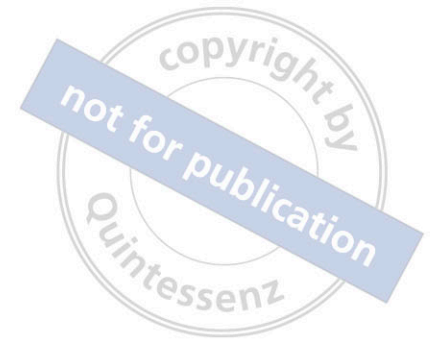

Foreword

The idea for this book emerged gradually, driven by the repeated success of our immediate implant treatments and immediate loading assisted by a digital workflow in our practice. This book, based on more than 200 documented cases, analyzed and broken down into single, multiple, and full edentulous cases, is at the root of our thinking and the standardization of our approach. Our approach has always been based on research and the application of clinical protocols validated by the literature. This was the driving force behind the genesis and writing of our previous book, *L'implantologie supra crestale*. This book aimed to develop a form of implantology based on the consideration of the periodontal environment and the relevance of its reconstruction to the durability of implant treatments by appealing to evidence-based dentistry.

Underpinned by this solid foundation, we asked ourselves how we could take into account the wishes of patients, who are always asking for shorter treatment times and optimal physical and psychological comfort during our therapeutic treatments. If we analyze how implantology has evolved since the end of the 1980s, its metamorphosis has often been induced by the demands of our patients.

This is the case with the development of single-tooth edentulism in esthetic areas, immediate implantation, and immediate loading in the 1990s and 2000s. As a social phenomenon that inexorably affects our specialty, is immediacy compatible with esthetic and durable implantology? Clinical protocols still need to be developed and scientific evidence confirmed in order to integrate immediacy into our daily therapeutic arsenal. We must resolve to forget about transitional removable prostheses, which are simple to insert for the practitioner but so destabilizing for our patients. Can we offer immediate implantation and loading on a daily basis while standardizing our results?

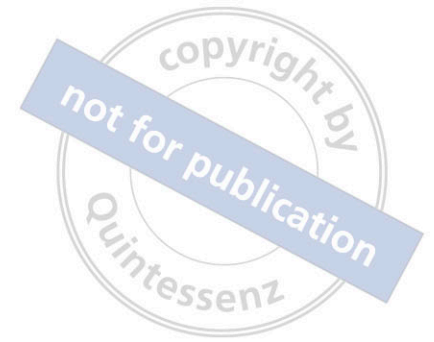

The literature is advancing, as are the therapeutic tools, to move towards immediate implantation and loading. Implant designs, implant surfaces, guided bone regeneration (GBR), and periodontal reconstructive techniques are leading us in this direction. The advent of digital options and tools in dentistry, as in many other professional and personal activities, brings new perspectives.

What about implant treatment? Will these new tools change the approach towards implant therapy and facilitate the procedure? As with any technological evolution, it is important to examine its impact on our practice and the clinical benefits that it can offer in a sustainable manner. Our initial view of the digital workflow was in no way technological and even less passionate with regard to the integrated circuit! Our questions related more to the potential ergonomic tool. Can the digital solution help us to address some of our limitations in the planning and management of procedures? Can it improve the reproducibility and quality of our results?

We have identified several areas for reflection based around:

- the fusion of biological and theoretical prosthetic rules in implantology;
- ergonomic management of restorations and immediate loading by way of:
 - a shorter operating time;
 - improvement of the esthetics and integrity of the tooth or the fixed or removable partial denture;
 - precise management of the emergence profile in its anatomy as well as its surface condition.

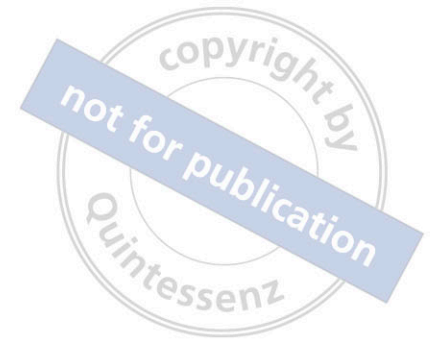

The purpose of this book is to share our experience in this evolution that has allowed us, for the past 6 years, to no longer manage temporary removable prostheses, to develop reproducible clinical protocols based on our knowledge and by integrating an ergonomic tool that is the digital workflow, and to propose immediate loading with temporary prostheses connected to the prosthetic bases before surgery. In addition to saving time and providing peace of mind, this significant development enables us to define GBR and guided tissue regeneration (GTR) and perform suturing techniques guided by the prosthesis. We would like to help you understand this approach by sharing fundamental guidance and innovative clinical protocols, illustrated using numerous cases treated in our office.

This introduction would not be complete without thanking Jérôme Vaysse from Laboratoire High Tech Dental in Toulouse, France and Dr. Dimitri Pascual, both of whom have done pioneering work. Their innovative experience has encouraged us to embrace this philosophy and allowed us to develop our protocol over the past 6 years.

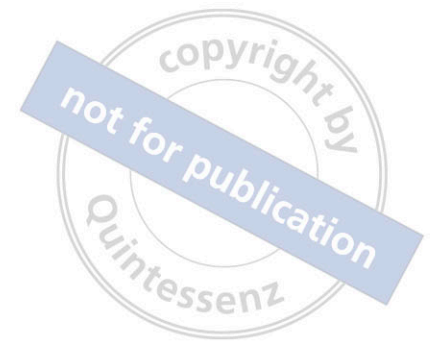We hope you will enjoy reading this book as much as we enjoyed imagining, structuring, and creating it.

Hervé Buatois, Nicolas Guillon



CONTENTS

Foreword	V
Chapter 1 Immediate implant placement	1
Fundamental reminders	3
Decision-making criteria.....	6
Positioning protocol	7
Hard and soft tissue management in the Quokka protocol.....	9
Chapter 2 Restoration and immediate loading	17
Interest.....	19
Conditions for success.....	21
Emergence profile, the essential guide	27
Chapter 3 Presentation of the Quokka protocol.....	31
Introduction	33
The prosthetic project	34
Implant-prosthetic planning	49
The surgical guide	52
Guided surgery and immediate loading	55
Transfer of the project to the final prosthesis	62

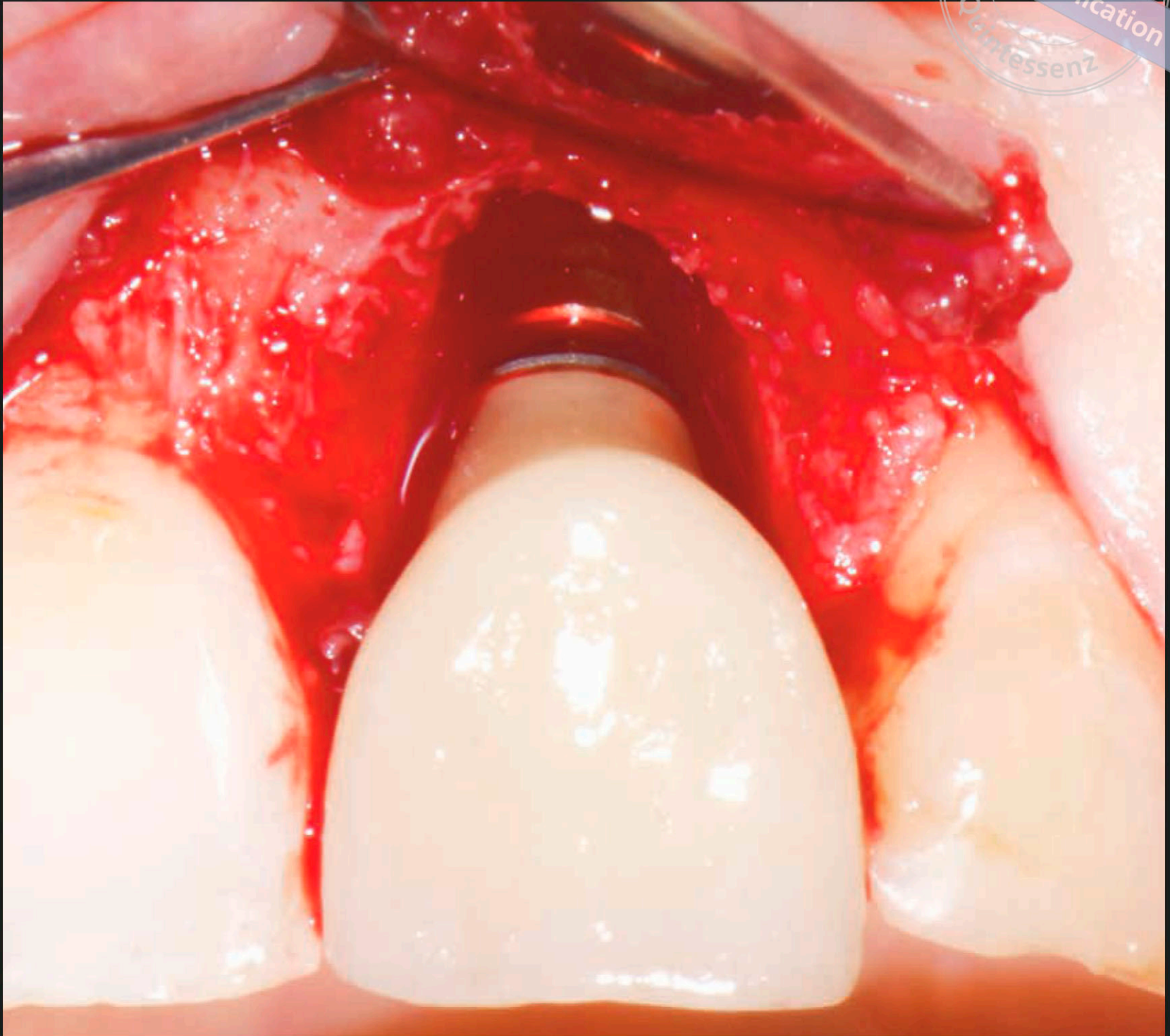

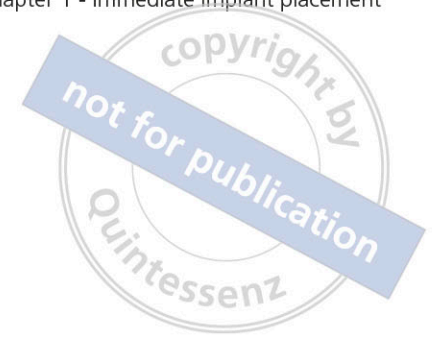Chapter 4	Single-unit clinical applications	73
	Alveolus intact, vestibular bone wall preserved – Single-unit cases 1 to 5	75
	Alveolus with narrow vestibular dehiscence ($< 1/3$ of root exposure volume) – Single-unit cases 6 to 9	113
	Alveolus with medium vestibular dehiscence ($1/3$ to $2/3$ of root exposure volume) – Single-unit cases 10 and 11	141
	Alveolus with large vestibular dehiscence ($> 2/3$ of root exposure volume) – Single-unit cases 12 to 15.....	155
Chapter 5	Clinical applications for partially edentulous patients	183
	Two to three anterior teeth – Plural-unit cases 16 and 17	185
	Two to three posterior teeth – Plural-unit cases 18 and 19	199
	Four anterior teeth – Plural-unit cases 20 and 21	211
	Six teeth or more – Plural-unit cases 22 to 24	231
	One implant for two teeth – Plural-unit case 25	259
Chapter 6	Full-arch clinical applications	269
	Toothed unimaxillary – Full-arch clinical cases 26 to 37	273
	Edentulous unimaxillary – Full-arch clinical cases 38 and 39.....	393
	Maxillomandibular – Full-arch clinical cases 40 and 41.....	417



Immediate implant placement

Fundamental reminders	3
Decision-making criteria	6
Positioning protocol	7
Hard and soft tissue management in the Quokka protocol	9





Fundamental reminders

Immediate implant placement represents the ultimate evolution of implant dentistry. This technique was developed to control the bone resorption inherent in any extraction¹. From implantation in a previously edentulous bone site, clinical validation has made it possible to reduce the amount of time required for immediate implant placement, i.e., placement that is performed at the same time as the extraction. The terminology had to be adapted to reflect this evolution: the Third International Team for Implantology (ITI) Consensus Conference that took place in 2003 proposed new terminology, modified in 2008 by Chen and Buser, when the ITI Treatment Guide Volume 3 on immediate implant placement was published². It now refers to four types of implantation:

type 1: immediate implant placement, which occurs on the day of extraction without prior bone or gingival healing;

type 2: early implant placement that occurs 6 to 8 weeks after soft tissue healing has taken place in the extraction site, but without significant bone healing;

type 3: early implant placement that occurs 12 to 16 weeks later once partial bone healing has taken place, with significant soft tissue and bone healing;

type 4: late implant placement, which takes place more than 6 months after extraction, once the alveolus has healed completely.

Immediate implant placement is recognized as a validated procedure in current implantology³⁻⁶; however, it is still associated with a higher risk of gingival recession during the initial healing phase than early implantation in esthetic areas³⁻⁵. The implantation time should not alter the rules for the 3D positioning of the implant in accordance with the surrounding tissue biology, which must adapt to this procedure. Replacing a tooth with an implant implies the reconstruction and repositioning of the optimal coronal volume lost following the avulsion of the tooth and the associated tissue modifications.

Our approach involves focusing on the positioning of the prosthetic implant platform, which we consider to be the guiding element of implant-prosthetic rehabilitation as it supports the emergence profile. Without optimal support, it will not be possible to achieve an anatomically and color-matched coronal volume through ceramic layering (Fig 1-1).

Of course, this support must be integrated seamlessly into a stable periodontal volume

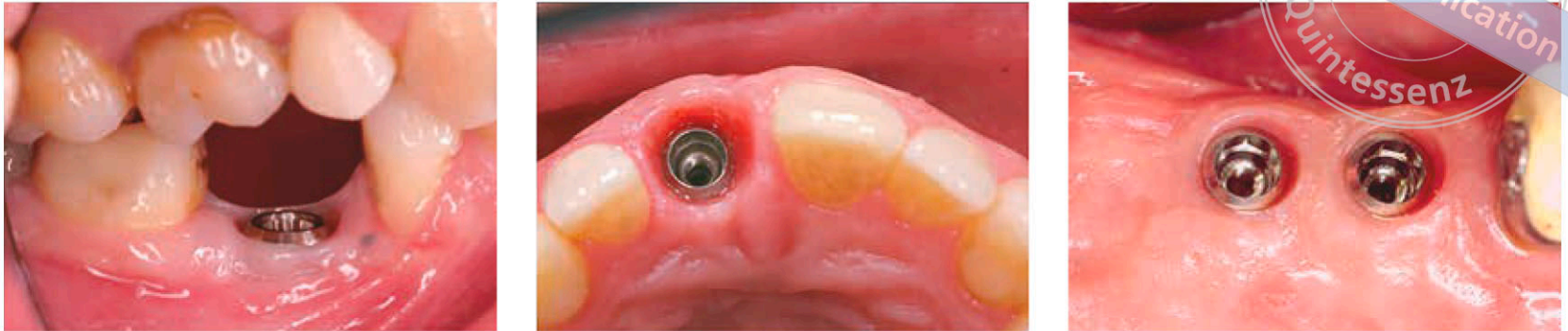


Fig 1-1 The location of the prosthetic platform is the guiding element of the emergence profile.

while taking into account the anatomic and biologic differences that exist between implants and natural teeth^{6,7}. This philosophy implies the reconstruction of bone and gingiva in many clinical situations to restore a peri-implant bone architecture that is compatible with both horizontal and vertical periodontal stability (biologic distance), in accordance with the implant design. The emergence profile is managed through the mesiodistal and bucco-lingual positioning of the implant and not burying the implant. Vertical positioning based on the implant design only achieves periodontal integration through relevant hard and soft tissue reconstructions^{8,9} (**Fig 1-2**).

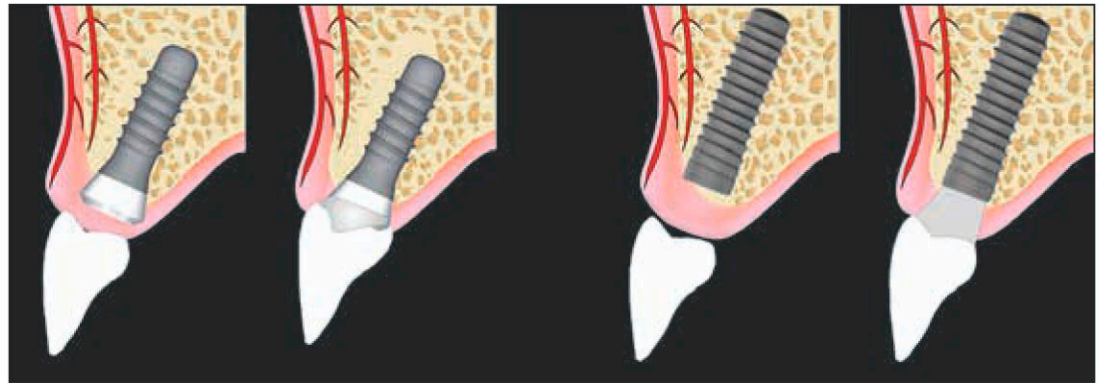


Fig 1-2 The emergence profile is managed by the mesiodistal and vestibulolingual/palatal positioning of the implant and not by the burying of the implant. The vertical positioning facilitates the periodontal integration.

Regardless of the implantation time, the choice must allow for an optimal functional and esthetic result for the patient. This is a crucial element in the therapeutic decision tree. Early implantation remains the reference procedure in the esthetic zone³. The relevance of this work is to describe an immediate approach that makes it possible to achieve similar results to other timed approaches. In our method, we have identified three master biologic rules that guide us during the surgical phase. These are as follows:

- The presence of a 2-mm native or reconstructed bone wall is the recognized standard for achieving stability of the vestibular wall around an implant^{8,10,11};

- Constant bone remodeling by resorption leads to the formation of the biologic space and brings the bone level 2 mm more apical to the prosthetic hiatus^{12,13};
- A minimum of 3 mm keratinized gingiva with a minimum gingival thickness of 2 mm is recommended. A minimum gingival thickness of 2 mm is an important factor in restructuring the biologic space^{14,15}.

To understand these biologic rules, it is essential to know the main principles of bone resorption following extraction. The literature is clear on this point. Within 1 year after extraction, vertical bone loss of 2 to 3 mm and horizontal bone loss

of 50% of the initial bone volume are observed. Two-thirds of this resorption occurs during the first 3 months^{12,16}. These figures refer to situations where the alveolus is intact following extraction (**Diagrams 1-1 and 1-2**).

The figures will be higher in the presence of unfavorable architecture (dehiscence or natural fenestration of the vestibular bone) or the existence of an apical infectious pathology (granuloma, cyst) or periodontal pathology (angular bone defect). Vestibular vertical resorption is affected by the initial bone thickness: it is twice as important when the initial thickness is less than 2 mm¹². This notion is significant when referring to a study conducted by Huynh-Ba et al on a sample of 93 patients where

measurements of vestibular bone wall thickness were less than or equal to 1 mm in 87.2% of cases and greater than 2 mm in only 2.6% of cases¹⁷. The thin vestibular bone wall (less than 2 mm), often referred to as the vestibular bone lamina, receives most of its vascularization from the periodontal ligament and is therefore tooth-dependent. Avulsion of the tooth removes this vascular supply, so this bone layer is lost after extraction, regardless of the filling procedures performed. The reduction in healing time is motivated by the desire to minimize postextraction bone resorption and thus bone reconstruction procedures; however, in many cases (where the bone wall thickness is less than 2 mm), this resorption will occur as an inexorable consequence of biologic rules. Reconstruction is therefore necessary to compensate for the bone loss resulting from this remodeling. A study by Chen and Darby on a sample of 34 patients who had undergone flapless extraction of a maxillary central or lateral incisor with the adjacent teeth present showed that 16 patients had an intact socket, 9 had dehiscence, and the remaining 9 exhibited fenestration after 1 day¹⁸. At 8 weeks, 57% of the sites that were intact after extraction and 56% of the sites with fenestration had dehiscence¹⁸. The immediate implant placement procedure must therefore incorporate an implant positioning and bone and gingival reconstruction protocol that is able to neutralize this remodeling to ensure a predictable outcome for the patient¹⁹⁻²¹. Various studies have validated this technique and given it its place in the therapeutic arsenal. This is true in terms of implant survival rates as compared to delayed protocols since the first publication was written on this topic by Lazzara in 1989²². Since then, this procedure has been validated by numerous studies²³⁻²⁶. Immediate implantation, like any other treatment option, presents advantages and disadvantages that must be kept in mind when developing treatment plans^{19,27}.

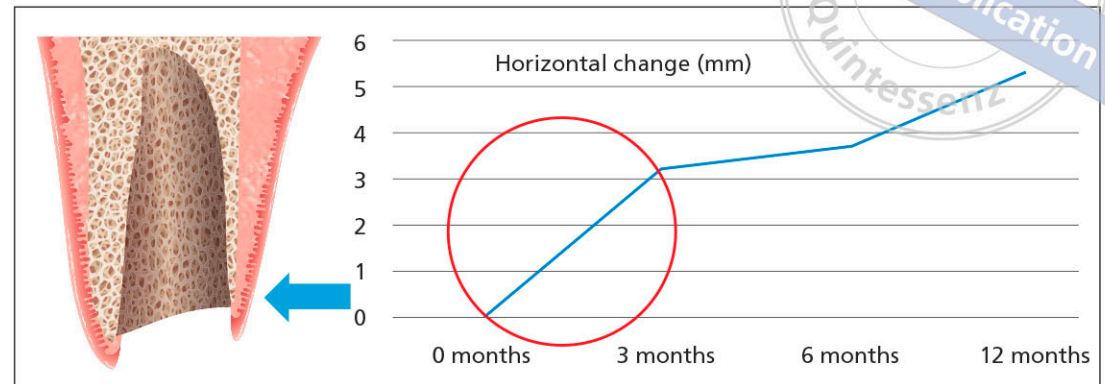


Diagram 1-1 Diagram of horizontal bone resorption over time.

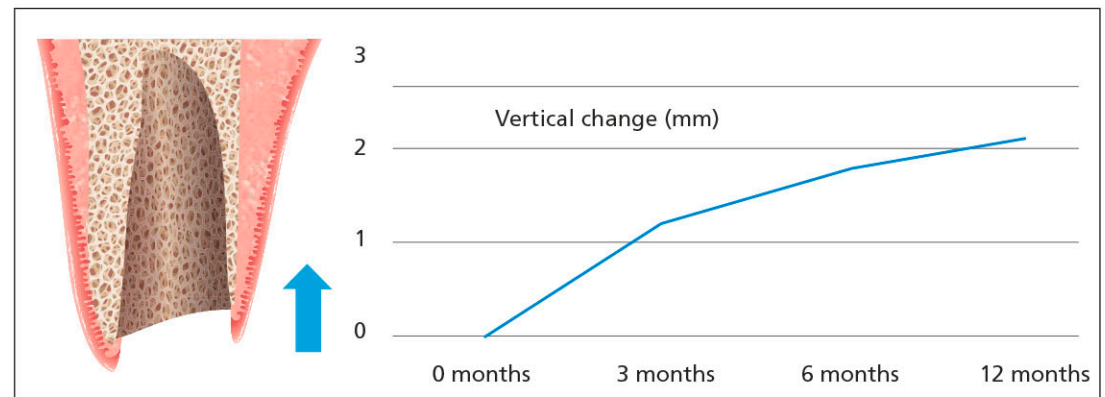


Diagram 1-2 Diagram of vertical bone resorption over time.

The advantages are as follows:

- it involves a single surgical procedure;
- the treatment period is reduced;
- the residual walls of the cavity are favorable to filling (three- or four-wall defect).

The disadvantages are as follows:

- bone architecture, depending on bone loss and initial dental axes, can be an unfavorable guide;
- the size of the cell may compromise primary stability;
- more invasive apical drilling may be necessary;

- there is a decrease in the height of keratinized tissue due to the absence of gingival closure during alveolar healing, and therefore a more frequent need for connective tissue grafting;
- there is an increased risk of vestibular recession of the marginal gingiva;
- the procedure is generally more complex than for early implantation (types 2 and 3).



Decision-making criteria

As with any therapy, knowledge of the favorable and unfavorable conditions for the optimization of a procedure is essential. In view of the literature and the recommendations of the ITI Consensus, a number of points must be understood before immediate implantation can be selected.

FAVORABLE CONDITIONS (Fig 1-3)

These include areas of low esthetic risk according to the ITI Esthetic Risk Assessment (ERA) classification²⁸:

- thick periodontal phenotype;
- low smile line;
- unitary edentulism;
- intact alveolus with a minimum vestibular wall thickness of 1 mm and a vestibular marginal margin that is no more than 3 mm more apical than the prosthetic platform of the implant neck;
- presence of unaltered proximal bone peaks;
- monoradicular tooth socket;
- site without acute phase infection;
- apical and palatal or lingual bone volume compatible with primary stability.

UNFAVORABLE CONDITIONS (Fig 1-4)

These include areas of high esthetic risk according to the ITI ERA classification²⁸:

- fine periodontal phenotype;
- thin vestibular wall (less than 1 mm);
- high smile line;
- vestibular dehiscence (bone edge located more than 3 mm apical to the ideal position of the future implant neck);
- multiple missing teeth;
- pluriradicular tooth;
- significant apical bone defect compromising primary implant stability;
- site with an acute infection;
- limited apical bone volume in relation to an anatomic obstacle.

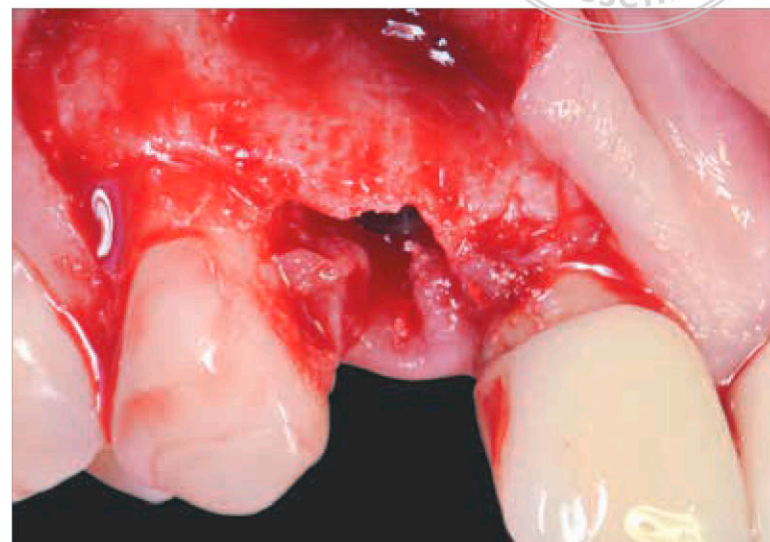


Fig 1-3 A favorable socket for a simple immediate implant procedure with an intact buccal wall with a thickness greater than 1 mm, with intact proximal bone peaks, thick gingival tissue, and sufficient keratinized gingiva.

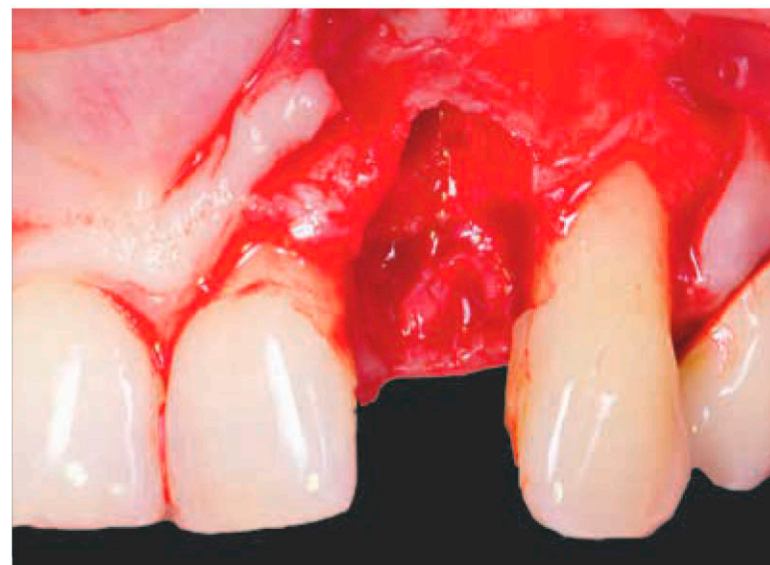


Fig 1-4 Complex socket architecture for immediate implantation with more than 3 mm vestibular bone loss from the optimal bone level for collar alignment. Proximal bone loss and alteration of the palatal wall can be observed; however, the gingival context is favorable.

To complete our review of the factors impacting the choice of therapy, a study by Kan et al of 100 patient CBCTs analyzed the bony environment of 600 teeth, and the authors derived a classification based on the root–cortex ratio²⁹:

- Class 1: roots in contact with the vestibular cortex (81.1% of sites);
- Class 2: roots in the middle of the alveolus not in contact with the cortices (6.5% of sites);
- Class 3: roots in contact with the palatal cortex (0.7% of sites);
- Class 4: two-thirds of the roots in contact with both cortices (11.7% of sites).

As will be discussed in detail in Chapter 3, Class 1 is most favorable for immediate implantation, followed by Class 2 and Class 3. Class 4 is the least favorable anatomic ratio for immediate implantation. This option is contraindicated if the apical bone site at the socket is not sufficient to achieve primary implant stability (Fig 1-5).

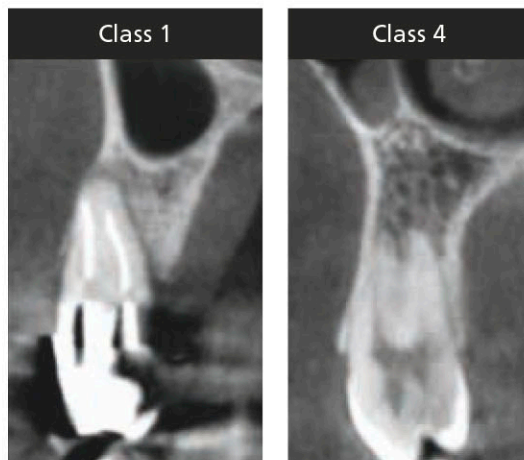


Fig 1-5 Radiologic appearance of the two root relationships in relation to the vestibular and palatal bone walls. Class 1 corresponds to the most favorable situation for immediate implantation, whereas Class 4 is the most unfavorable situation for such a procedure.

Positioning protocol

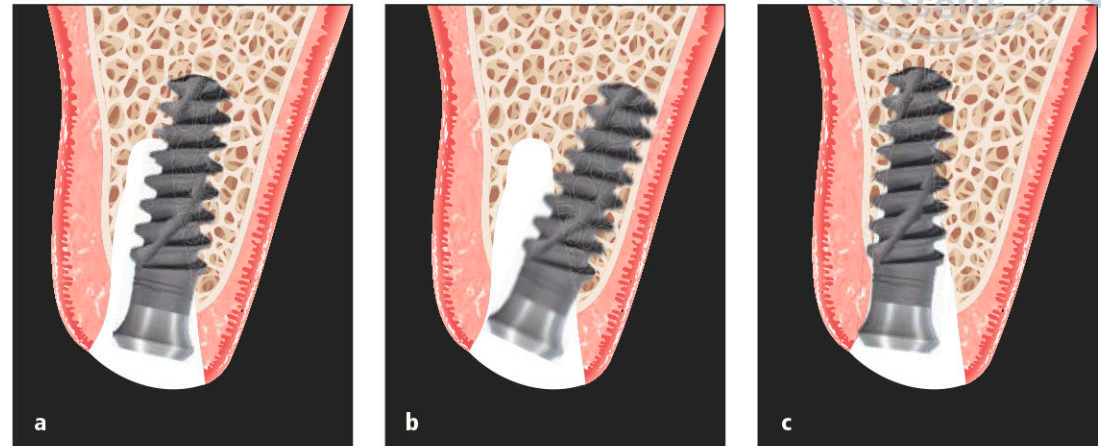


Fig 1-6 a to c (a) Suitable position for immediate extraction-implantation, combining implant positioning and primary stability. (b) Implant neck position too buccal. (c) Implant position in line with the bone socket, leading to overly buccal positioning of the implant neck and unstable primary implant stability.

Simple procedure

Because each technique needs a learning curve, as a beginner it is important to learn how to perform immediate implantation in a favorable context, namely a site with:

- a thick periodontal phenotype;
- a thick vestibular bone wall (greater than 1.5 mm);
- sufficient bone apically, palatally, and lingually to ensure primary stability;
- the absence of acute infection (chronic silent infections are not a contraindication)³⁰⁻³³;
- the possibility of opting for flapless surgery.

The procedure involves perforating the palatal or lingual cortical bone of the alveolus in its limit corresponding to the middle or apical third using a ball bur or pointing drill. The first drill will penetrate this perforation with a 45-degree vestibular angulation, then its axis will be straightened as it is driven in to finish drilling in an axis parallel to

the axis of the extracted tooth. The final position of the implant should be 2 mm more palatal to the vestibular inner wall and 1 mm more apical to the desired 3D position. The space left between the implant body and the vestibular wall will be filled with a slow-resorbing bone substitute^{34,35}. In the case of a tissue-level (TL) or tapered tissue-level (TLX) implant, a 2-mm space must be left between the implant neck and the vestibular inner wall. The purpose of this drilling is to exploit the bone triangle that is frequently present in the anterior maxilla between the tooth socket, often in a very vestibular position, and the palatal cortex. For premolars and molars, the principle is the same, relying on the area corresponding to the middle and apical thirds of the palatal wall of the vestibular alveolus of the maxillary premolars, the lingual wall of the mandibular premolars, the vestibular wall of the palatal alveolus of the maxillary molars, and the interradicular bony septum of the mandibular molars (Fig 1-6).

Advanced procedure

This is another step in the learning curve that should make it possible to treat more complex cases that present with:

- a thin alveolar bone wall (less than 1 mm);
- dehiscence of the buccal wall exposing the coronal third of the root volume;
- unaltered proximal bone peaks;
- a fine phenotype;
- an apical granuloma without fenestration;
- a combination of the above factors.

To validate such a procedure, it is necessary to ensure that the residual surrounding bone volume will allow primary stability in the modified 3D position as described above. In addition, a minimum of 3 mm keratinized gingival height around the tooth to be extracted is required^{14,15}. If these two conditions are met, immediate implantation is possible. Periodontal reconstruction of the implant environment will then be required to enable stability of the gingival level around the implant emergence profile. It will also ensure the buccal gingival margin is in a position similar to that of the contralateral tooth, or at least with a change in vertical positioning (recession) of less than 1 mm. Recession greater than 2 mm will be considered an esthetic failure³⁶. In this clinical context, buccal recessions are more frequent and associated with three times the risk of vertical bone resorption (mean 2.1 mm)^{34,37-39}. It will therefore be necessary to overcorrect the defects to compensate for the tissue shrinkage that occurs during soft tissue healing and associate it with partial regeneration of the bone tissue, particularly in the medial zone of the defect, which is the furthest from the cellular sources of regeneration. This will involve use of guided bone regeneration (GBR) techniques with a graft consisting of a slow-resorbing bone substitute (deproteinized bovine bone mineral

[DBBM]) by filling in the thin vestibular bone wall or overcorrecting the bone defect horizontally^{20,38,40-42}. The latter will be covered with a resorbable collagen membrane. A dense connective graft of the tuberosity type will complete this correction in the vestibular region in cases with a thin phenotype, making it possible to minimize the occurrence of gingival recession and achieve more similar results between thin and thick phenotypes⁴²⁻⁴⁵.

Complex procedure

This represents the highest level of complexity in immediate implantation: its implementation therefore requires skills acquired through routine practice of the two previously described procedures. Sites may exhibit:

- an alveolus with dehiscence and/or fenestration exposing two-thirds or more of the coronal volume;
- gingival recession on the tooth to be extracted;
- loss of proximal bone peaks;
- proximal angular defects;
- an attack on the lingual or palatal wall;
- vestibular keratinized gingiva of less than 3 mm.

Of course, the bone volume, regardless of its alteration, must allow for primary implant stability in the optimal prosthetic axis. It must also allow for bone and gingival reconstruction, leading to a 3D environment similar to that required in the literature on healed crests. Overcorrection is even more important in this case, since the risk of partial bone regeneration is correlated to the distance from cellular and vascular sources. This complex context poses several contentious issues to which appropriate answers must be found.

Insufficient keratinized gingiva

The soft tissues will need to be corrected not only by thickening, but also by increasing the keratinized

gingiva. This means that a connective graft must be performed, not on the tuberosity but rather on the deep palate, which is more vascularized but less fibrous, to be able to expose part of this graft and induce keratinized healing in this area⁴⁶. The difficulty often lies in being able to combine the thickness and the increase in the quantity of keratinized tissue. As such, large connective tissue grafts are required.

Major bone loss but proximal peaks not altered

The increase in the size of the bone defect will complexify the predictability of GBR over the entire volume. As the size increases, the distance between the vascular and cellular sources becomes greater and the mechanical stabilization of the graft becomes more random. It is therefore necessary to provide the graft with greater osteoinductive activity by adding autogenous bone to the DBBM and/or by using growth factors such as plasma rich in growth factors (PRGF)^{47,48}. For the sake of standardization, the use of PRGF has been systematized according to the Anitua protocol during immediate implantation, regardless of the level of complexity⁴⁹⁻⁵¹. The rules of GBR are more applicable than ever with a collagenous resorbable membrane stretched and stabilized using pins. A nonresorbable membrane may be a solution for this type of defect, but the need for its eventual removal is more questionable in the context of immediate implantation with unburied implants. Complementary surgery should be evaluated in terms of the benefits and risks it presents for the management of the surrounding soft tissue. Supplementation with a tuberosity (bulky and fibrous) graft will secure the result in the event of partial failure of GBR⁵².

Altered proximal bone peaks

In this context, we have reached the limit of the capabilities of vertical GBR. As such, it is necessary to review the 3D positioning of the implant according to a modified prosthetic axis with a more apical vertical position of the implant towards the altered proximal bone peaks, implying a more apical emergence profile. This can be minimized by adding a tuberosal fibrous connective graft, but will inevitably have an esthetic impact of which the patient must be informed. Such situations are often encountered in the sequelae of periodontal disease, which frequently leads

to alteration of the neckline⁵³. In the case of a patient with no alteration of the surrounding gingival levels but with attachment loss affecting the adjacent teeth, performing pre-implant or peri-implant vertical bone reconstruction would be biologically impossible, except if performing strategic extractions to avoid altering the proximal bone peaks.

Buccal gingival recession

In addition to the previously described GBR procedures associated with connective tissue grafting, the esthetic impact of coronal positioning

in terms of repositioning the mucogingival junction line and therefore determining the pink esthetic score for the final result must be evaluated. In such contexts, if recession is associated with reduced or absent keratinized gingiva (Miller class 2), the type 2 (early implant placement) procedure should be preferred. The practitioner may also choose to maintain the indication for immediate implantation provided that the patient is clearly warned of the esthetic risk of a 2-mm gingival lift.

Hard and soft tissue management in the Quokka protocol

The notion of immediacy has a temporal justification and aims to shorten the duration of implant-prosthetic treatment. From the present authors' point of view, it is primarily of biologic interest as it limits the number of interventions. This makes it possible to work with the soft tissues in their full vascular and elastic capacity during implant placement. Conversely, increasing the number of interventions will lead to tissue that is increasingly scarred and therefore less easily mobilized and less vascularized in theory⁵⁴. We combine immediate implantation with immediate restoration to offer patients a certain psychological comfort; they arrive at the office and then leave with their tooth having been fixed. From a clinical perspective, this immediate restoration also makes it possible to guide the volume of GBR that is required through the presence of the coronal volume, as well as the volume of soft tissue adapted, which, associated with adequate 3D positioning, will help to obtain

an optimal emergence profile. This has become a real comfort in daily practice.

A screw-retained prosthesis, finalized and connected to a titanium baseplate before surgery, is the clinical ideal that guided us in our intellectual path. It offers several significant advantages: a much smoother surface than that achieved after relining in the mouth, a more finished esthetic of the tooth, and, above all, the possibility of an operative time that will make it possible to suture the soft tissues around the provisional prosthesis. This is an important development that allowed us to achieve optimal maturation of the emergence profile at 3 months post-implantation (Figs 1-7 and 1-8). From this point of view, the digital workflow will make it possible to standardize these possibilities in cases of single- and multiple-tooth and complete edentulism thanks to planning and CAD/CAM. This workflow will be detailed later in this book.

The therapeutic tools used are:

- creation of a flap through tunnelling;
- elevation of a full-thickness flap with or without releasing incision;
- GBR with a bovine inorganic bone substitute (Bio-Oss; Geistlich, Wolhusen, Switzerland) incubated in PRGF phase F2 (Endoret; BTI Biotechnology Institute, Vitoria, Spain);
- fibrin membrane from PRGF phase F1 (Endoret);
- a non-crosslinked bilayer collagen membrane (Bio-Gide; Geistlich);
- grafting of tuberosal connective tissue;
- palatal connective tissue grafting;
- a half-thickness incision for tension-free coronal traction;
- an anchored suspended advanced flap (ASAF) suture (Fig 1-9);
- a papillary suture.

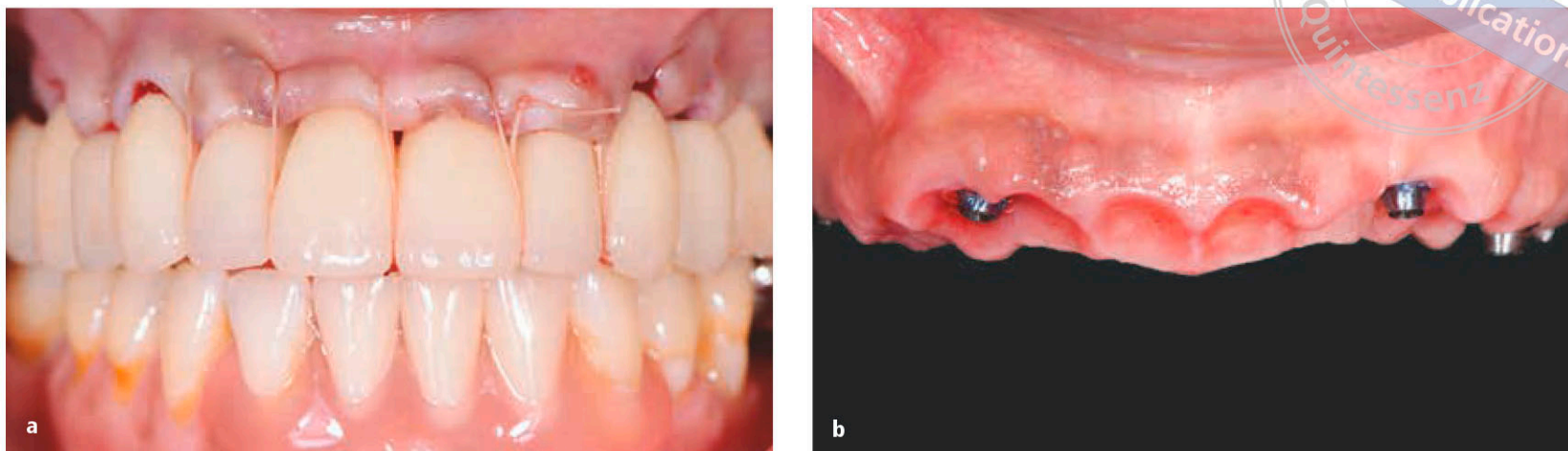


Fig 1-7 a and b (a) Immediate (instantaneous) loading of a provisional fixed/removable partial denture of twelve teeth connected to six implants. Note the sutures hanging vertically from the vestibular flap after coronal repositioning following a half-thickness incision, and the plunging pattern of the pontics in the non-implant extraction sites. (b) Scar situation 3 months after GBR-induced surgery, GTR, and placement of provisional prosthesis-guided sutures.

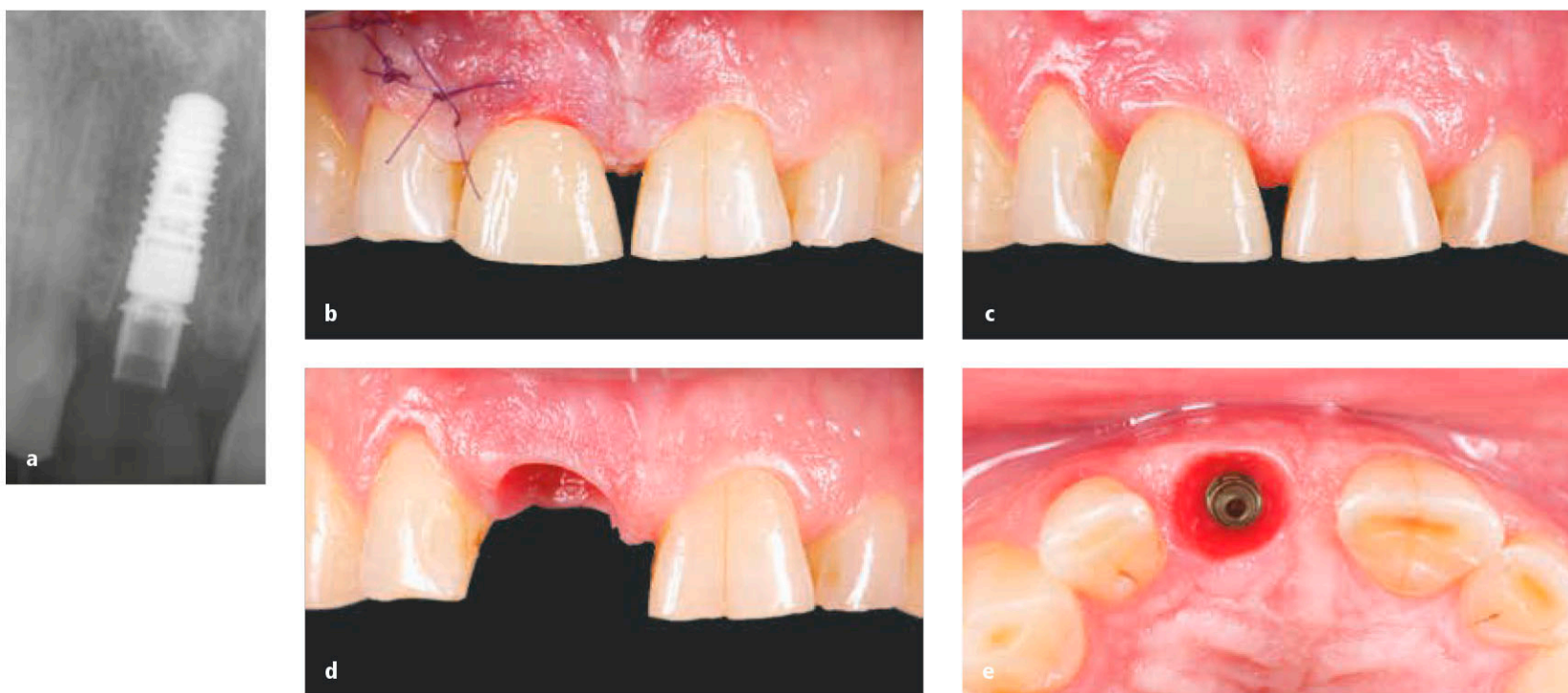

Fig 1-8 a to e (a) Radiologic view of the BL RC implant with a Variobase (Straumann, Basel, Switzerland). Note the more apical positioning of the implant as recommended by Chen et al. (b) Immediate loading of a screw-retained provisional tooth connected to a titanium baseplate on a bone-level (BL) implant with an ASAF suture. (c) Clinical appearance at 3 months postoperatively. Note the absence of inflammation. (d and e) Appearance after removal of the temporary tooth. Note the quality of soft tissue support and 3D periodontal volume and emergence profile architecture consistent with a provisional tooth-induced central incisor, GBR, and sutures.

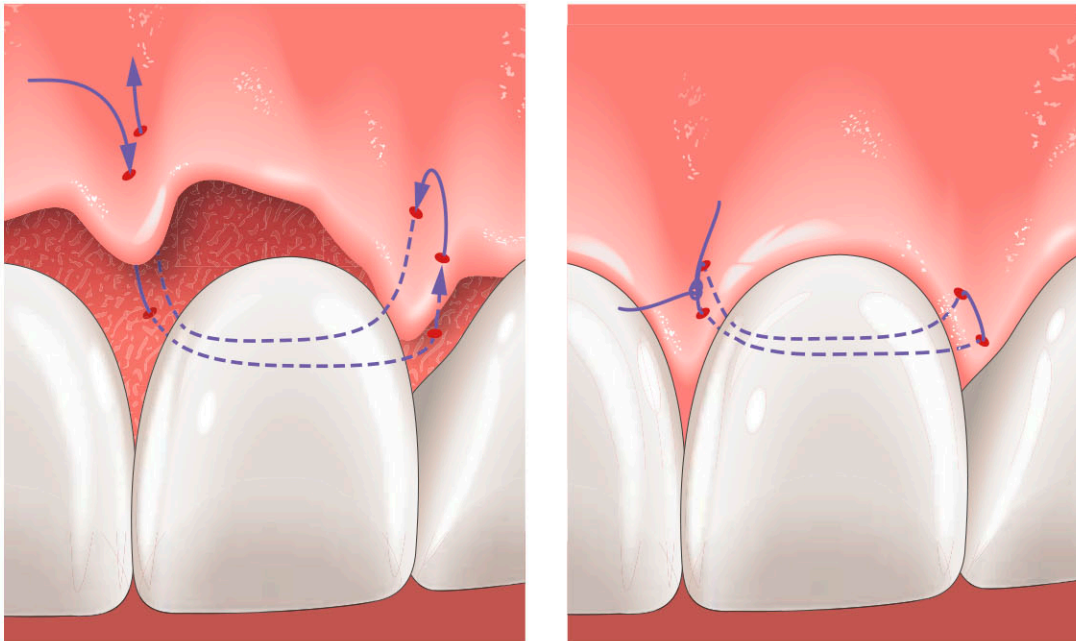
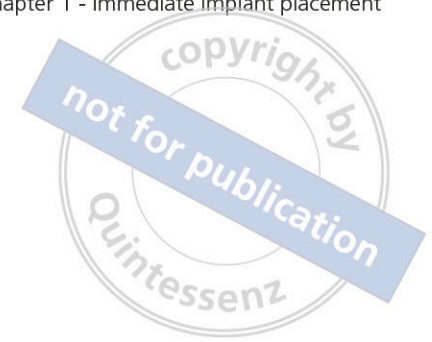

Fig 1-9 An anchored suspended advanced flap (ASAF) suture.

Treating more than 200 cases in total has allowed us to streamline our clinical approach to hard and soft tissue management during immediate implantation. Depending on the clinical situation at the outset, we wanted to define hard and soft tissue reconstruction protocols to standardize the performance of these procedures. This allows for repetition within each technique applied, and thus for continuous improvement of the technique and quality of the postoperative analysis according to the different categories. This is only a classification based on our practice, so must leave room for adaptations specific to each patient.

We have deliberately distinguished between the classification of bone defects and gingival defects even though they are often clinically interconnected.

Bone defects can be classified as follows:

- **GBR 1:** Four-walled bone defect of an immediate implant socket with a buccal wall not exceeding a vertical offset of more than 3 mm with the proximal bone peaks;
- **GBR 2:** Bone defect with vestibular dehiscence exposing less than one-third of the implant volume once the implant is positioned in the socket or vestibular wall, with intact proximal bone peaks;
- **GBR 3:** Bone defect with vestibular dehiscence exposing between one- and two-thirds of the implant volume once the implant is positioned in the socket, with intact proximal bone peaks;
- **GBR 4:** Bone defect with vestibular dehiscence exposing between one- and two-thirds of the implant volume once the implant is positioned in the socket with proximal and/or palatal or lingual involvement.

Gingival defects (GDs) can be classified as follows:

- **GD 1:** Vestibular gingival tissue thickness less than 2 mm;
- **GD 2:** Height of vestibular or lingual keratinized tissue less than 3 mm;
- **GD 3:** Vestibular gingival recession with apical keratinized tissue greater than or equal to 3 mm;
- **GD 4:** Vestibular gingival recession with less than 3 mm apical keratinized tissue.

The treatment protocols that we have standardized against this classification are summarized in [Tables 1-1 and 1-2](#).



Table 1-1 Classification of bone defects.

<p>GBR 1</p>	<p>Tunneling flap</p>	<p>Internal GBR with sticky bone (PRGF + DBBM) + fibrin</p>	<p>Coronal traction of the flap and ASAF suture around the temporary tooth</p>
<p>GBR 2</p>	<p>Full-thickness flap, sulcular incision of + 2 teeth on each side, without discharge</p>	<p>Internal and external GBR with sticky bone profile (PRGF + DBBM) + fibrin Covered by a collagen membrane scalloped against the temporary tooth</p>	<p>Coronal traction of the flap and ASAF suture around the temporary tooth</p>
<p>GBR 3</p>	<p>Full-thickness flap, sulcular incision of + 2 teeth on each side, with discharge</p>	<p>Internal and external GBR with sticky bone profile (PRGF + DBBM + autogenous chips) + fibrin Covered by a collagen membrane scalloped against the temporary tooth and stabilized using apical pins</p>	<p>Coronal traction of the flap and ASAF suture around the temporary tooth</p>
<p>GBR 4</p>	<p>Full-thickness flap, sulcular incision of + 2 teeth on each side, with discharge</p>	<p>Internal and external GBR in vestibular, proximal, and/or palatal profile with sticky bone (PRGF + DBBM + autogenous chips) + fibrin Covered by a collagen membrane transfixed by the temporary tooth and stabilized using apical pins</p>	<p>Coronal traction of the flap and ASAF suture around the temporary tooth</p>



Table 1-2 Classification of gingival defects.

GD 1	Tunneling	2-mm-thick tuberosal connective tissue graft over the width of the vestibular surface of the site	Coronal traction of the flap and ASAF suture around the temporary tooth with anchoring of the stabilized graft on the inner side of the flap
GD 2	Tunneling	2-mm-thick deep palatal connective tissue graft over the width of the vestibular surface of the site	Coronal traction of the flap and ASAF suture around the temporary tooth with anchoring of the stabilized graft on the inner side of the flap with exposure of the connective graft according to the desired gain of keratinized gingiva
GD 3	Sulcular incision of + 1 tooth on each side, with two discharges Full-thickness flap, then half-thickness flap	2-mm-thick tuberosal connective tissue graft over the width of the vestibular surface of the site	Coronal traction of the flap and ASAF suture around the temporary tooth with anchoring of the stabilized graft on the inner side of the flap or using two mattress sutures on the palatal flap
GD 4	Sulcular incision of + 1 tooth on each side, with two discharges Full-thickness flap, then half-thickness flap	2-mm-thick deep palatal connective tissue graft across the width of the vestibular surface of the site	Coronal traction of the flap and ASAF suture around the temporary tooth with anchoring of the stabilized graft on the palatal flap and -1mm exposure of the connective tissue



Presentation of the Quokka protocol

Introduction	33
The prosthetic project	34
Implant-prosthetic planning	49
The surgical guide.....	52
Guided surgery and immediate loading	55
Transfer of the project to the final prosthesis.....	62

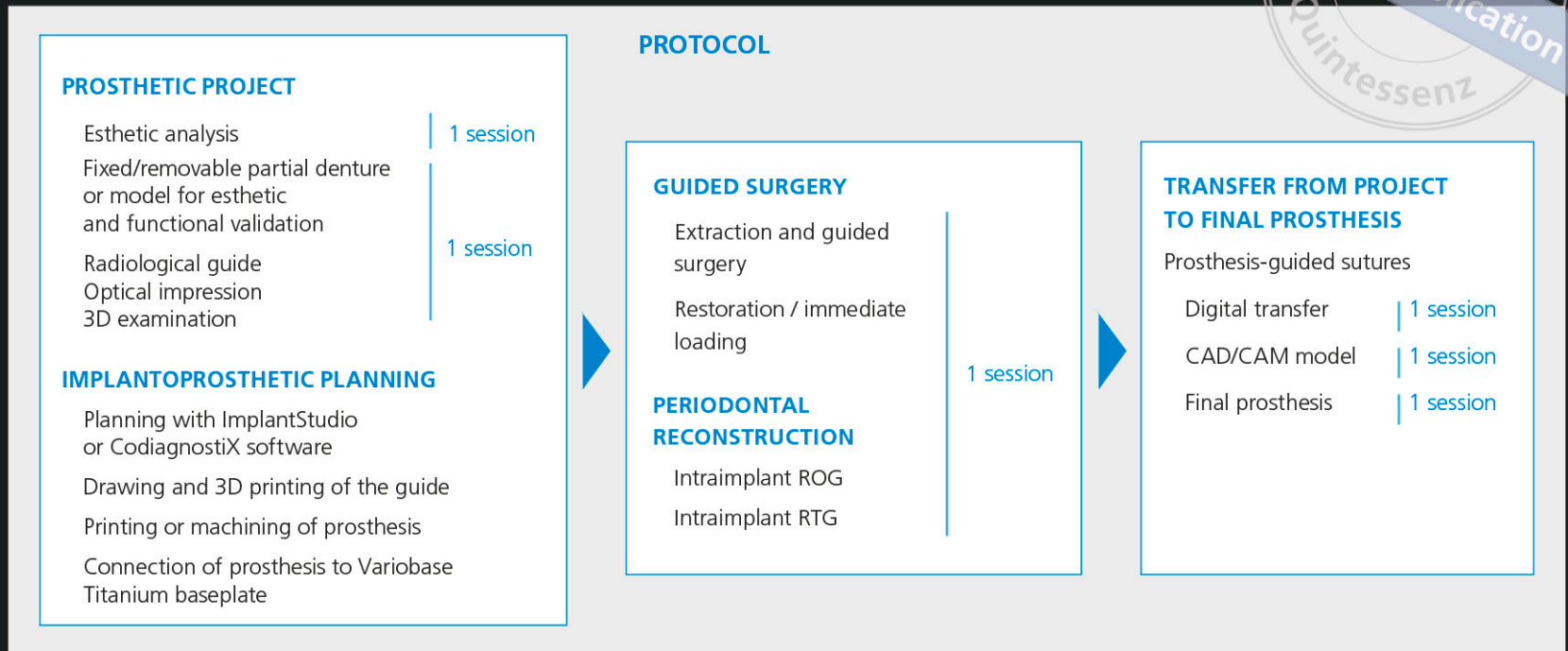


Fig 3-1 Schematic of the Quokka clinical protocol combining the academic principles of preimplant prosthetic study, 3D implant planning guided by the prosthetic project, the introduction of digital guided surgery in the concept of immediate implantation and instant loading via the digital workflow, prosthesis-guided periodontal reconstruction, prosthesis-guided suturing, and finally the transfer to the final prosthesis of the implant-prosthetic project at the end of the periodontal consolidation period.

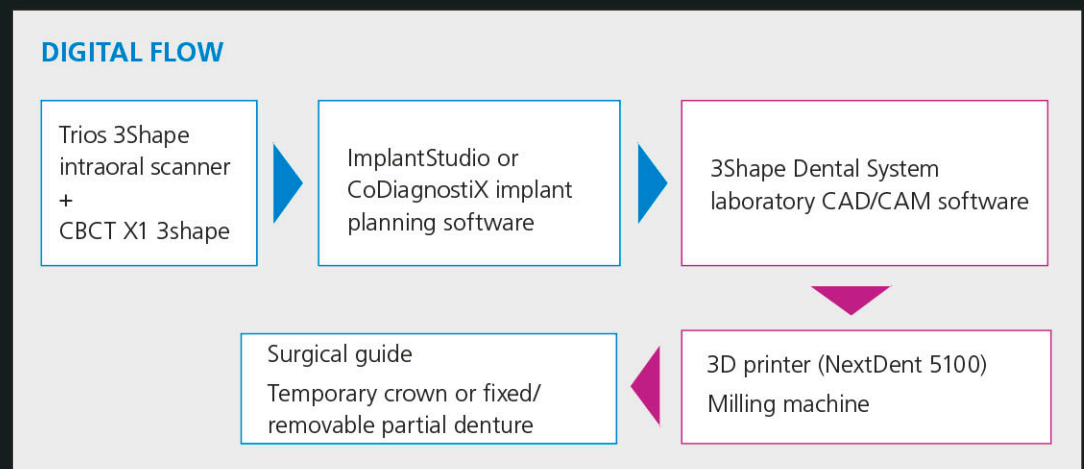
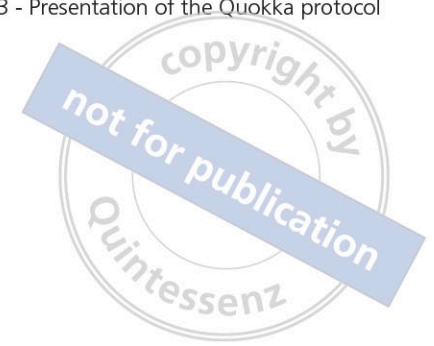

Fig 3-2 Digital flow diagram used in our daily practice for the past 6 years. Initially, in the first 2 years of development of our concept, we attached the provisional abutments to the fixed/removable partial denture in the mouth during surgery, with the relining polished before suturing, before connecting the titanium bases to the fixed/removable partial denture before surgery



Introduction

The Quokka concept, also known as “Smile in 1 hour by Quokka”, is a disruptive concept for implant-prosthetic treatment developed in the present authors’ practice. Its evolution began in 2016 with the integration of a digital workflow for immediate loading. This immersion in the possibilities offered led us to describe a successful clinical protocol that is now used daily in our practice to manage single, multiple, and complete implants. It is based on four key ideas:

- the central position of the prosthetic project in any major implant treatment, involving a significant modification of the patient’s function and/or esthetics;
- the removal of any transitional removable prosthesis while administering patient care;
- a reduction in the overall duration of implant treatment;
- placement during implant surgery of the provisional prosthesis connected to the titanium bases **before** surgery, allowing a faster implant placement procedure and especially the development of the concepts of guided bone regeneration (GBR) and sutures guided by the prosthesis.

The strength of this protocol is that it systematizes the meeting of these four axes of reflection within a **standardized, rapid, and reproducible** approach that can be adapted to the different

types of edentulism. The digital workflow is an ergonomic tool that then makes it possible to simplify the study procedures, registration procedures and procedures for carrying out our treatments, while improving the quality of the obtained result on a daily basis. We are able to offer treatment for single or multiple missing teeth in four sessions, and for completely edentulous patients in six sessions.

In this chapter, we will present in detail the architecture of this protocol (**Fig 3-1**). In the second part of this book, we will describe its different clinical applications through cases we have treated in our practice. All these cases, dating from 2016 to 2023, were treated using a digital workflow that has remained unchanged for 7 years, with the exception of regular intrasystem updates. This is the 3Shape workflow (3Shape, Copenhagen, Denmark) performed using a Trios intraoral scanner (versions 3, 4, and 5), Implant Studio planning software and Dental System laboratory software. For the past year, we have been using coDiagnostiX planning software (Dental Wings, Montreal, Canada) for its broader application with the Straumann implant system (Basel, Switzerland), especially in managing the implant abutment library that allows the use of tapered bone-level (BLX) implants and their segmenting possibilities, which represents a real opening to some interesting clinical applications (**Fig 3-2**).

The prosthetic project

Functional and esthetic analysis

The importance of these analyses will depend on the extent and location of edentulism and the patient's expectations. They may be minor, for example in the case of a single missing tooth, or comprehensive, as with complete rehabilitations to treat multiple missing teeth, terminal tooth migration, and significant esthetic and functional discomfort. The purpose of this chapter is not to go into the details of these analyses, but rather to highlight the protocols used and the digital tools available for analysis. Fundamental knowledge is essential to fuel the reflection. The protocol and digital workflow are only ergonomic tools for reproducibility. We often refer to the concept used in computing of garbage in, garbage out (GIGO), meaning that if incorrect data are entered, the output data (results) will also be incorrect. This is to emphasize how important it is to distinguish clinical and fundamental knowledge from knowledge of technical or digital tools. Knowledge precedes and potentiates the possibilities of tools.

Functional analysis

Functional analysis must precede all other analyses because any prosthetic rehabilitation must be part of a healthy and functional musculoarticular context. Occlusal analysis, like any other analysis, is based on an established protocol that consists of evaluating the musculoarticular system, starting from the temporomandibular joints (TMJs) and muscles, to arrive at the individual dental morphology. The aim is to understand mastication in its entirety, as described in 1920 by Georges S. Monson (Occlusion as applied to crown and bridge-work).

We will discuss occlusal diagnostic strategy as we have been using it in our practice for many years and teaching it at CampusHB. The purpose of this book is not to go into detail on all the elements necessary for functional and esthetic analyses, but to refer to the basic courses that exist in these respective fields; however, we will explain the methodology used in our treatments. There is an opposition between the gnathological school, which is very mechanistic, and the functionalist school, represented by Pedro Planas, but in reality, they are not so different. Everyone is free to use one or the other based on their knowledge and skills. A synthesis of the two approaches dictates clear conditions for functionality (Fig 3-3):

- absence of intracapsular pathology;
- absence of muscular pathology;
- a reproducible and myocentric position of the mandible;
- alternating unilateral mastication.

The occlusal diagnostic strategy starts with the musculoarticular examination and ends with the analysis of the occlusal paths that generate the alternating unilateral mastication, as illustrated in Fig 3-4. In unitary rehabilitations, this complete analysis is questionable if there is no musculoarticular pathology or aberrant functional asymmetry; however, in the context of longer rehabilitation procedures, including those involving the anterior region (which implies reconstruction of the anterior determinant or guide), or that of complete single-arch or maxillomandibular rehabilitation, this analysis becomes essential to ensure symmetrical functional harmony. This is vital to control the forces required for immediate loading. The symmetrical and adapted occlusal load

OCCLUSION - FUNCTION

Normality is symmetry and balance,

- Symmetry of joint amplitudes
- Symmetry of resting states and states of muscular tension
- Symmetry of dental volumes
- Symmetry of functional balance

Pathology is asymmetry and imbalance.

Fig 3-3 Summary of desired functional normality before any immediate loading.

is just as important as the strength of the implant anchors and is a major determining factor in the success of immediate loading. When performing complete rehabilitation, we systematically opt for a balanced occlusion similar as for full removable dentures (FRD) to balance the lateral forces on the implant-supported prosthesis, whatever the material used. In single-arch treatments, it is important to modify the occlusal planes and curves with temporary polymethyl methacrylate (PMMA) resin occlusal tables in the antagonist arch if necessary. The use of nocturnal muscle deprogramming splints is a relevant option that is used during the immediate loading phase and placement of the final prosthesis. It is used systematically in complete treatments, subject to the patient's situation for other rehabilitations (Fig 3-5).

Esthetic analysis

It is difficult to dissociate esthetic analysis from functional analysis because a normal dental morphology is often the result of normal functional coronal volumes; however, smile analysis is a major element in our reconstruction therapies and an esthetic smile remains a major goal for patients that is synonymous with health and anti-aging. It is based on three essential elements:

- facial harmony;
- macroesthetics;
- microesthetics.

The tools currently available for smile design are all based on these elements. We use Smile Design by 3Shape (Copenhagen, Denmark) and have recently also begun using the 3D modeling software RAYFace. For the fundamentals, we recommend the publications by Spear and Kois, Morleys, and Coachman, developer of Digital Smile Design (DSD). Coachman was the first to use the digital tool to standardize the esthetic values described in the fundamental publications. We do not claim to explain the entire esthetic analysis here, but rather to outline some of the basic tools that are sufficient to use in the first instance with smile analysis and design software. Facial harmony through integration of the smile with the face is based on (Figs 3-6 to 3-8):

- three vertical and three horizontal lines (in frontal view);
- a vertical line, an angle, and a vertical length (in profile).

Macroesthetics defines the relationship between tooth volumes and (Figs 3-9 to 3-12):

- the lips;
- the gingiva;
- the adjacent teeth;
- their axis;
- their length/width ratio;
- their intrinsic form.

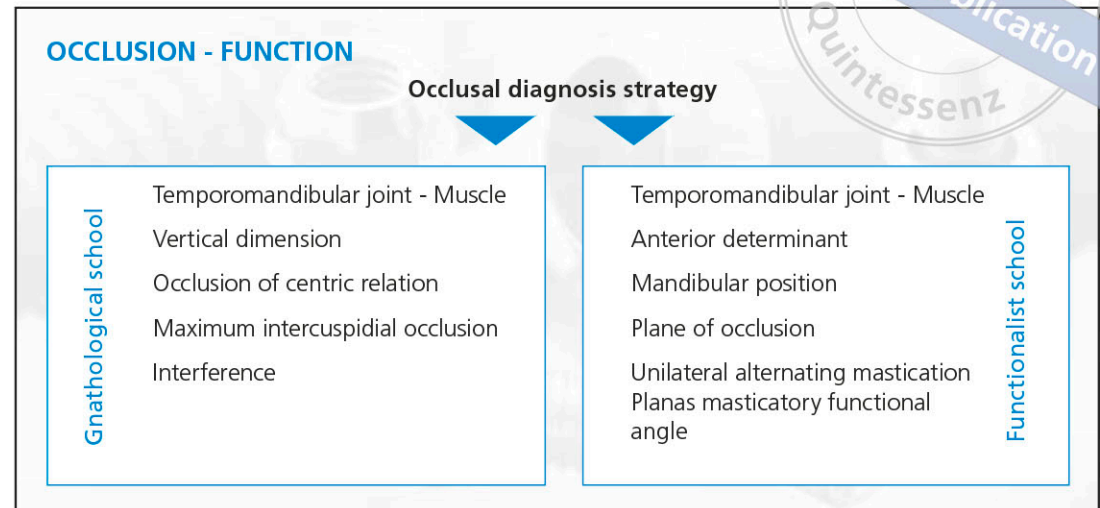


Fig 3-4 The occlusal diagnostic strategy represents the chronology to be followed in the evaluation and correction of occlusal dysfunction.

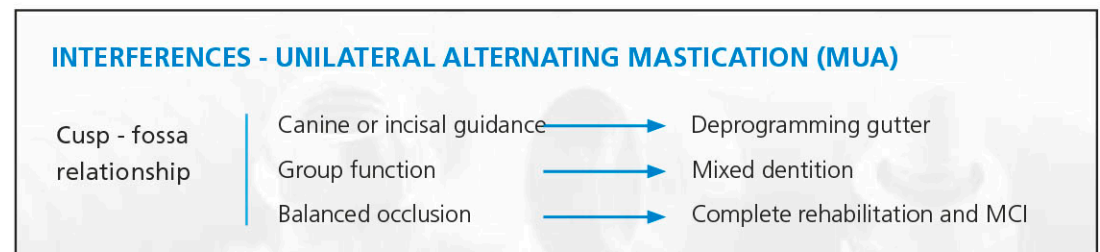


Fig 3-5 Recovery of functional dental relationships according to clinical situations.

Microesthetics is defined by the surface condition of the tooth and its stratification, which determine its visual chromatic rendering based on a priority ratio: brightness, then saturation, then shade. This last element is more concerned with the final prosthetic work carried out by the ceramist. At this stage in producing the provisional models, we limit ourselves to personalized morphological volumes and surface states.

This step enables the creation of a digital model that can be used to produce standard tessellation language (STL) files to:

- create a printed model from which a silicone key can be made to fabricate a mock-up (this option

is mainly used for denoportal restorations with veneers or crowns);

- design a provisional fixed/removable partial denture using CAD/CAM software and then for machining in a PMMA disc (Fig 3-13);
- import an additional file into planning software (an "additional scan" file that can be merged with the patient's STL files) to integrate the future coronal volume into the 3D implant position in accordance with the implant-prosthetic project. This is then referred to as a digital wax-up (Fig 3-14).

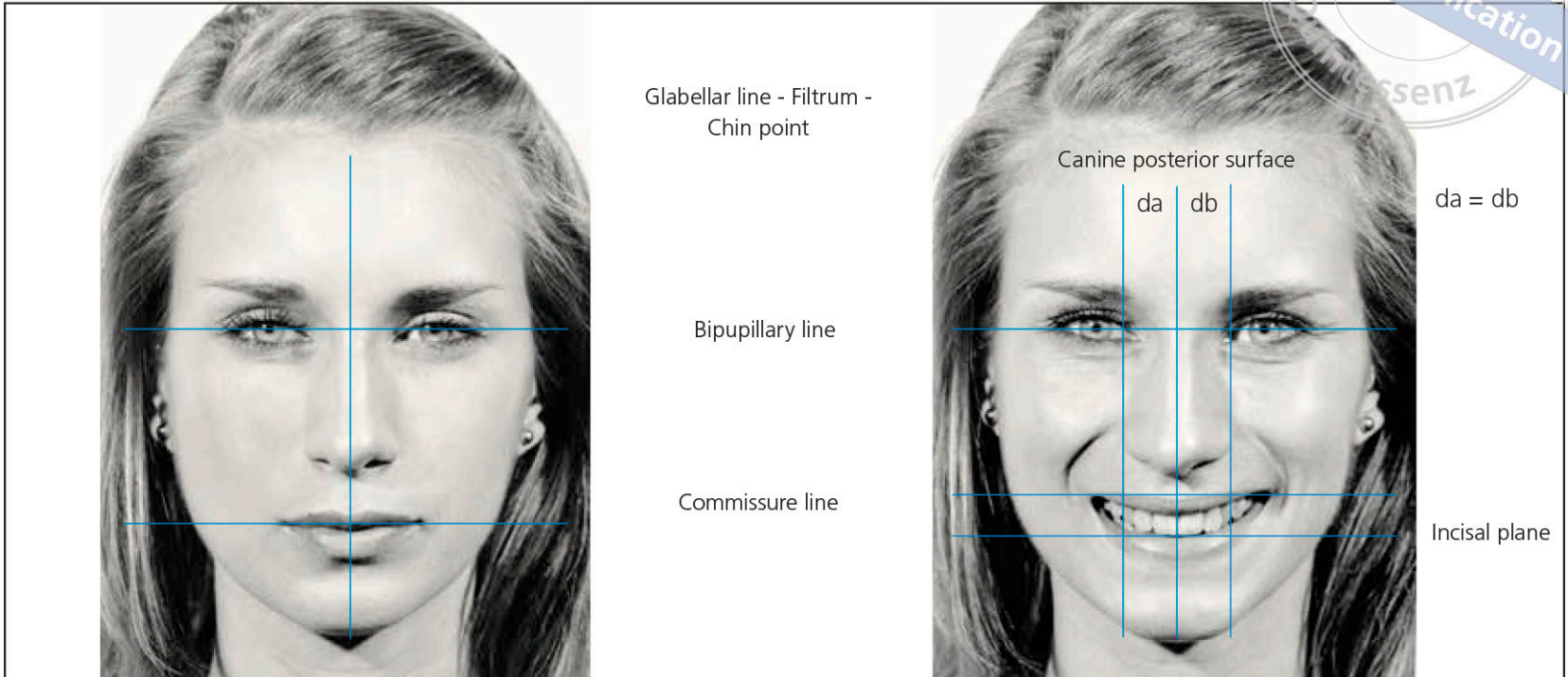


Fig 3-6 Analysis of facial integration of the smile in frontal view.

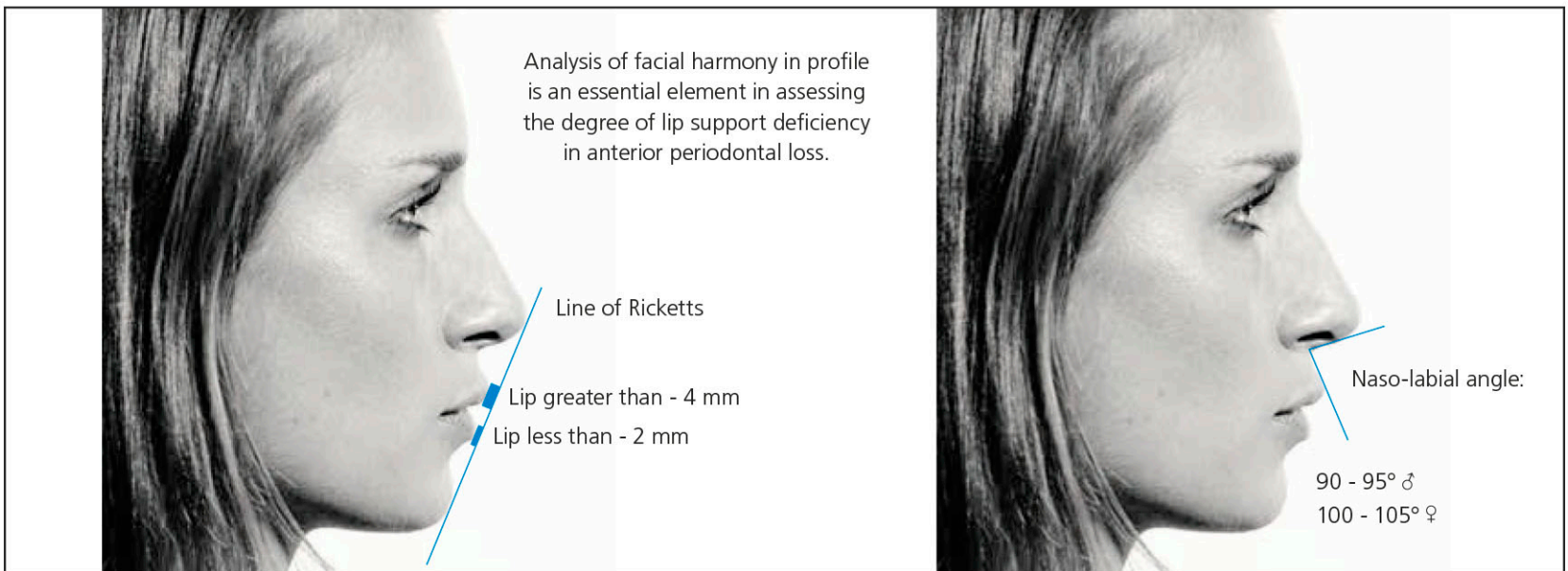


Fig 3-7 Profile analysis of smile integration.

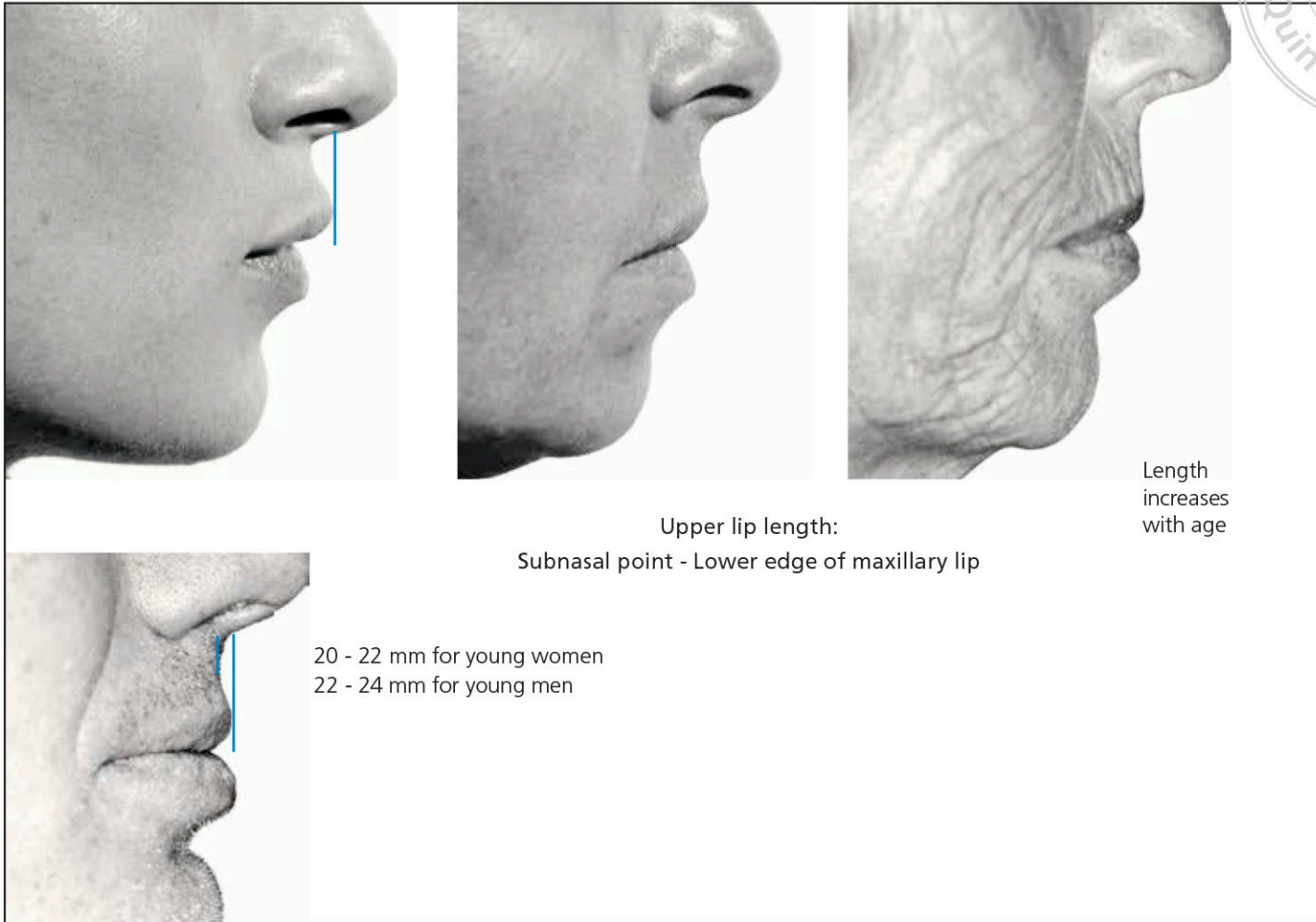



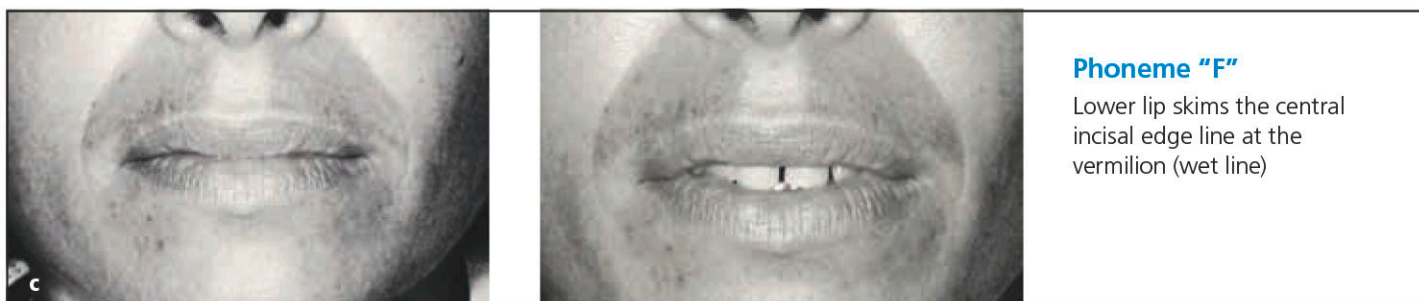
Fig 3-8 Consideration of age and sex criteria in lip support during dental rehabilitations.

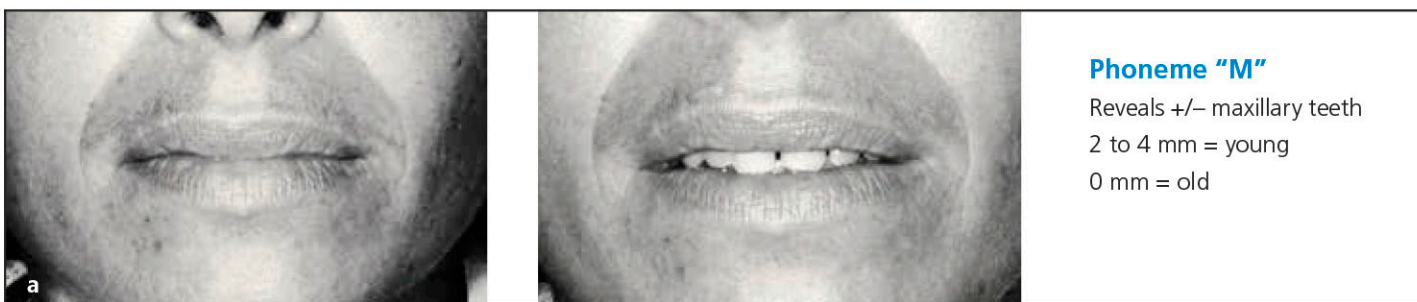
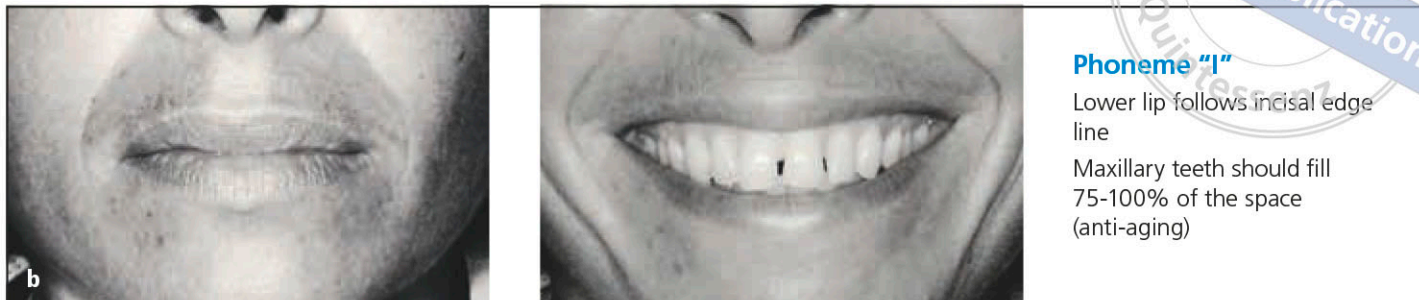
Fig 3-9 a Analysis of length, volume, and tooth–lip axis relationships when articulating the phonemes M.

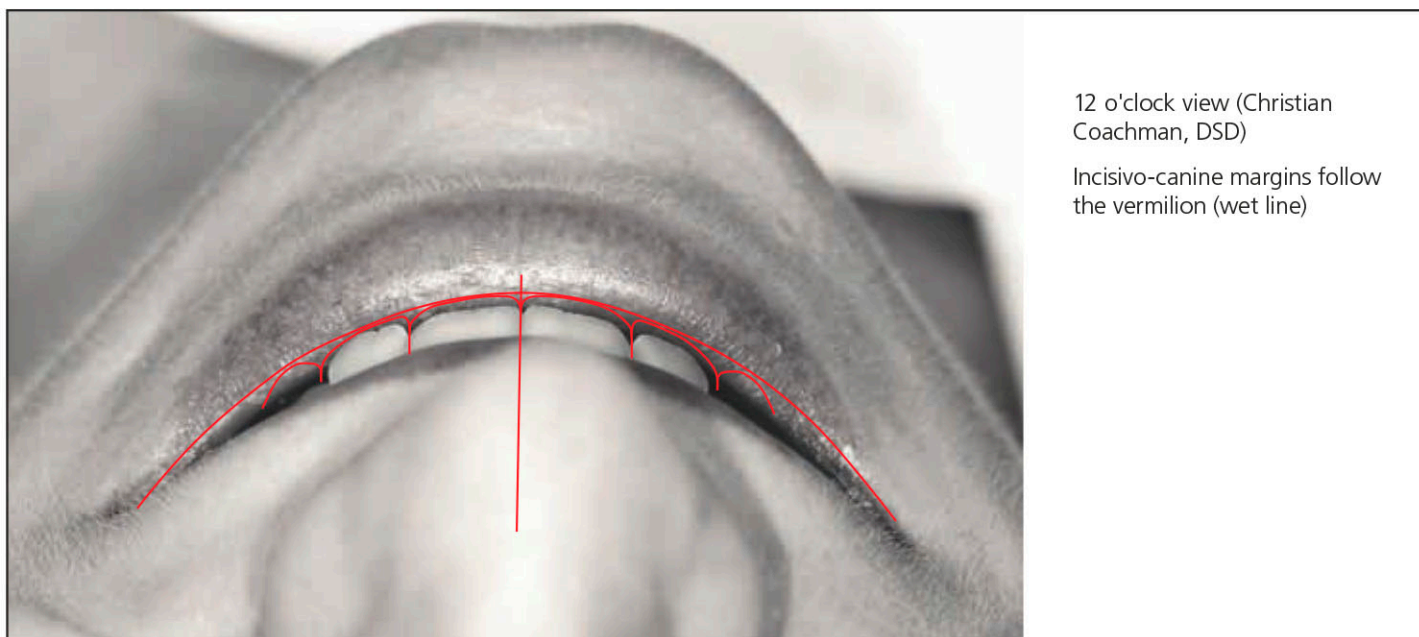


Phoneme "I"
Lower lip follows incisal edge line
Maxillary teeth should fill 75-100% of the space (anti-aging)



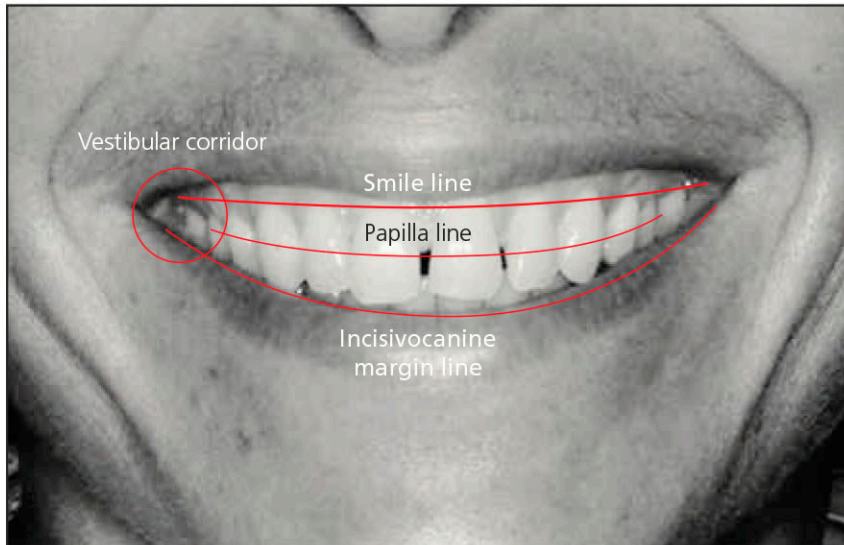
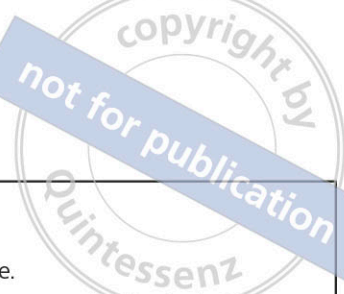Phoneme "F"
Lower lip skims the central incisal edge line at the vermillion (wet line)

Fig 3-9 b and c Analysis of length, volume, and tooth-lip axis relationships when articulating the phonemes I, and F.



12 o'clock view (Christian Coachman, DSD)
Incisivo-canine margins follow the vermillion (wet line)

Fig 3-10 The 12 o'clock view, introduced by Christian Coachman, allows analysis of the axis of the maxillary incisor group. The incisal edges should follow the vermillion line delimiting the wet lip from the dry lip.



Incisvocanine margin line

The lower lip follows the incisal edge line.
Maxillary teeth should fill 75-100% of the space (anti-aging).

Smile line

Tjian & Miller defined 3 classes: high, medium and low (70% of the population in the medium class). The middle class reveals all maxillary teeth when smiling, following the smile line.

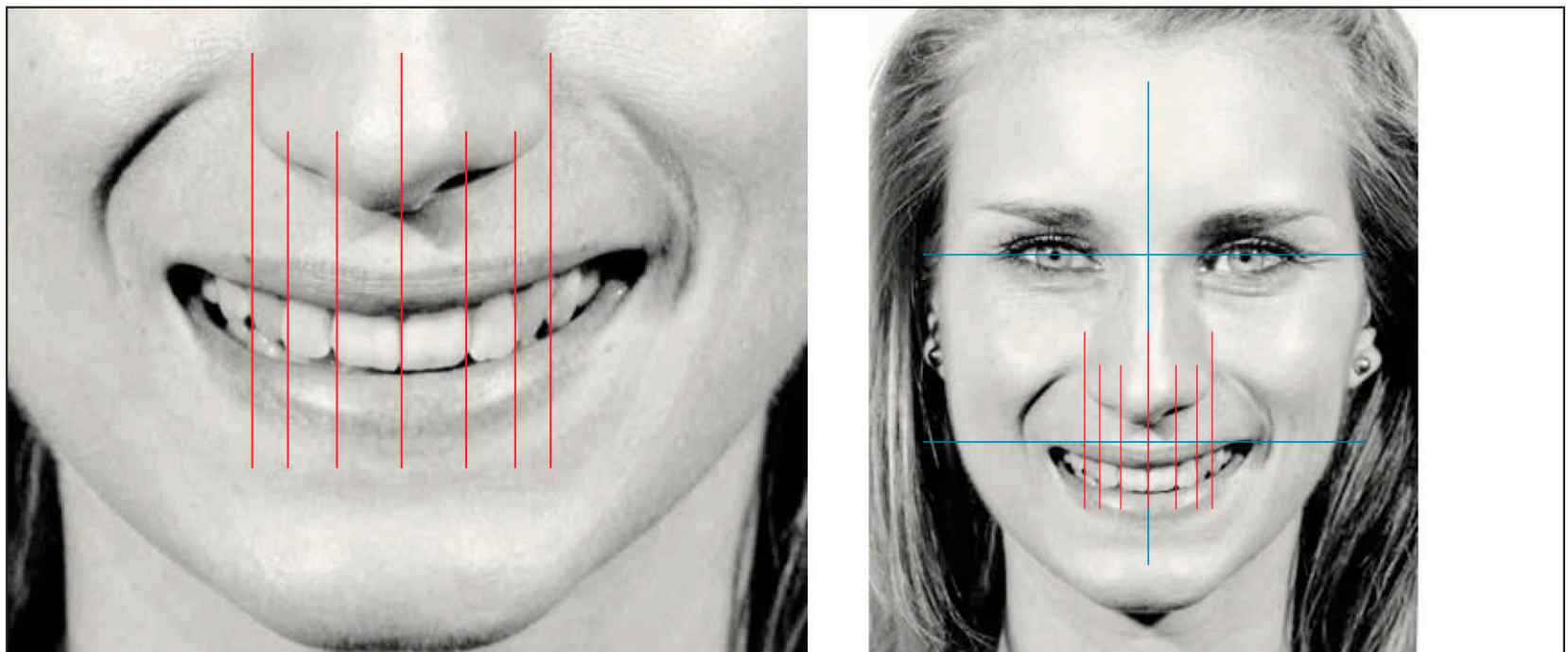
Papilla line

The papilla line follows the papilla points. The height of the papillae is around 40% of the height of the teeth.

Vestibular corridor

The smile line must be filled posteriorly by the dento-gingival volume.

Fig 3-11 Analysis of the relationship of the teeth to the lips, gingival collars, and oral corridors.



RED proportion: Recurring Esthetic Dental proportion 1 - 0.7 - 0.5. Central incisor proportion: 80% (75 - 85%).

Fig 3-12 The dental proportion to be respected according to the RED ratio by Christian Coachman.

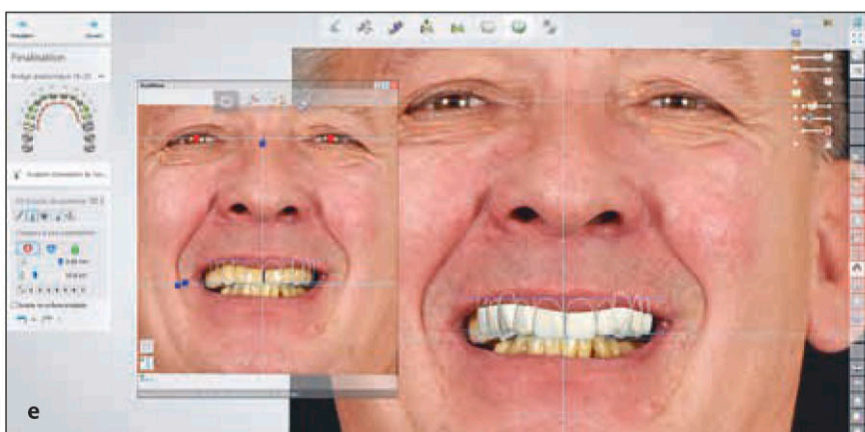
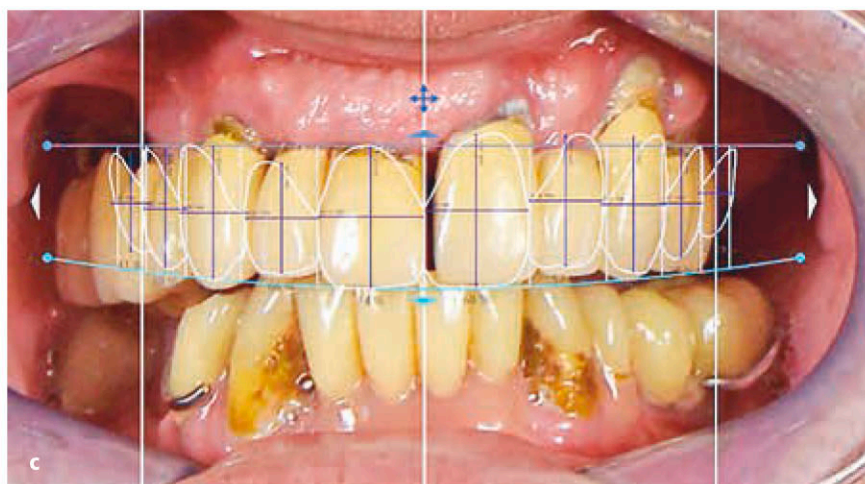
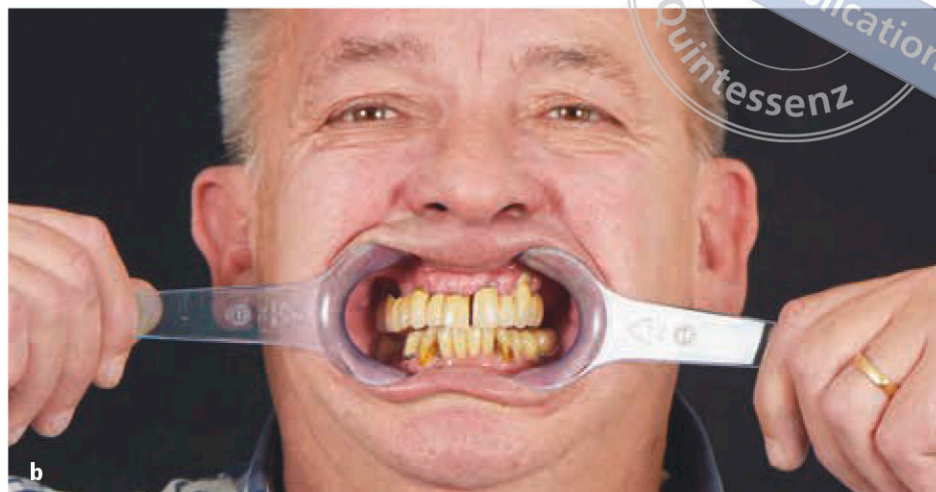
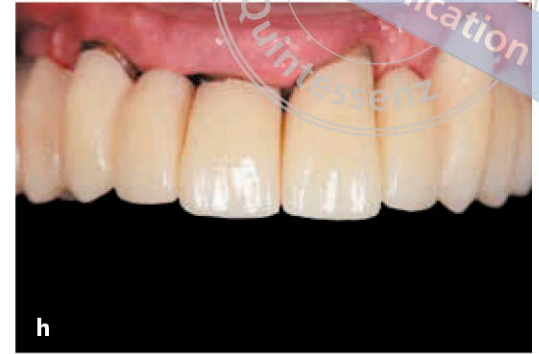
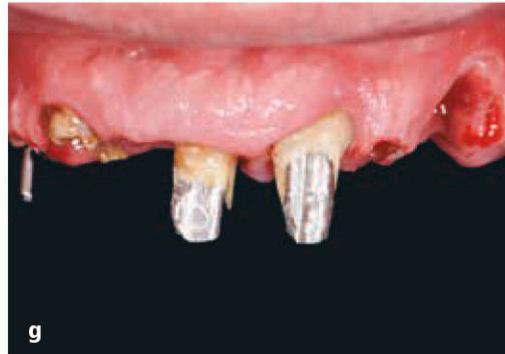
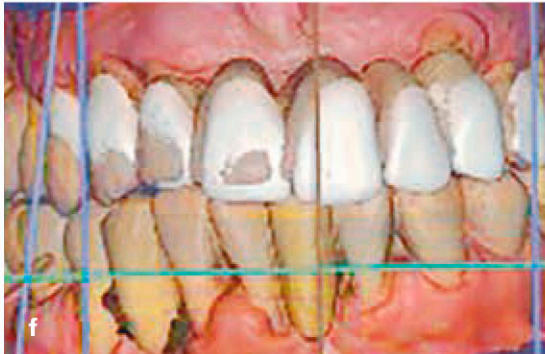Fig 13-13 a to j (a and b) Standardized photos inspired by Digital Smile Design (DSD) by Christian Coachman for esthetic analysis in the 3Shape Trios Smile Design software. (c) Elaboration tracing of the new setup integrating the smile line, the RED proportions, and the width and height of each tooth to be reproduced in the CAD/CAM software (Dental System, 3Shape). (d) Simulation of the new smile for digital evaluation of the future result. (e) Elaboration of the dental assembly in Dental System by Dentitek (Dardilly, France). (f) STL file of the bridge elaborated digitally before exporting for machining in a PMMA disk. (g) Sizes of the provisionally preserved teeth for the support of the partial denture for validation. (h) Partial denture in place with adaptation of the limits with regard to the very provisional function of this partial denture and the future of the teeth. (i and j) Frontal and side views of the prosthetic project validated by the patient, both esthetically and functionally.

copyright by
not for publication
Quintessenz



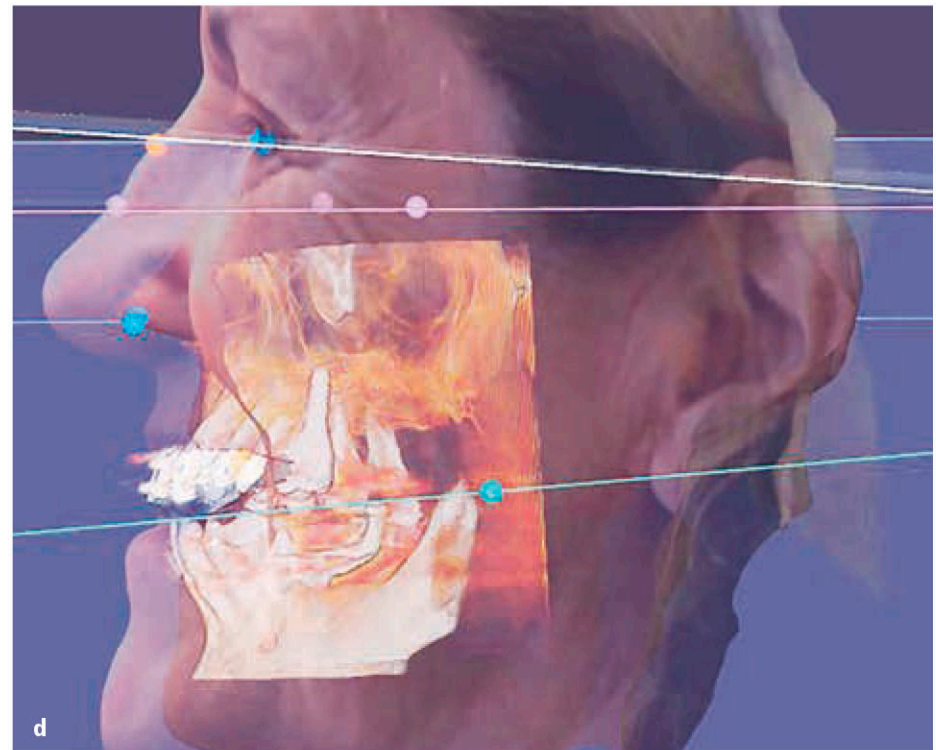
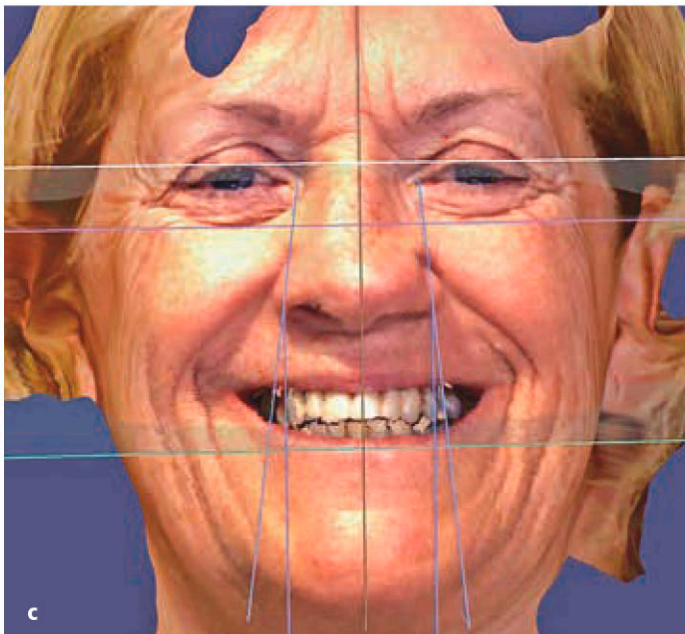
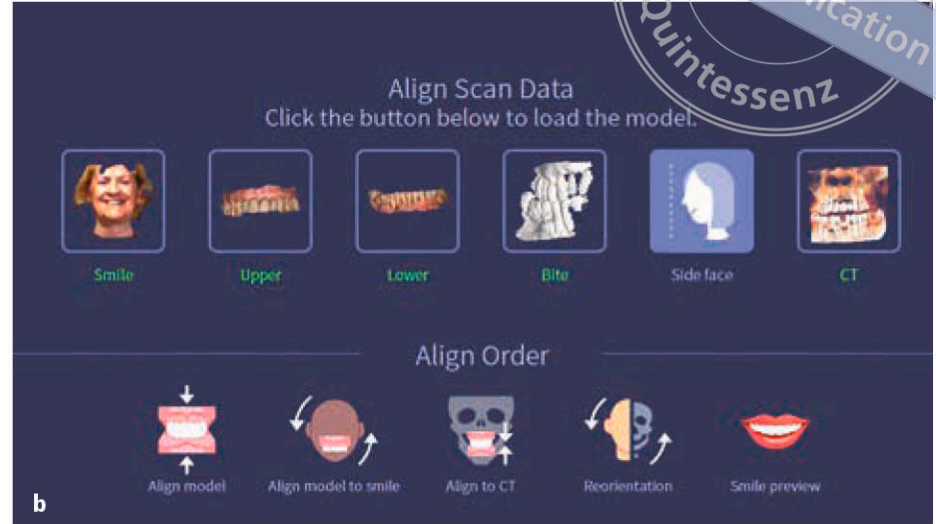
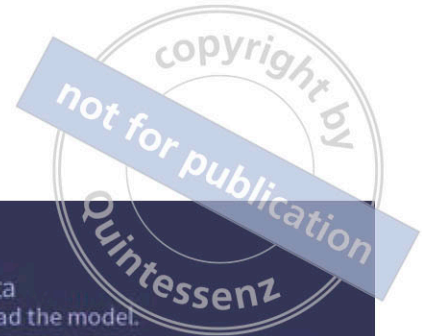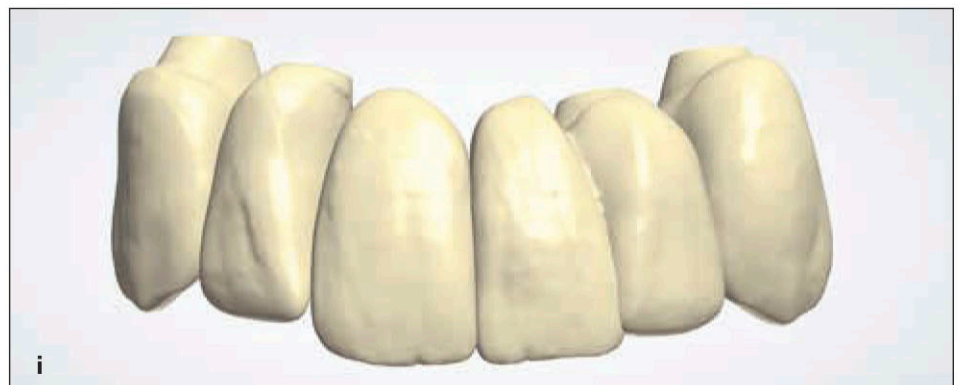
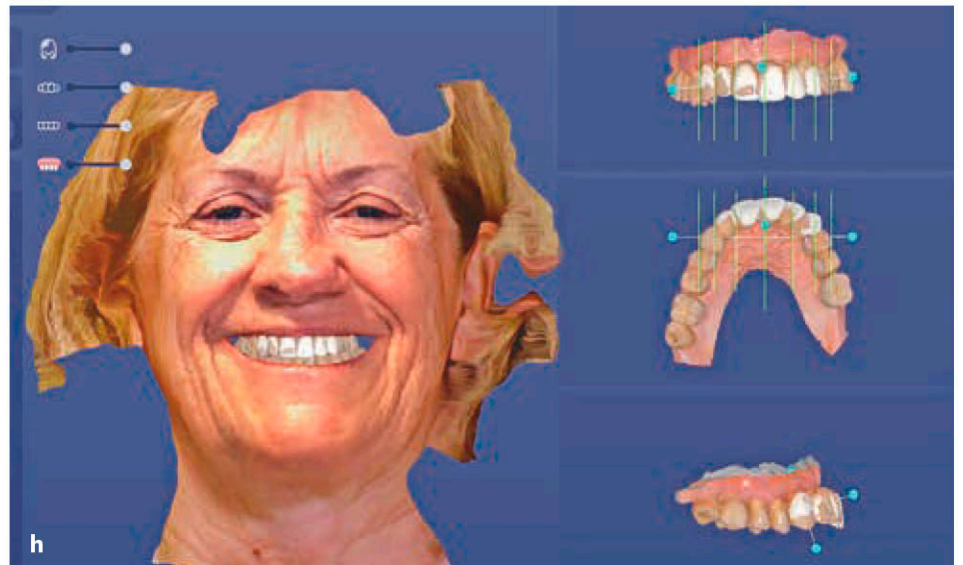
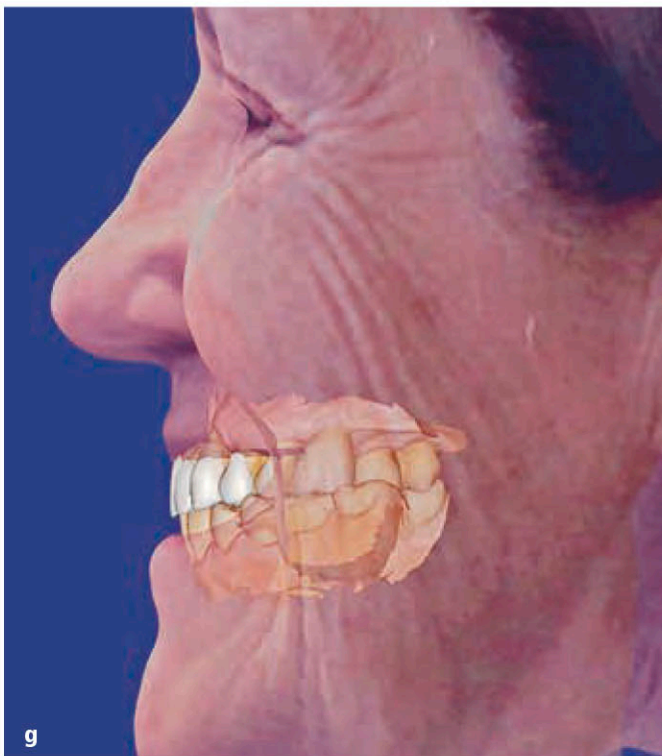
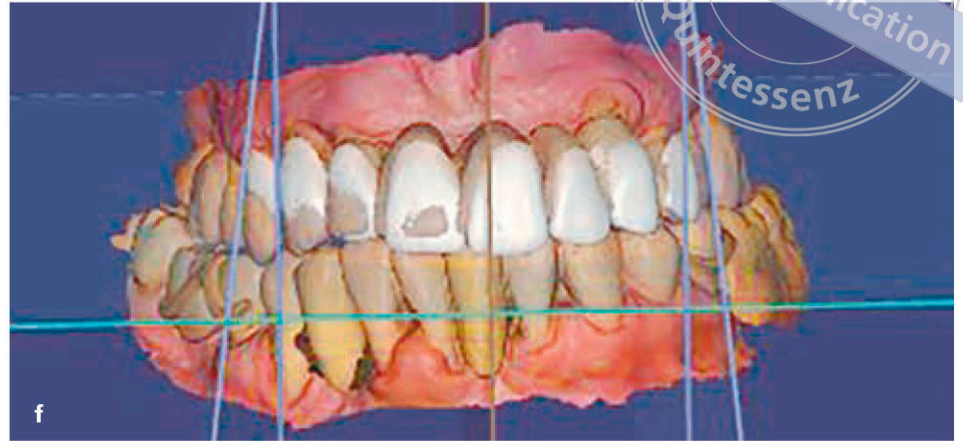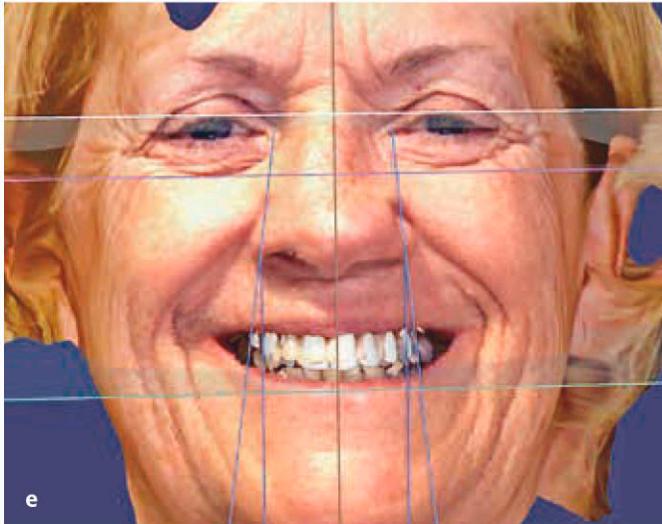


Fig 3-14 a to i (a) 3D acquisition of the patient's face using a new modeling tool (RAYFace, Ray Medical). From a near-simultaneous (0.5 seconds) capture of several photos from five angles, the resulting 3D reconstruction provides a model of the patient's face and smile. (b) It is then possible to merge the STL files of the dental arches and their bitewings with the DICOM file of the 3D radiological examination through surfacing. (c) Once the fusion is complete, reference planes can be drawn, including the Frankfurt, occlusal, sagittal medial, axis-orbital, bipupillary, canine, and other desired planes in order to

spatially order the 3D model with respect to these reference reconstruction planes. (d) Profile view of the model with the planes and the merged CBCT. (e) Elaboration of the smile from a library is then performed in 3D and oriented with the reference planes. (f) View of the arch assembly in the STL files without the face layer. (g) Profile view with the face layer. (h) A useful working window that makes it



possible to build the virtual wax-up in 3D and check its integration with the patient's face in three dimensions. (i) STL file of the instant loading bridge after its elaboration in Dental System after importing the STL file of the assembly made in RAYFace.

