

The hybrid approach to treating severe lower-extremity lymphoedema

Treating patients with severe lymphoedema can be challenging due to the recurrence of oedema over time. This case study illustrates how using different approaches provided a longer-term solution for a patient. A combination of traditional combined decongestive therapy, self-care and surgery were used to provide a successful outcome.

Authors:

Yuko Takanishi; Yoshihiro Ogawa;
Yuichi Hamada; Robert Harris

The successful management of lymphoedema using various strategies has been reviewed in the literature (Shaitelman et al, 2015). The use of combined decongestive therapy (CDT), a combination of manual lymph drainage, compression therapy, exercises and skin care has been well documented and is accepted internationally as the gold standard for successful lymphoedema management (Liao et al, 2012; International Society of Lymphology, 2016). Despite its acceptance, there have been many debates about individual components of CDT and their usefulness (Ezzo et al, 2015). Self-management has been utilised as an alternative and adjunct to therapist-applied CDT (Tidhar et al, 2014). More recently, surgical approaches to the treatment of lymphoedema have gained popularity, with many options now being available. The long-term efficacy of these options, however, remains unclear (Neligan et al, 2016).

This case study reports on a patient who underwent several intensive phases of CDT to manage her oedema.

CASE STUDY Medical history

A 62-year-old retired, single female patient residing in Japan presented with left lower extremity lymphoedema. At the age of 46, the patient had undergone surgery for ovarian cancer that included a total hysterectomy, bilateral salpingo-oophorectomy and pelvic lymphadenectomy. In addition to surgery, postoperative adjuvant chemotherapy was provided. At age 47, the patient experienced left lower-leg oedema with continued tissue swelling.

At the age of 52, the patient received CDT therapy at another hospital. Over the course of 1 year, she received therapy two to three times per

week that consisted of manual lymph drainage and elastic compression garments. The patient tried self-bandaging with multi-layer compression bandages, however the oedema increased over this time period. The patient experienced severe deformation of the limb and found taking care of herself increasingly difficult.

Treatment

The patient started receiving treatment at the Limbs Tokushima Clinic in Tokushima City, Japan, when she was 57. She underwent an intensive reduction-phase of CDT over 1 month. During this time, she received treatment for 1 hour per day, 6 days a week. The CDT treatment comprised of:

- Daily moisturising skin care using Hirudoid® Lotion
- Dr Vodder's manual lymph drainage treatment protocol for a patient with secondary leg lymphoedema, according to Wittlinger et al (2010)
- Compression therapy using short-stretch multi-layer lymphoedema bandaging consisting of Rosidal® K Short Stretch Bandage (L&R) (8 cm, 10 cm and 12 cm), Mollelast® conforming bandage (L&R) (6 cm), Rosidal® Soft compression bandage (12 cm and 15 cm), Idealbinde wide stretch compression bandage (L&R) (20 cm) and Kompres®II foam padding (L&R)
- Exercise therapy. Exercises were performed using a treadmill and joint motion machine for 1 hour a day.

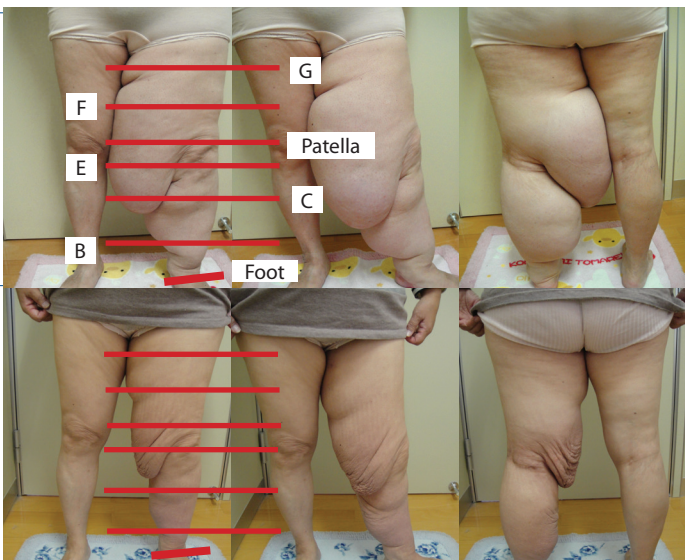
The oedema improved during the initial intensive reduction-phase CDT performed at the Limbs Tokushima Clinic [Table 1]. The patient was fitted for a compression garment after the intensive reduction-phase CDT. She received a Y30, class 2, flat-knit, custom-made

Yuko Takanishi is a Registered Nurse at Limbs Tokushima Clinic, Japan; Yoshihiro Ogawa is Cardiovascular Surgeon, Director at Limbs Tokushima Clinic, Japan; Yuichi Hamada is Chief of Plastic Surgery in the Department of Plastic Surgery, Japanese Red Cross Fukuoka Hospital, Japan; Robert Harris is Director of the Dr Vodder School – International, Canada

This article was previously published in the *Journal of Lymphoedema* JOL 13(1): 12–5

Table 1. Reduction-phase combined decongestive therapy, including multi-layer lymphoedema bandaging

Date	Measurement point	Right (cm)	Left (cm)
20 November 2012	Thigh (G)	59.4	76.0
	Thigh (F)	51.0	78.2
	Patella (upper border)	40.6	76.5
	Knee joint (E)	35.0	73.5
	Lower leg (C)	30.8	57.0
	Ankle joint (B)	20.0	30.8
	Foot	22.2	22.6
19 December 2012	Thigh (G)	56.5	65.2
	Thigh (F)	48.5	58.0
	Patella (upper border)	40.5	48.1
	Knee joint (E)	35.0	46.8
	Lower leg (C)	29.7	39.8
	Ankle joint (B)	19.8	25.0
	Foot	21.7	21.8



garment manufactured in Japan. The patient was taught home care exercises and skin-care practices.

The left inner, upper thigh showed a good response to CDT immediately after treatment, but this improvement proved difficult to maintain at home. Despite the use of the compression garment, the patient's swelling increased too much to allow its continued use. Reduction-phase therapy was, therefore, continued at 6-month intervals.

At age 60, the multi-layer lymphoedema bandaging protocol was adapted slightly. Instead of 10 short-stretch bandages, three medium- and six short-stretch Biflex® bandages (Thuasne) were used. In addition to this, Mobiderm® Autofit (Haddenham Healthcare), which is an uneven chip-foam bandage, was used under the stretch bandages. Mobiderm applies uneven pressure to the tissues and is reported to help improve the softening of fibrosis and fluid mobilisation. The change

Table 2. Reduction-phase combined decongestive therapy including medium stretch and Mobiderm bandages

Date	Measurement point	Right (cm)	Left (cm)
6 May 2016	Thigh (G)	61.0	74.0
	Thigh (F)	48.2	69.0
	Patella (upper border)	41.7	64.0
	Knee joint (E)	37.5	60.0
	Lower leg (C)	32.4	39.3
	Ankle joint (B)	20.4	24.7
	Foot	22.4	22.2
13 June 2016	Thigh (G)	60.0	67.8
	Thigh (F)	47.0	57.0
	Patella (upper border)	40.0	49.0
	Knee joint (E)	36.0	45.0
	Lower leg (C)	32.0	36.2
	Ankle joint (B)	20.2	24.8
	Foot	22.0	22.0

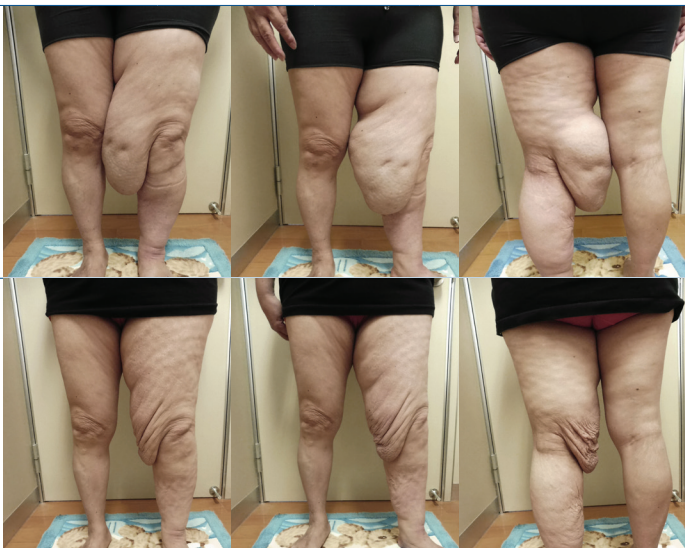
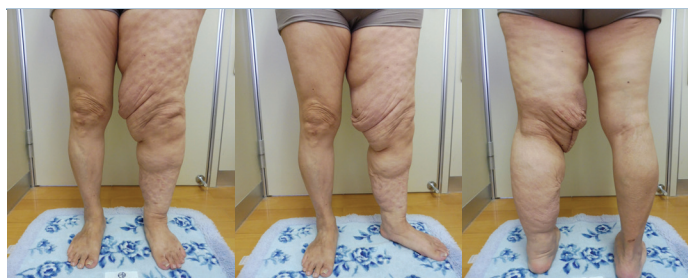

Table 3. Post plastic surgery to remove the skin flap (14 February 2017)



Measurement point	Right (cm)	Left (cm)
Thigh (G)	59.4	67.0
Thigh (F)	48.6	59.0
Patella (upper border)	41.7	45.0
Knee joint (E)	36.0	43.0
Lower leg (C)	30.0	36.5
Ankle joint (B)	20.4	24.5
Foot	22.2	22.0

References

- Ezzo J, Manheimer E, McNeely ML et al (2015) Manual lymphatic drainage for lymphedema following breast cancer treatment (Review). *Cochrane Database Syst Rev* (5): CD003475
- International Society of Lymphology (2016) The diagnosis and treatment of peripheral lymphedema: 2016 Consensus Document of the International Society of Lymphology. *Lymphology* 49: 170–84
- Liao SF, Li SH, Huang HY (2012) The efficacy of complex decongestive physiotherapy (CDP) and predictive factors of response to CDP in lower limb lymphedema (LLL) after pelvic cancer treatment. *Gynecol Oncol* 125(3): 712–5
- Miura M, Hamada Y (2017) Scanning electron microscopy findings in patients with lower-and upper- extremity lymphedema: fine-structure characteristics of subcutaneous tissues observed during lymphaticovenous anastomosis. In: Koshima I, ed. *Surgical Treatments for Lymphedema*. *Parson Syobo*: 86–102
- Neligan C, Jaume Masia, Piller N (2016) *Lymphedema: Compete Medical and Surgical Management*. CRC Press
- Shaitelman SF, Cromwell KD, Rasmussen JC et al (2015) Recent progress in the treatment and prevention of cancer-related lymphedema. *Cancer J Clin* 65(1): 55–81
- Tidhar D, Hodgson P, Shay C, Towers A (2014) A lymphedema self-management programme: report on 30 cases. *Physiother Can* 66(4):404–12
- Wittlinger H, Wittlinger A, Wittlinger D, Wittlinger M (2010) *Dr. Vodder's Manual Lymph Drainage: A Practical Guide*. Thieme Medical Publishers, Stuttgart, Germany

in bandaging technique provided enhanced reduction of the oedema and softening of the tissues. The patient found the self-application of these materials easier than the short-stretch bandages alone. Despite this, the sac-like oedema on the left inner, upper thigh continued to reform after treatment [Table 2].

Surgery

The sac-like, sagging-skin on the inner, upper left medial thigh was difficult to resolve and made donning and use of the compression sleeve challenging and required surgical removal. Preoperative examination with fluorescence lymphography using indocyanine green showed the presence of considerable dermal backflow in this area. The imaging also showed that the lymphatic vessels had been obliterated in the shallow layers of the skin but had expanded in the deeper layers.

Lymphaticovenous anastomosis (LVA) surgery was performed at five points in the lower left leg. The sac-like, sagging skin in this region complicated usual treatment. During LVA surgery, surgeons often notice systematic changes in the connective tissue surrounding the subcutaneous lymphatic vessels and skin layer (Miura and Hamada, 2017). During surgery, large dilated lymphatic vessels were observed in this region, indicating that they are a high-flow type. These vessels were observed in subcutaneous tissues other than the shallow layers. The state of the fibrosis varied depending on location. Only a small amount of fibrosis was observed under the skin, however, when considering the size of the extremity.

A significant further reduction was obtained using LVA surgery [Table 3], six months after the surgery). A slight but insignificant increase was noted at position F. The goal of the surgery was to reduce the skin flaps to enable easier donning of the garment and self-care, rather than volume reduction.

DISCUSSION

The initial phase of CDT led to a significant improvement in limb reduction. Although limb volume measurements were not calculated, limb circumference was reduced at all measuring points except the ankle. On the thigh (F), the limb was 20 cm smaller at one marking point after 4 weeks of intensive CDT.

It is evident from comparison of the results in Tables 1 and 2 that 4 years after the initial phase of treatment there was some return in oedematous volume in the affected limb. The second treatment regimen including the Mobiderm bandage, however, led to an additional reduction in limb volume. Modifications can be made to CDT, such as changing the type of bandaging material used, to maximise the effect of treatment, as were made in this case. Once the patient's limb size has reduced sufficiently, he or she can undergo plastic surgery in order to remove excess skin flaps, as occurred in this case study.

LVA surgery appears to have enhanced the effects achieved during CDT at this point in time. It will be interesting to follow this patient's management of her lymphoedema to see how successful the LVA procedure is in maintaining the reductions achieved in the long term.

CONCLUSION

Over the course of just over 4 years, the patient had a significant and consistent reduction in oedema volume using a combined approach to treatment. The effectiveness of each strategy appears to be cumulative and complimentary. It is uncertain from this case study whether the effect achieved after the final LVA surgery was enhanced by the excellent reduction attained in the first phases of CDT. Conversely, we do not know whether the effects achieved by CDT will be maintained or improved upon by the LVA surgery. WAS