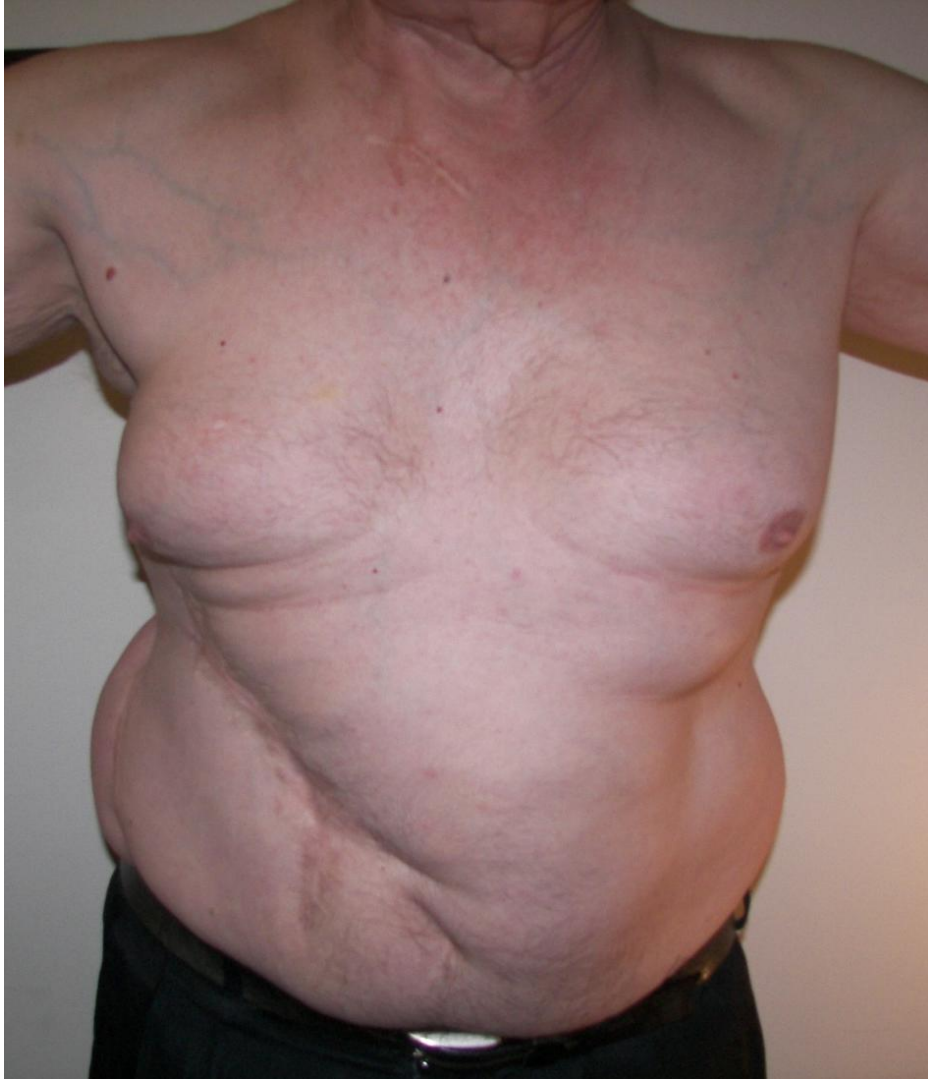

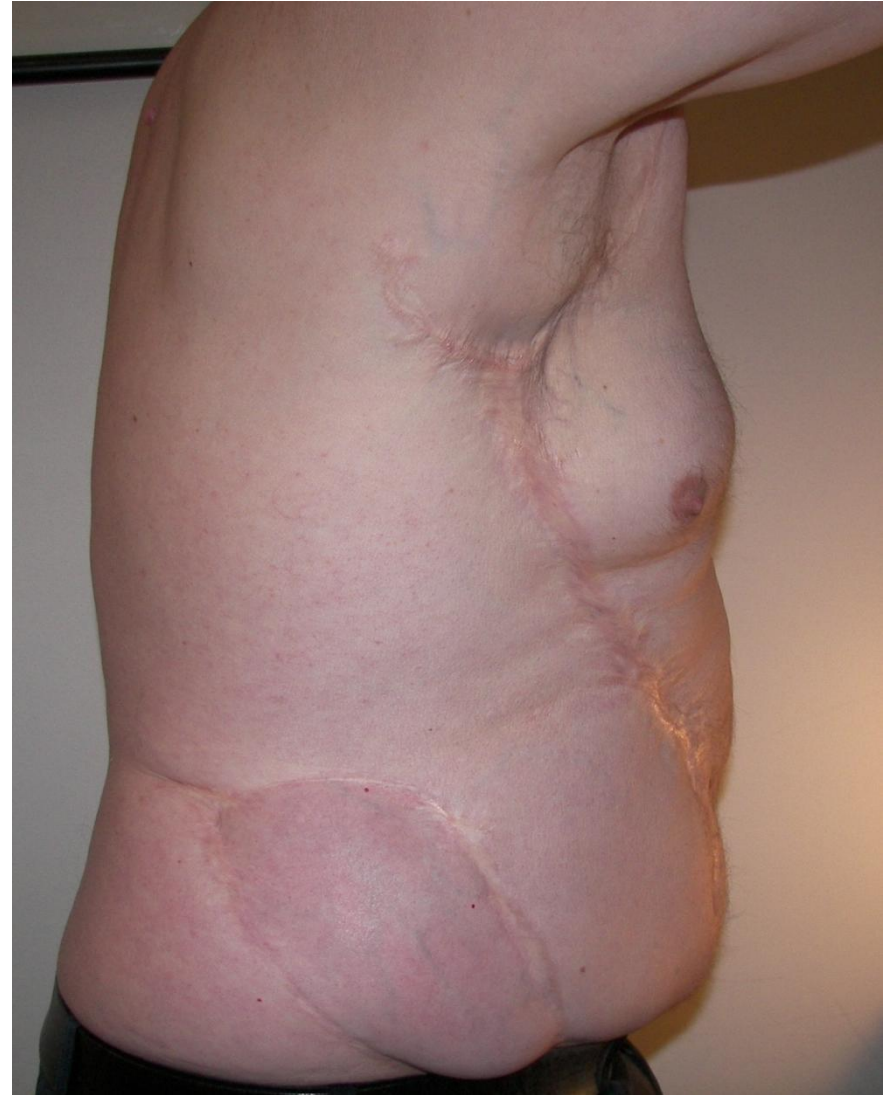Case Study

Mr P. 65 year old male

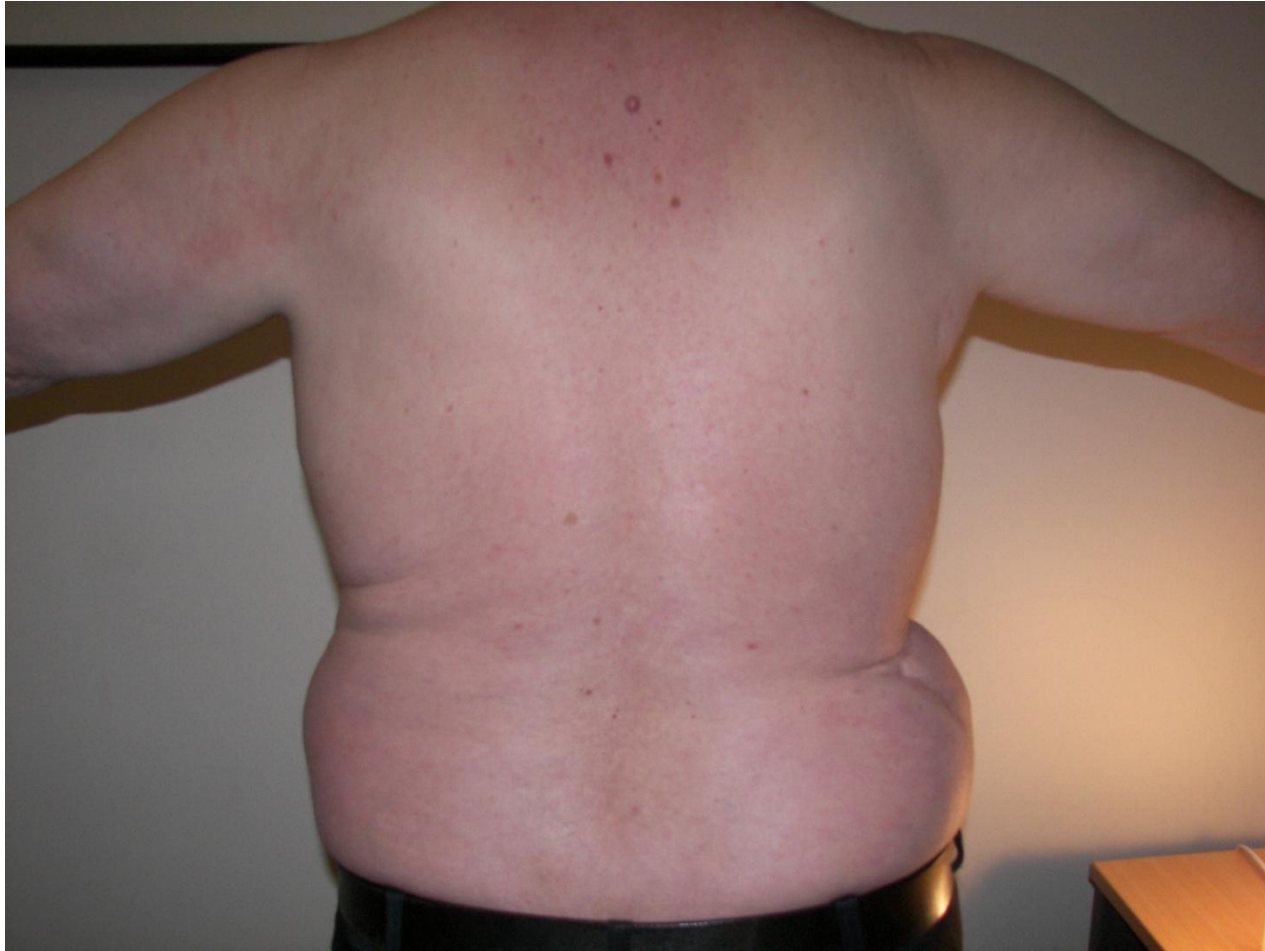- Developed primary lymphoedema in right leg at 13.
- Pinnacle implant surgery?
- Charles resection surgery.
- Surgery for Torticollis.
- Liposuction.
- Current condition.



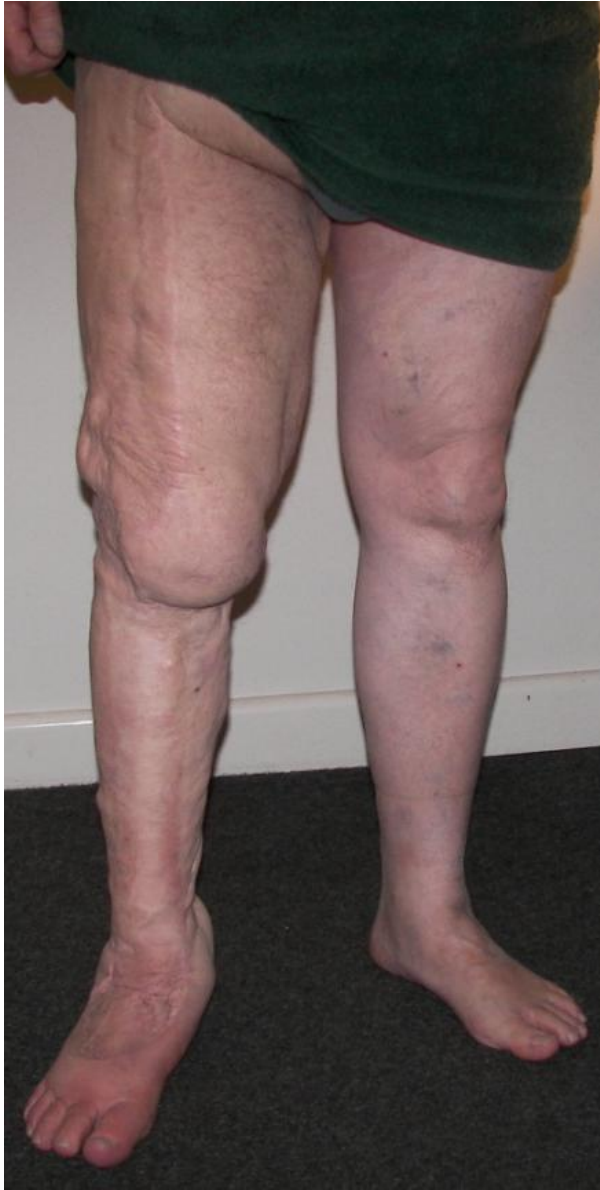Anterior view chest



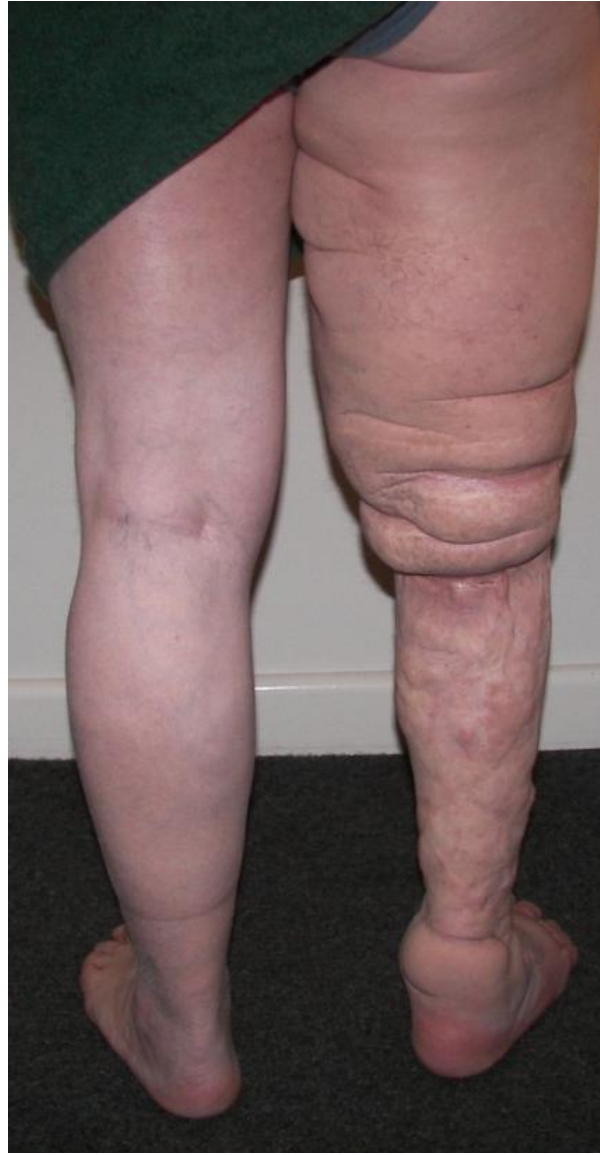Lateral view right side



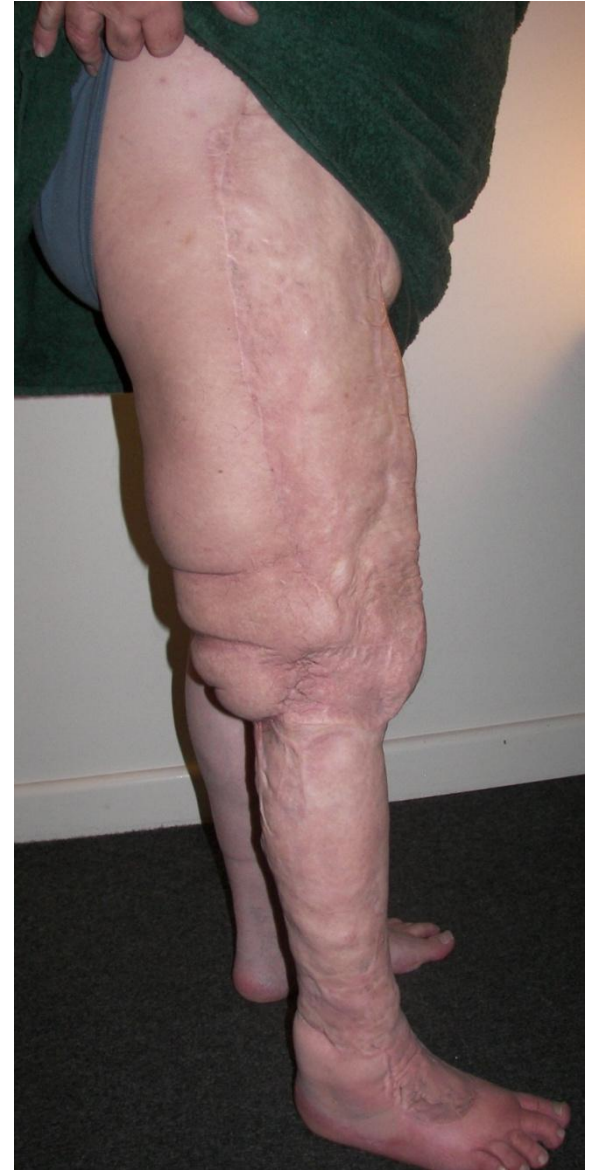Posterior view



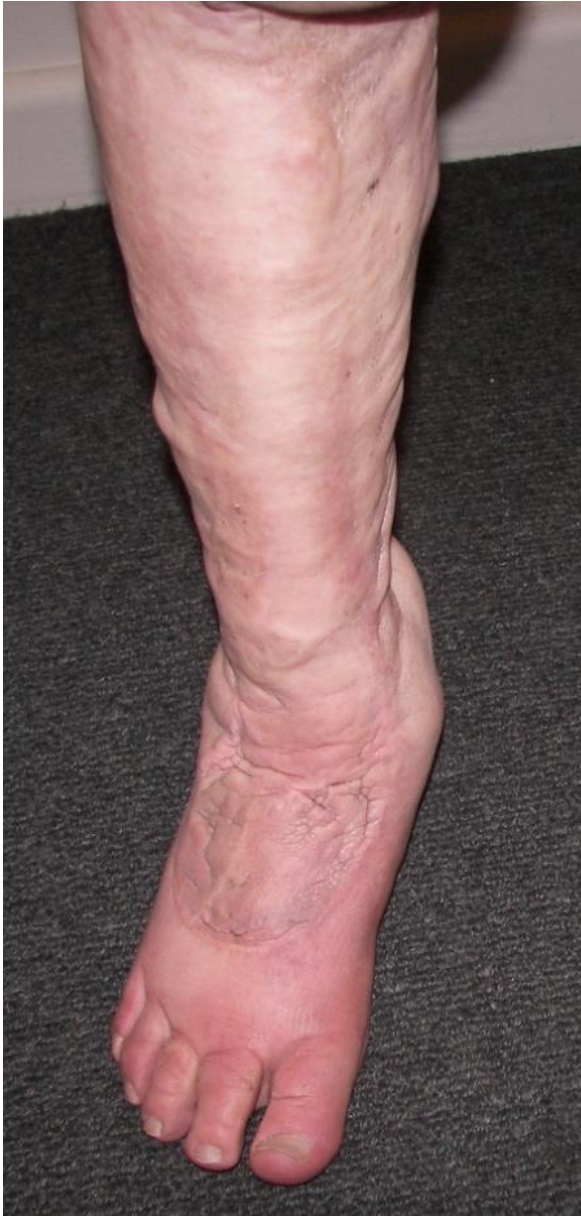Anterior view right leg



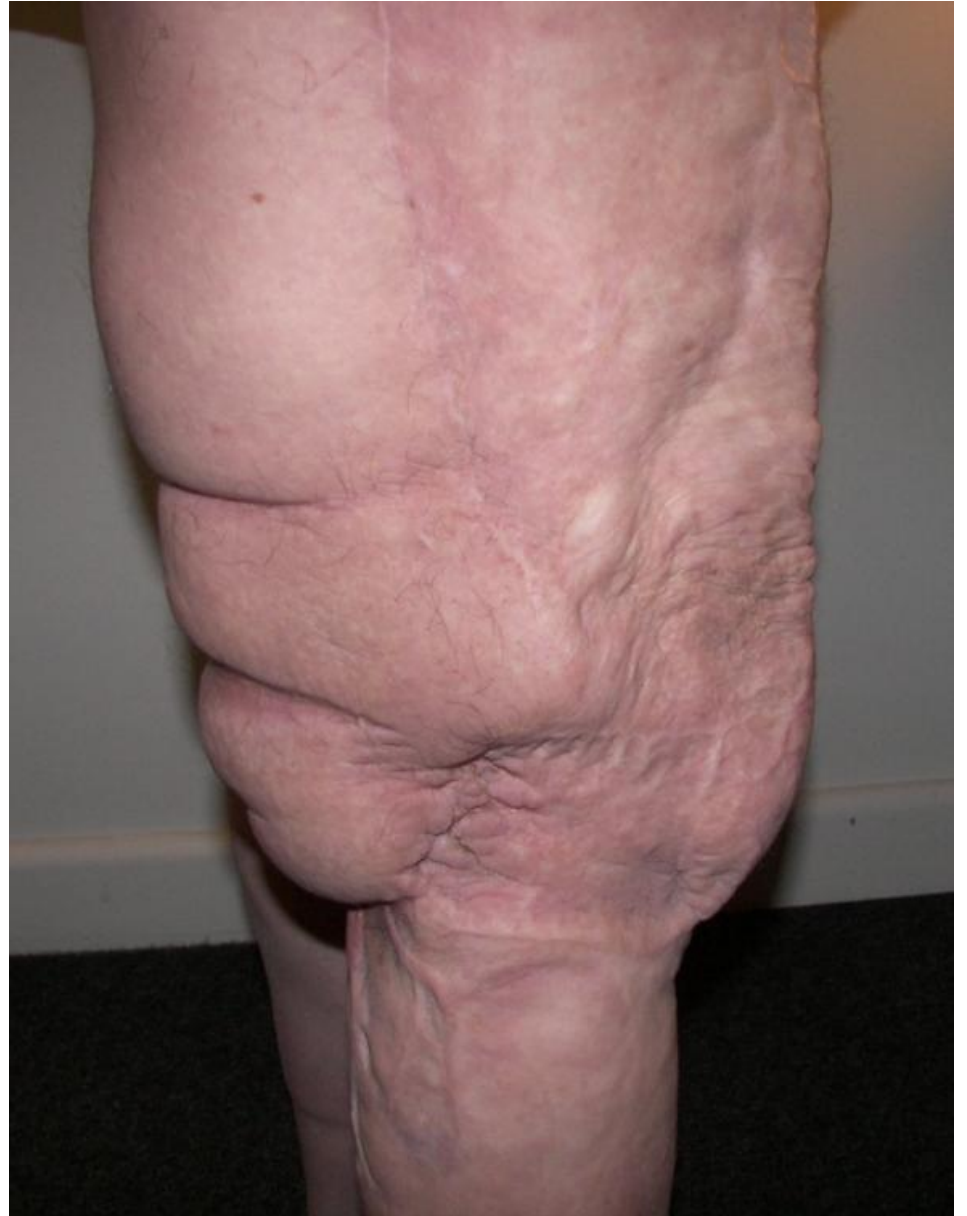Posterior view right leg



Lateral view right leg



Close up right lower limb

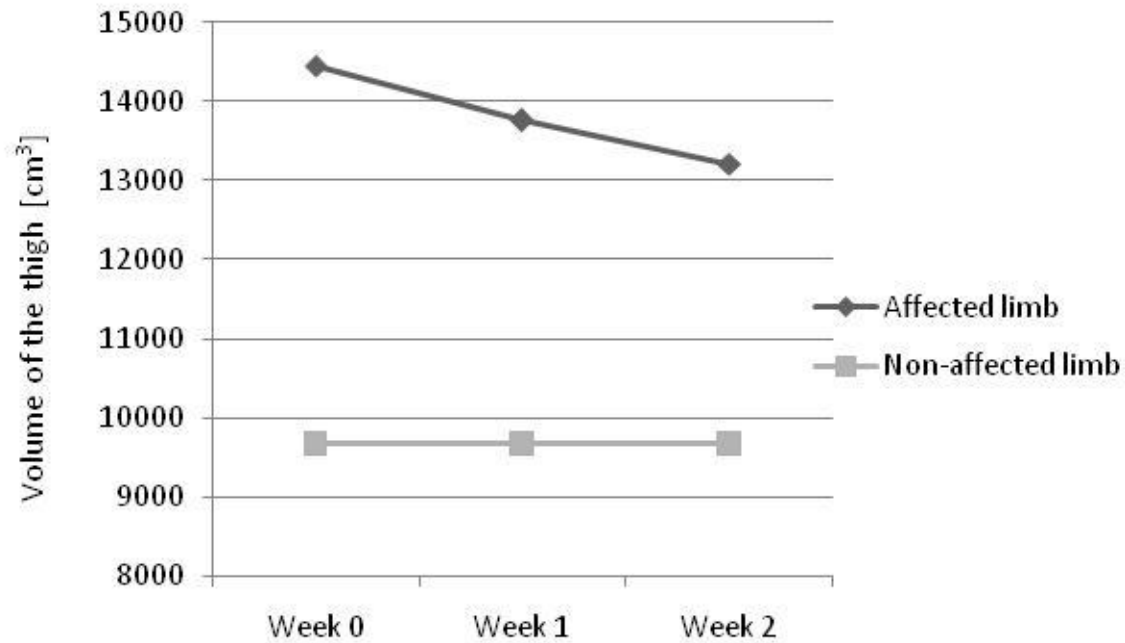


Close up right thigh and knee

Treatments

- Vodder Sequences
- Mobiderm bandaging (initial- garment made for ease of wear).
- Mobiderm for genitals
- Kinesio tape
- Skin care

Results



- Skin
- Well being
- Future
- Questions