

**DermaSaver**



REAL CASE STUDIES FROM HEALTH CARE FACILITIES LIKE YOURS

# CASE STUDY COLLECTION

## ED GOODWIN



Founder and President of HipSaver Company and inventor of DermaSaver products enjoys a Spring day with his rescued Rottweiler Sonja. Check out Sonja's favorite website [4theloveofdog.org](http://4theloveofdog.org) Sonja thanks you for supporting your local animal rescue organizations.

Dear Health Care Provider,

Everyday we hear care-givers telling us how wonderful the DermaSaver products are, using words like "miraculous", "nothing else like it" and of course "we love your products!" While we love to hear the testimonials, everyone knows a picture is worth a thousands words so we started asking for before & after photos along with case studies.

Compiled here is our first collection of DermaSaver Case Studies. These case studies were done in actual institutions just like yours by practicing nurses, therapists and care-givers like yourself. These are not professional photographs, just the work of caring people who wanted to document the incredible successful results that they were achieving with DermaSaver.

We developed DermaSaver three years ago to provide a superior preventative product for skin tears, bruising, and pressure ulcers. After listening to care-givers telling us what they wanted and what was missing from the products they had available before DermaSaver, we built in the following features:

- *Products that fit right and stay positioned on the desired area.*
- *Smooth fine fiber knit surface yarns to reduce friction and shear*
- *Soft & cushy product with the same resillance of skin (Indentation load deflection)*
- *Anti-microbial properties*
- *A surface that does not adhere to wounds*
- *Breathable fabric that does not trap moisture*
- *Totally launderable*

To our surprise, these features not only created a preventative effect but also a therapeutic effect on existing wounds. All of these features in combination allow existing wounds to heal by protecting from additional environmental assaults.

Please take the time to review these impressive case studies and their implications to improve your care plan. The prevention of a single wound improves life quality and saves real dollars for your facility. And surveyors have been impressed with the successful results achieved with DermaSaver.

As always, please call me with questions, comments or ideas.

Sincerely,

Ed Goodwin

PS. *We're always striving to provide something new and now all DermaSaver products are available with a pure silver thread lining to promote healing, reduce pain and kill bacteria on the product.*

ISABELLE COOKE



104 years old June 2008

Dear DermaSaver,

We have a resident that will be 104 years old in June. She frequently sustained numerous skin tears and bruises to both of her arms. According to her daughter, "it seems I got weekly calls to notify me about skin tears and bruises. These sleeves have been a lifesaver. My mother really enjoys them. I'm also impressed how well they fit with her clothing. They are not too tight."

Since we applied the DermaSaver Arm Tubes four months ago this resident has not sustained any skin injuries. She absolutely loves them, finding them soft and comfortable. We are now also using DermaSaver Leg tubes for additional protection, and no new skin issues have developed.

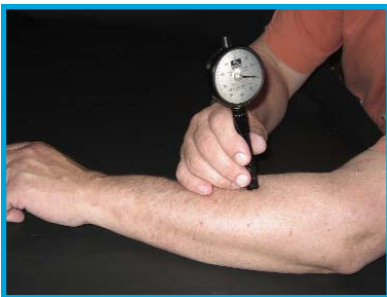When asked today, the resident replied, "The sleeves are soft, warm and comfortable. They are a good length and don't get in the way when I eat, and that's important to me."

We are also using the DermaSaver Arm Tubes on an elderly diabetic gentleman. His skin has remained intact since he has worn them.

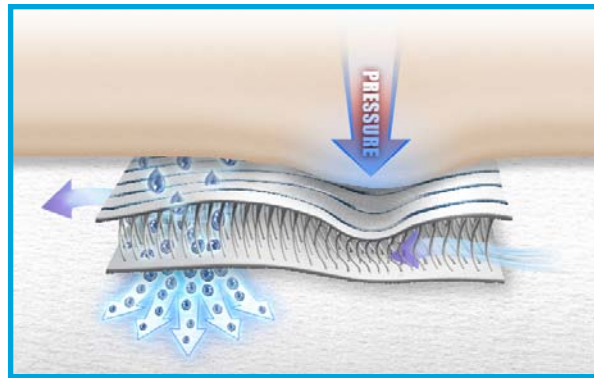
I will continue to order and promote your product. As a certified wound care consultant I am always looking to prevent a problem before it occurs, and your product serves that purpose very well.

*Gail Beausoleil, RN WCC*  
Infection Control Nurse  
Pierce Memorial Baptist Home  
Brooklyn, CT

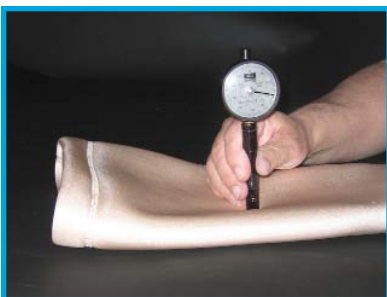**WHAT MAKES DERMASAVER WORK SO WELL? THE SCIENCE BEHIND THE RESULT.**



Durometer reading from skin (30)



The Aegis Microbe Shield inhibits microorganism growth on treated area ONLY. There is no microbial encroachment and no leaching outside the treated area.



Durometer reading from DermaSaver (30) matches skin

Microfilaments flex to reduce pressure on bony prominences such as the heel, elbow, vertebra and trochanter and to protect arms and legs from bumps and other traumas that cause skin tears and bruises. DermaSaver SkinTubes are made of two layers of MicroSpring Textile using 8000 microfilaments per square inch to act as mini pressure reducing springs. DermaSaver pressure reduction products have up to 20 thousand microfilaments per square inch.

DermaSaver MicroSpring Textile is designed to have the same "cushiness" (durometer compression resistance) as human skin. It is like adding an external layer of skin and subcutaneous fat. The surface yarns are a fine knit which reduces shear and friction.

All layers of DermaSaver products are protected by the Aegis Microbe shield which uses an EPA registered antimicrobial technology to inhibit the growth of micro-organisms on the product only. It is permanently bonded to the fibers, does not leach, or volatilize. It does not foster adaptive micro-organisms.



## CASE STUDY

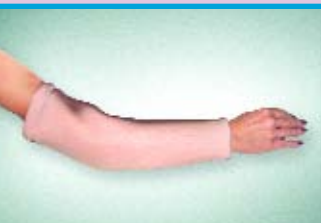RIDGEWOOD CARE CENTER, RACINE, WI

■ BY CYNDI KAVIS R.N., INSERVICE COORDINATOR

“Due to multiple meds that cause bruising and fragile skin this woman’s arms looked like those of a battle victim. Now she can even wear short sleeves! I wish I could show you the big smile on her face.”

“I am not a new consumer of these arm tubes and we have found them to be a wonderful approach to prevent the destruction caused by meds, disease processes and some unpredictable environmental issues. They have been a God Send for several of our patients. This is just the first time we actually followed up with pictures to prove what we already knew.

~ Cyndi Kavis, RN, Inservice Coordinator, Ridgewood Care Center, Racine WI

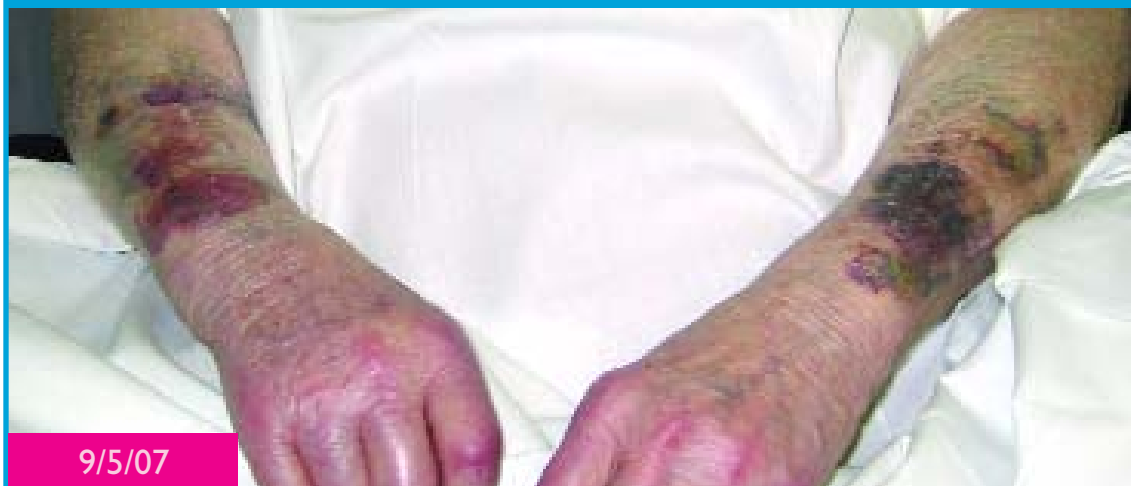

DERMASAVER ARM TUBE

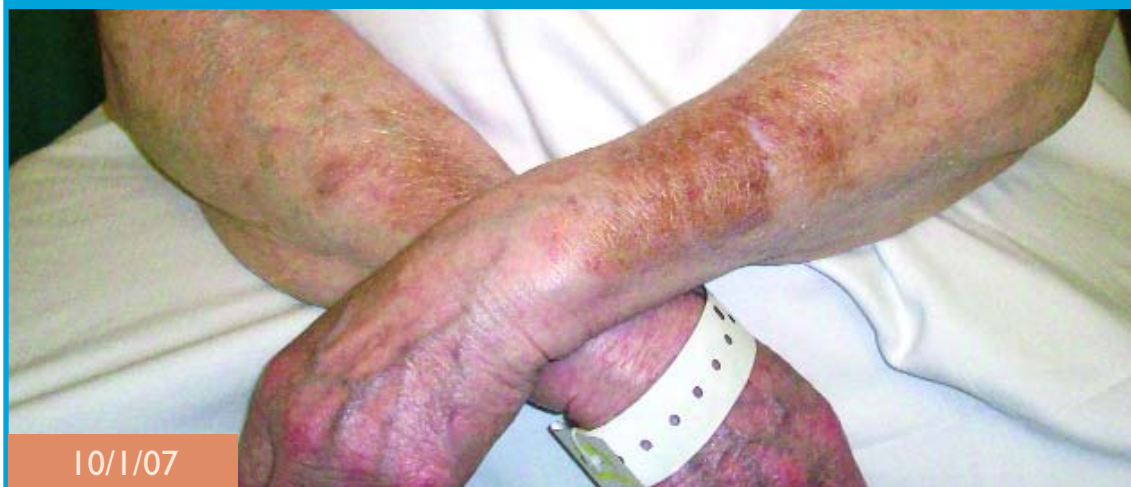Before the DermaSaver arm tubes were used, she had to wear long sleeves which were often difficult and painful to put on because of severe arthritis and did not prevent the bumps and bruises.

After 3 and a half weeks of wearing DermaSaver Arm Tubes, the improvement is outstanding.

## BEFORE USING DERMASAVER FULL ARM TUBE



## AFTER 3 1/2 WEEKS USING DERMASAVER FULL ARM TUBE



## CASE STUDY

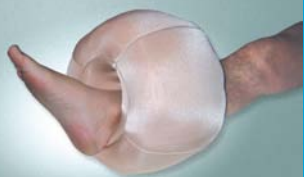FLORIDA HOSPITAL WOUND CLINIC, ORLANDO, FL

### ■ BY TINA HASTY, RN, CWSA

The patient is a 78 year old female with a history of diabetes, peripheral vascular disease, with an initial wound on 2nd and 3rd toes leading to toe amputation followed a right transmetatarsal amputation on 12/06/07. The patient has been undergoing hyperbaric oxygen treatment for a compromised flap. On 12/20/07 she developed generalized edema of right foot, and then developed a necrotic area on right heel due to keeping foot elevated and additional pressure directly on the right heel. The necrotic area on the right heel measured 2.5 x 3.2 x no depth due to eschar. No topical wound treatment was used, patient was instructed to keep heel well moisturized.

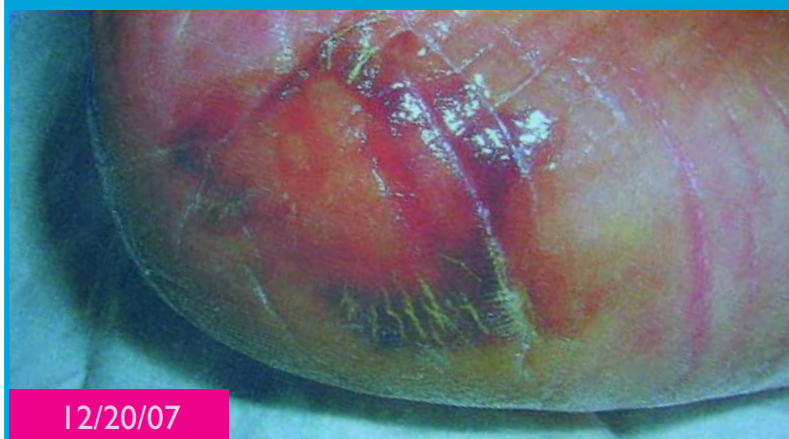The patient was given a DermaSaver Heel Elevator on 12/20/07 and was instructed to wear it at all times and keep right foot elevated at all times. On 01/04/08 the necrotic area was completely resolved. Due to the patient's history of poor vascular circulation and necrotic areas resulting in non-healing and amputation.

I believe the the DermaSaver Relevator Heel Elevator was the sole factor that prevented the patient from developing a deep non-healing pressure ulcer.

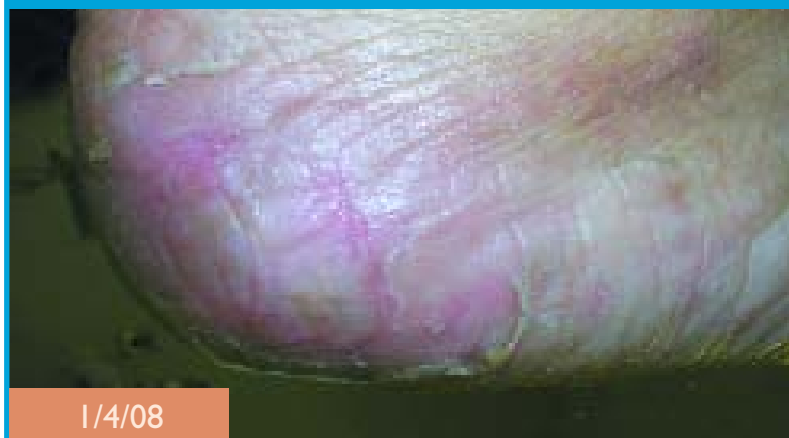

DERMASAVER RELEVATOR

### BEFORE USING DERMASAVER RELEVATOR



### AFTER 15 DAYS USING DERMASAVER RELEVATOR



## CASE STUDY

SHOLOM HOME WEST, ST. LOUIS PARK, MN

## ■ BY TIMOTHY GREEN, RN-ADON

Patient admitted to SNF on Sept 4, 2007 with wounds to knees with pronounced open area to left l/e distal to patella. Wet-to-dry dressing done B.I. D. Patient is premedicated for Tx and staff very cautious due to decreased but continued tactile defensiveness.

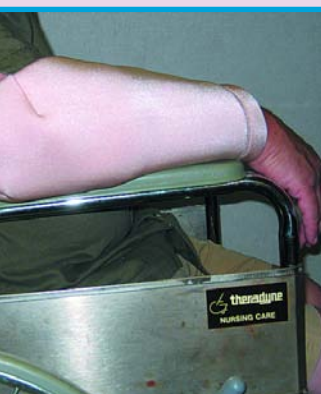**OCT 11, 2007:** Wound base 100% granulated with moderate. Wound now measures approximately 5 x 3 cm. DermaSaver Shin-Knee tubes used bilat and tolerated well. DermaSaver Arm-Bow tubes used for upper extremities also for protection and comfort per patient's request.

**Nov 1, 2007:** Patient observed to have significant improvement to lower left extremity. No signs/symptoms of infection to peri-wound tissue. Wound measures 0.9 x 1.0 cm. No pain with tube changes and this represents a dramatic improvement since admission. No other topical treatments were used. Wounds that were on the other lower extremity are all healed. Previous impediment to treatment was severe tactile defensiveness.

Patient and family members expressed delight with the DermaSaver products used on all four extremities. The products that were applied daily (DermaSaver Shin-Knee & DermaSaver Arm-Bow Tubes) were very comfortable and were easy to use and clean. When the patient was informed that because of his willingness to participate in the case-study, many others will benefit, the patient smiled beamingly and expressed thanks for the education on the products and would continue to use them once home. The other patients/residents who are using various DermaSaver products are all pleased with their ease of use and comfort.

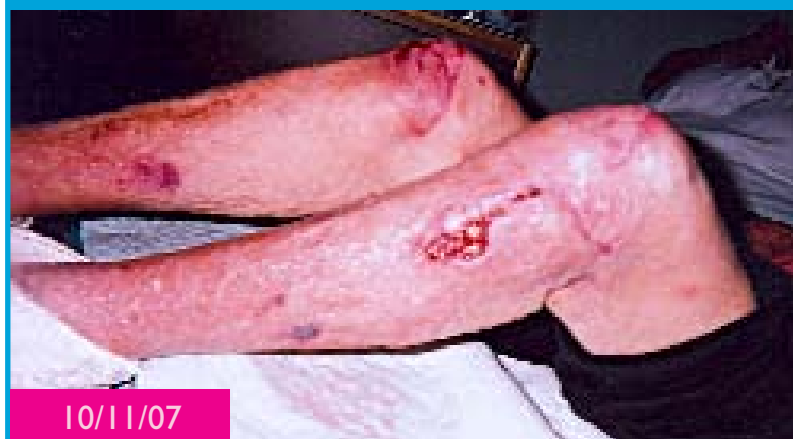

DERMASAVER SHIN-KNEE TUBE



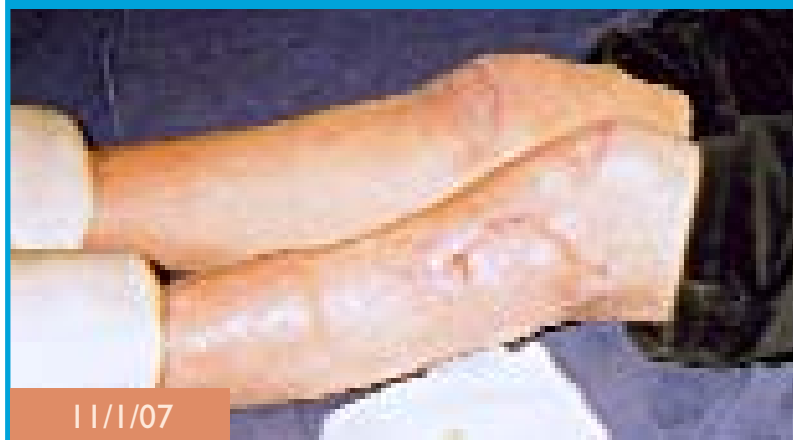DERMASAVER ARM-BOW TUBE

## BEFORE USING DERMASAVER SHIN-KNEE TUBES



10/11/07

## AFTER 21 DAYS USING DERMASAVER SHIN-KNEE TUBES



11/1/07

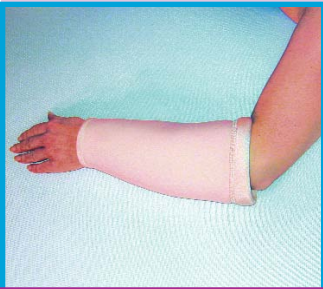# DERMASAVER CASE STUDY



CASE STUDY

AUBURN NURSING & REHAB CENTER, AUBURN, IL

■ BY MELISSA PIERSON, LPN, SKIN NURSE



DERMASAVER FOREARM TUBE



MELISSA PIERSON

“One month ago I was introduced to the DermaSaver products by my corporate nurse. I tried the Shin-Knee Tubes and Arm Tubes on two of my patients. They have not had a skin tear for three weeks with the use of your

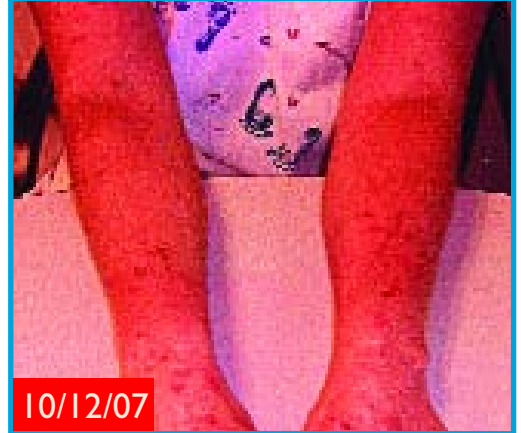products. Due to long-term use of steroids for spinal problems with severe pain, my skin is very fragile and thin. I barely brush my arm against anything and I obtain purplish bruising and skin tears.”

“After using your products, the Forearm Tubes, I have had no further bruising or skin tears. The bruising and skin tears that were present before applying your product have healed. I would recommend your product to anybody. I will still wear your products to protect my arms.”

Sincerely,

Melissa Pierson

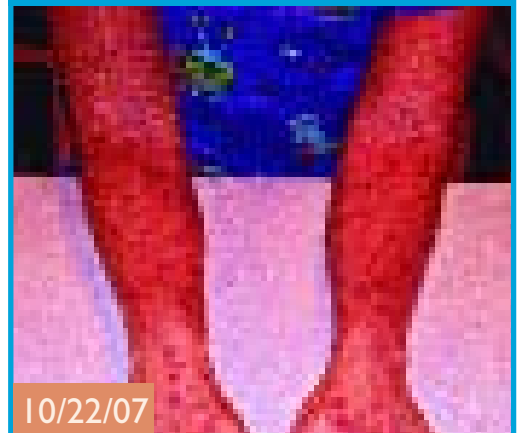
BEFOR USING DERMASAVER FOREARM TUBES



DERMASAVER FOREARM TUBES



AFTER 10 DAYS USING DERMASAVER FOREARM TUBES



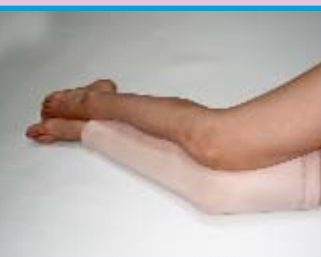## CASE STUDY

PEACHTREE CENTRE, GAFFNEY, SC

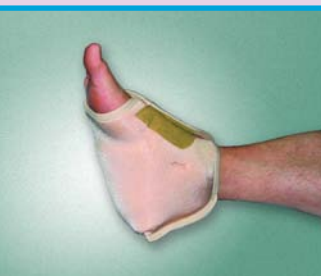■ By **AMANDA McABEE, RN**

Resident has a very large skin tear on her right leg (approx. 10cm x 10cm and just this week received two shin-tears to her left leg (one approx. 1 inch and the other approx 6cm)

**Nov 26** - The resident's skin tears have already scabbed over!

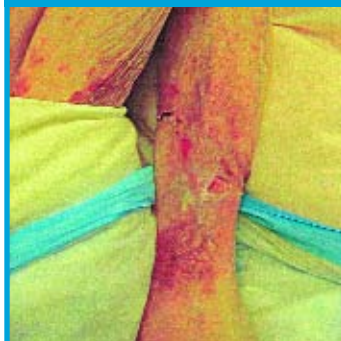

DERMASAVER FULL LEG TUBE



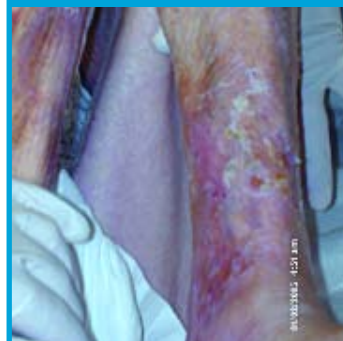DERMASAVER STAY-PUT HEEL PROTECTOR

BEFORE USING DERMASAVER FULL LEG TUBES



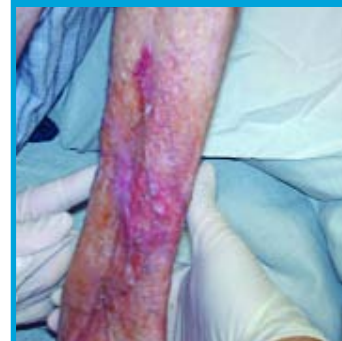11/21/07 LEFT SHIN

AFTER USING DERMASAVER FULL LEG TUBES



11/28/07 LEFT SHIN

AFTER USING DERMASAVER FULL LEG TUBES



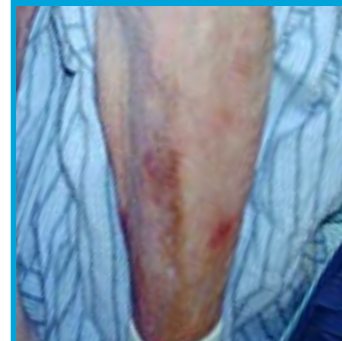12/12/07 LEFT SHIN

BEFORE USING DERMASAVER FULL LEG TUBES



11/21/07 RIGHT SHIN

AFTER USING DERMASAVER FULL LEG TUBES



12/12/07 RIGHT SHIN

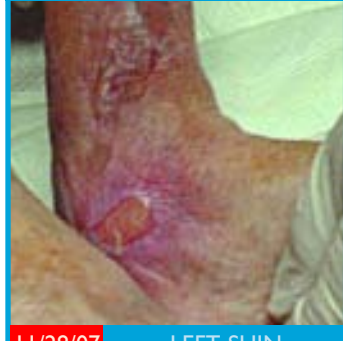

**PRIMARY CARE STAFF:**

PAT PUTNAM, LPN, INFECTION CONTROL NURSE; ANGIE ACREY, LPN, FLOOR NURSE; APRIL CRAWFORD, LPN, FLOOR NURSE

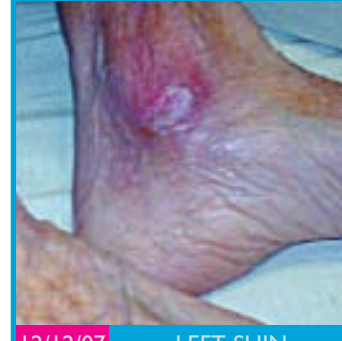**Nov 28** - Resident already had a blister on her ankle, but with her thin skin condition, it opened up. So we started using the Stay-Put Heel Protector.

BEFORE USING DERMASAVER STAY-PUT HEEL PROTECTOR



11/28/07 LEFT SHIN

BEFORE USING DERMASAVER STAY-PUT HEEL PROTECTOR



12/12/07 LEFT SHIN

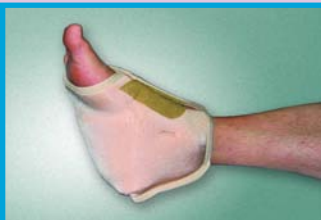

# DERMASAVER CASE STUDY



## CASE STUDY

REGENCY AT THE PARK, COLLEGE PLACE, WA



DERMASAVER STAY-PUT  
HEEL PROTECTOR

**9-29-07:** This resident's feet have external rotation when at rest (in bed or in recliner) and he has had two stage 2 pressure ulcers on the outer malleolus's of both ankles since admission. We have been trying duoderm dressing and booties at HS (cloth covered cotton boots) for approximately 3 months. When the wounds would resolve to a stage 1, the duoderm would be removed, and the booties were continued, but they did not stay in place and constantly had to be re-applied several times throughout the night (interfering with his sleep), and resulting in the return of the the stage 2 ulcers. We would then repeat the process; this has continued for the last 3 months. We decided to try the DermaSaver Stay-Put Heel Protectors. With this product alone, we had the stage 2's resolved to stage 1's within one week. Plus they remained in place throughout the night. (The resident was very relieved to be able to sleep uninterrupted!) He was able to ambulate with them on, which allowed him to remain independent with his toileting needs.

**10-11-07:** The resident is still presenting with the stage 1 pressure ulcers, but he continues to show signs of resolving without the use of any other dressing. He is wearing the DermaSaver Stay-Put Heel Protectors 24/7, and is still able to ambulate safely.

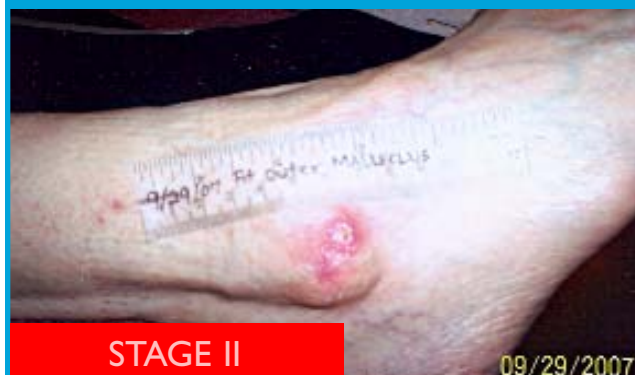**10-17-07:** After three weeks of using the DermaSaver Stay-Put Heel Protectors, the wounds on his malleolus's are now resolved. This outcome would not have been achieved without this product, as our previous failed attempts with other products have proven. He has some scar tissue over both ankles that will always be a vulnerable area for him, and so the DermaSaver Stay-Put Heel Protectors will continue to be utilized.

We were very pleased with the results of this study, and we plan to use DermaSaver products on a regular basis in our facility.

Thank you for this product!

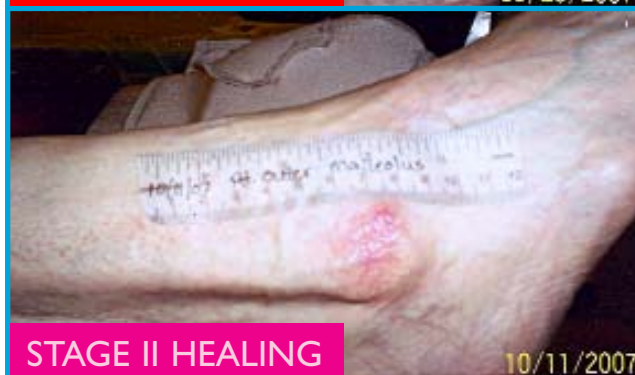*Regency At The Park  
Nursing Staff*

### CASE STUDY USING DERMASAVER STAY-PUT HEEL PROTECTOR



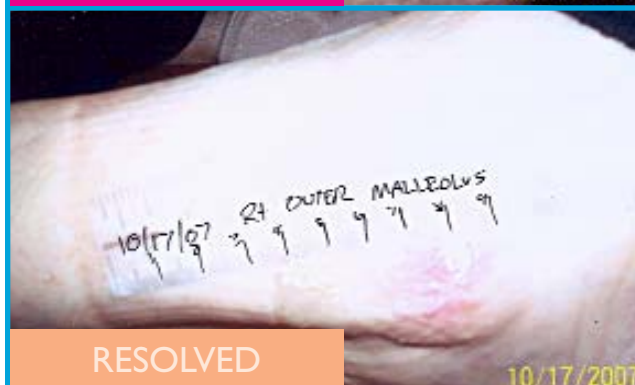STAGE II

09/29/2007



STAGE II HEALING

10/11/2007



RESOLVED

10/17/2007

## CASE STUDY

## WESBURY UNITED METHODIST COMMUNITY

■ **By AUTUMN SEELY FERRINGER, LPN, WCC**

### BACKGROUND HISTORY



**PRIMARY CARE STAFF:**  
 MIRANDA SLEE, CNA; SUSAN JOHNSON, LPN; MELINDA CRAIG, LPN  
 FRONT: TAMMY SWAVEY, CNA

A 93-year-old female admitted to the facility on May 7, 2007 with the following pertinent diagnoses; CVA, L hemi paresis, Aphasia, COPD, Cor Pulmonale, SVT, A fib, Tachy – Brady Syndrome, Pacemaker, HTN, Multiple Myeloma, Chronic Kidney Disease, Muscle Weakness, Ambulatory Dysfunction, Hip Replacement Status post, History of Steroid use and numerous additional diagnoses.

She takes the following medications; Nasonex spray, calcium carbonate, furosemide, aspirin, Protonix, metoprolol, docusate sodium, multi vitamin, paroxetine hcl, prednisone, theophylline, Xopenex,

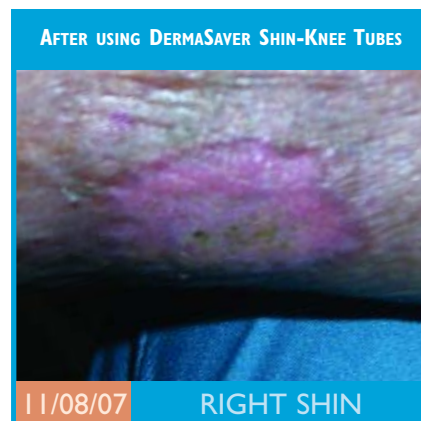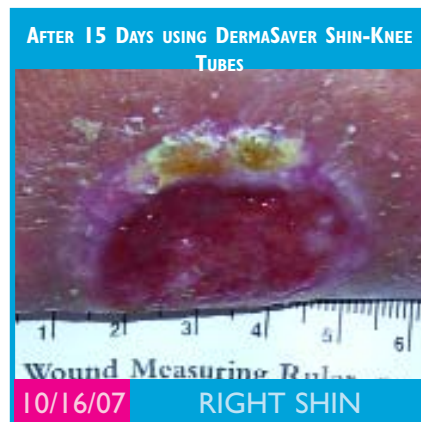
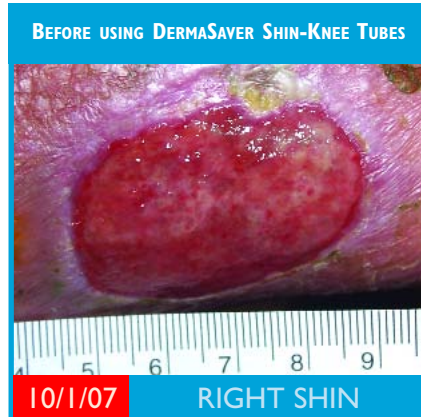Dulcolax, milk of magnesia, acetaminophen and Mylanta.

Due to her age, medical history and resulting medications, especially long standing steroid therapy, her skin is thin and fragile. She has hemosiderin staining to all 4 of her extremities from repeated trauma to her skin with minimal contact, as well as frequent skin tears. At times she will develop a bullae or hematoma that will ulcerate and require debridement. Healing is slowed due to the same reasons her skin is fragile. Prevention is key in the plan of care for this resident. Her personal goal on admission to our facility was to “make my legs like new”. Upon admission we were challenged with skin tears to her lower extremities that were large and required debridement to remove eschar so we could work towards healing. While we succeeded in healing those areas we failed to keep her free of repeated trauma since the slightest bump results in a complicated skin injury.

Once we saw the DermaSaver leg protectors we wanted to try them in order for her to reach her goal. When wearing the DermaSaver product, her legs were protected and provided an opportunity to heal without any recurrent injury to them. Her legs also looked smooth and toned. During the time she has worn the DermaSaver Shin-Knee tubes the only injury she had to her one lower extremity was on her lateral thigh beyond the area covered by the DermaSaver product.



**DERMASAVER SHIN-KNEE TUBE**





## CASE STUDY

WESBURY UNITED METHODIST COMMUNITY

■ By **AUTUMN SEELY FERRINGER, LPN, WCC**

### OCTOBER 1, 2007

*Started Derasaver Shin-Knee Tube*

- **R shin** measured 4 cm X 3.2 cm X 0.1 cm
- **L shin** 1.3 cm X 1.1 cm X 0.1 cm

### OCTOBER 4, 2007

- **R shin** 3.7 cm X 3.2 cm X 0.1 cm
- **L shin** 0.5 cm X 0.8 cm X 0.1 cm

### OCTOBER 11, 2007

- **R shin** 3 cm X 2.5 cm X 0.1 cm
- **L shin** 0.5 cm X 0.7 cm X 0.1 cm

### OCTOBER 16, 2007

- **R shin** 2.3 cm X 2.5 cm X 0.1 cm
- **L shin** – healed

### OCTOBER 22, 2007

- **R shin** 2.3 cm X 2.5 cm X 0.1 cm

### NOVEMBER 3, 2007

- **R shin** 1.5 cm X 1 cm X 0.1 cm

### November 8, 2007

- **R shin** – healed

### OVERVIEW OF LEG WOUNDS

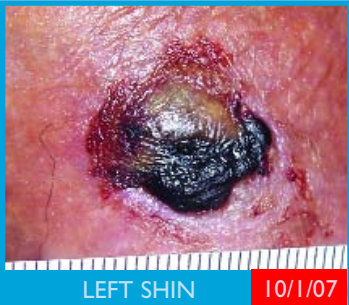The **R shin** injury started on 8/27/07 as a hematoma, then localized into a purple fluid filled bullae, measuring 5.3 cm X 5 cm and was raised 0.3 cm. The bullae unroofed 9/10/07 revealing a beefy red wound base. On 9/17/07 the wound base had developed yellow slough and required enzymatic debridement. The measurement was 4 cm X 4 cm X 0.1 cm. On 9/23/07 the wound was debrided, returning to the red wound base and measuring 4 cm X 3 cm X 0.1 cm.

The **L shin** wound started 9/22/07 as an unroofed bulla and initially measured 1.5 cm X 1.4 cm X 0.1 cm.

### COMPARISON OF WOUND MEASUREMENTS TOWARDS HEALING

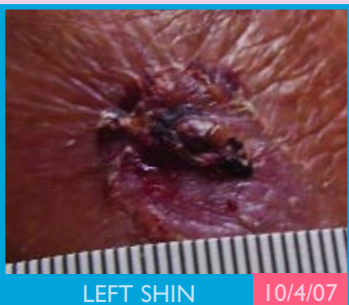DATE	R SHIN	L SHIN
8/22/07	5.3 X 5 X 0.3 (raised)	
9/17/07	4 x 4 x 0.1	
9/23/07	4 x 3 x 0.1	1.5 x 1.4 x 0.1
10/01/07*	4 x 3.2 x 0.1	1.3 x 1.1 x 0.1
10/4/07	3.7 x 3.2 x 0.1	0.5 x 0.8 x 0.1
10/11/07	3 x 2.5 x 0.1	0.5 x 0.7 x 0.1
10/16/07	2.3 x 2.5 x 0.1	<b>HEALED</b>
10/22/07	2.3 x 2.5 x 0.1	
11/3/07	1.5 x 1 x 0.1	
11/8/07	<b>HEALED</b>	

\**Dermasaver product initiated.*



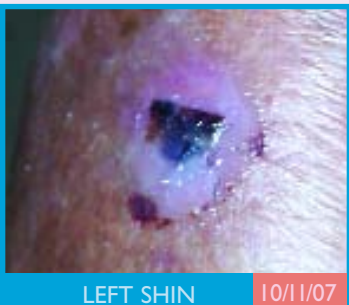LEFT SHIN

10/1/07



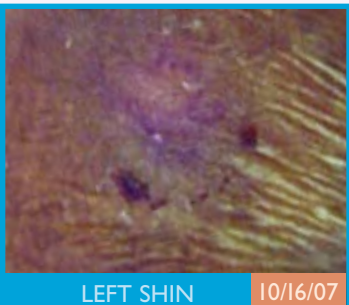
LEFT SHIN

10/4/07



LEFT SHIN

10/11/07



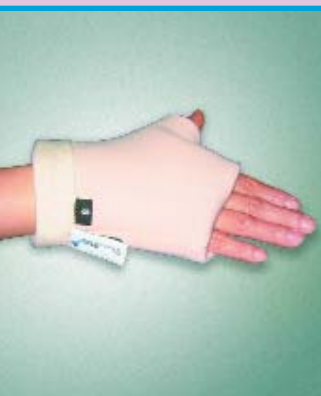LEFT SHIN

10/16/07

## CASE STUDY

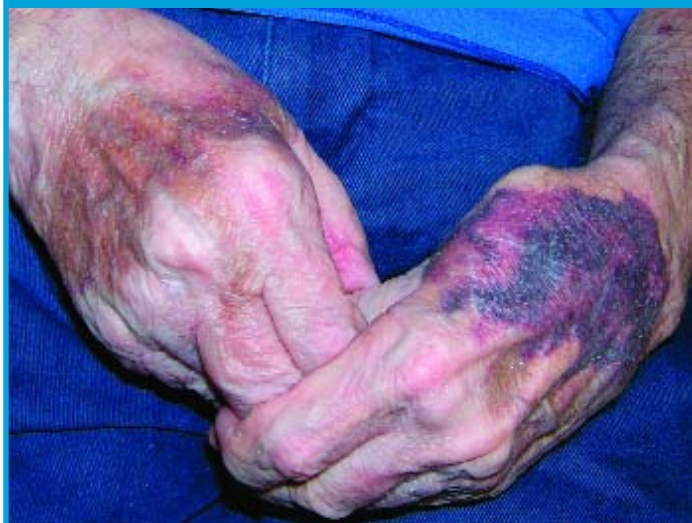Brandywine Nursing and Rehab Center, Wilmington, DE

■ BY DEBRA LYNCH, DIRECTOR OF NURSING



DERMASAVER KNUCKLE PROTECTOR

## BEFORE USING DERMASAVER KNUCKLE PROTECTOR

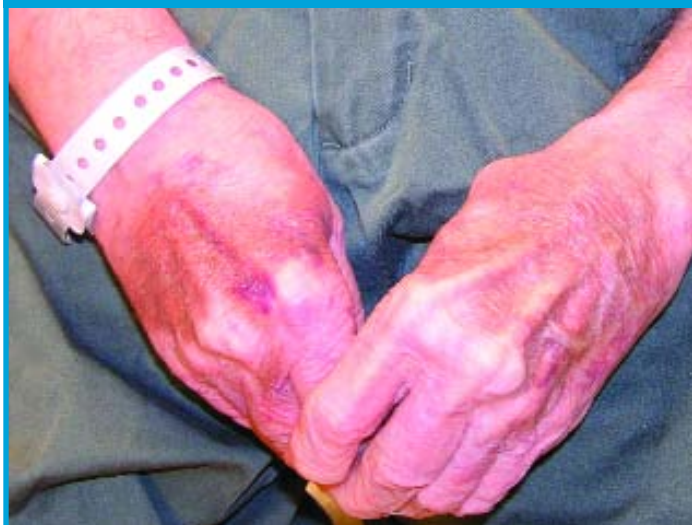

1/11/08

The resident is a 78 year old male with multiple bruises of both hands. The resident has a diagnosis of Congestive heart failure, Parkinson's disease, Arthritis, depression and hypertension. The resident self ambulates in his wheelchair but has difficulty navigating door ways resulting in bruising of the hands.

DermaSaver Knuckle Protector were initiated on December 25, 2007. Areas improved slowly due to fragile skin and underlying tissues. The resident re-injured his hands on January 11, 2008 prior to the gloves being applied for the day. However, by February 4, 2008 there was significant improvement. The DermaSaver Knuckle Protector are easy to apply and provide improved protection for his hands.

## CURRENT STATUS



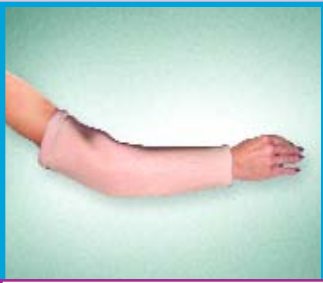2/4/08



## CASE STUDY

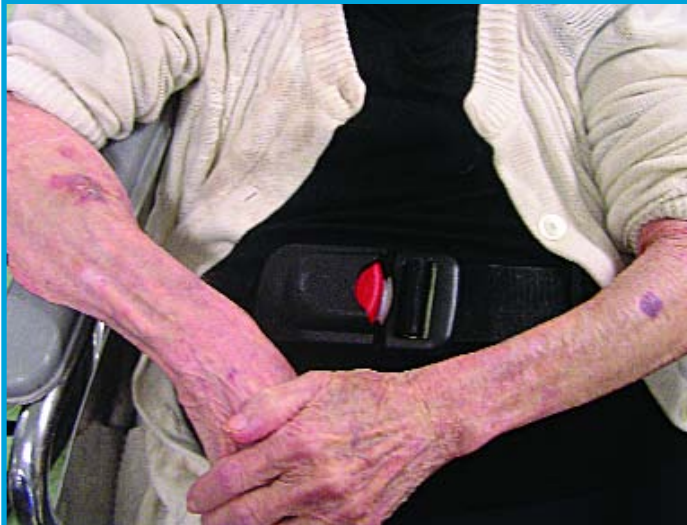Brandywine Nursing and Rehab Center

■ BY DEBRA LYNCH, DIRECTOR OF NURSING



DERMASAVER ARM TUBES

### BEFORE USING DERMASAVER ARM TUBES

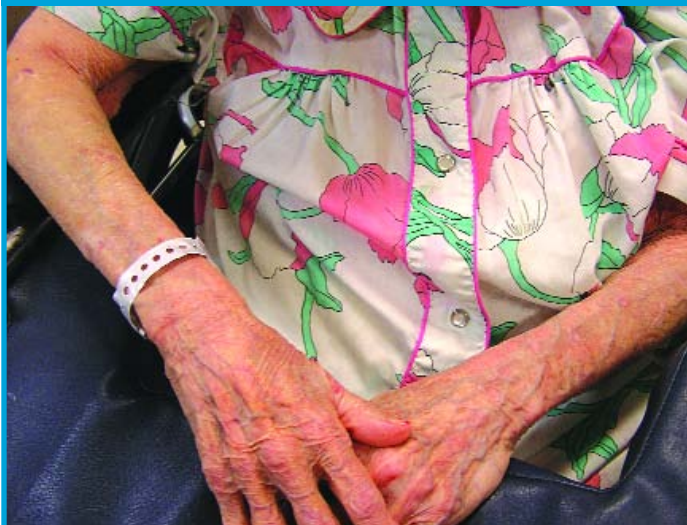

12/25/07

The resident is a 91 year old female with multiple bruises and skin tears to bilateral forearms. The resident has a diagnosis of ambulatory dysfunction, depression, dementia, Alzheimer's disease and fractured pelvis. There are multiple behavioral and safety awareness issues resulting in bruising and skin tears.

On December 25, 2007, DermaSaver Arm Tubes were initiated bilaterally. Areas improved slowly as the skin tube provided protection from injury due to behavioral and safety awareness issues. Another brand of sleeves had been utilized prior to the DermaSaver Arm tubes but without significant improvement or protection from injury.

### AFTER USING DERMASAVER ARM TUBES

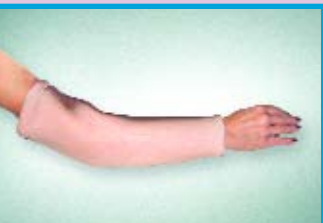

3/4/08

## CASE STUDY

EDWIN MORGAN CENTER, LAURENBURG, NC

■ BY KIM BYRNE, PTA



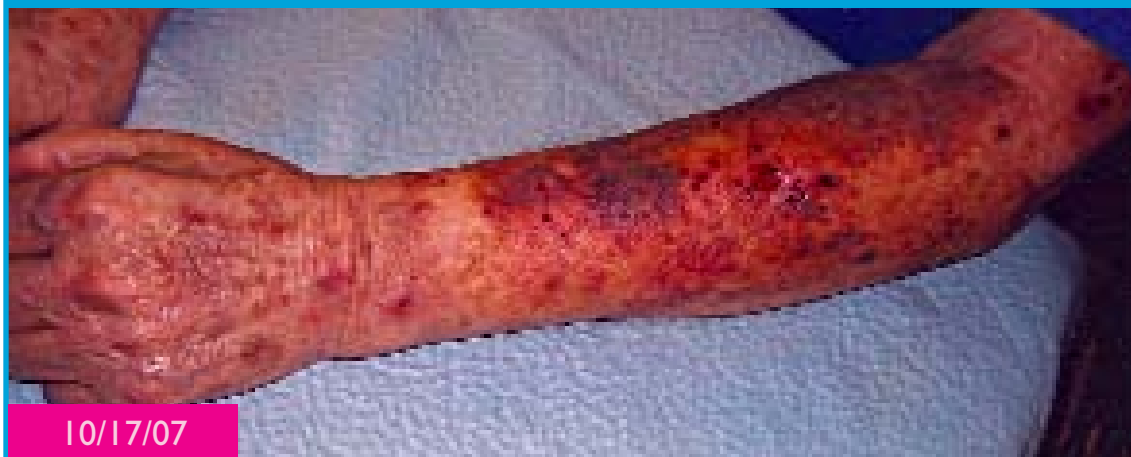DERMASAVER ARM TUBE

“The resident is a 70 year old male with multiple abrasions/bruising to bilateral forearms due to uncontrolled movements of UE and skin conditions. Diagnosis of Dementia, Psoriasis, Solar Elastosis, Xerosis Cutis, Dermatitis and Pruritis. Resident was actively scratching at skin resulting in broken skin with active bleeding and bruising. Trials of skin ointment to alleviate itching were attempted. However, he continued to scratch with skin integrity compromise.”

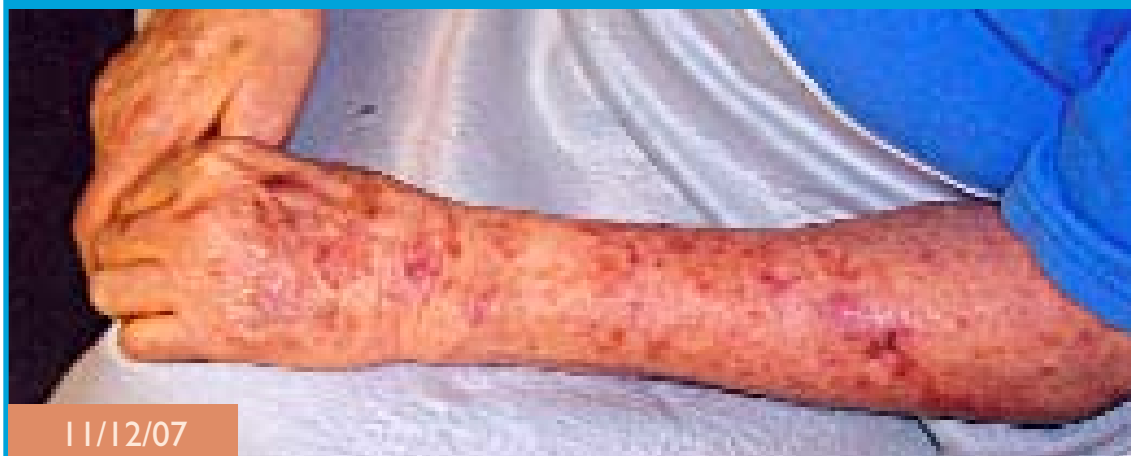**OCT 26 2007:** “Small DermaSaver Arm Tubes were issued. Areas improved with resident able to scratch at outside of sleeve without causing injury to skin. Sleeves used in conjunction with Topicort and Eucerin cream. Wounds healed within two weeks with no open areas or bruising to areas protected by DermaSaver Arm Tubes decreasing risk/portal site for infection. There are red blotchy areas which is due to the skin condition of psoriasis. However, you will notice there are no scabbed or bruised areas.”

“The DermaSaver products are soft, easy to apply, comfortable for the residents and actually remain in the correct alignments unlike all other products that we have tried.”

## BEFORE USING DERMASAVER FULL ARM TUBE



## AFTER 26 DAYS USING DERMASAVER FULL ARM TUBE

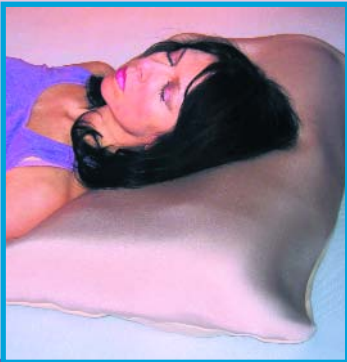
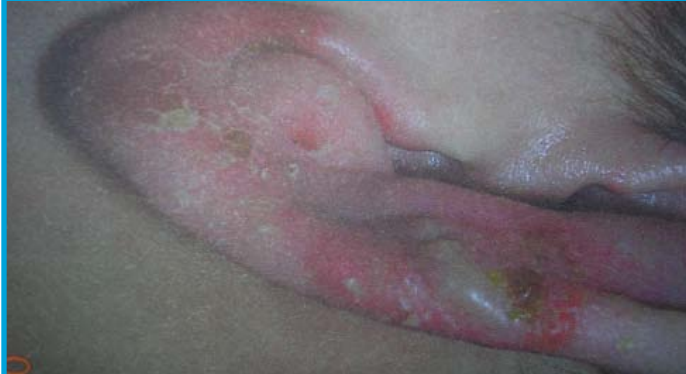


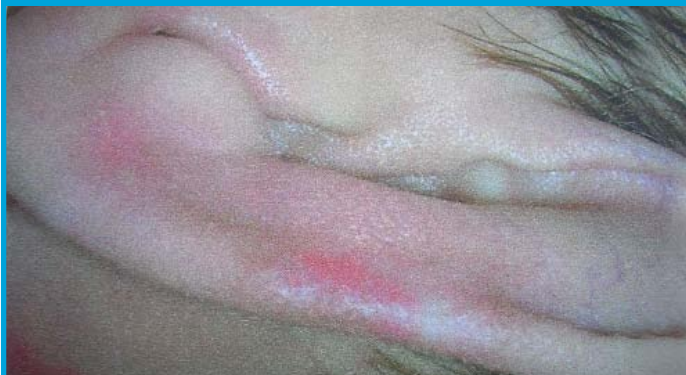## CASE STUDY

FLORIDA HOSPITAL WOUND CLINIC, ORLANDO, FL

■ BY TINA HASTY, RN, CWSA

DERMASAVER PRESSURE  
REDUCTION PILLOW CASEBEFORE USING DERMASAVER PRESSURE  
REDUCTION PILLOW CASE

4/1/08

AFTER 13 DAYS USING DERMASAVER PRESSURE  
REDUCTION PILLOW CASE

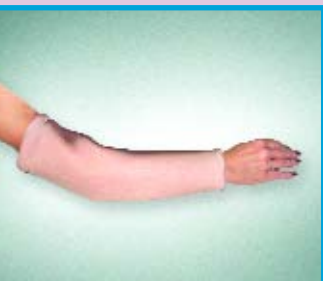4/14/08

A 24 year old male with muscular dystrophy presented to the clinic on April 1, 2008 with a pressure wound on his left ear. The caregiver reports patient is laid on the left side due to contractures and respiratory difficulty while on his right side. The wound measurement on the left ear was 1.5cm x 0.9cm x 0.1cm. The following wound care orders were given, to cleanse ear daily with normal saline and apply thin layer of zinc oxide and to use DermaSaver Pressure Reduction Pillow Case while in bed. The patient returned on April 14, 2008 with no measurable wound and intact skin on his left ear. The skin on his left ear was pink with no drainage or reddened areas present. The care giver states he had used the DermaSaver Pressure Reduction Pillow Case for ten days and saw improvement almost immediately.

## CASE STUDY

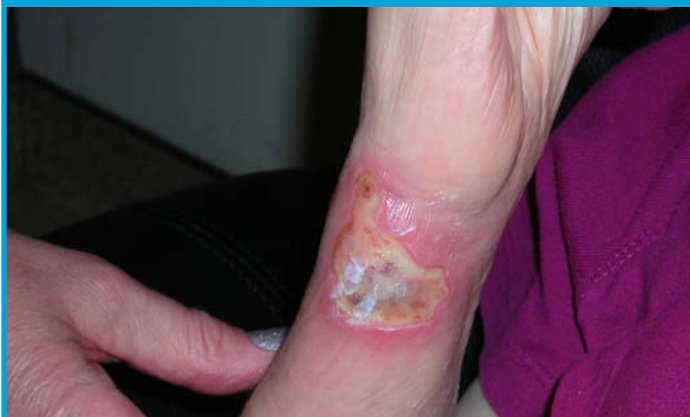WRENTHAM DEVELOPMENTAL CENTER, WRENTHAM, MA

■ BY MAUREEN ETHIER, RN, NURSING SUPERVISOR, UNIT 2



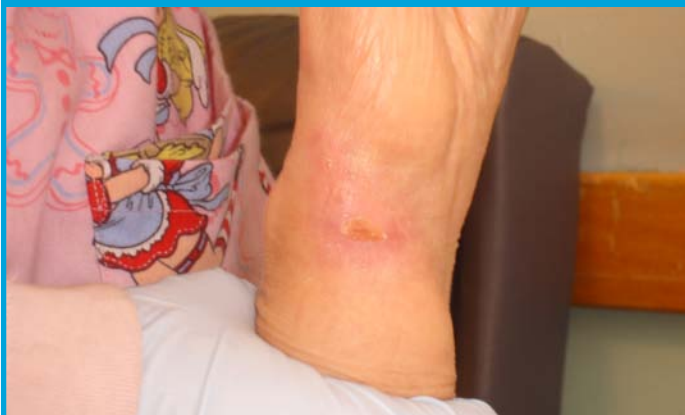DERMASAVER ARM TUBES

## BEFORE USING DERMASAVER ARM TUBES



2/15/08

## AFTER 7 WEEKS USING DERMASAVER ARM TUBES



4/8/08

The resident is a 52 year old female with the diagnosis of Mental Retardation, Seizure Disorder, Cerebral Palsy and Osteoporosis, who sustained a friction injury to her right wrist resulting in cellulitis. She also has degenerative disease causing cervical stenosis with atrophy and loss of function in both forearms.

On 2/15/08 DermaSaver Arm Tubes were issued in conjunction with a topical treatment. Within a short time improvement was noted and the wound healed. Resident now enjoys wearing DermaSaver tubes on both arms daily. The products are comfortable and washable, which makes them very appropriate for our population.

We were extremely pleased with the results of this study and plan to continue to use DermaSaver products on a regular basis in our facility.

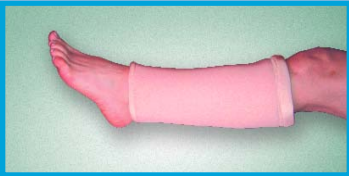



## CASE STUDY

ARCADIA NURSING & REHAB CENTER, LITTLE EGG HARBOR, NJ

■ By **MARIA FINER, RN, BC, BSN, STAFF DEVELOPMENT/WOUND SPECIALIST**



**DERMASAVER SHIN TUBES**



### WOUND TEAM

BACK: ANGELA SANTARSIERO, ACTIVITIES DIRECTOR;  
LINDA MAKULOWICH, RN, UNIT MGR;  
FRONT: MARIA FINER, RN, BC, BSN

Resident was admitted to this facility on 1-23-08 with numerous bruises and areas of deep tissue injury (DTI) to bilateral lower extremities. Resident was very pleased with the DermaSaver products and stated, "I love these, they are soft and they are mine." The resident's son also stated they feel very soft and 'cushiony'."

Skin tears and bruising decreasing in size and resolving noted March 6, March 11, March 27.

April 2, 2008 Areas to right and left legs resolved. Areas greatly improved. Resident continues to enjoy wearing the DermaSavers and stated, "I love them,"

Angela Santarsiero, our Activities Director who took the photos, is not a medical person but she stated, "I have never seen something work so great. Those are not the same legs I took pictures of last month!" Of course they were!

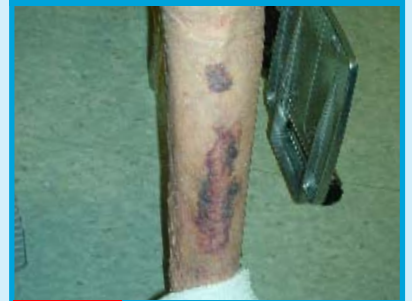The improvement has been outstanding. I have been an RN since 1991 and in my practice have not seen a non-invasive product work so well.

The product is extremely easy to use! We will definitely continue to use DermaSavers in this

facility. In addition the staff at DermaSaver were so friendly and kind. It was our pleasure to work in conjunction with DermaSavers.

~ Maria Finer, RN, BC, BSN

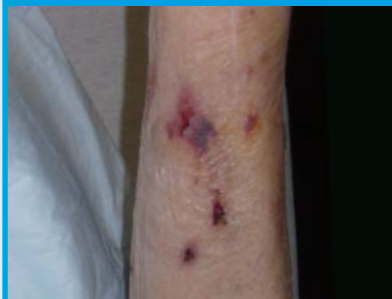BEFORE USING DERMASAVER SHIN TUBES



2/19/08

LEFT SHIN

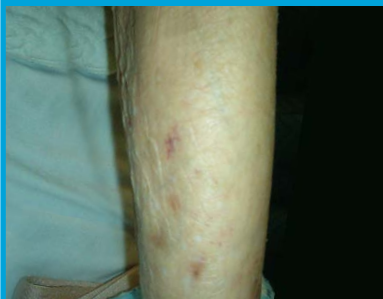BEFORE USING DERMASAVER SHIN TUBES



2/19/08

RIGHT CALF

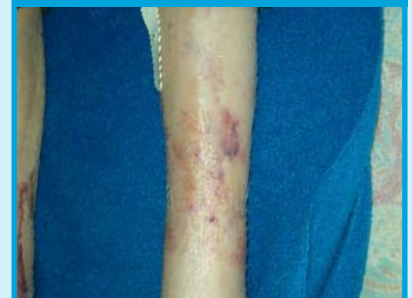AFTER 44 DAYS USING DERMASAVER SHIN TUBES



4/3/08

RIGHT CALF

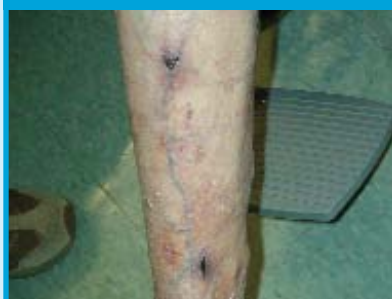AFTER 34 DAYS USING DERMASAVER SHIN TUBES



3/24/08

LEFT SHIN

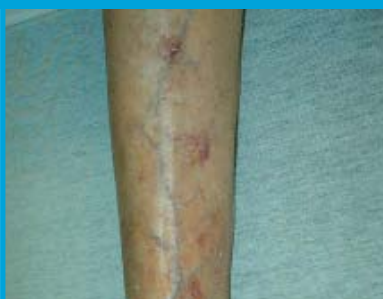BEFORE USING DERMASAVER SHIN TUBES



2/19/08

RIGHT SHIN

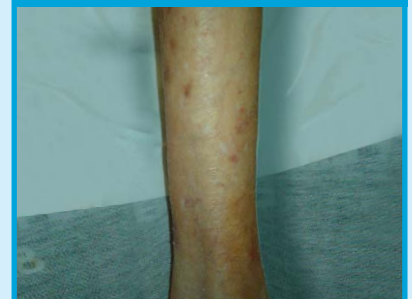AFTER 44 DAYS USING DERMASAVER SHIN TUBES



4/3/08

RIGHT SHIN

AFTER 44 DAYS USING DERMASAVER SHIN TUBES



4/3/08

LEFT SHIN

## CASE STUDY

EVERGREEN HEALTH CARE, STAFFORD SPRINGS, CT

## ■ By MICHELLE FRITZE, RN/WCC

Resident is a 72 year old white male, S/P right TKA with spacer implant on 2/18/08. Surgical wound became infected with MRSA and was admitted on 2/22/08 for I/V antibiotic therapy x 4weeks. Past medical history includes IDDM, HTN, and CAD.

Resident was weight bearing as tolerated upon admission. His right leg had moderate external rotation. Resident felt increase knee comfort when the lower leg was in this position. A rolled blanket was suggested by physical therapy and was used to support the right leg. A foam boot was being used for an area on the Achilles area. A low air loss mattress was already in place, due to other skin issues. Repositioning was done every two hours, but resident was not compliant with this. In spite of frequent monitoring of the leg, the resident developed a pressure area on 3/5/08 on the right outer malleolus, measuring 1.8 x 2.2cm, with redness surrounding the wound, measuring 4x5cm.

Most of the wound was covered with necrosis and thick leathery slough. Treatment started immediately, using Accuzyme ointment. The surrounding skin was very red and the wound was very painful for the resident.

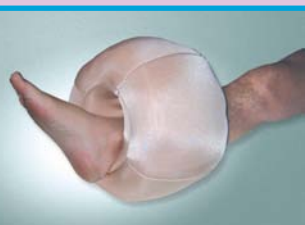**3-14-08:** We decided to try the DermaSaver Relevator Heel Elevator. By the next morning, the resident reported he slept well and less pain in the area of the wound.

The wound continued to slowly improve. By 3/28, the redness surrounding the wound was significantly decreased and the pain reported by the resident was gone.

**4-4-08:** We continued treating the wound with Accuzyme until 4/4/08, when 90% of the wound bed was clean and had granulation tissue. We changed our treatment to Panafil QD. We continued using the DermaSaver Relevator Heel Elevator. The resident, family, and MD were very pleased with the progress.

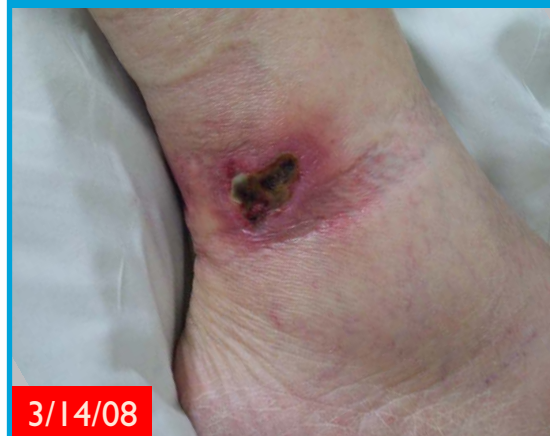The wound now measured 1.2 x 1.8cm, in only 3 weeks! The surrounding tissue and skin remained less reddened and the resident had no complaints of pain. The resident was very pleased with the DermaSaver Relevator Heel Elevator.

**4-14-08:** The resident was discharged home, with daily visiting nurses to continue with wound care. The area continued to progress well and measured 1x1.5cm. The wound bed appeared slightly discolored, but due to the green color of the Panafil ointment. The resident did not complain of any discomfort and praised the DermaSaver Relevator. He was even more excited when he was able to take the product home with him! Thank you DermaSaver!

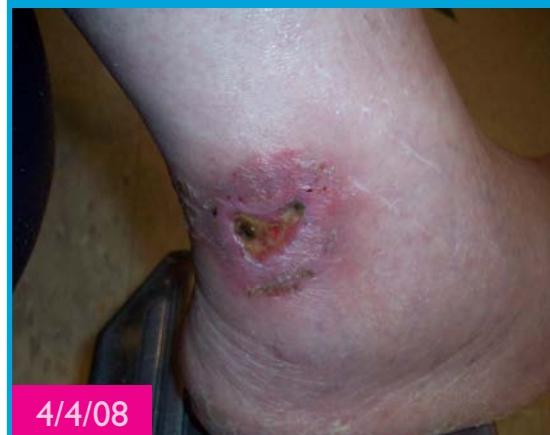

DERMASAVER RELEVATOR

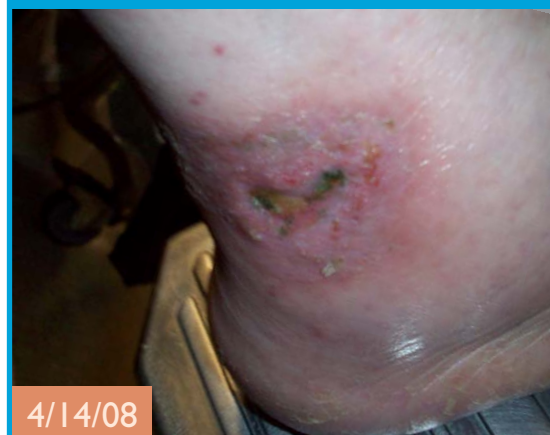## BEFORE USING DERMASAVER RELEVATOR



## AFTER 3 WEEKS USING DERMASAVER RELEVATOR



## AFTER 30 DAYS USING DERMASAVER RELEVATOR



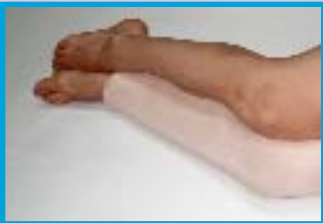# DERMASAVER CASE STUDY



CASE STUDY

CORE NURSING & REHAB, BEDFORD, IN

■ BY ALISON SWITZER, RN

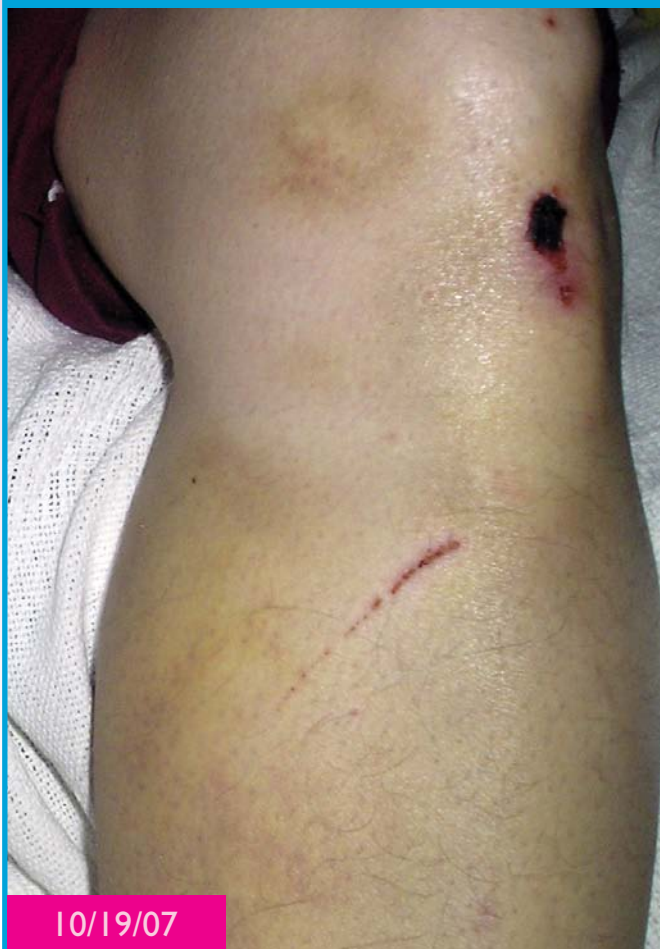

DERMASAVER FULL LEG TUBE

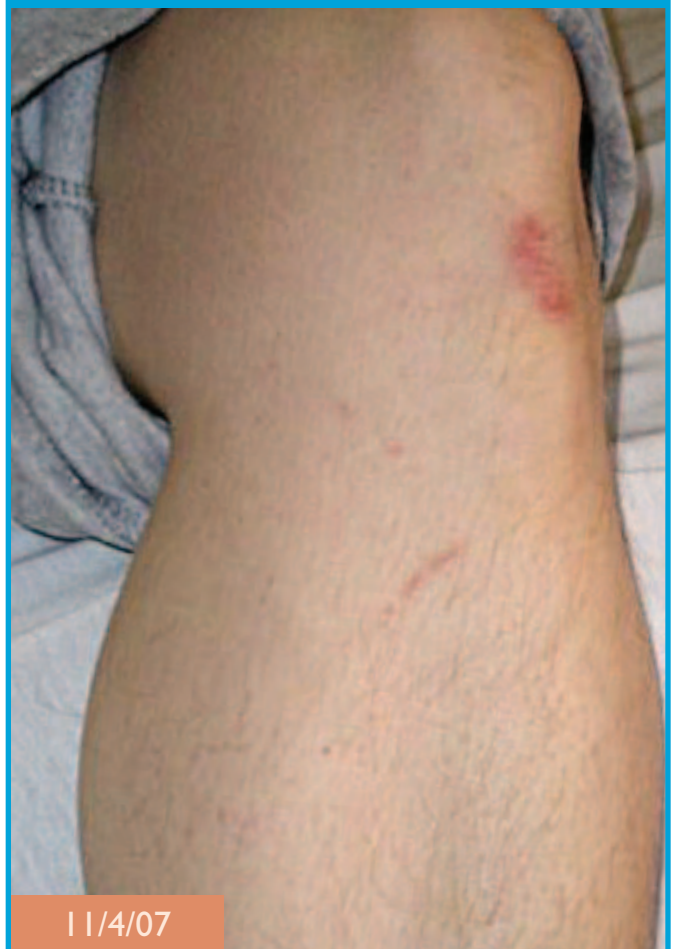“We have several younger residents at our facility who have the devastating disease of Huntington’s chorea. These pictures are of a 41 year old female resident with Huntington’s. The progression of this disease causes uncontrollable and extreme flailing/thrashing movements that result in severe bruising and skin tears, especially to the upper and lower extremities. We have tried numerous interventions to prevent these injuries, including sleeves, knee and elbow pads, surface pads, etc., but to no avail. Nothing was effective in eliminating the continuous bruising and skin tears until we tried using DermaSaver products. DermaSaver has not only eliminated the severe, chronic bruising on this resident, but we are using DermaSaver on all our residents with Huntington’s and achieving the same results.”

“The first set of pictures with the bruising was taken on 10/19/07. The second set was taken on 11/4/07. This resident was exhibiting new bruised areas and skin tears on a minimum of weekly. Since she has been wearing the DermaSaver arms and legs on a daily basis, while in and out of bed, there has been no further bruising or skin tears identified on this resident. We are happy that we found this product.”

BEFORE USING DERMASAVER FULL LEG TUBES



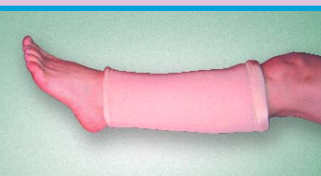AFTER 16 DAYS USING DERMASAVER FULL LEG TUBES



## CASE STUDY

BOYD MEMORIAL NURSING HOME, CARROLLTON, IL

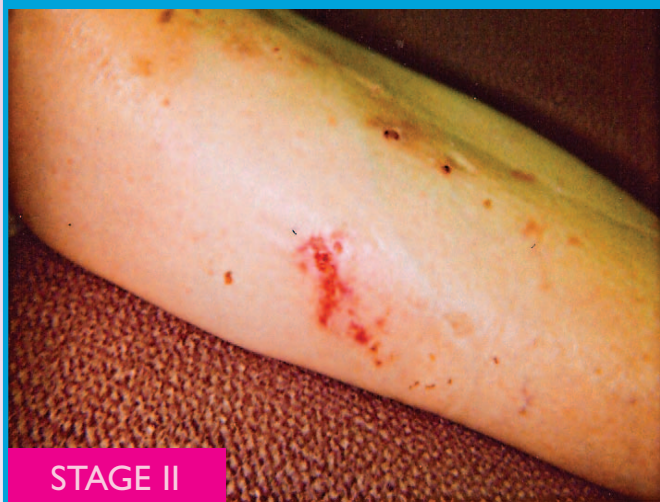■ BY ANITA ADAMS RN, CWCN



DERMASAVER SHIN TUBES

Due to agitation and mental confusion, this resident started banging his legs against the metal bars of the recliner in 9/07 creating multiple skin tears.

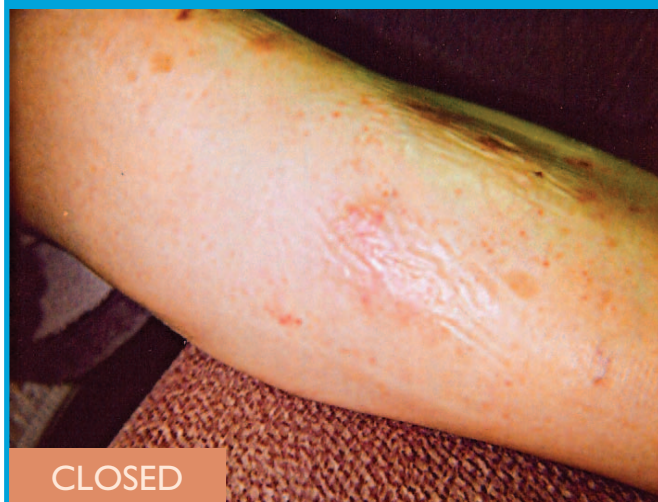### BEFORE USING DERMASAVER SHIN TUBES



STAGE II

SEPT. 25, 2007: Stage II (2 cm x 0.5 cm)

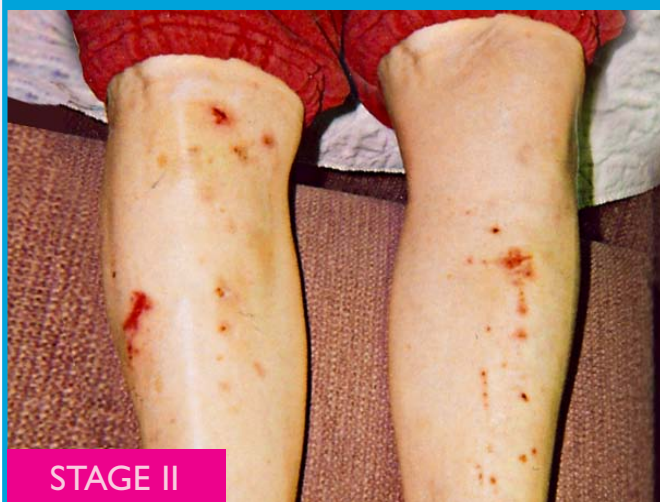### AFTER 9 DAYS USING DERMASAVER SHIN TUBES



CLOSED

OCT 4, 2007: Closed

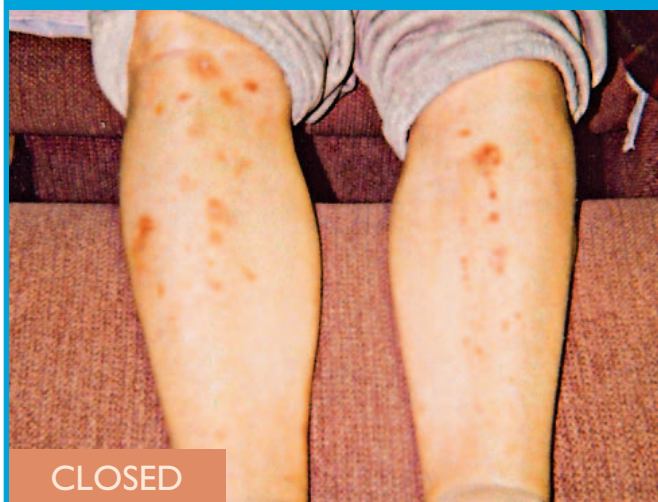### BEFORE USING DERMASAVER SHIN TUBES



STAGE II

SEPT. 25, 2007: Three openings, the largest on lower right leg (Stage II, 2 cm x 0.5 cm)

### AFTER 13 DAYS USING DERMASAVER SHIN TUBES



CLOSED

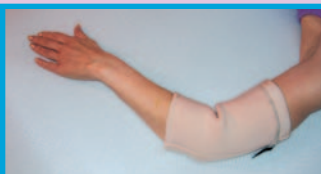OCT 10, 2007: Follow-up: All skin tears closed with no new openings.

# DERMASAVER CASE STUDY



## CASE STUDY

NATHAN LITTAUER HOSPITAL NURSING HOME, GLOVERSVILLE, NY



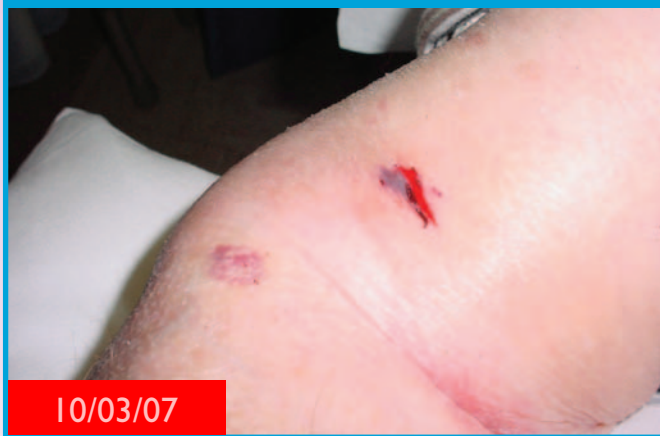DERMASAVER ELBOW TUBE



■ BY PATRICIA RODECKER, RN, WCC

SKIN CARE TEAM: Yvonne Torres, 7-3 CNA,  
Judy Mallory, RN, Patricia Rodecker, RN, WCC

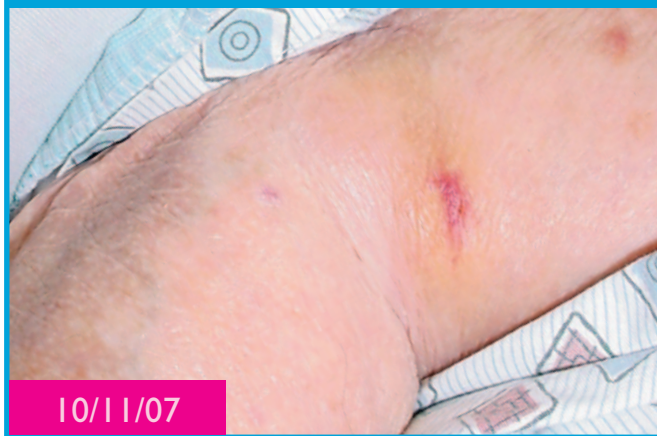### BEFORE USING DERMASAVER ELBOW TUBE



10/03/07

**OCT. 03, 2007:** 88 year old female with skin tear above right elbow. "V" shaped 1.25cm x 0.25cm scant amount of bleeding. Dressed with Mepitel (Molnlycke), Bacitracin, DSD.

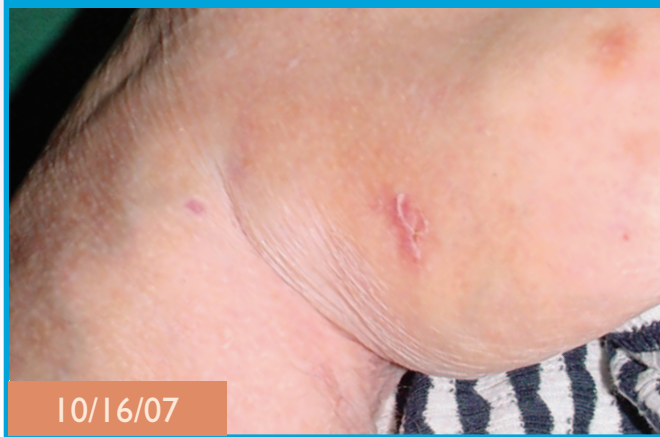### AFTER 9 DAYS USING DERMASAVER ELBOW TUBE



10/11/07

**OCT. 11, 2007:** Area closed – treatment changed to Remedy Skin Repair Cream BID (Medline). Continued use of DermaSaver Elbow Sleeve.

### AFTER 14 DAYS USING DERMASAVER ELBOW TUBE



10/16/07

**OCT. 16, 2007:** Healed, closed wound. Continued use of Remedy Skin Repair Cream and DermaSaver Elbow Sleeve for prevention.

**OCT. 24, 2007:** DermaSaver Elbow Sleeve – continues to be effective for prevention.

I find now staff are coming to me and requesting DermaSaver products as a preventative measure. They like the ease that they are applied and the comfort to the residents, which has increased compliance.

Sincerely,

*Pat Rodecker,*  
RN, WCC

## CASE STUDY

Citronelle Convalescent Center, Citronelle, AL

■ BY **SUSAN G. HERRING, ASSISTANT DIRECTOR OF NURSING**



DERMASAVER DERMA BRIEF

“We had great success with the DermaBriefs in the case study and we are now using them on four other residents to help with their wound healing process and to prevent further wound development.

Below is a week to week record showing progress of the wound.

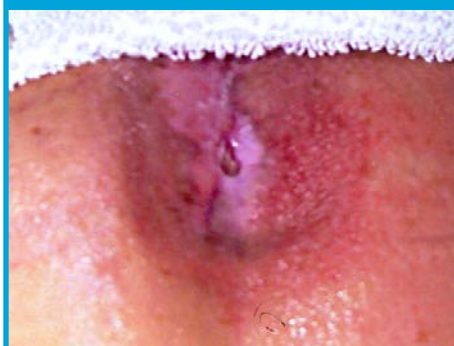The resident was admitted on 10-12-2007 with a 1cm x 0.7cm x 0.1cm deep Stage II wound to his sacrum.

After application of the DermaBriefs, the wound decreased in size to 0.2 cm x 0.1cm with no depth and now the wound is healed. We will continue to use the DermaBrief to prevent any further skin breakdown.

Thank you again for developing this wonderful product that is aiding us in our wound care program.”

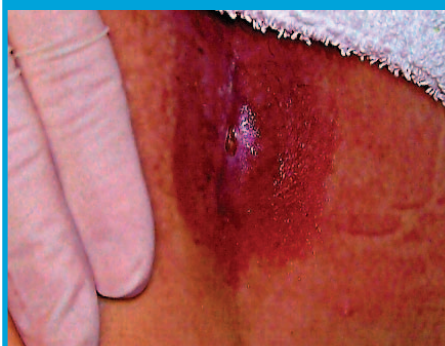Susan G. Herring

BEFORE USING DERMASAVER DERMA BRIEF



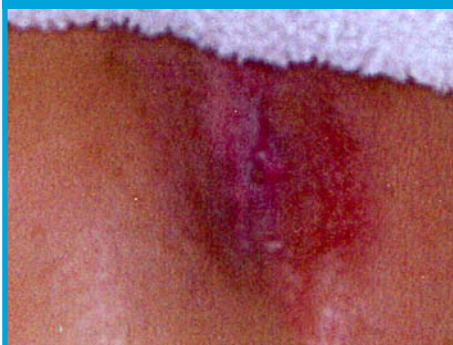12/10/07 Sacral Wound – STAGE II

1 WEEK USING DERMASAVER DERMA BRIEF



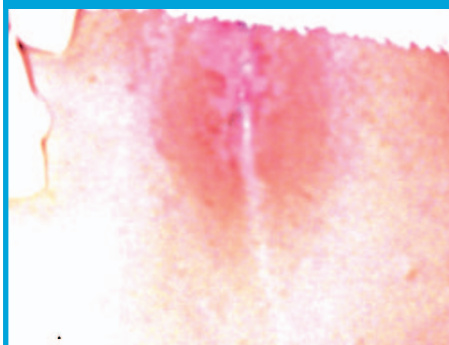12/17/07 STAGE II

2 WEEKS USING DERMASAVER DERMA BRIEF



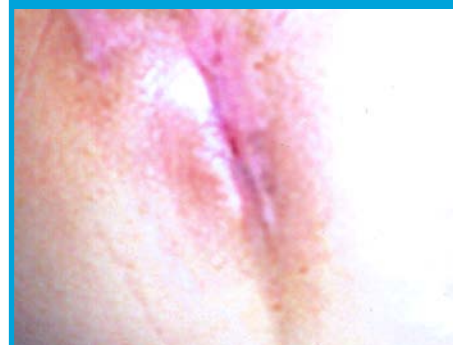12/24/07 STAGE II HEALING

3 WEEKS USING DERMASAVER DERMA BRIEF



12/31/07 Much Improved

AFTER 4 WEEKS NO OPEN AREAS TO SACRAL WOUND



1/4/08 Wound HEALED

## CASE STUDY

SENIOR VILLAGE PERRYTON, TX

■ BY STEPHANIE BATES, RN DON

**Re: Resident.WG, blisters/swelling to bilateral lower extremities.**

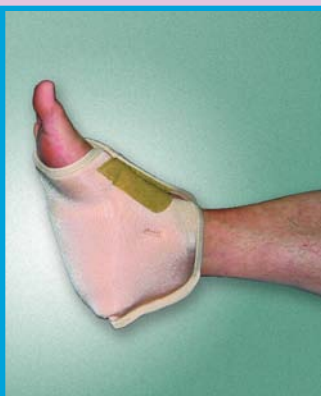This resident has edema and was taking 60mg of Lasix by mouth every day to control the swelling in her lower extremities. She also has dementia of the Alzheimer's type and because of this began refusing to take her daily medications. After two days without her medications her lower extremities became very edematous. Upon a routine inspection several large blisters were noted to bilateral heels as a result of the swelling.

**1/28/08:** I contacted DermaSaver and ordered the Stay-Put Heel Protectors for the resident and had them shipped over-night. We also began using the DermaWrap product to help control the swelling to her lower extremities. We then changed her Lasix from a by mouth dose to an injectable form.

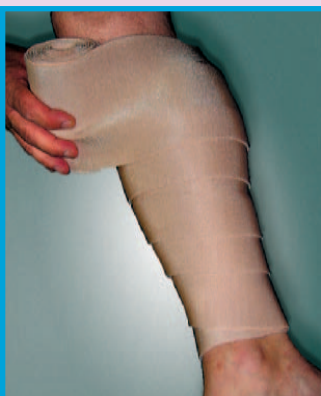**1/29/08:** We began using the DermaSaver Stay-Put Heel Protectors around the clock and began treatments on the resident's heels wrapping with the DermaWrap product on a daily basis.

**1/31/08:** I evaluated the wounds and the progression made. The areas had begun scabbing, healing, no drainage or signs and symptoms of infection and significantly less swelling. Most notable is that there is no evidence of any pressure ulcers developing at this time, because of the resident's status this was a primary concern that we have been able to prevent thus far.

**2/7/08:** I again evaluated the wounds for progress. It was noted that the heels continue to heal without developing pressure ulcers. There is a blood blister that remains after the swelling and blisters have resolved, but tissue surrounding the blister is healthy and healing. Resident was switched back to by mouth Lasix and is taking her medication regularly. We are continuing to use the DermaSaver Stay-Put Heel Protectors as a preventative measure on a daily basis.

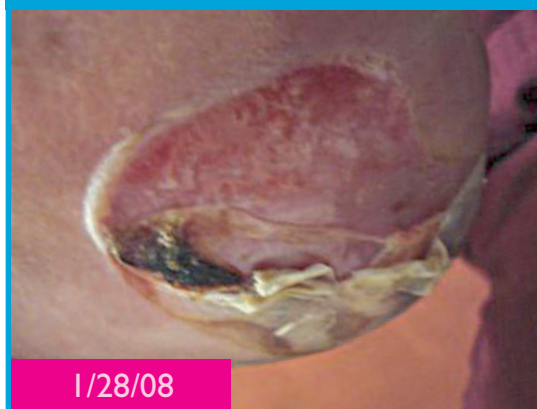

DERMASAVER STAY-PUT  
HEEL PROTECTOR



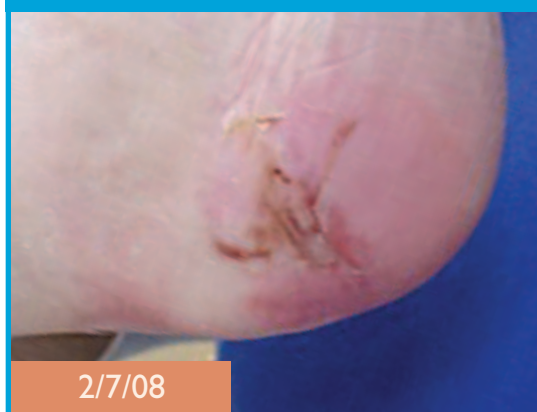DERMAWRAP

BEFORE USING DERMASAVER STAY-PUT HEEL PROTECTOR



1/28/08

AFTER USING DERMASAVER STAY-PUT HEEL PROTECTOR

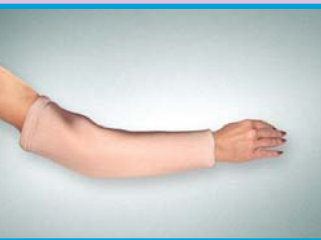

2/7/08

## CASE STUDY

THE LUTHERAN HOME, RIVER FALLS, WI

■ BY KIMALEY STAPLETON, DIRECTOR OF NURSING, RN, BSN



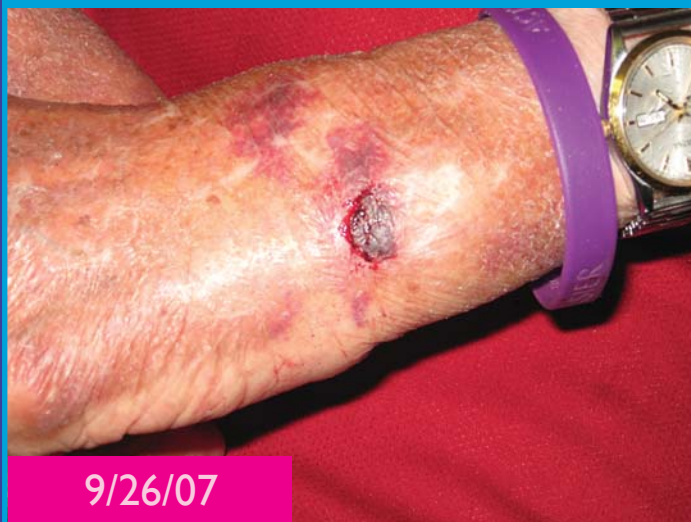DERMASAVER ARM TUBE

The skin tear occurred on 09/26/07 and was healed on 10/04/07! This resident has very fragile skin and we were able to heal this skin tear in 9 days by wearing the DermaSaver Arm Tube.

We used a clear film type dressing after realigning the skin tear edges. After approximating the wound edges and applying the film dressing we applied the DermaSaver sleeves immediately. We are a faithful user of the Derma saver sleeves.

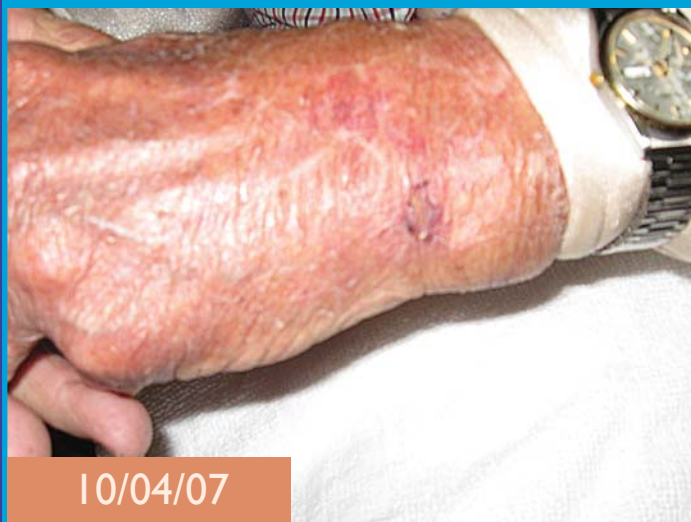This resident was happy to wear the protective sleeve during healing and afterwards for added skin protection.

### BEFORE USING DERMASAVER ARM TUBE




9/26/07

### AFTER 9 DAYS USING DERMASAVER ARM TUBE



10/04/07



DERMASAVER ■ 1-800-358-4477  
WWW.DERMASAVER.COM