

Testimonial for Australian Medical Sheepskin

While being treated for a heart condition, my mother developed a necrotic bed sore that unfortunately went undetected for four days, to the point it was black and had an odor. On the 5th day treatment was begun with the application of antibiotics and the typical bandaid meant for bed sores. The protocol is to label the bandaid with that day's date and I did observe that process. With that process the sore can go a fairly long time without being checked. I was told by the medical professionals that the bed sore bandage may not be changed unless it becomes soiled or wet from a bath for example.

When I learned of the coccyx bed sore sheepskin pad I decided to give it a try. I wasn't convinced until I started to see the rapid healing with my own eyes. I took a picture on the first day the doctor viewed it when starting antibiotics and then proceeded to photo document for the duration of mom's stay. The speed with which it healed was amazing. The sore healed in 2.5 months. The enormity of the sore and depth has left her with a permanent scar but it is definitely healed and she has gone without the sheepskin pad for quite awhile choosing to sit/lay on a sheepskin blanket (with clothing on) just in case the compromised skin breaks again. So far so good.

During the care in her home she became more weak and because she was so afraid to lay on the old sore, she developed a new bed sore on her right side. I was on top of it immediately and even though it was tiny, it was quite open and bled. Within 2 to 3 days using the sheepskin pad this new sore healed. A few days later there was a slight mark only.

I know Steve, you can explain why the sheepskin works. I can only tell you that it does. It is my understanding that it whisks away moisture and promotes sloughing which is exactly what you need to heal the wound. You want to promote tissue growth and remove fluids. The opposite happens with the products that are used where my mom was when diagnosed with the bed sore. Or should I say it takes much longer. At the onset of her very large bed sore I was told of a few scenarios for how long she would have to deal with the sore. They ranged from many months to over a year to never healing. Imagine my surprise seeing it heal so quickly. All thanks to the sheepskin pads!

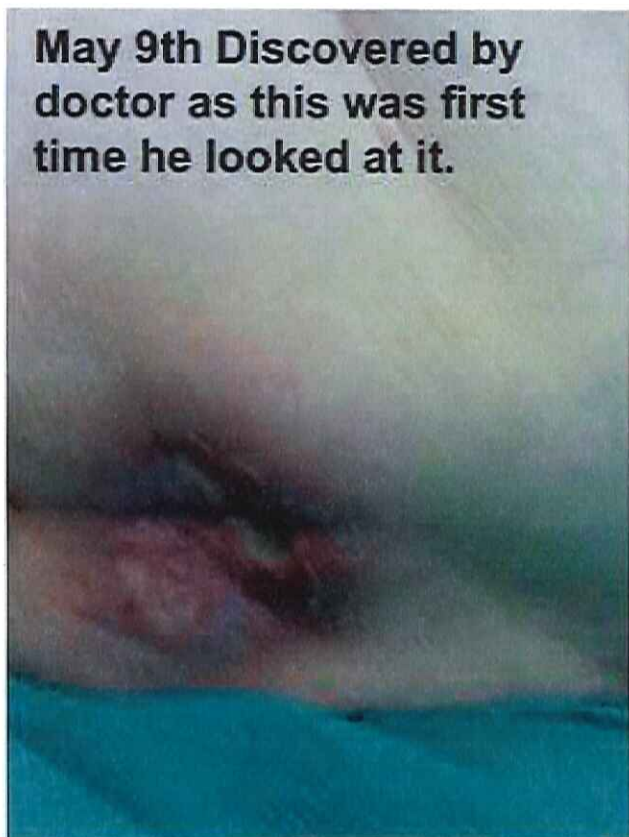And in closing I dare say that prevention would be exactly what our health care system should look at by using these sheepskin products. I bought a 6 pack of coccyx sheepskin pads and washed and used them over and over. These could be used for years. Prevention is less costly.

So very glad we had these pads as it was one less trauma my mother faced during her recuperation.

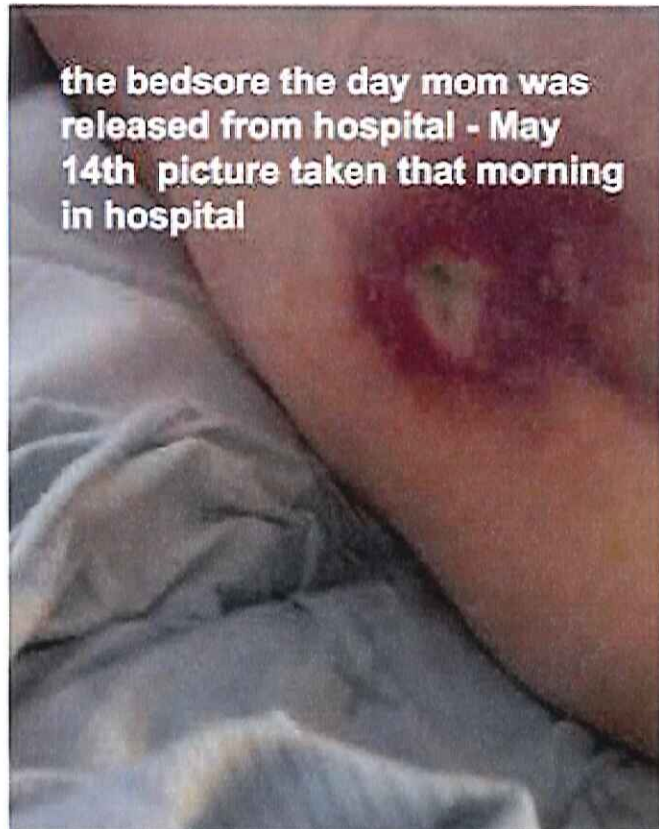
Gail P Fenwick
Moose Jaw, Saskatchewan

Mom was diagnosed with Afib on April 28th/15, entered ICU and remained there until Friday May 1st. Transferred to Medicine May 1st and during her stay (May 1 to May 14th) she developed a necrotic bed-sore that went unnoticed by Dr. Majid. He saw it for the first time on May 9th/15 after she had had it 4 days. She did not have the sore in ICU April 28 - May 1 Sore developed somewhere between May1-5

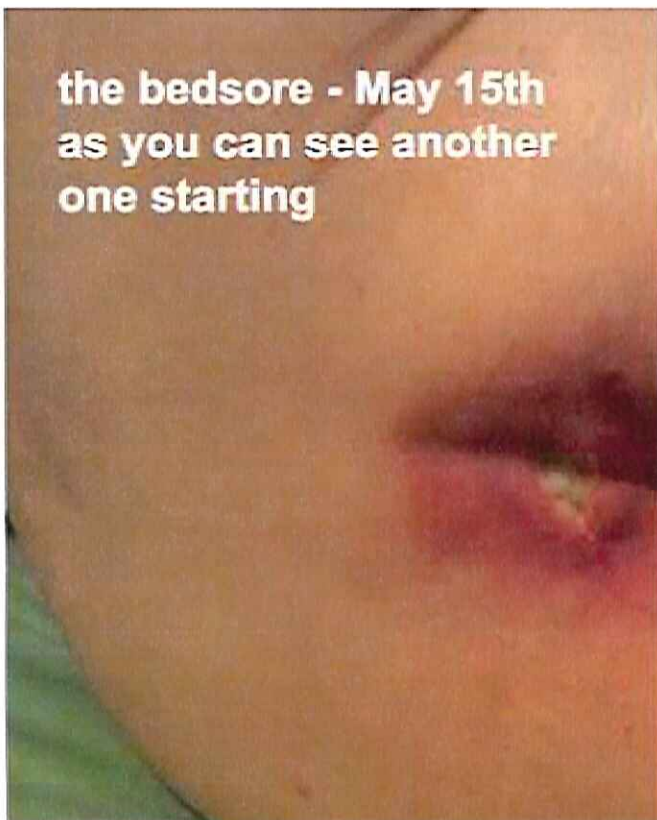
May 9th Discovered by doctor as this was first time he looked at it.



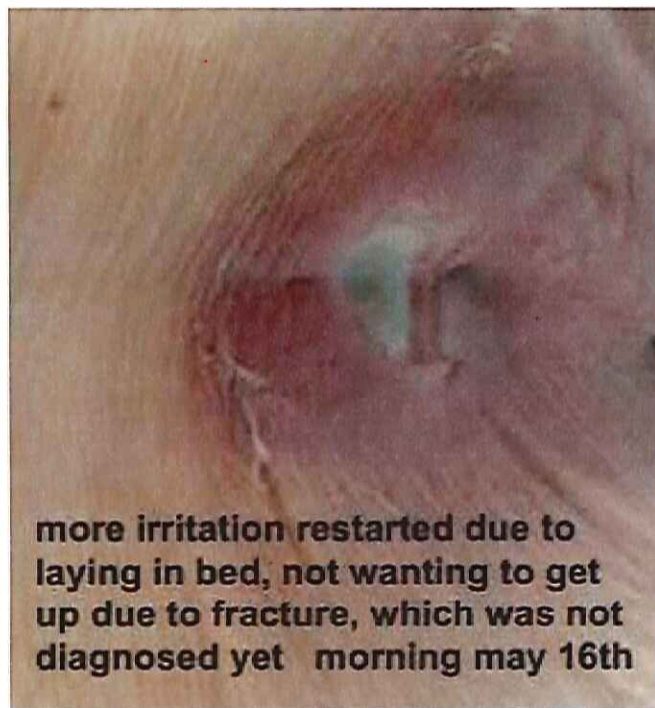the bed sore the day mom was released from hospital - May 14th picture taken that morning in hospital



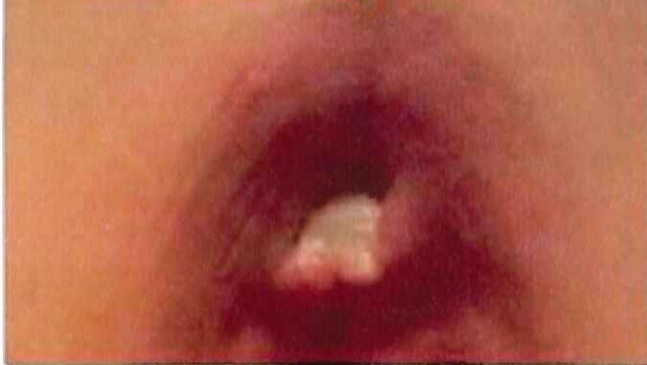the bed sore - May 15th as you can see another one starting



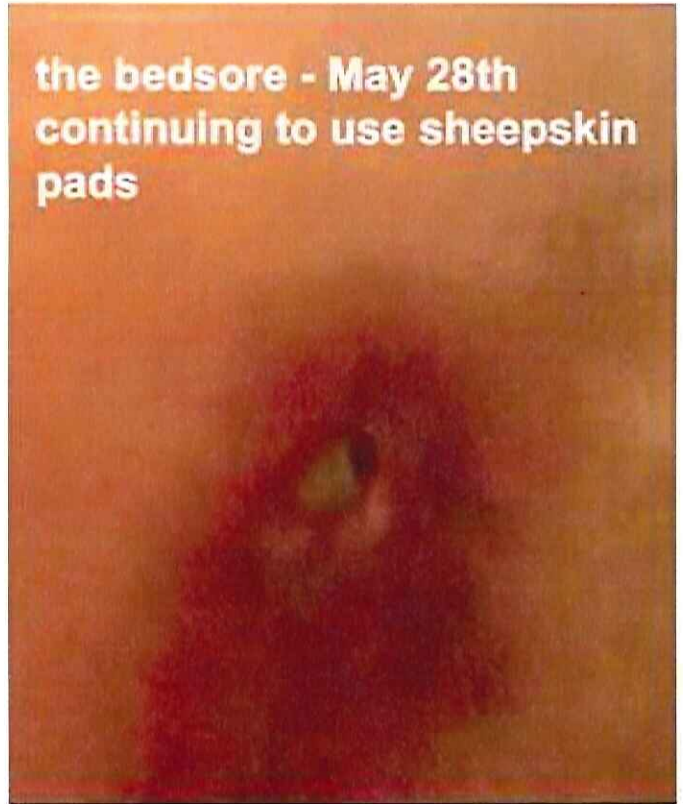
more irritation restarted due to laying in bed, not wanting to get up due to fracture, which was not diagnosed yet morning may 16th



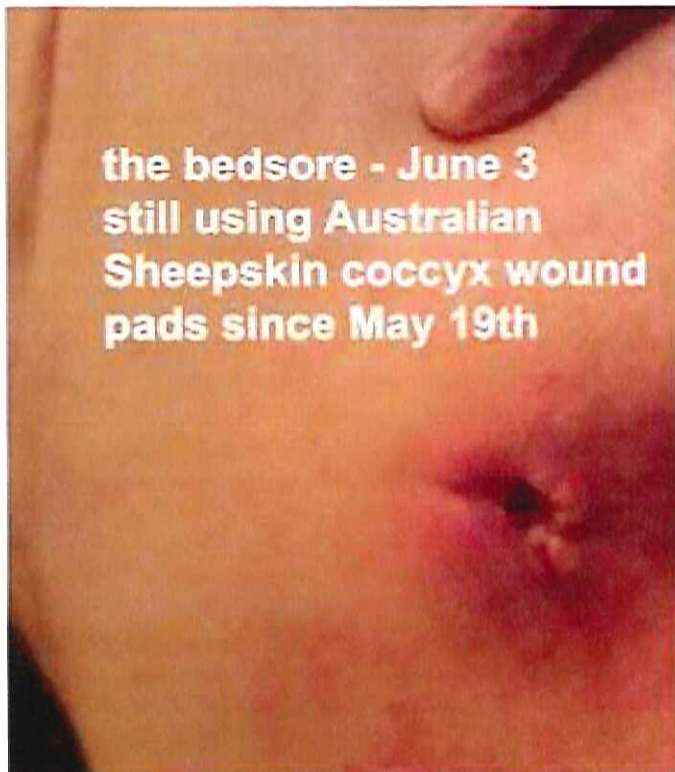
the bedsore - May 23rd
after using Australian
Sheepskin coxyc would
pads since May 19th



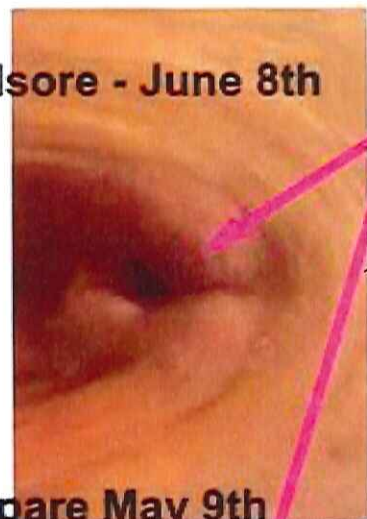the bedsore - May 28th
continuing to use sheepskin
pads



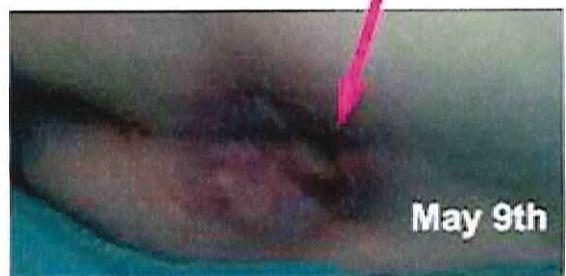the bedsore - June 3
still using Australian
Sheepskin coccyx wound
pads since May 19th



the bedsore - June 8th



compare May 9th
to June 8th



May 9th