

CASE REPORT

The use of ozone therapy in Buruli ulcer had an excellent outcome

Antonella Bertolotti,¹ Annunziata Izzo,¹ Pier Giovanni Grigolato,² Maria Letizia Iabichella¹

¹InterMed Onlus, Brescia, Italy
²Department of Pathology, University Brescia, Brescia, Italy

Correspondence to
Dr Maria Letizia Iabichella,
ml.iabichella@gmail.com

SUMMARY

This is the first case reporting the effective use of 2 weeks of ozone therapy for the treatment of Buruli ulcer (BU), a dramatic disease caused by *Mycobacterium ulcerans*, an epidemic in central Africa. This simple and cheap treatment could become an effective option for managing BU as an alternative to antibiotic or surgical treatments.

BACKGROUND

Buruli ulcer (BU) is an extensive tissue necrosis resulting from an initial skin infection caused by a diffusible lipid toxin (mycolactone) produced by *Mycobacterium ulcerans*, a bacterium prevalent in humid, rural tropical areas. Several thousand people are infected each year, especially in tropical Africa, where BUs are often a source of major disability.¹

As little is known about disease transmission, prevention is difficult. Furthermore, even though several studies are in progress, to date, there is no vaccine.¹

A combination of oral rifampicin (RMP) and injectable streptomycin is an effective option,² recommended by WHO,³ in early, limited disease,⁴ but the social situation in areas where BU has high diffusion rarely allows their use.⁵ Furthermore, antibiotic treatment is accompanied by a reversion of the local immunosuppression. As not all patients with *M ulcerans* infection have BU, the synergistic antimycobacterial action of antibiotics and immune defence mechanisms may be required to clear the infection efficiently.⁶

Surgical treatment and functional rehabilitation are often necessary, but their use and the best time for surgery for large BUs need clarification.³ The high relapse rates,⁷ prohibitive cost and limited access to surgery in endemic areas in Africa led to the search for new therapeutic options capable of being easily used by local healthcare providers in these poorly assisted areas.

The differential diagnosis of BU due to *M ulcerans* on a clinical or epidemiological basis only is difficult,³ so the BU diagnosis needs to be confirmed by Ziehl-Neelsen (ZN) staining at rural health centres.⁸

Diagnostic tests suitable for use in primary care settings are needed, along with well-tolerated, effective, cheap and easily administrable treatments.

The health cooperation project between InterMed Onlus, Brescia Hospital and the Health Centre run by the Camillian Sisters in Zinvié,

Benin was started in 2010 with the aim of providing a clinical structure where Italian physicians gave their assistance to the local population and taught local healthcare providers the management of the most serious pathologies observed, including BU.

CASE PRESENTATION

A 16-year-old female met our assistance centre with an ulcer in the left arm. The patient was treated for 8 weeks with antibiotic therapy with RMP by mouth 10 mg/kg and streptomycin intramuscularly 15 mg/kg, in accordance with the WHO guidelines,⁸ without any clinically significant improvement in the ulcer site in the previous 5 months. The wound area was 60 cm², 0.5 cm deep and with fibrin and necrosis tissue appearance (figure 1A,B).

The patient gave informed consent for the publication of this report.

INVESTIGATIONS

BU was clinically diagnosed and, in accordance with the WHO guidelines, the diagnosis was confirmed with histological and molecular analyses with advanced PCR DNA.

Histological analysis

We collected a biopsy sample of 1 cm² of skin and muscle from the patient during the assessment visit. The sample was fixed in formalin at the Zinvié laboratory and then transported to the second Department of Pathology of Brescia (Italy) where the histological examination was performed. H&E staining was used for the histological study (figure 2A); the sample highlighted the presence of acid-fast bacilli.

DIFFERENTIAL DIAGNOSIS

Molecular analysis

To confirm the presence of bacterium, PCR was performed. Genomic and bacterial DNA were obtained from four 10 µm thick sections cut from paraffin blocks of all samples. The sections were collected and rehydrated by washing in xylene and solutions of decreasing alcohol concentration (100%, 95% and 70% ethanol). After standard digestion with proteinase K at 56°C, the DNA was purified using the Tissue NucleoSpin Kit (Macherey-Nagel, GmbH & Co, Duren, Germany).⁹ PCR for the IS2606 region of the *M ulcerans* (332 bp) was applied using 100 ng of DNA (figure 3A). False negatives caused by a possible DNA degradation due to the treatment were excluded by control amplification of the human

To cite: Bertolotti A, Izzo A, Grigolato PG, et al. *BMJ Case Rep* Published online: [please include Day Month Year] doi:10.1136/bcr-2012-008249

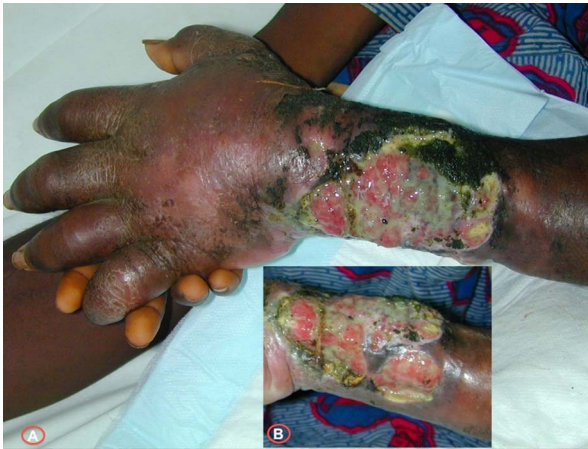

Figure 1 Buruli ulcer of the patient at baseline.

β -globin gene (figure 3B). Molecular methods for the detection of *M ulcerans* showed the presence of a specific band before treatment (figure 3A, lane 3) and the absence of the band after ozone therapy (figure 3A, lane 4).

TREATMENT

We developed a method where O_3 was administered topically by positioning a bag around the lesion and insufflating an O_2 - O_3 mixture at a concentration of 30 μ g/ml. The inflated bag

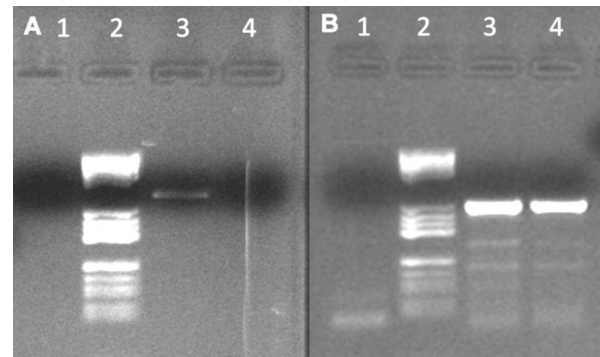


Figure 3 PCR detection of *Mycobacterium ulcerans*. PCR for the IS2606 region of the *M ulcerans* (332 bp) was applied (A): lanes 1, negative control; 2, molecular weight V; 3, case 1 before ozone therapy; 4, case 1 after ozone therapy. False negatives were excluded by control amplification of the human β -globin gene of *M ulcerans* DNA (B): lanes 1, negative control; 2, molecular weight V; 3, amplified human β -globin gene; 4, amplified human β -globin gene.

was sealed just above the lesion to avoid gas leakage. Then the bag was positioned to let the gas mixture be in contact with the ulcer wound for around 20 min (figure 4A).

When the bag was removed, the wound was medicated as usual by applying a sterile gauze with an uncompressing bandage.

This procedure was repeated four times a week for 2 weeks to stimulate debridement and to heal the skin ulcers.

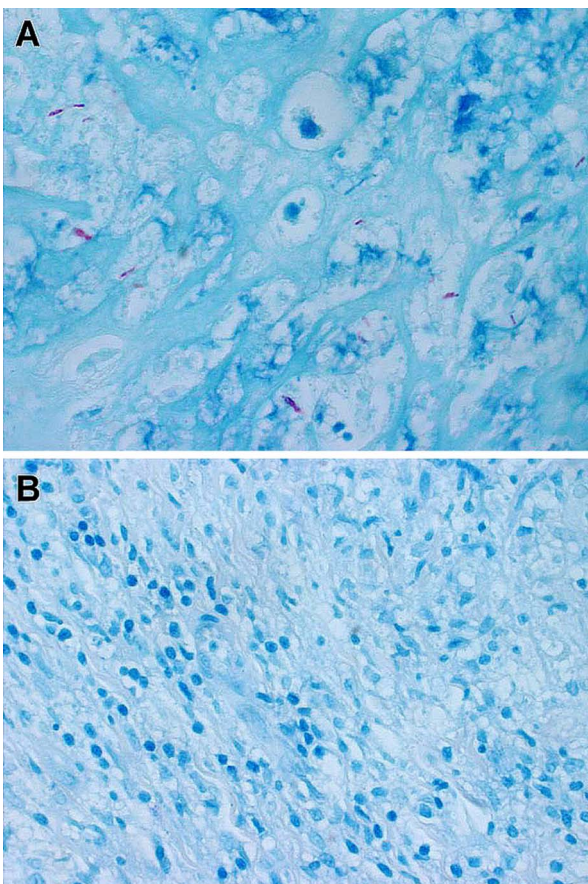


Figure 2 Histochemical Ziehl-Neelsen staining of *Mycobacterium ulcerans*. Ziehl-Neelsen staining of the skin before ozone therapy (A) and after ozone therapy (B) ($\times 40$ magnification).

OUTCOME AND FOLLOW-UP

The ulcer improved at each ozone application, with a progressive reduction of the wounded area, continuous appearance of granulation tissue and skin recovery, and a parallel reduction of the oedema, necrosis and exudate just after the first ozone application (figure 4B).

The ulcer was clean and granulated, without any sign of infection, after the first week of treatment. At the end of the 2 weeks of treatment, the BU disappeared and granulation was present in all wound area (figure 5A).

A histological examination showed the absence of *M ulcerans* (figure 2B), which was confirmed by the absence of the band after ozone therapy (figure 3A, lane 4).

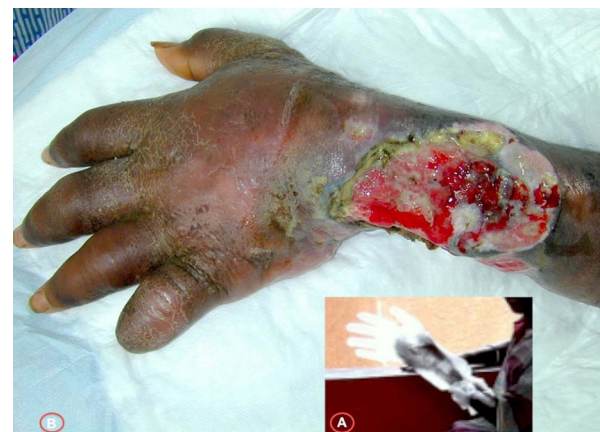

Figure 4 Application of ozone therapy on the Buruli ulcer (A) and outcome after the first application (B).

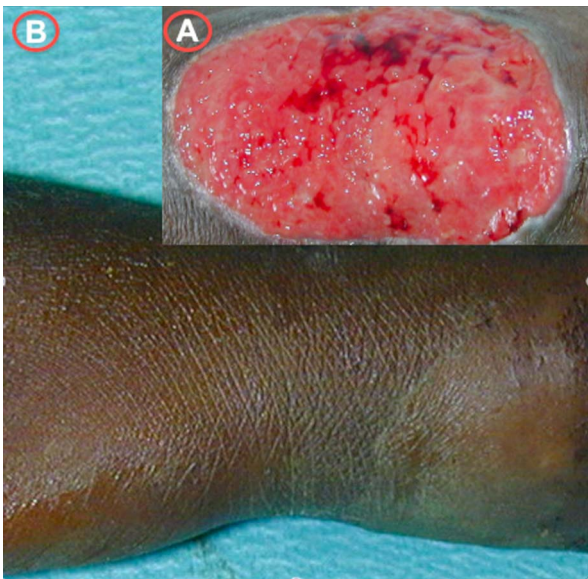


Figure 5 Buruli ulcer of the patient after 2 weeks of ozone therapy (A) and follow-up at 6 months (B).

After 6 months of follow-up, the patient had no sign of BU and the wound was completely healed (figure 5B).

The patient did not experience any local or systemic adverse event.

DISCUSSION

The aim of our collaboration with the Health Centre run by the Camillian Sisters in Zinvié is to provide clinical assistance to patients with BU using a cheap treatment that can be prepared and administered in a simple manner by local, well-trained healthcare providers. This approach, together with a holistic approach to the patient with BU, including health education,¹⁰ could permit BU treatment and control.

In Africa, where a surgery unit or advanced medications are rarely available, the method we used needs only an oxygen tank, an ozone generator, water and a plastic bag, together with a system to let the gas come into contact with the ulcer.

The case reported above was the first of a series of patients treated with this cheap and simply usable treatment in a place with scarce or no hygienic conditions. This case was completely collected and described.

A study evaluating the results of the application of ozone for the treatment of BU is ongoing in our center; we are conducting a randomised study to confirm the effectiveness of this treatment in a representative sample of patients. As soon as the results are available, we will ensure their publication.

Learning points

- ▶ The use of ozone to treat Buruli ulcer might become an effective and safe option if the outcome observed in our case is confirmed in a well-designed, randomised trial.
- ▶ Ozone preparation and its application could be a cheap and simple-to-be-used therapy in poor regions where recommended therapies, as antibiotics and surgery, are difficult to be administered.

Competing interests None.

Patient consent Obtained.

Provenance and peer review Not commissioned; externally peer reviewed.

REFERENCES

- 1 Einarsdottir T, Huygen K. Buruli ulcer. *Hum Vaccin* 2011;7:1198–203.
- 2 Etuafu S, Carbone B, Grosset J, *et al.* Efficacy of the combination rifampin-streptomycin in preventing growth of *Mycobacterium ulcerans* in early lesions of Buruli ulcer in humans. *Antimicrob Agents Chemother* 2005;49:3182–6.
- 3 Kibadi K, Boelaert M, Fraga AG, *et al.* Response to treatment in a prospective cohort of patients with large ulcerated lesions suspected to be Buruli ulcer (*Mycobacterium ulcerans* disease). *PLoS Negl Trop Dis* 2010;4:e736.
- 4 Nienhuis NA, Stienstra Y, Thompson WA, *et al.* Antimicrobial treatment for early, limited *Mycobacterium ulcerans* infection: a randomised controlled trial. *Lancet* 2010;37:664–72.
- 5 Buruli ulcer. A disabling infection. *Prescrire Int* 2010;19:261–2.
- 6 Schutte D, Um-Boock A, Mensah-Quainoo E, *et al.* Development of highly organized lymphoid structures in Buruli ulcer lesions after treatment with rifampicin and streptomycin. *PLoS Negl Trop Dis* 2007;1:e02.
- 7 Kibadi AK. Relapses after surgical treatment of Buruli ulcer in Africa. *Bull Soc Pathol Exot* 2006;99:230–5.
- 8 World Health Organization. Buruli ulcer: progress report. 2004–2008, 2008. <http://www.who.int/wer/2008/wer8317.pdf>
- 9 Stinear T, Ross BC, Davies JK, *et al.* Identification and characterization of IS2404 and IS2606: two distinct repeated sequences for detection of *Mycobacterium ulcerans* by PCR. *J Clin Microbiol* 1999;37:1018–23.
- 10 Agbenorku P, Agbenorku M, Amankwa A, *et al.* Factors enhancing the control of Buruli ulcer in the Bomfa communities, Ghana. *Trans R Soc Trop Med Hyg* 2011;105:459–65.

Copyright 2013 BMJ Publishing Group. All rights reserved. For permission to reuse any of this content visit <http://group.bmj.com/group/rights-licensing/permissions>.

BMJ Case Report Fellows may re-use this article for personal use and teaching without any further permission.

Become a Fellow of BMJ Case Reports today and you can:

- ▶ Submit as many cases as you like
- ▶ Enjoy fast sympathetic peer review and rapid publication of accepted articles
- ▶ Access all the published articles
- ▶ Re-use any of the published material for personal use and teaching without further permission

For information on Institutional Fellowships contact consortiasales@bmjgroup.com

Visit casereports.bmj.com for more articles like this and to become a Fellow