No. 774

IDENTIFICATION OF HIGH-RISK CORONARY ARTERY DISEASE WITH REST AND EXERCISE DUAL-ISOTOPE SPECT. K. A. Williams*, C. M. Schneider, University of Chicago, Chicago, IL. (101263)

Background: Extensive perfusion defects (PD), transient ischemic dilatation (TID), and increased (↑) RV activity each indicate severe (SEV) coronary artery disease (CAD) on exercise SPECT imaging. The relative frequency of these signs was examined in patients (pts) with and without high risk CAD. ***Methods:*** Rest ^{201}Tl and exercise ^{99m}Tc (sestamibi or tetrofosmin) SPECT images were analyzed for TID (i.e., ^{99m}Tc/^{201}Tl inverted cavity counts > 1.19), PD pattern indicating left main or 3-vessel CAD, and peak RV/LV activity ratio in 315 pts: 96 with SEV CAD (left main or 3-vessel), 144 with 1- or 2-vessel CAD (MILD), and 75 with no significant (NOSIG) CAD on angiography or a low likelihood of CAD. ***Results:*** TID was common in the SEV group (78%, vs. 65% in MILD, 24% in NOSIG group, each p<.03). An ↑RV/LV ratio (stress peak RV/LV count ratio >42% and stress/rest ratio >1.2) was present in 33% of SEV, 9% or MILD, and 5% of NOSIG (p<.01 SEV vs. other groups). The PD pattern indicated SEV CAD in 33% of SEV, 28% of the mild group, and 16% of the NOSIG group (p<.02, SEV vs. NOSIG). Marked (i.e., >3 mm) ST-depression with angina pectoris was rare (3%) in NOSIG, but did not distinguish SEV from MILD. ***Conclusions:*** SEV CAD is suggested by the presence of angina plus marked ST-depression, a multivessel pattern of PD, ↑RV activity with exercise, and TID with dual-isotope SPECT. TID is more frequent than ↑RV activity in such pts; the latter is more specific for SEV CAD, e.g., a tight left main with less proximal right CAD.

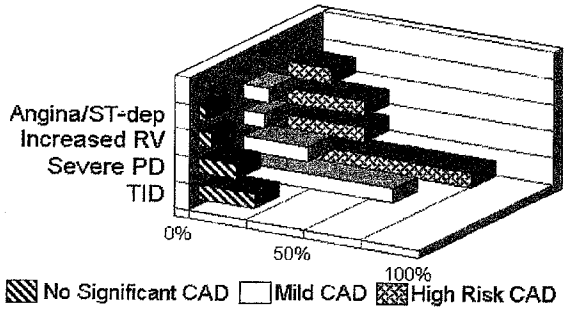

No. 775

EVALUATION OF THE NEW GENERATOR-PRODUCED PET RADIOPHARMACEUTICAL CU62-ETS VERSUS CU62-PTSM FOR MYOCARDIAL PERFUSION IMAGING. J. L. Lacy*, N. G. Haynes, N. Nayak, C. S. Martin, D. Dai, M. A. Green, Proportional Technologies, Inc., Houston, TX; Purdue University, West Lafayette, IN. (101274)

Aims: Although Cu62-PTSM has been shown to provide high quality PET myocardial perfusion images, liver uptake is relatively high, and myocardial uptake is nonlinear with flow. The goal of this work was to determine whether the PET agent Cu62-ETS, a related *bis*(thiosemicarbazone) tracer which is produced by the Zn62/Cu62 generator, demonstrates superior imaging characteristics when compared to generator-produced Cu62-PTSM for myocardial perfusion imaging. **Methods:** 7 normal volunteers and 1 CAD patient, who had all previously undergone PET myocardial perfusion imaging with PTSM, received rest-dipyridamole stress PET scans using the ETS agent following the same protocol in both cases. Mean injected doses were 19.5±2.0 mCi and 18.3±2.4 mCi for Cu62-PTSM and Cu62-ETS, respectively. Comparable doses were injected for rest and stress studies, which were separated by a 45 minute period to allow decay. Images were processed and displayed in short axis format, and regions of interest were drawn around the myocardium and the liver. **Results:** The stress/rest myocardial ratio for ETS was 1.54±0.15 vs 1.36±0.17 for PTSM ($p < 0.05$). The heart/liver ratio at rest for ETS was 1.04±0.08 vs 0.70±0.18 for PTSM (p<0.05). At stress, the heart/liver ratios were 1.07±0.11 and 0.65±0.13 for ETS and PTSM, respectively (p<0.05). **Conclusions:** The new agent Cu62-ETS exhibits a significantly higher stress/rest myocardial ratio and much lower liver uptake levels compared to Cu62-PTSM. Therefore, this tracer, whose performance is similar to N13-ammonia and which can be generator-produced and widely distributed, merits further investigational studies.

No. 776

DETERMINATION OF LEFT VENTRICULAR EJECTION FRACTION BY ADVANCED ECHO IMAGING MODALITIES IMPROVES CORRELATION WITH RADIONUCLIDE ANGIOGRAPHY. E. H. Yu*, R. M. Iwanochko, R. Burke, C. Sloggett, H. Rakowski, S. Siu, R. J. Burns, The Toronto Hospital, Western Division, Toronto, ON, Canada; University of Toronto, Toronto, ON, Canada; The Toronto Hospital, Toronto, ON, Canada. (101344)

Correlation of LV ejection fraction(LVEF)by echocardiography (echo) and radionuclide angiography(RNA) is poor.This is especially evident when the echo endocardial border definition (EBD) is poor.Intravenous (IV) contrast and tissue harmonic imaging (THI) are 2 methods for enhancing EBD. We evaluated their effect on the accuracy of echo for the measurement of LVEF. **Methods:** We prospectively studied 35 consecutive patients (20 male, mean age 54 yrs.) referred for RNA because of a poor quality echo.Mean BSA was 1.93 m^2(range 1.5-2.7 m^2).Standard echo views were obtained using fundamental imaging (FI),THI,and IV contrast (Levovist®) enhanced power harmonic imaging(CON).LVEF was calculated using Simpson's biplane formula (SBF) for each echo.All patients underwent equilibrium ECG-gated RNA (32-frames/RR) within 1 hour of echo. Independent blinded observers calculated LVEF obtained by FI,THI,CON,and RNA.Echo LVEF's obtained by FI,THI,and CON were compared to RNA using linear regression.The range of differences between RNA and each echo method are shown in the attached table (range of Δ). **Results:** Images for the calculation of LVEF using SBF are feasible in 100%,80%,and 40% by CON,THI,and FI respectively(p<0.001 for all pairwise comparisons).CON LVEF has the best correlation with RNA LVEF. **Conclusion:** CON provides adequate EBD for reliable calculation of LVEF

Linear Regression of LVEF (RNA vs. Echo)

Modality	SEE	r	range of Δ (%)
FI	9.6	0.54	(-8 to +26)
THI	7.4	0.9	(-12 to +18)
CON	4.0	0.97	(-11 to +11)

No. 777

QUANTITATIVE REST TC-99M TETROFOSMIN TOMOGRAPHY IN PREDICTING FUNCTIONAL RECOVERY AFTER REVASCULARIZATION: COMPARISON WITH DOBUTAMINE ECHOCARDIOGRAPHY. A. Cuocolo*, W. Acampa, A. Bruno, M. Castellari, V. Longari, L. Spinelli, University Federico II, Napoli, Italy; IRCCS-Ospedale Maggiore, Milan, Italy. (500050)

Objectives: Myocardial perfusion imaging and low-dose dobutamine echocardiography have been used to identify viable myocardium in patients with ischemic left ventricular (LV) dysfunction. This study was designed to assess the comparative values of rest Tc-99m tetrofosmin cardiac tomography and dobutamine echocardiography for predicting recovery of LV function after revascularization. Methods: Seventeen patients with previous myocardial infarction and impaired LV function (ejection fraction 34±9%) underwent on the same day low-dose (5-10 mcg/kg/min) dobutamine echocardiography and rest tetrofosmin imaging. Resting echocardiogram and tetrofosmin tomography were repeated 3 months after revascularization. In each patient, tetrofosmin activity was quantitatively measured in 16 segments. LV function was assessed in corresponding segments. Baseline akinetic or dyskinetic segments were considered as showing functional recovery when wall motion improved after revascularization. Optimal threshold cutoff to separate reversible from irreversible dysfunction was determined by receiver operating characteristic analysis. Results: Of the 77 segments with severe wall motion abnormalities (akinetic or dyskinetic) at baseline echocardiography, 30 showed functional recovery and 47 did not change after revascularization. In asynergic segments with functional recovery, tetrofosmin uptake was 53±16% at baseline and 60±15% after revascularization (p<.001). In asynergic