

Lungs

The lungs are attached to their surrounding structures by a suction system and the suspensory, lung and interpleural ligaments.

The suction system is created by the negative pressure within the thoracic cavity, which forces the lung to be always flattened against the lining. The suction is localized at the periphery of the lungs and makes possible thoracic expansion.

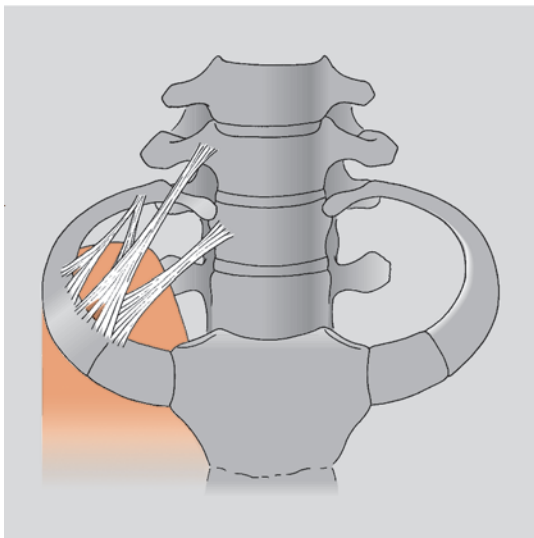


ILLUSTRATION 2-1

The Suspensory Ligament of the Pleural Dome

The suspensory ligament attaches the pleural dome to the skeleton (*Illustration 2-1*). It consists of muscular fibers of the scalenus minimus (sometimes mixed with fibers of the anterior and medial scalene muscles), plus the fibrous fasciculi. This ligament is not directly inserted into the parietal pleura, but rather into the intrathoracic fascia. This fascia forms a “connective tissue dome” at the level of the top of the lungs, where it and the elements of the ligament form a partition. This partition, which is anatomically independent of the parietal pleura, is firmly attached to the nearby skeleton and is called the cervicothoracic fibrous septum. In the physiology of movement, this septum

is the link between the superior lobe of the lung and the cervicothoracic junction.

The lung ligament is usually said to be formed from reflected folds of pleura under the pulmonary hilum. In fact, the fold does not stop at the pulmonary hilum, but continues as far as the diaphragm. Overall, the line of reflexion has the form of a tennis racquet, with the web-like part surrounding the pulmonary hilum in the front, behind and above, while the handle is represented by the lung ligament, which is connected to the thorax like a mesentery. Both strips of this “mesentery” are joined together (*Illustration 2-2*). The lung ligament is linked to the esophagus by means of surrounding fascia.

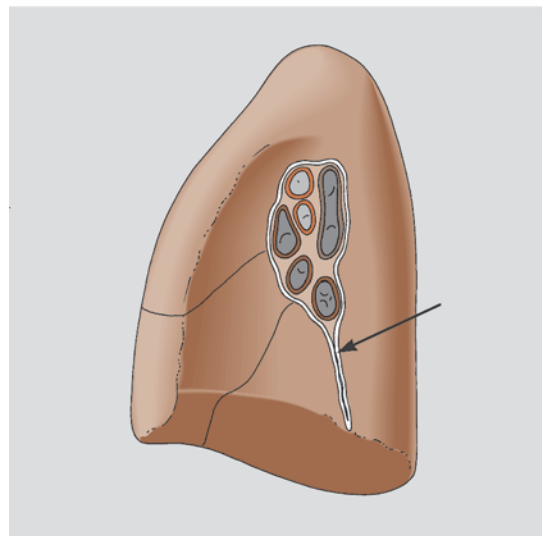


ILLUSTRATION 2-2

The Lung Ligament

Another link between the two lungs is the interpleural ligament, which is formed by the joining of the two interazygos cul-de-sacs (*Illustration 2-3*).

Heart

The heart is attached to surrounding structures by a suction system and a ligamentous system. The suction system is the same as

ANATOMY

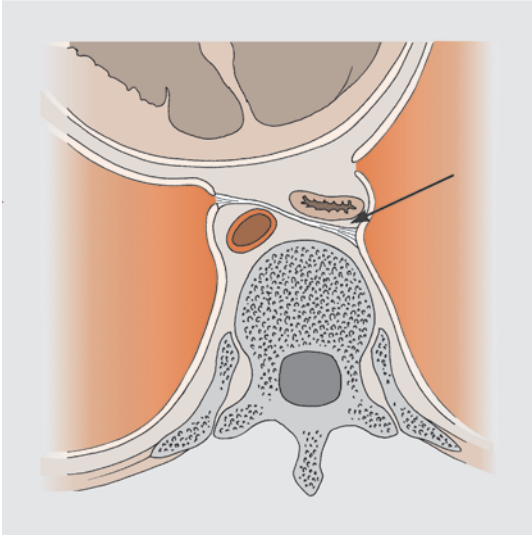


ILLUSTRATION 2-3

The Interpleural Ligament

that of the lungs. There is a parietal membrane lining the deep face of the fibrous pouch and a visceral membrane covering the heart. The fibrous pouch is therefore lined with the parietal pericardium on the inside and the mediastinal pleura on the outside. Thus, there is a double system of serous membranes around the heart.

The heart is stabilized as follows (*Illustration 2-4*):

- anterosuperiorly by the superior sternopericardial ligament
- posterosuperiorly by the vertebropericardial ligament
- anteroinferiorly by the inferior sternopericardial ligament
- posteroinferiorly by the left and right phrenicopericardial ligaments
- inferiorly by the anterior phrenicopericardial ligament

Note that the heart has no lateral osseous attachments and that this role is performed by the lungs and pleura. The lungs, because of their tendency to expand, create a medial pressure which holds the heart in place.

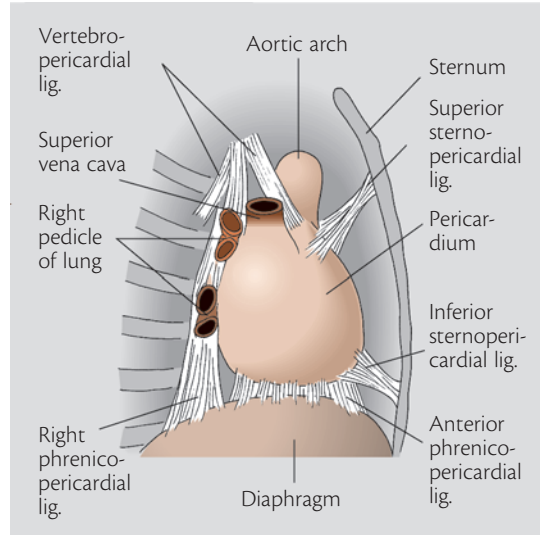


ILLUSTRATION 2-4

The Pericardial Ligaments

TOPOGRAPHICAL ANATOMY

For evaluation and treatment, it is necessary to know where to place one's hands. A knowledge of topographical anatomy gives you a window by which to gaze into the interior of the body. If the line on the left between the border of the sternum and the nipple is divided into three parts, the lungs occupy the lateral third, the costodiaphragmatic sinus the middle third and the heart the medial third. This simplification may startle anatomists, but is largely sufficient for the application of our treatments.

Bronchi

The essential reference mark is that of the tracheal bifurcation. This is at the level of T4/5 posteriorly and the sternal angle or manubrium anteriorly. The most common mistake is to think that it should be more inferior. The bronchi are obliquely directed inferiorly, laterally and posteriorly. The angle is more oblique on the right than on the left. The traction of the right lung is stronger, so much so that the tracheal bifurcation is

slightly to the right of the median line. The right bronchus is shorter than the left, but larger. The left bronchus is concave superiorly and laterally.

Lungs

The important reference marks are the inferior and superior limits of the lung, costodiaphragmatic antrum, posterior left medias-tinal antrum, interlobal fissures and hilum.

The pleural dome is a few centimeters higher than the upper limit of the thoracic cage, which is formed by R1 and the C7/T1 articulation. The pleural dome is the only palpable part of the pleuropulmonary area.

The inferior border of the lung, in a position of medium inhalation, lies behind a horizontal line passing through the upper part of T11. Anteriorly, for the right lung, this inferior border is schematized by a line coming from the sixth costochondral joint, via R6 medially, obliquely inferolaterally to the junction of the midaxillary line and R8. Posteriorly, the oblique fissures begin at T4 and go obliquely downward to the meeting point of R6 and the midclavicular line (*Illustration 2-5*).

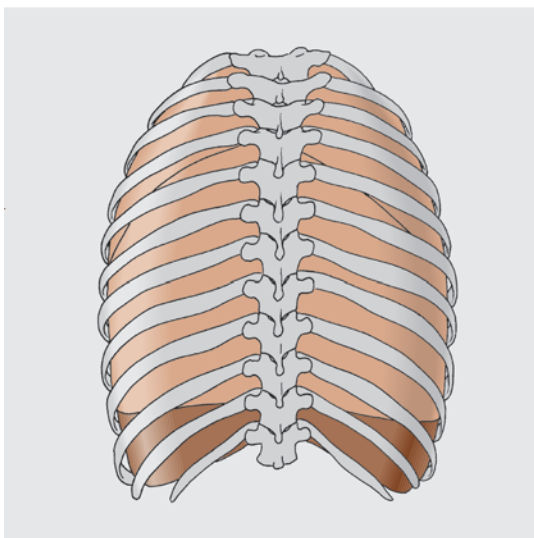


ILLUSTRATION 2-5
Posterior Pulmonary Reference Marks

Anteriorly and on the right, the lungs are delineated inferiorly by a line that is slightly concave superiorly and goes from the lateral edge of the lower extremity of the sternum to the intersection of the axillary line with R8 (see above). The costodiaphragmatic sinus begins in the same place but is oblique and goes down to the intersection of the axillary line and R9. The oblique fissure appears laterally and follows R6. The horizontal fissure begins laterally at the intersection on the oblique fissure of the midclavicular line and R6, and then follows the 4th costal cartilage medially (*Illustration 2-6*).

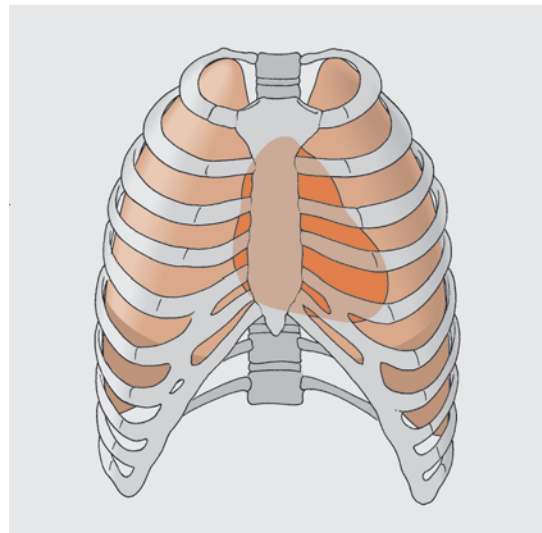


ILLUSTRATION 2-6
Anterior Cardio-Pulmonary Reference Marks

Anteriorly and on the left, the lung and costodiaphragmatic sinus begin at the level of the sternum and 4th left intercostal space. The heart forms a concave indentation medially and posteriorly. The edge of the lung and the sinus then descend vertically to the 6th and 7th costal cartilage respectively.

The two halves of the costodiaphragmatic antrum begin at the lower extremities of the costomediastinal antrums and then separate laterally, crossing R10 on the axillary line. From this point they go posteri-

PHYSIOLOGIC MOTION

orly, medially and finally superiorly to the 12th costovertebral joint.

Heart

In the normal thorax, the cardiac area is in the form of a quadrilateral. The two superior angles are on each side of the sternum, in the 2nd intercostal space, approximately 2cm to the left and right of the sternum. The right inferior angle corresponds with the sternal extremity of the 6th right intercostal space. The left inferior angle is usually found in the 5th left intercostal space, just inferomedial to the left nipple.

Physiologic Motion

MOBILITY

Lungs

The lungs are in perpetual motion, from pulmonary respiration (the most noticeable movement), skeletal muscle movements and motility.

We have already discussed the pulmonary suction system (page 32). This system keeps the lungs adherent to the pleura but also able to slide upon it. In all movement, the lungs and thorax are interdependent; each lung follows its hemithorax. Obviously, there is no bulk displacement of the lungs and expansion is made in the same directions and axes as the movements of the thorax.

Let us examine what happens during forced inhalation, which is only an exaggeration of normal inhalation. Each hemithorax increases in volume, followed by the pleura and lung. This increase is made possible by the mobilization of the supple structures of the hemithorax. The diaphragm (and diaphragmatic pleura) descends, the rib cage undergoes an anterior and lateral expansion and the costal pleura follow the action of the rib cage. Therefore, the expansion of the

hemithorax, and thus the lung, takes place because of the lowering of the diaphragm and costal expansion. The pleuromediastinal wall is fixed.

Because the superior diaphragm of the thorax is essentially made up of stringy structures, the pleural dome is fixed. These fixed points are necessary so that a structure may be stretched. This means that the lungs are subject to forces that pull in opposite directions, albeit on the same axis: traction (force) in one direction must always be linked to a countertraction (tension).

The lung is submitted to a force F on the costal pleura, but also to a tension T on the mediastinal pleura, which prevents the entire lung from moving laterally (*Illustration 2-7*). This tension, which balances

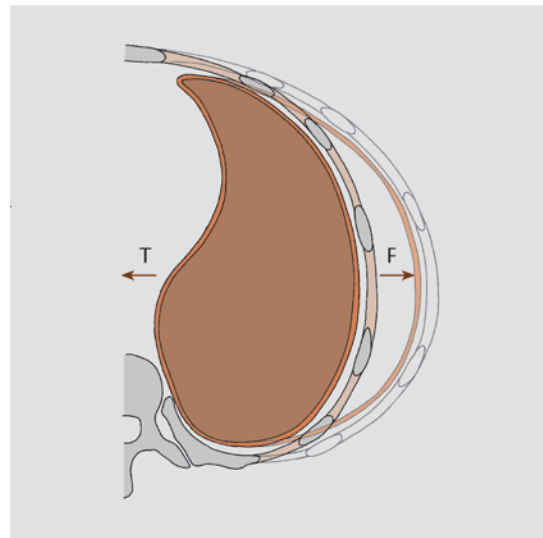


ILLUSTRATION 2-7

Forces and Tensions on the Pleura During Inhalation

.....
the lateral costal expansion, is created via the lung ligament. The tension which balances the downward expansion caused by the diaphragm muscle is created by the suspensory ligament. The movement of the thorax is the sum of the movements of each costovertebral unit (a thoracic vertebra and its pair of ribs).

During inhalation, each lung executes a rotation around a set of axes going through the costovertebral and costotransversal articulations. This axis varies from a nearly frontal plane for the upper ribs to a nearly sagittal plane for the lower ribs. The direction of the axis is directly related to the orientation of the transverse process, which varies in the same way.

The upper ribs undergo a “pump handle” movement which causes the anterior rib cage and sternum to move anterosuperiorly. The lower ribs undergo a “bucket handle” movement which causes a lateral elevation of the lower ribs.

Another rib movement, which is particularly noticeable during forced inhalation but also exists in a latent state during normal inhalation, is a horizontal rotational movement around a vertical axis. For most costovertebral units, this axis passes through the center of the imaginary circle in which the posterior arc of each rib is inscribed.

In fact, if schematically the portion of the oval which each rib makes is extended tangentially, we obtain an ovoid form with two centers (*Illustration 2-8*). Each hemi-

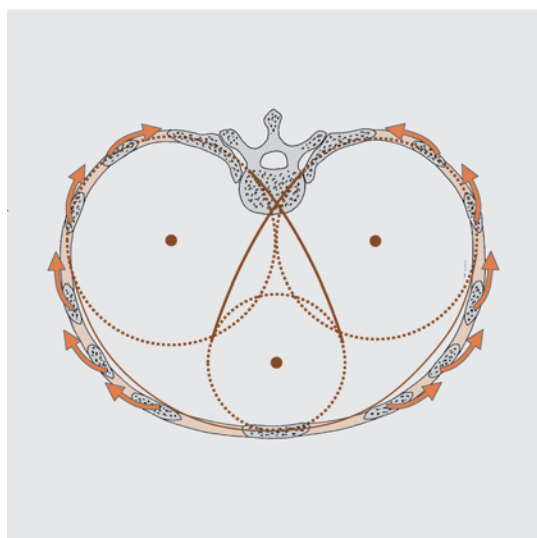


ILLUSTRATION 2-8

Horizontal Rib Rotation During Inhalation

thorax has a common anterior center and an individual posterior center. During forced inhalation, each rib rotates externally around its posterior center.

Most of these rib movements increase all the diameters of each hemithorax. The lungs, being elastic, will increase in volume during this external rotation and expansion. In fact, the extension of the arcs of the ribs represents the mediastinal pleura and hemithorax (*Illustration 2-8*).

The lung, which is fixed to the mediastinum, will be laterally stretched around the posterior center of the hemithorax (*Illustration 2-9*). On a pulmonary level, this center is made up of the segmentary apical bronchia for the upper lobe and by the bronchial tree for the rest of the lung. The position of the bronchial tree in the lung is logical, as it prevents the whole of the lung from being pulled in all directions during respiration.

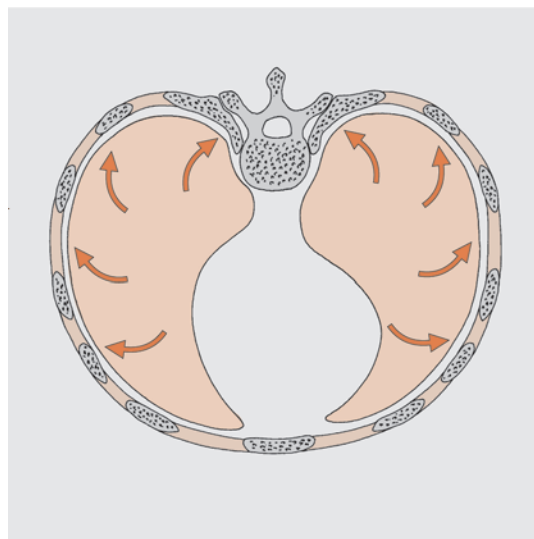


ILLUSTRATION 2-9

Pulmonary Expansion During Inhalation

All these rib movements are synchronous. The mediastinal pleura is fixed and the stretching of the pulmonary parenchyma follows an external rotational movement. Pulmonary expansion is maximal toward the

PHYSIOLOGIC MOTION

front for the upper lobes (pump handle) and toward the sides for the lower lobes (bucket handle). During mobility, the middle lobe on the right moves in the same manner as the upper lobe.

In the lower lobes, the bronchial trees are oriented obliquely laterally and inferiorly. External rotation of the lung during inhalation occurs in a plane perpendicular to this axis. Note that the left bronchus comes off the trachea less obliquely than the right (*Illustration 2-10*). The change in the axis of the lung is not restricting, because the resulting torsion is counteracted by the elasticity of the parenchyma and the sliding of the pleura and fissures.

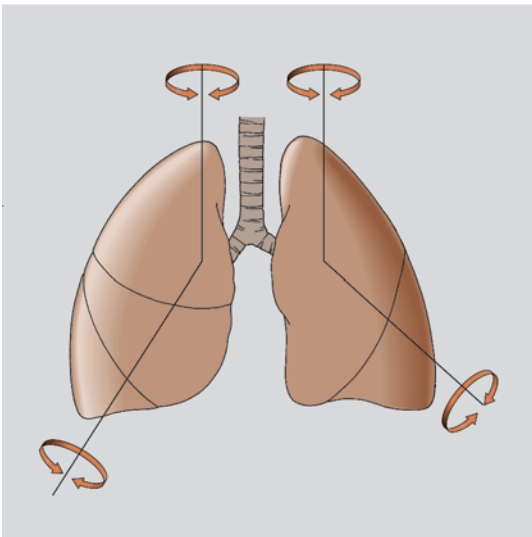


ILLUSTRATION 2-10

Lung Mobility

In conclusion, the mobility of the lung during inhalation is an external rotation of the parenchyma on a vertical axis for the upper lobes and on an obliquely inferolaterally directed axis for the lower lobes. Pulmonary expansion is possible owing to the tension of the lung ligament, the left bronchus (which fixes the visceral pleura to the mediastinum) and the suspensory ligament (which fixes this dome at the top).

Mediastinum

The mediastinum is made up of the heart and a set of tubes which transport air, blood, water and food. It is bounded by two sagittal mediastinal pleura laterally, the sternum anteriorly and the spine posteriorly. In this section, we will first describe cardiac mobility and then the mobility of the remainder of the mediastinum.

Heart movements are the most frequent (100,000 movements per day) of all autonomic movements. Apart from the vibrations, which spread to the adjacent viscera and are carried to all structures by arterial pulsations, we have detected no repercussions of this pump upon the thoracic viscera. The heart itself performs a powerful torsion (twisting) movement, which is put through a system of shock absorbers. From deep to superficial, this system consists of:

- the double-layered pericardium (which permits sliding)
- the pericardial stringy pouch (which prevents excessive dilatation of the heart)
- the mediastinal pleura
- lateral pulmonary pressure

During inhalation, the ligaments of the lung and bronchi exert an isometric tension on the lungs so that they do not move laterally as a block. One force (F1) resulting from the expansion of the right hemithorax and lung, is counteracted by an isometric tension (T1), created by the pulmonary ligament and the primary bronchus at the visceral pleura of the right lung. Similar forces F2 and T2 are applied to the left lung. Forces T1 and T2, being of equal force and in opposite directions, cancel each other out. The interpleural ligament, which is the union of the cul-de-sacs of both the aorta and esophagus, connects the right and left mediastinal parietal pleura. Forces F1 and F2 balance each other across the mediastinum and should remain

in equilibrium (*Illustrations 2-11-A and 2-11-B*).

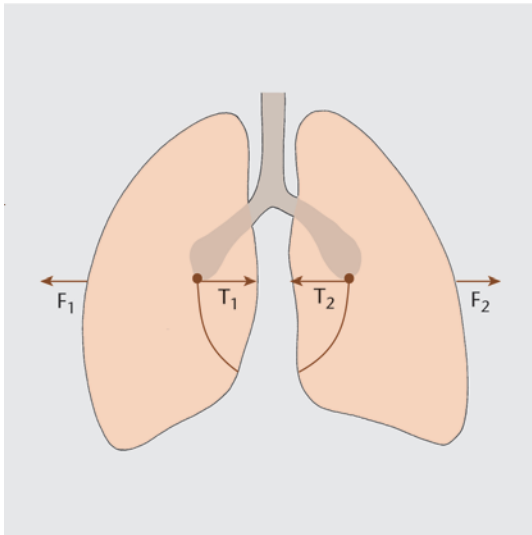


ILLUSTRATION 2-11-A
Traction on the Mediastinum

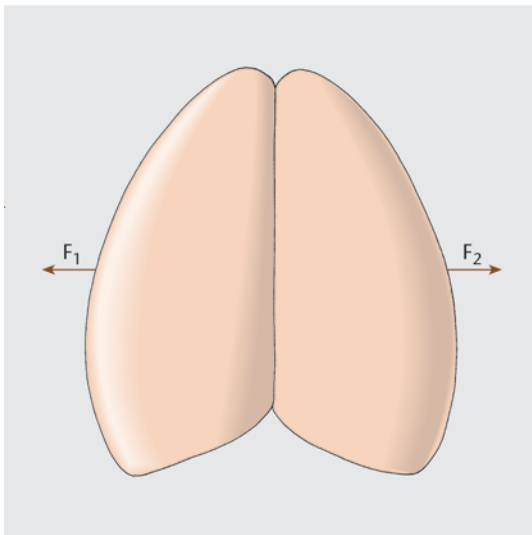


ILLUSTRATION 2-11-B
Schematic Representation of Mediastinal Tension

During inhalation, the diaphragm is lowered to enable the phrenic center to influence the viscera. By means of a change of pressure, the diaphragm will raise the ribs laterally. These are the basic effects of respiration on the thorax that we were taught in school.

In fact, the situation is a little more complex. The phrenic center certainly would have an influence on the visceral mass, but the vertical tension of the mediastinum intervenes. For purposes of visceral manipulation, the diaphragm is suspended from the mediastinum. Do you think that the phrenicopericardial ligaments exist in order to stabilize the heart and to keep it in place? Certainly not. They quickly fix the phrenic center when the diaphragm descends. The tension of these ligaments and therefore the mediastinum is extremely important in enabling the diaphragm to move around these fixed points, more so than the muscle's pressure on the visceral mass.

MOTILITY

Lungs

One reason for our belief that visceral motility has a close relationship with embryogeny (page 6) is that the lungs, during the motility cycle, retrace their movement during fetal development. The lungs are the last important organs to appear; they can be perceived at the end of the second month and from then on grow very quickly. They are originally posterior but move anteriorly on either side of the heart as they grow larger. After birth, when they have been expanded by the intake of air, their anterior aspects move entirely to the front. Likewise, motility is a pendulum-like motion with the lungs moving from a relatively posterior to a more anterior position.

The general motility of the lung is identical to its mobility, with a vertical axis of motion for the upper lobe and an obliquely inferolateral axis for the lower lobe. On the right, the middle lobe moves synergistically with the upper lobe. The axes coincide with the same structures, the bronchial trees. While "listening" for motility, it is easy to confirm by palpation the fact that the left

EVALUATION

crease the pressure, at first in a posterior direction. When your fingers can no longer move straight posteriorly, change to a posterosuperior direction. The more forward bent the patient, the deeper your fingers can go.

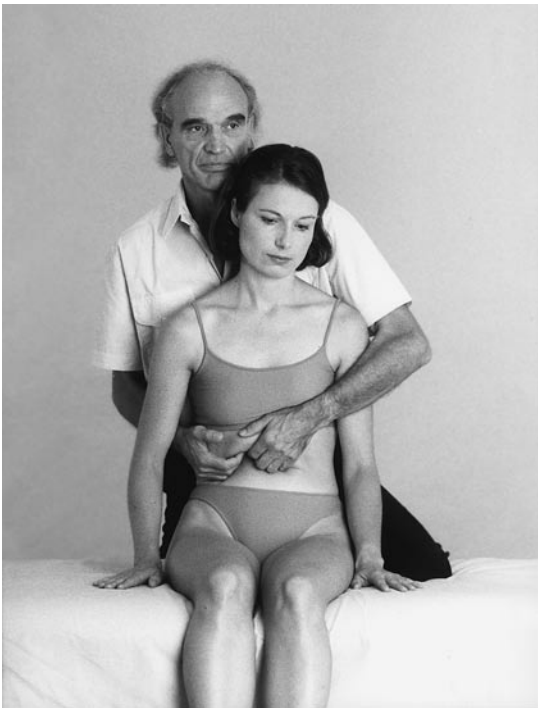


ILLUSTRATION 4-9

Direct Subcostal Approach to the Liver

Direct Tests

When you push the central part of the liver posterosuperiorly as described above, it should move by 1-2cm. Of all mobilizations, that of the liver is the most objective because no other solid organ directly interferes with or gets in the way of its movement. Depending on the location and direction of the pressure, you can test several structures of the liver. Many combinations and variations of the tests described here are possible.

Pushing the liver superiorly tests the level of restriction in the inferior structures. For example, excessive resistance to this movement could reflect a problem with

the hepatorenal ligament. Appreciating the amplitude and speed of the liver's return inferiorly, as you release the pressure, tests for restrictions in the superior structures. When there is a restriction, the return will be slower than normal and of a shorter distance. This test can be made more specific by modifying the direction of the push and the position of the patient. For example, sidebending the patient to the left and directing the posterosuperior push toward the right shoulder will allow a finer appreciation of any restrictions in the right triangular ligament.

The left triangular ligament can sometimes be evaluated fairly directly. Place your fingers just to the left of the xiphoid process. Sidebend and rotate the patient to the left as you come under and just posterior to the ribs. From this position, a pressure directed towards the left triangular ligament from your fingers should allow you to evaluate that structure.

To fully appreciate the sagittal or transverse motions of the liver, it is necessary to push in a primarily posterior direction. If you push your fingers directly toward the back, this will lift the posterior aspect of the liver and the organ will fall forward. A delay or decreased distance in the return of the liver in this situation is related to the function of the anterior part of the coronary ligament.

Indirect Tests

The elasticity of the lower ribs may be utilized for indirect evaluation of liver mobility. These tests may be done in a supine, left lateral decubitus or seated position. The ribs are compressed as you check for abnormal resistance. A feeling of normal costal elasticity but a resistance underneath them indicates some problem of liver mobility. Depending on the direction of costal compression, the areas of liver restriction can

be localized. However, these techniques are nonspecific because there are other possible reasons for abnormal rib movement, primarily musculoskeletal dysfunctions. Before testing the right side, you should test the left side for the purpose of comparison.

With the patient in the supine position, place the palm of your hand on the inferior anterolateral aspect of the right thorax and compress the ribs, pushing them anteriorly, inferiorly and medially. This technique should be painless and progressive. The shape of the thorax should be easily deformed (think of all the variation due to sex, body type and age). During the movement, place your other hand under the costal edge. Normally, except in children, the liver does not spill over the costal edge.

With the patient in the left lateral decubitus position, push the right costal mass anteriorly and inferiorly, using the same methods as in the supine position.

With the patient in the seated position, stand to his left. Surround the lower right ribs with your joined hands and compress the thorax, bringing it towards you, while at the same time rotating it first to the left and then to the right. The articulation tests of the costovertebral and costochondral joints

corresponding to the liver can be done in association with these tests.

MOTILITY TESTS

With the patient in the supine position, place your right hand flat over the hepatic region, fingertips above the sternoxiphoid line, pointing toward the left triangular ligament, and palm on the lateral part of R9-11 over the right lateral aspect of the liver. Your hand should follow the convexity of the rib cage; in order to concentrate better, it is a good idea to place your left hand on top of your right. You must be passive in order to be objective. If the motion is difficult to appreciate, or in order to free your mind, try visualizing the anatomy of the liver—this is a good way of becoming precise and of enhancing your perception. For the beginner, it is usually easier to palpate the motion during the expir phase.

In the frontal plane, during expir, your hand should rotate from right to left in a counterclockwise motion around an antero-posterior axis that passes just distal to the third knuckle of the right hand. In this motion the palm of the hand moves toward the umbilicus (*Illustration 4-10*).

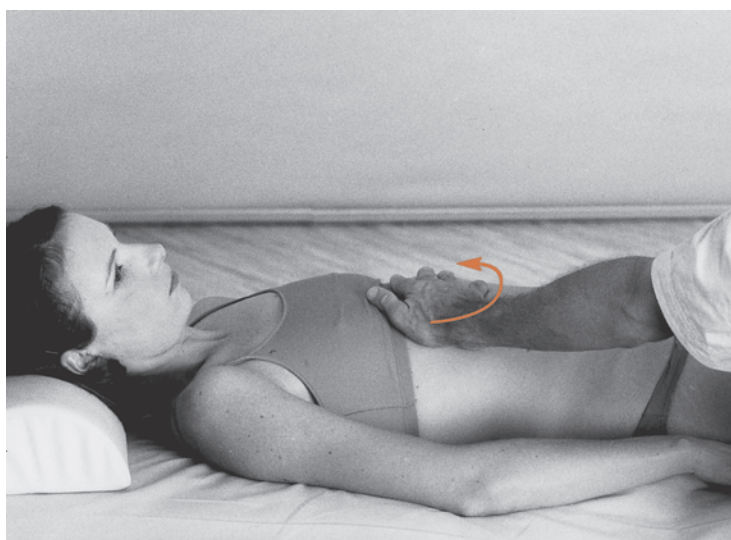


ILLUSTRATION 4-10
*Motility Test of the Liver—
Frontal Plane*

RESTRICTIONS



ILLUSTRATION 4-11
*Motility Test of the Liver—
Sagittal Plane*

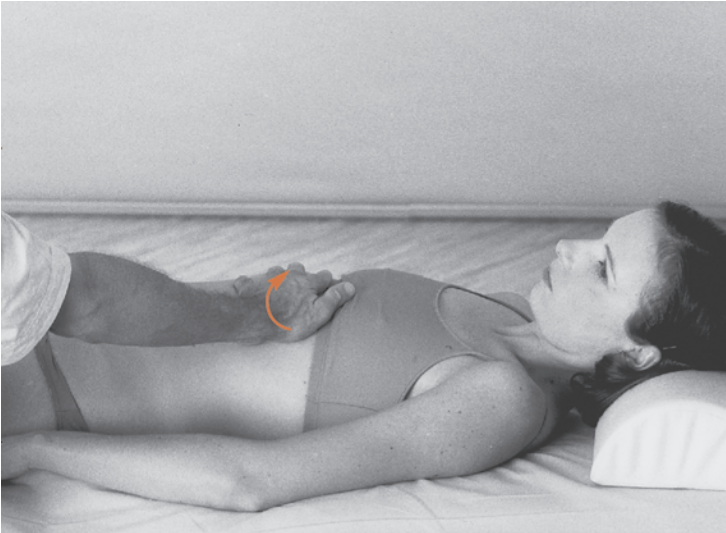

ILLUSTRATION 4-12
*Motility Test of the Liver—
Transverse Plane*

In the sagittal plane, during expir, the superior part of your hand rotates anteriorly and inferiorly around a transverse axis through the middle of the hand. The inferior part of your hand rotates in a similar manner and therefore seems to press harder against the body (*Illustration 4-11*).

In the transverse plane, during expir, your hand rotates to the left around a vertical axis that passes through the knuckles of the sensing hand. This seems to bring the palm away from the body while the fingers press in harder (*Illustration 4-12*). After you become comfortable testing these different

planes one at a time, you can test them all simultaneously for a more complete appreciation of the motility of the liver.

Restrictions

There are many types of restrictions involving the liver; we will mention some common ones. With hepatitis the liver will feel tight, while in cases of chronic obstructive lung disease it will feel heavy. Occasionally a total fixation of the liver can create a fibrosis of its supporting ligaments; this is common

in cases of cirrhosis. During direct mobilization techniques you can feel these restrictions let go little by little, occasionally with a crackling sound. It is a marvelous sensation and reinforces one's appreciation of the efficacy of this technique. Posterior restrictions are common, perhaps because of the pleuropulmonary relationship. Every pleural problem directly affects the mechanics of the liver through restriction of its connections with the diaphragm. For this reason, it is imperative to check the motions of the liver in the aftermath of pulmonary diseases, and vice versa.

Manipulations

Manipulations to improve mobility should usually precede those to treat problems of motility. Frequently, a dysfunction in the liver will not involve the gall bladder, and vice versa. If both organs are involved, treat the gall bladder first.

DIRECT TECHNIQUES

Seated Position

As noted above, mobilization of the liver with the patient in a seated position enables you to release restrictions as far toward the back as possible. The direct technique is just a rhythmic, slow (approximately 10 per minute) repetition of the diagnostic technique; it involves evaluating the quality of motion by lifting the liver posterosuperiorly in a gentle and progressive manner by 1-2cm and then releasing it. The motion is inversely proportional to the amount of restriction in the coronary ligament; the more severe the restriction, the less the excursion (*Illustration 4-13*). As the technique is repeated, the ligament will release (sometimes with a popping sound). Five to six repetitions should suffice. It is better to begin with the external part of the liver (the most mobile) at the level of the

colonic impression in order to first release the tension of the hepatic flexure of the colon via the right phrenicocolic ligament. Then move toward the falciform and stomach areas where, to treat the area of the left triangular ligament, the fingers should be pushed superiorly and laterally. To work on the entire liver at once, put one hand medially and the other laterally. As you move your fingers to work on different areas, adjust the position of the patient to focus your effects on those areas.

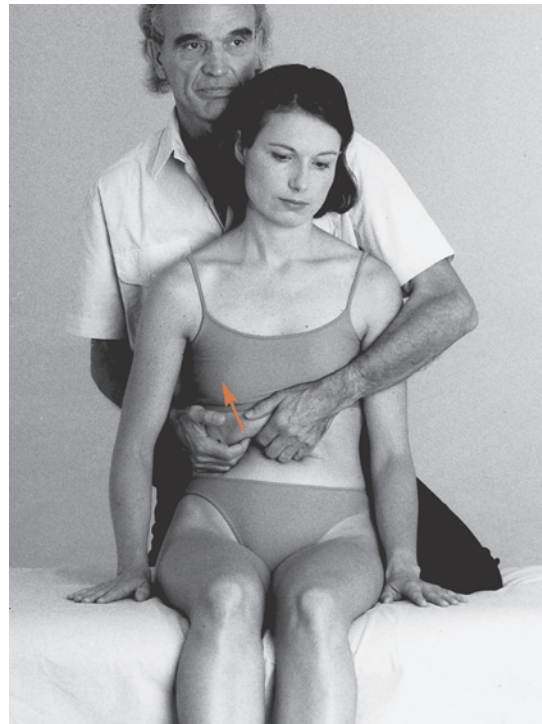


ILLUSTRATION 4-13

Direct Manipulation of the Liver—Seated Position

This is very similar to manipulations for the stomach (see chapter 5). Of course, all the organs and structures attached to the liver are affected by this technique. When the tension of the anterior organs is released, the liver must be pushed up; you can then direct your fingers more toward the back to try to reach the anterosuperior part of the kidney, if desired.

MANIPULATIONS

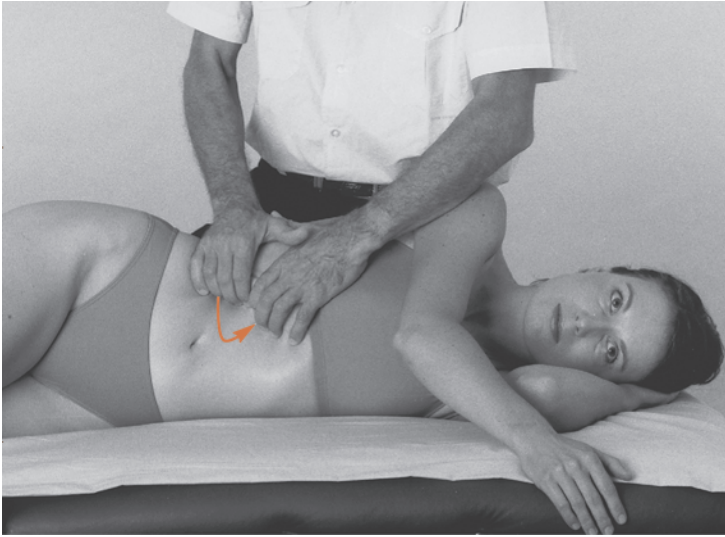


ILLUSTRATION 4-14

*Direct Manipulation of the Liver—
Left Lateral Decubitus Position*

Left Lateral Decubitus Position

Place yourself behind the patient and put the palms of your hands on the anterolateral extremities of R7-9, with the pads of the fingers subcostal. Push the ribs anteriorly, inferiorly and medially (toward the umbilicus) and then in the opposite direction, in a slow back-and-forth cycle of around 10 per minute with steadily increasing amplitude (*Illustration 4-14*). It is not necessary to synchronize the movements with respiration. You can adjust the technique so that it focuses on motion in one particular plane. For frontal plane motion, push the ribs toward the umbilicus with more movement of the lateral aspects. For motion in the transverse plane, roll the ribs toward the midline. For sagittal plane motion, press your thumbs together on the posterior axillary line and use your fingers to rotate the ribs forward. Recoil (pushing medially and anteriorly in all planes and then releasing suddenly) can also be performed here.

This technique moves the ribs, pleura, peritoneum and liver and is a good general mobilization which is tiring for neither you nor the patient. It is especially useful in patients who have had hepatitis. In general, however, techniques performed through the

abdominal wall are more effective. Techniques which work through the ribs are used primarily when the abdomen is too tense, or as an adjunct.

Emptying of the Gall Bladder

Place the patient in a seated position and stand behind him with your fingers subcostal, just lateral to the gall bladder, as here the abdomen is more easily depressed. Flatten your fingers well against the inferior side of the liver and be careful not to confuse the gall bladder with the first part of the duodenum or the transverse colon. The superior duodenum is not sensitive to palpation, whereas the gall bladder often is. For this reason, first look for tender points in this area. You can easily reach the bottom of the gall bladder, which has a relatively anterior position. To force it to contract (and expel the bile or sediments which could be in it), push your fingers rhythmically with a moderate amount of force in short (2-4cm) strokes superiorly, posteriorly and medially along the long axis of the gall bladder. As you continue, the gall bladder will become less sensitive. This is the first sign of an effective treatment. If the gall bladder is tender it is important to do this technique gently at first (4-8 times) until the tenderness has dis-

sipated and then increase your force. At this point, change the direction of your force to inferior, posterior and medial to release the neck of the gall bladder. Repeat this motion until there is a release.

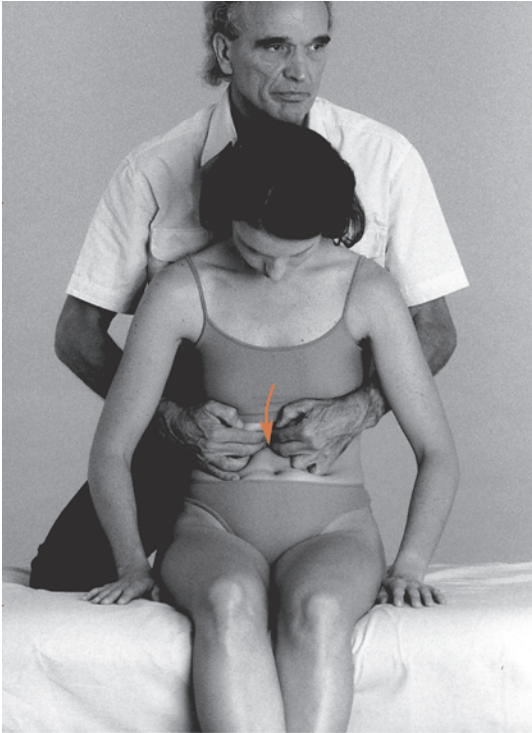


ILLUSTRATION 4-15

*Manipulation of the Common Bile Duct—
Seated Position*

In cases of cholelithiasis, there are risks of microhemorrhages or parietal inflammation if you press too hard. If the pain is too sharp, release the pressure and use your fingers gently and carefully. In the case of cholecystitis, carry out an antispasmodic movement like those done for the pylorus of Oddi's sphincter (see chapter 6). After the spasm decreases, you can increase your pressure or continue with the technique described previously.

Manipulation of the Common Bile Duct

Following the emptying of the gall bladder, flow in the bile ducts needs encouragement.

The common bile duct (a smooth canal with only one sphincter at its opening into the duodenum) has fibromuscular walls and is able to reduce the size of its lumen. Its optimal function therefore depends on appropriate tone.

Use the seated position (*Illustration 4-15*) which increases the patient's kyphosis and enables you to reach the deeper areas. The common bile duct is found very far back, posterior to the duodenum, at the T11/12 junction near the vena cava and epiploic foramen. Lower down, it is posterior to the pancreas. You therefore have to work on the most accessible part, which is that posterior to the duodenum. The anterior projection of the duct behind the duodenum is on the midclavicular-umbilical line, two fingers' width under the edge of the rib cage. Sometimes sidebending the patient to the left makes it easier to work on the duct. Push your fingers or thumbs toward the back and, when you have gone as far as possible, gently stretch your thumbs downward toward the umbilicus and release the pressure very slowly. Repeat this procedure slowly and rhythmically. When you have become comfortable performing this movement, you can add an oblique lateral to medial direction to it which results in an arc (*Illustration 4-15*). This movement often provokes a characteristic discharge sound from the body. For best results, continue downward bit by bit toward the sphincter of Oddi as you feel each part of the duct relax.

For a patient in the supine position with knees flexed, stand at the patient's right. Press your thumbs or palm at the point on the abdomen described above (overlying the common bile duct and the duodenum), first toward the back, then toward the feet and slightly to the left (*Illustration 4-16*). This movement is more difficult to perform and demands greater precision than that performed in the seated position, as the aid of gravity is not enlisted.

MANIPULATIONS

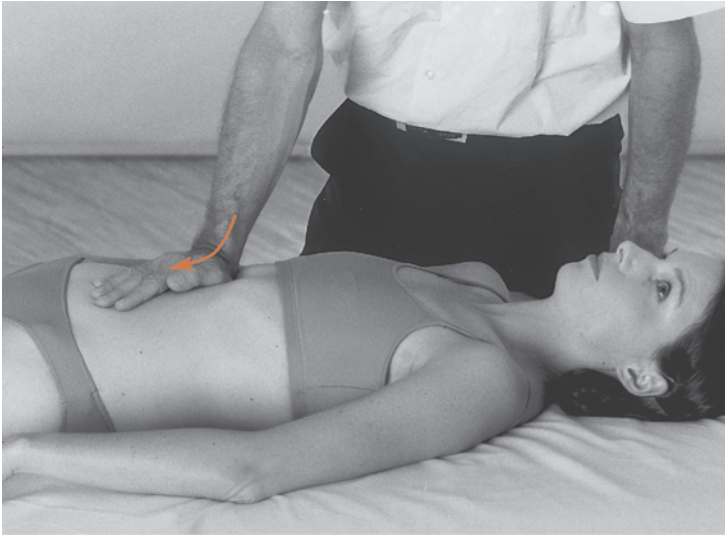

ILLUSTRATION 4-16

Manipulation of the Common Bile Duct—Supine Position

COMBINED TECHNIQUES

Seated Position

This is a variation on the direct technique in the seated position. As before, press your fingers against the lower border of the liver, preferably with one hand placed medially and the other laterally in order to appreciate the whole liver. Next, lean on the patient's shoulders and maneuver the body into the position where maximal stretching occurs for the area you wish to focus on. The direct aspect (short lever) is the hand or hands on the abdomen. The indirect aspect (long lever) is the use of a distant part, the shoulders, for positioning to influence the target area.

Using this positioning, the torso can be “played with” to find the correct position or series of positions to release restrictions of the liver. The patient, who feels safe and relaxed under the control of the practitioner, lets go and moves freely. The thoracic movement allows a precise multidirectional treatment to take place effectively and without pain. For example, left rotation and right rotation of the torso cause your fingers to be positioned more posteriorly or anteriorly, respectively. If the patient leans forward, you

can reach the posteroinferior region more easily; if he bends to the side, you can reach the opposite side more easily.

Let us take the manipulation of the left triangular ligament, which is one of the more difficult ones, as an example. The patient must be bent forward in order to bring your fingers as far posteriorly as possible and then sidebent to the right while you push your fingers as far as possible toward the left. Maintain this pressure and the position of your hands while the patient sidebends to the left, which brings the left extremity of the liver inferiorly. This makes it easier to raise this part of the liver with your hands. Utilizing these movements of the torso, many combinations of techniques are possible (*Illustration 4-17*). This is an extremely useful technique and can be adapted for use on the gall bladder or common bile duct.

Another helpful combined technique stretches the common bile duct. It is usually applied after the direct release of the duct and before treating the sphincter of Oddi. In the kyphosed seated position, fix the duct just superior to the sphincter by a strong posterior pressure. While maintaining this pressure, extend and rotate the patient's torso to the right, which increases the dis-

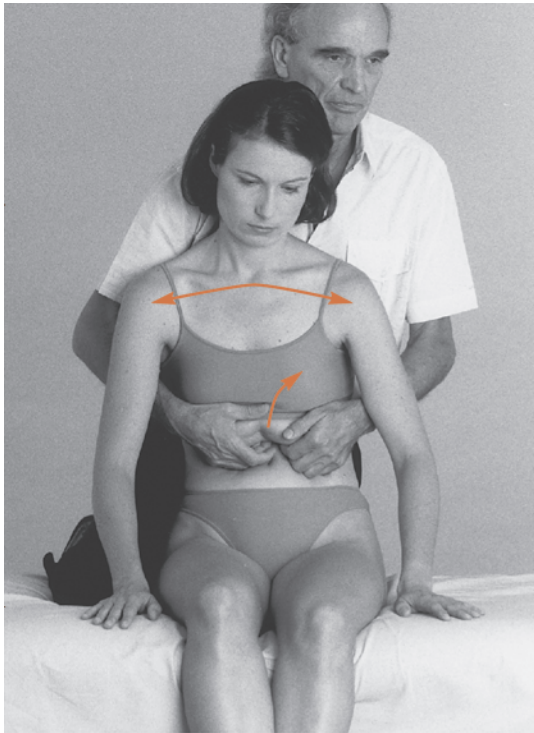


ILLUSTRATION 4-17

Combined Manipulation for Release of Left Triangular Ligament—Seated Position

tance between the fixed point and the diaphragm/liver. This effectively stretches the entire duct. Repeat this technique 3-5 times until you sense a release. The movement can

also be done via the patient's elbows, with his hands clasped behind his neck.

Supine Position

A similar technique can be performed with the patient in the supine position. The short arm lever is as described above, but the long arm lever is accomplished by utilizing the lower extremities. With both the hips and knees flexed, the lower extremities can be rotated and/or sidebent to get to the position necessary for greatest effect (*Illustration 4-18*). If you perform rotation and sidebending to the right, there is a compression effect on the liver. Sometimes this can lead to a point of balanced tension that will result in a very significant release. If the movements are performed to the left, then the result is a stretching of the structures concerned.

The choice between the seated and supine positions will depend on personal preference, circumstances and whatever is more comfortable for you and the patient. However, one or the other may give more optimal results in a particular situation, since the structures through which the long lever is working differ. In the seated position, the long lever is working through the

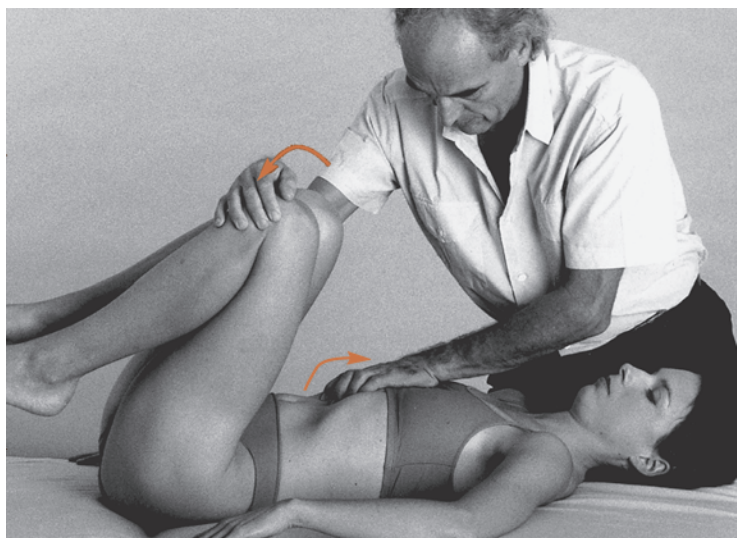


ILLUSTRATION 4-18

Combined Manipulation of the Liver—Seated Position

MANIPULATIONS

lungs, pericardium and diaphragm; if there are associated problems or restrictions with those tissues, this approach will give the best results. In the supine position, the primary viscera being used as levers are the kidneys and colon; this technique is preferred if there are associated problems or restrictions in these organs.

INDUCTION TECHNIQUES

Liver

These induction techniques are performed in the supine position to give the treating hand the largest possible contact with the right thoracoabdominal surface. Your fingertips should be placed as close to the left triangular ligament as possible, with the hand on the rib cage and its ulnar aspect just extending onto the abdomen.

For learning purposes, it is advisable to go over the motions of motility in the different planes one at a time. We will describe the technique for inducing expir in the different planes. Remember that in induction you work by encouraging the part of the motility cycle which is easiest and has the greatest amplitude. If the motion of inspir were greater, you would then encourage it

by doing movements opposite to those described below.

In the frontal plane, the motion of the liver is along the line of the falciform ligament. The superolateral part of the liver moves inferomedially toward the umbilicus during expir (*Illustration 4-19*). For induction, follow the lateral edge of the liver on the arc of a circle toward the umbilicus, approximately once every 10 seconds. This is usually the most easily palpable aspect of liver motility and you should familiarize yourself with it. It is important in induction to encourage the motion in precisely the right direction. During motility, if you try to push the organ in the wrong direction, it will stop moving. This stoppage differs from the still point in that as soon as you let go the motion will resume, but with no improvement. The motion of expir is more forgiving than that of inspir.

In a sagittal plane, as the liver turns on a transverse axis during expir, the superior part rolls anteroinferiorly. From the position described above, encourage this motion by supinating the hand on the abdomen (*Illustration 4-20*). To get a better feel for this motion, try putting one hand posteriorly and one anteriorly, pronating the former and supinating the latter.



ILLUSTRATION 4-19

*Induction of the Liver in Expir—
Frontal Plane*

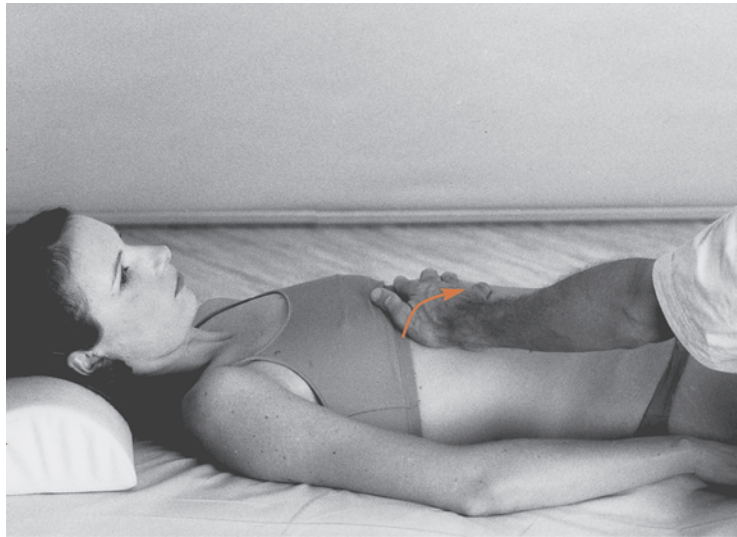


ILLUSTRATION 4-20
Induction of the Liver in Expir—Sagittal Plane

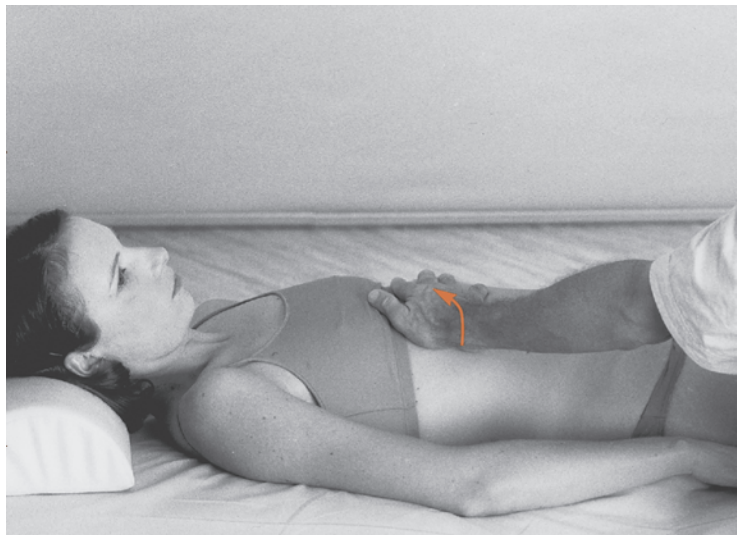


ILLUSTRATION 4-21
Induction of the Liver in Expir—Transverse Plane

In a transverse plane, you must follow and encourage the liver's motion in expir around a sagittal axis. From the same position, push or pull the lateral aspect of the rib cage anteromedially with the palm of the hand while your fingers push the medial aspect posteriorly (*Illustration 4-21*). This accentuates the rotation to the left of the external edge of the liver.

When these induction movements are to be combined, first induce the motion in the frontal plane, as it is the primary motion of this organ and easiest to appreciate.

After feeling this confidently, add the

motions in the sagittal plane and finally the transverse plane. In clinical practice, this is the most common way to perform induction of the liver.

Common Bile Duct

Induction of the common bile duct is performed in the supine position and is similar to the direct technique described above. Gently press the heel of your hand or fingers just underneath the rib cage, on the mid-clavicular-umbilical line. Do not push hard enough to reach the duct; induction does

Evaluation

Again, the history is of primary importance and should enable you to differentiate important functional syndromes from structural problems. It is essential, when there is any doubt, to consult a gynecologist and perform any necessary test or examination. Perhaps in this area, more than any other, you must be able to recognize your own limitations.

The bimanual pelvic exam allows you to appreciate various uterine positions, differences in endometrial elasticity, the possibility of pregnancy, etc. You should be able to easily and painlessly mobilize the uterus during palpation.

The intrarectal exam enables you to feel the position of the cervix, the pressure states of the different cul-de-sacs and the tension of the cervicosacral attachments. We shall discuss this exam more fully, in relation to the coccyx, in chapter 11.

Laboratory examinations are indispensable if there is any doubt as to the etiology of symptoms. These include simple ultrasound as well as colposcopy. Most women are examined regularly by a gynecologist, and undergo an annual pap smear, which

considerably limits the risks of a late discovery of neoplasia. You should always be aware of the considerable risk of neoplasia in the urogenital region.

MOBILITY TESTS

Abdominal palpation is performed with the patient in the supine position, legs bent and feet on a cushion to increase flexion of the hip. The aim is to approach the fundie region laterally in order to check the mobility of the uterus. Place the fingers just above the pubic symphysis on the inferior origin of the rectus abdominis muscles in order to direct them posteriorly on the bladder. The more the legs are bent, the more deeply you can go into the pelvic cavity. You can even actively bend the legs to increase the efficiency of your palpation (*Illustration 10-3*). To reach the uterus, you need to go via the abdominal wall, the loops of the small intestine, or the bladder, depending on their position in the body.

The mobility of the ovary and broad ligament is tested in either the lateral decubitus or reverse Trendelenburg position with the hips and knees flexed. Starting at the ASIS, push your hand posteriorly and, when you



ILLUSTRATION 10-3

*Mobility Test of the Uterus—
Abdominal Route*

EVALUATION

have gone as far back as possible, move it toward the symphysis. Evaluate the elasticity of the tissues and note zones of adhesion, always comparing one side to the other. If you lose your place, ask the patient to contract the psoas muscle, which can serve as a reference.

For bimanual palpation, place two fingers into the vagina and the other hand on the abdomen facing the fundus. The two hands act together to test the mobility of the uterus and ovaries (*Illustration 10-4*). In the case of a serious retroversion, the abdominal hand will not be of much help, as the fundus will not be palpable.

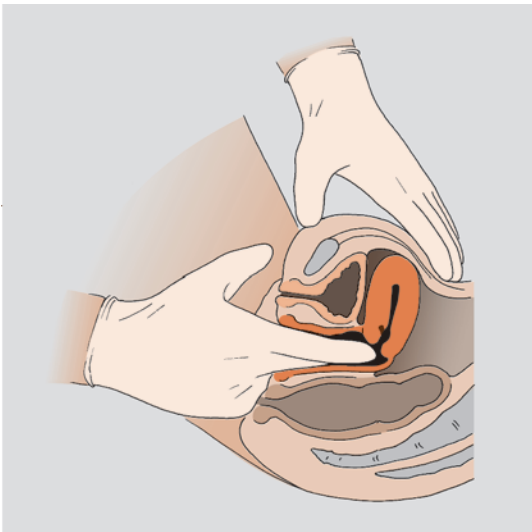


ILLUSTRATION 10-4

Mobility Test of the Uterus—Bimanual Palpation

Rectal palpation is performed in the prone position. When your finger reaches the level of the sacrococcygeal articulation, push it forward and, via Douglas' pouch, it will contact the uterus. If the uterus is retroverted, you will feel a round hard mass which prevents your finger from moving forward. When in a normal position, the cervix shows little resistance to digital pressure and is easily movable.

The sacral pressure technique provides an easy method for distinguishing musculoskeletal sacral and sacroiliac restrictions from those resulting from tightness of the uterosacral ligaments. With the patient prone, push the sacrum anteriorly with the heel of your hand at the S2/3 region. If there is no movement, there is a musculoskeletal restriction. To be more precise, test the three (superior, middle and inferior) areas of the sacrum. If the sacrum moves anteriorly but has difficulty in returning posteriorly or does so slowly, there is a restriction in the uterosacral ligaments. When the return motion has a rotatory nature, there is a restriction on one side (usually the side toward which it rotates).

Normally, the uterus leans on the bladder. Vesicouterine mobility can be tested by lifting the bladder via the median and medial umbilical ligaments. One cannot separate the bladder from the uterus, but a force applied to one automatically has an effect upon the other. The patient can be lying down or seated; we prefer the latter position because the test is facilitated by gravity (see pages 165-166).

MOTILITY TESTS

The test for the uterus is similar to that for the bladder. The patient is supine with knees bent. Place the palm of one hand over the pubic symphysis with the fingers pointed toward the umbilicus. During expir, the back of the hand moves toward the umbilicus (the fingers move posteriorly while the heel of the hand moves anteriorly) (*Illustration 10-5*). For a fuller appreciation of uterine motility, place your other hand under the sacrum with the fingers under the base and the heel of the hand under the apex. In expir, that hand should move anterosuperiorly (the base of the sacrum moves posteriorly and the apex anteriorly).

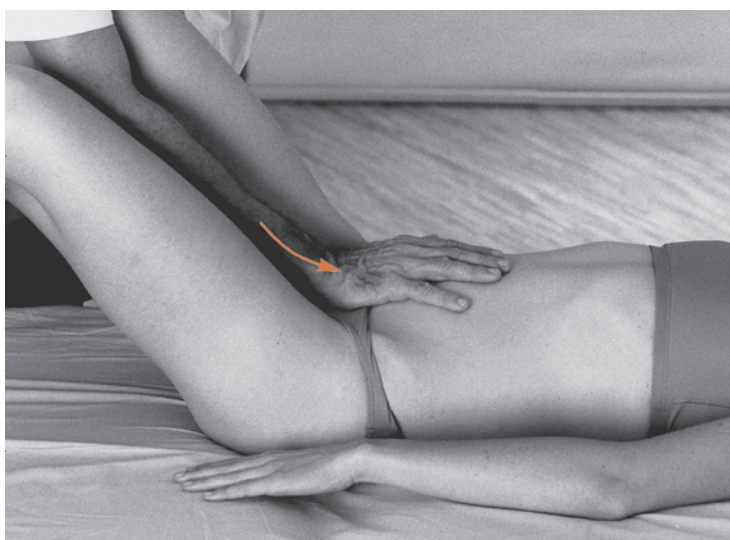


ILLUSTRATION 10-5

Motility Test of the Uterus

The motility test for the ovaries is performed with the patient in a supine position. Place the palm of the hand between the ASIS and the symphysis, fingers directed superiorly and slightly laterally. During inspir, the hand will rotate laterally and move slightly superiorly (a clockwise rotation on the left, counterclockwise on the right). Once you are able to feel this motion comfortably, you will also be able to feel the lateral edge of the hand move posteriorly, with a small component of external rotation. The opposite motion occurs during expir.

Restrictions

Possible restrictions range from a partial absence of mobility to a total collapse of the reproductive system, and we cannot describe them all. The reproductive system is dynamic; it is not held together by simple ligaments stretched out like pieces of string. Nearly the entire system of attachment is based on contractile fibers; the broad ligaments, round ligaments, parametrium, subperitoneal tissue, sagittal peritoneal folds and pelvic floor all contain some contractile muscle fibers. For this reason, induction is most effective on the reproductive sys-

tem—it is much easier to induce a release in a muscle than a ligament. It seems that, on a pelvic level, problems with motility involve the tonicity of the contractile fibers more than their mobility.

Scars from abscesses or surgery, as well as microadhesions from infectious processes, disrupt the motion of the reproductive organs. Small twists or spasms can reduce or close the abdominal ostium and interfere with the complex phenomena of ovulation and fertilization. Miscarriages, abortions and ectopic pregnancies can all cause serious tubal adhesions. Reflex spasms are complex phenomena and depend on both local conditions and systemic states. For example, emotional upset during hysterosalpingography can prevent passage of the contrast material. This demonstrates that the fear of being infertile can interfere with the effort to become pregnant.

Manipulations

In manipulations of the pelvic organs, a good general rule is to treat the abdominal organs first. For example, you should clear up any problems of the small and large intestines before beginning work on the uter-

MANIPULATIONS

us. Also, be sure that the patient urinates before treatment.

CONTRAINDICATIONS

A patient who has an IUD or is pregnant should not have genital manipulation under any circumstances. All infections and hemorrhagic symptoms necessitate much care and a precise diagnosis. Do not proceed if you have any doubts.

DIRECT AND COMBINED TECHNIQUES

The direct technique in the supine position is similar to the mobility test; the patient has her feet raised on a cushion in order to increase hip flexion, release muscular tension and increase the depth of the field to be palpated. Begin by pushing or pulling the fundus from side to side with a translatory movement to effect a local release. This is an efficient defibrosing technique, and should be repeated about ten times, gently and rhythmically without irritating the tissues, until a release is felt. If a release does not occur after 10-15 cycles, either the problem is someplace else or you are doing

the technique incorrectly. In any case, stop, as further treatment will only irritate the local tissues. You can increase the efficiency of the stretching by sidebending the lower limbs on the pelvis. Fix a point (preferably a point of restriction) of the lateral vesico-uterine region and focus on it more clearly by sidebending around it to the opposite site by using the lower limbs. This produces an excellent local stretch. This technique is especially effective on the broad ligaments and tubo-ovarian adhesions.

In the lateral decubitus position, the patient has the hips and legs flexed on the body to release the abdominopelvic wall. Depending on the restriction, either stretch the lateral aspect of the uterus closest to you by pushing down with your thumbs, or bring the opposite region toward you with your fingers (*Illustration 10-6*). Repeat this gently and rhythmically until you feel a release.

In the reverse Trendelenburg position, use the technique described for the supine position, with the addition of an antigravitational component. That is, the hands mobilize the uterus superiorly as well as laterally (*Illustration 10-7*). This is the most effective technique in cases of urogenital ptosis.

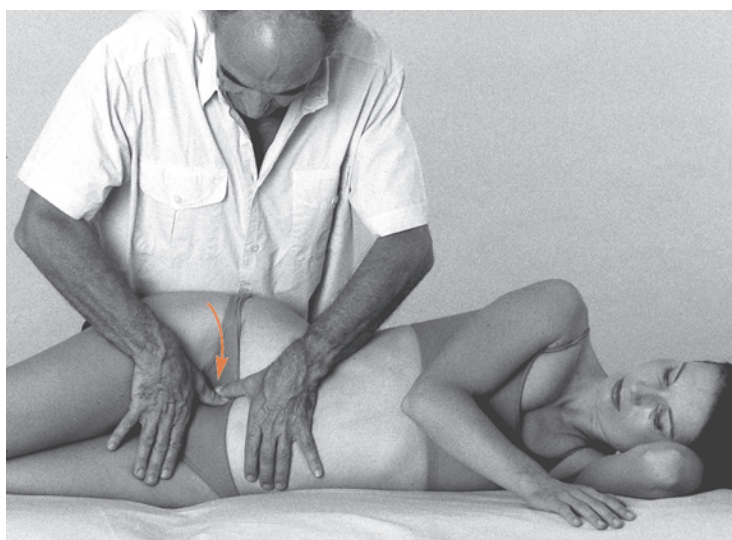


ILLUSTRATION 10-6

Manipulation of the Uterus via the Abdominal Route—Lateral Decubitus Position

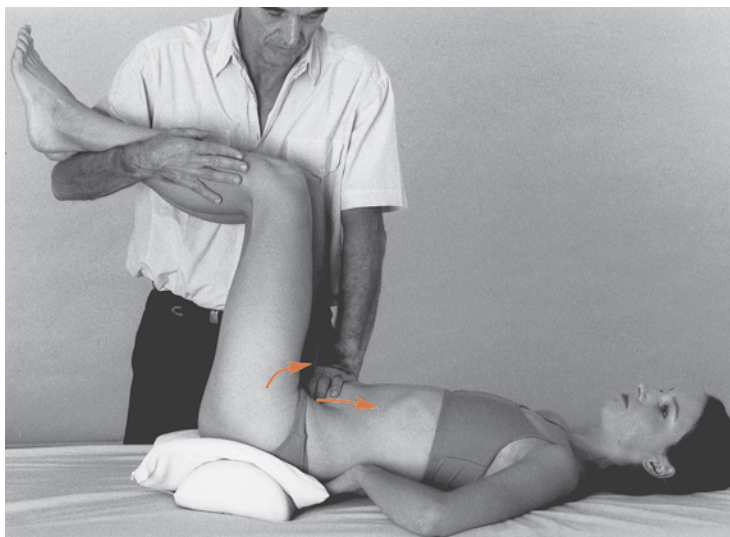


ILLUSTRATION 10-7
*Manipulation of the Uterus
 via the Abdominal Route—
 Reverse Trendelenburg Position*

In the seated position, the technique is similar to that for bladder restrictions. Place your fingers just above the symphysis to pull the median and medial umbilical ligaments upward. To increase the stretching effect and thus the efficacy of the technique, bend the patient backward to increase the distance between the xiphoid process and the symphysis (*Illustration 10-8*). This technique releases pressure from loops of the small intestine which often contribute to ptosis of the pelvic organs. This is an example of the general rule to clear what is above before attacking problems in the pelvis.

INDUCTION TECHNIQUES

For uterine induction with the patient in the supine position, place the palm of your hand just above the symphysis and then push it posteriorly as if you wished to go under the pubic bones. Gradually direct your hand upward. This technique can also be performed with one hand under the sacrum, which should move in the opposite direction (anteroinferiorly) to create opposing forces. This technique is intermediate between direct pressure and induction in terms of force, and enables overly tight uterosacral

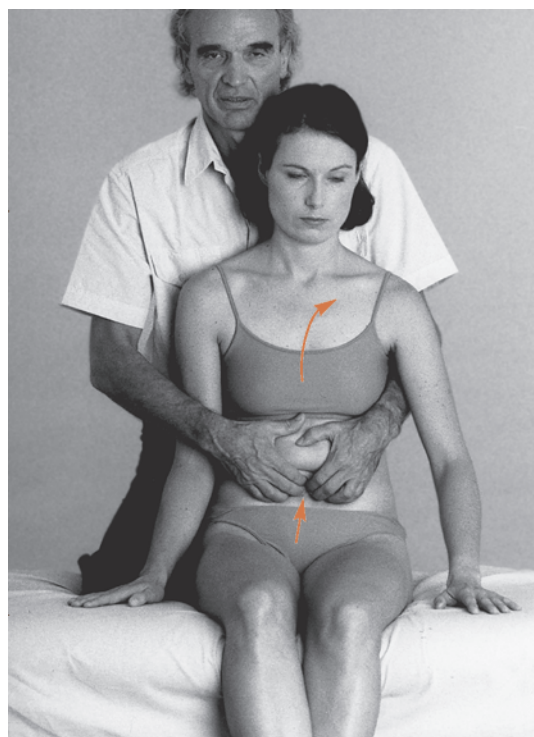

ILLUSTRATION 10-8
Vesicouterine Manipulation—Seated Position

structures to relax. For lax structures, we do short and rapid stretching in an attempt to stimulate them. We have to admit, however, that while our methods can produce beneficial changes temporarily in cases of

EFFECTS

lax structures, it is difficult to maintain the changes.

With the lateral decubitus position, place one hand above the symphysis and the other on the sacrum. Carry out an anteroposterior induction/pressure in the same directions as in the preceding technique (*Illustration 10-9*). The advantage of doing the technique in this position is that it frees the hand on the sacrum (in the supine position, the hand is squashed by the patient's weight), and enables you to easily combine movements in all three planes.

With the vaginal bimanual technique (page 181), you can free uterine fibroses and, above all, stretch the cul-de-sacs. This technique should be performed gently and rhythmically, and a release should be felt after five or six cycles. In order not to confuse the doctor-patient relationship, this technique should not be needlessly prolonged.

Induction via the rectal route is definitely the most effective technique for manipulation of the sacral structures and the release of Douglas' pouch. The intrarectal finger should push the cervix anteriorly and make the sacrococcygeal unit move posteriorly. This technique is described in detail in

chapter 11.

Manipulation of the uterine tubes and ovaries must be gentle. For this reason, we prefer using induction on them to avoid the risk of damaging the fragile structures involved. With the patient in the supine position with legs bent, place the palm of your hand on the line between the median axis and the left or right ASIS, depending on which side is being worked on. For the left ovary, the palm of the hand moves slightly superolaterally during inspir and then performs a clockwise rotation (*Illustration 10-10*). Manipulation of the ovaries must always be accompanied by manipulation of the uterus; the uterus is usually treated first as it is made up of stronger tissues.

Effects

All serous membranes tend to undergo adhesions after certain inflammatory problems. The female pelvic organs are very vulnerable to these inflammatory processes and tend to often ptose or congest. The effect of our techniques is to defibrose, decongest, raise and remobilize the reproductive organs. Whenever there are scars, restrictions of mobility or poor circulation, urogenital ma-

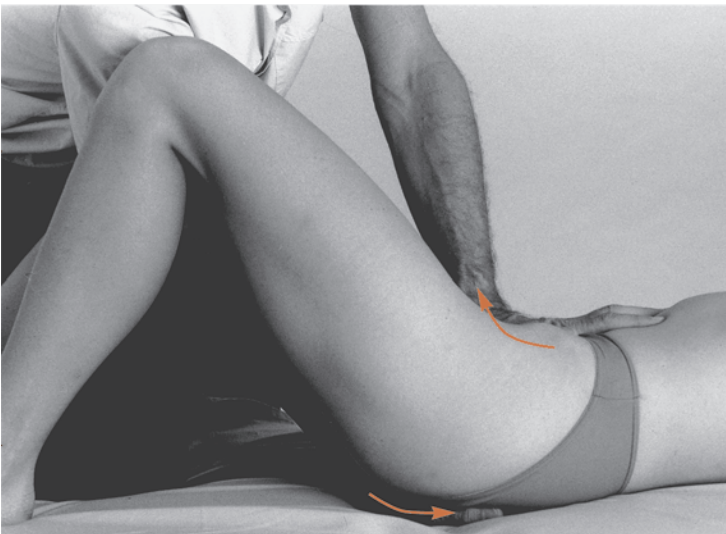

ILLUSTRATION 10-9

*Uterosacral Manipulation—
Lateral Decubitus Position*

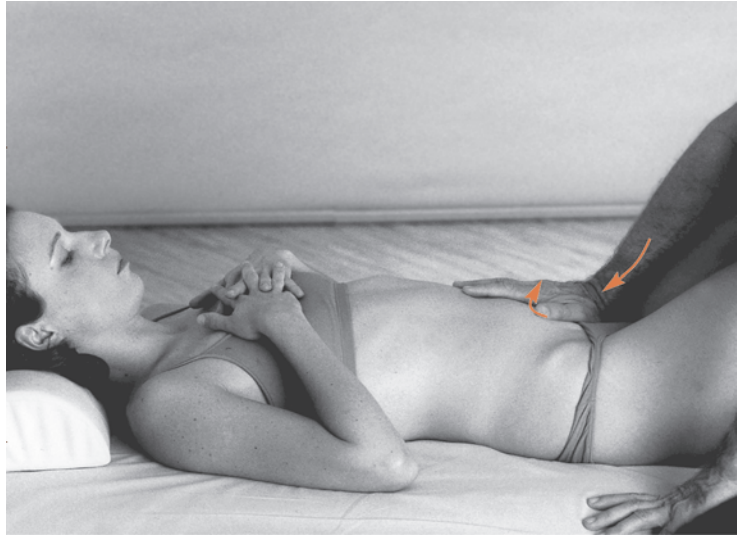


ILLUSTRATION 10-10
Tubo-Ovarian Induction

nipulation is useful. The more intense and chronic the suffering, the better the results. This type of case forms a major part of our own practices; one of us (Barral) has treated over five thousand women for gynecological problems.

The aim of the tubo-ovarian manipulations is to increase or restore local mobility; any idea of using a strong force must be abandoned. We are practicing visceral clock making—even a slight fold of the fimbriae, bend in the tube, bad orientation of the ostia or uterine sidebending can be enough to block pelvic fluid circulation and inhibit the process of fertilization.

We believe that we have resolved several cases of infertility through visceral manipulation, although this kind of result can never be strictly evaluated scientifically, as too many parameters are involved. Our best results have occurred with patients who came in for a different problem. In any case, it seems very reasonable to attempt to harmonize and release the soft tissues of the pelvis before performing complicated and expensive testing procedures.

After intravaginal manipulations, it is not uncommon for there to be a slight salmon-colored bleeding for a few days. This is a

transient problem and will resolve without further intervention. Be sure to check the area posterior to the cervix, as many important and surprising things (old secretions, remnants of yeast infections, condoms, etc.) can be found here.

Adjunctive Considerations

ASSOCIATED OSSEOUS RESTRICTIONS

Lumbosacral vertebral restrictions are almost always found in patients with urogenital problems, either due to reflex or mechanical effects. Reflex knee pain may be provoked by an irritation of the genitocrural nerves from problems of motion inside the pelvis. Hormonal disorders are frequently responsible for reproductive problems. In this case, the vertebral restrictions are localized in the superior cervical area, perhaps because of their relationship with the hypothalamic-pituitary axis.

RECOMMENDATIONS

Be aware of the patient's menstrual cycle—the best time to use manipulation is at the