

Regional Attenuation WithOut Delta (RAWOD): A distinctive EEG pattern that can aid in the diagnosis and management of severe acute ischemic stroke

Anita L. Schneider, R. EEG/EP T., CNIM and
Kenneth G. Jordan, M.D., FACP

*Jordan NeuroScience, Inc.
San Bernardino, California*

ABSTRACT. *Acute thrombolysis with recombinant tissue plasminogen activator (tPA) is the only treatment of proven effectiveness in acute ischemic stroke (AIS). Cerebral edema (CE) is the most feared and fatal complication of AIS. For both of these conditions, patient selection for treatment and timing of intervention are crucial but controversial issues. Conventional diagnostic tools for AIS, including the neurological exam, computerized cerebral tomography (CT) Scan, and magnetic resonance imaging (MRI) have not as yet been able to determine which patients are the best risk-benefit candidates for thrombolysis, nor are they sensitive to the early detection of patients at risk for cerebral edema. This article suggests that the use of Emergency EEG (EmEEG) in AIS can reveal a distinctive EEG pattern that adds value to the selection of patients for thrombolytic and cerebral edema treatment. This pattern, called RAWOD (Regional Attenuation WithOut Delta) can identify patients with massive AIS earlier than CT or MRI. Patients with RAWOD are unlikely to benefit from thrombolysis but may be candidates for early surveillance and intervention for cerebral edema.*

KEY WORDS. *Acute ischemic stroke, cerebral edema, EEG, emergency EEG, RAWOD, stroke.*

THE SCOPE OF THE PROBLEM

Acute cerebral ischemia is the result of deficient blood supply to a part of the brain, causing reduced function of neurons and glia that may progress to cell death and permanent dysfunction (Semple and Sacco 1999). According to current stroke statistics from the American Heart Association, AIS is three to four times as frequent as hemorrhagic stroke (American Heart Association 2005). In the United States, stroke is the third leading cause of death and the leading cause of disability among adults. There are over 700,000 new strokes annually, with 155,000 deaths (22% mortality). There are currently four million disabled survivors of stroke, and its annual economic burden is \$40 to \$60 billion.

CURRENT TREATMENT FOR AIS

Thrombolysis

Approved in 1995, tissue plasminogen activator (tPA) thrombolysis remains the only established effective treatment for AIS (Burger and Tuhim 2004). Its benefit has been confirmed in numerous studies, with a mean 30% improvement in good to excellent outcomes compared to controls (NINDS rt-PA Stroke Study Group 1995). Unfortunately, its use is tightly constrained to a 3-hour time window after stroke onset, and is accompanied by a 7 to 10% incidence of intracranial hemorrhages (ICH). This risk-benefit trade-off has generated controversy among stroke experts regarding several aspects of its use, particularly over criteria for patient selection (Furlan and Katzan 2003). Risk factors for thrombolysis-associated ICH include: clinically severe AIS (NIHSS > 20), CT Scan evidence of large AIS, administration after three hours of onset, severe hypertension, and concomitant aspirin or heparin use (Tanne et al. 2002). Unease with tPA treatment among many physicians and its restricted time window has limited its use. Currently, only 5 to 10% of AIS patients in the United States receive tPA (Furlan and Katzan 2003). Studies using intra-arterial tPA (Furlan 2004) and recent evidence that transcranial Doppler ultrasound (TCD) (Alexandrov et al. 2004) enhances tPA thrombolysis may expand its role in AIS and extend the time window for its use.

Treatment for Cerebral Edema (CE)

The most feared and fatal complication of AIS is swelling of the brain in and around the area of infarction (Robertson et al. 2004). CE is seen in infarcts that involve 30 to 40% or more of the hemisphere and most often occurs in proximal occlusions of the internal carotid artery (ICA) or middle cerebral artery (MCA). The

edema usually does not become clinically evident for two to four days following AIS and peaks around the 5th to 7th day (Steiner et al. 2001). The swelling tissue compresses healthy adjacent brain and its nutrient blood vessels, enlarging the size of the infarct in a vicious cycle. Cerebral edema is often fatal due to cerebral herniation. Successful treatment has been elusive in spite of intervention with osmotic agents, barbiturate coma, hypertonic saline, and hypothermia (Steiner et al. 2001). Recently a surgical technique of decompressive hemicraniectomy has been resurrected with technical modifications. Several anecdotal studies suggest it can save lives and improve outcomes in selected patients (Robertson et al. 2004). As with the tPA issue, there is controversy about this intervention, the criteria for patient selection, and timing of treatment (Mori et al. 2004).

CURRENT DIAGNOSTIC TOOLS FOR AIS

Neurological Exam

In the majority of AIS in the ICA or MCA territories, the neurological exam will reveal varying degrees of hemiparesis, sensory loss, visual field defects, and cortical association impairments, such as aphasia (dominant hemisphere) and spatial neglect (nondominant hemisphere). However, AIS is not necessarily a straightforward diagnosis. Patient histories may be incomplete, misleading, or unobtainable. Focal neurological deficits are not specific for AIS. Diagnostic confusion can occur in a significant minority of patients without focal motor or sensory loss who have isolated language or association cortex abnormalities. These syndromes are unfamiliar to non-neurologists who are often the first to screen AIS patients. They include acute receptive aphasia, visual agnosia, alexia with or without agraphia, Gerstmann's syndrome, right parietal confusional state, and personality changes due to frontal infarction. When patients are comatose, confused, sedated, or paralyzed, these deficits may be undetectable (Jordan 2004).

Computerized Cerebral Tomography (CT scan)

The CT scan is the imaging test most often used in the diagnosis of AIS. Although it can exclude hemorrhages, masses, and other lesions, it is often normal or equivocal in early AIS (MacDonnell et al. 1988). This can lead to delayed or incorrect diagnosis. The characteristic CT pattern seen in AIS is attenuation of the X-ray density in the affected cerebral region. This finding is dependent upon increased water content within the infarcted tissue (Somford et al. 2004). This "imbibition" of fluid into the injured tissue can take from several hours to two days to become visible (Smajlovic and Sinanovic 2004).

Magnetic Resonance Imaging (MRI)

Recently developed multiparametric MRI scanning has provided insights into the dynamic and precarious balance between infarcted cerebral tissue and tissue at risk, called the “ischemic penumbra” (Beaulieu et al. 1999). This technique compares the volume of perfusion deficits caused by occluded arteries (“Perfusion Scan”) with the volume of infarcted tissue (“Diffusion Weighted Imaging”). Tissue that is severely underperfused, but not yet infarcted, is ischemic and is at high risk for progressing to infarction if perfusion is not restored (Somford et al. 2004). This MRI testing is elegant and informative, but it is not generally available. In addition, it is expensive and can have a lag time of hours before detecting AIS (Lansberg et al. 2001).

Emergency EEG (EmEEG) can add value to the diagnosis and management of AIS

A recent review of EEG in AIS summarized the evidence that EmEEG can add value to the neurological exam and imaging studies conventionally used in the diagnosis and management of AIS (Jordan 2004). Imaging is predominantly anatomic and static. EEG provides physiologic and dynamic information. The advantage of EEG in this setting is based upon its inherent biological properties, as indicated below.

1. Sensitivity to Cerebral Ischemia. EEG is the most sensitive neurodiagnostic tool for detecting cerebral ischemia and correlates with its location and degree (Jordan 2004). Pyramidal neurons residing predominantly in cortical layers 3, 5, and 6 generate graded postsynaptic excitatory and inhibitory potentials. These potentials are modulated by transcortical and subcortical influences and their summated responses are detected at the scalp EEG (Ebersole 2003). These pyramidal layers are selectively vulnerable to hypoxia and ischemia (Courville 1958). Studies from intraoperative EEG monitoring and animal models have shown that EEG changes occur within five minutes of acute cerebral ischemia (Sundt et al. 1981) (Figure 1). This detection sensitivity is superior to current imaging methods and to the clinical exam if the patient is asleep, sedated, paralyzed, or has an altered level of consciousness.

2. EEG Patterns Correlate with Changes in Cerebral Blood Flow (CBF). Normal CBF is 50 to 70 mL/100 g/min. Characteristic EEG changes in wave morphology, frequency, and amplitude have been documented in mild, moderate, and severe AIS (Table 1).

In mild cerebral ischemia (CBF 25 to 35 mL/100 g/min), visual raw EEG analysis may show subtle decreases in the amplitude of fast activities greater than 13 Hz.

EEG abnormalities in moderate to severe hemispheric AIS were described as long ago as 1948 (Cohn et al.) and include, with increasing severity: (1) widespread polymorphic delta activity in the involved hemisphere maximally seen in temporal and frontotemporal regions, (2) ipsilateral attenuation or loss of alpha and beta

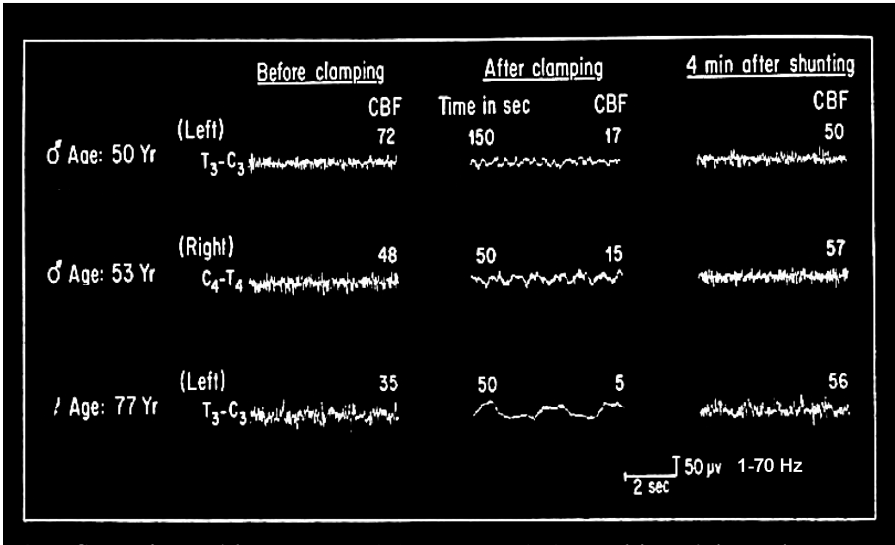


FIG. 1. Intraoperative EEG during carotid surgery in three patients. Changes in the three columns demonstrate key attributes of EEG in acute ischemic stroke (AIS). Left and middle columns: rapid onset of EEG changes within 150 seconds of ischemia, and correlation of EEG morphology and frequency changes with levels of ischemia. Middle and right columns: reversibility of EEG changes with improvement in CBF (note the compressed timebase). (Reprinted with permission from Sundt et al. 1981)

activity as well as sleep spindles, and 3) marked suppression of all EEG frequencies (Figure 2) Synaptic transmission and EEG activity, though abnormal, remain preserved down to a CBF of 12 mL/100 g/min. Cellular energy failure and loss of cell membrane integrity (cell death) are reflected in isoelectric EEG activity below 10 to 12 mL/100 g/min.

3. EEG Detects Reversible and Irreversible Cerebral Ischemia. The correlation of EEG and CBF allows the EEG to detect a “window of reversibility”

Table 1. Morphologic and frequency changes in EEG correlating with reductions in cerebral blood flow (CBF) and degree of neuronal injury (Composite data from Sharbrough et al. 1973, Ingvar et al. 1976, Astrup et al. 1981, Nagata et al. 1989, Jordan and Stringer 1991).

| CBF Level (ml/100g/min) | EEG Change | Degree of Neuronal Injury |
|-------------------------|---------------------------------------|---------------------------|
| 35–70 | Normal | No injury |
| 25–35 | Loss of fast beta frequencies | Reversible |
| 18–25 | Slowing of background to 5–7 Hz theta | Potentially reversible |
| 12–18 | Slowing to 1–4 Hz delta | Potentially reversible |
| <8–10 | Suppression of all frequencies | Neuronal death |

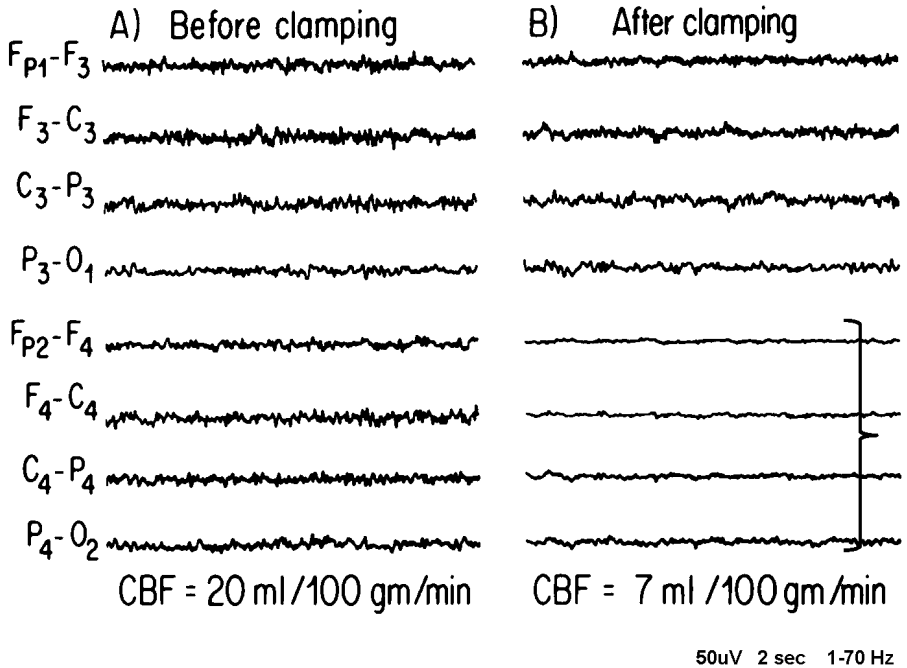


FIG. 2. Intraoperative EEG during severe ischemia. During clamping of the right carotid, cerebral blood flow (CBF) drops dramatically below the infarct threshold. There is prompt regional loss of all frequencies. Note the absence of delta activity as well (bracket). (Reprinted with permission from Daube et al. 1990)

between the early appearance of ischemic abnormalities and ultimate neuronal death (Jordan 1993). This EEG attribute has led to early diagnosis, intervention and reversal of severe cerebral ischemia in AIS and vasospasm (Wood et al. 1984 and Vespa et al. 1997) (Figure 1). It has also been long recognized that the EEG can warn of irreversible cerebral ischemia. When intraoperative EEG during carotid surgery reveals ipsilateral loss of amplitude of all frequencies, permanent neurological deficits are likely if the EEG remains unchanged for more than 15 minutes. This EEG pattern correlates with a drop in regional CBF to infarct levels less than 12 mL/100 g/min (Table 1 and Figure 2).

RAWOD

A study of EmEEG in 48 patients with AIS (Jordan 1998) revealed a distinctive EEG pattern of regional attenuation of all frequencies without supervening delta. This pattern was seen in 18 subjects with infarcts in the ICA/MCA distribution

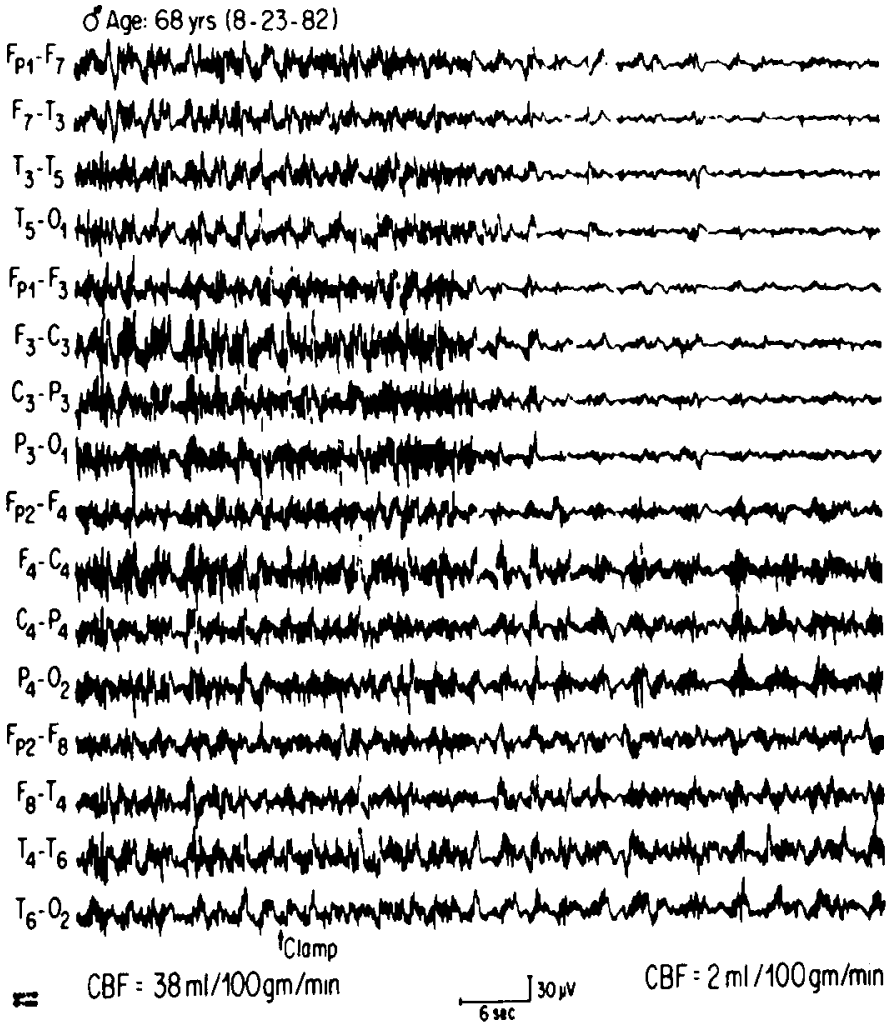


FIG. 3. Intraoperative EEG monitoring during left carotid endarterectomy. There is dramatic, rapid attenuation of all EEG components on the left following clamping of the carotid artery, associated with profoundly low cerebral blood flow (CBF). Note the slow paper speed of 5mm/second. (Reprinted with permission from Daube et al. 1990)

(37%). Given the acronym RAWOD (Regional Attenuation WithOut Delta), the EEG findings are remarkably similar to those described when clamping of the carotid artery produces profound cerebral ischemia (Figures 2 and 3). The study described these same EEG changes in emergency department patients with sporadic AIS. RAWOD

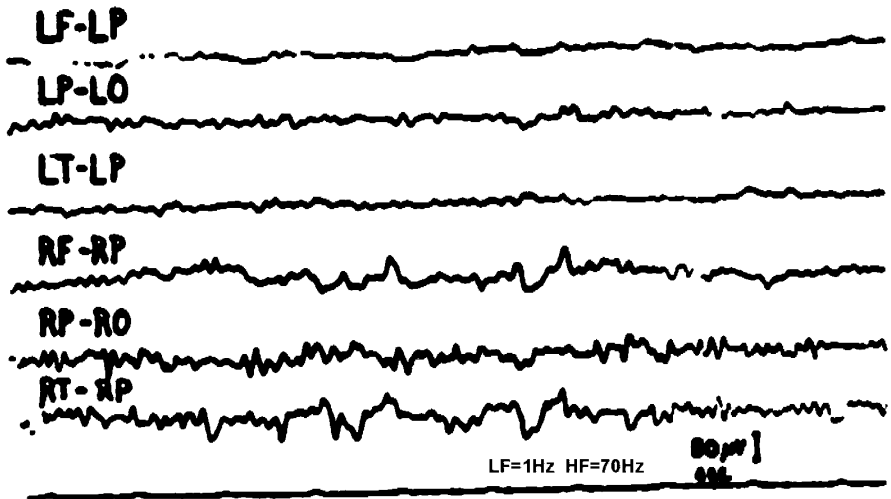


FIG. 4. EEG in massive acute ischemic stroke (AIS). The patient had pathologically proven left hemisphere AIS involving more than 50% of the hemisphere. All frequencies on the left hemisphere are suppressed. On the right, polymorphic delta activity is seen in the frontal region, reflecting trans-facial herniation from severe left hemisphere edema. (Reprinted with permission from Marquardsen et al. 1964)

also shares cardinal features with early EEG reports in pathologically proven massive AIS with herniation (Figure 4). The incidence of RAWOD was the same in patients studied before or after three hours from stroke onset, suggesting that RAWOD occurs rapidly after AIS (Table 2). However, without timely EEG, these changes remain unobserved and undocumented.

EEG characteristics of RAWOD

These include:

1. Greater than 50% amplitude attenuation of all EEG frequencies in the ischemic hemisphere, with minimal or no supervening delta activity,

Table 2. Comparison of RAWOD patients presenting less than 3 hours after symptom onset and 3 to 24 hours after symptom onset.

| Time from Symptom Onset | <3 hours | 3–24 hours | Total |
|-----------------------------------|----------|------------|---------|
| No. Patients | 26 | 22 | 48 |
| No. with RAWOD (%) | 9 (35) | 9 (39) | 18 (37) |
| Time of EEG from onset (mean hrs) | 2.5 | 14.2 | 8 |

2. Maximal and persisting involvement in the frontal, central, parietal, and temporal derivations, which predominantly reflect the ICA/MCA vascular distributions, and
3. Relative sparing of activity in the occipital derivations, which predominantly reflects the posterior cerebral vascular distribution.

On rare occasions, extra-axial fluid collections, such as epidural or subdural hematomas can suppress EEG activity. In addition, regional post-ictal suppression may resemble RAWOD. However, hematomas are readily identified on imaging studies, and post-ictal patterns are transient.

Large structural hemisphere lesions involving cortical grey and subcortical white matter usually produce polymorphic delta activity (PMD) in addition to attenuating faster frequencies (Gloor et al. 1977). PMD is believed to arise from injury to subcortical association fibers, which modulate cortical synaptic activity. One of RAWOD's distinctive features is the dramatic attenuation of delta activity in the presence of a large structural hemisphere lesion (Figure 5). This absence of delta, we believe, is most likely due to widespread disconnection of subcortical axons from the cortex due to massive infarction.

Clinical Characteristics of RAWOD patients

All RAWOD patients had extremely severe clinical deficits, with a mean NIHSS score of 31 (range 21–38). There was no difference in mean scores between patients who had EmEEG earlier or later than three hours after AIS onset, suggesting that maximal deficits occurred early (Table 3).

Correlation of RAWOD with CT, CBF, Somatosensory Evoked Potentials (SEP), and TCD Studies

CT Scan. Ten of the RAWOD patients (56%) had initial CT scans showing no new areas of infarction. Repeat CT scans performed 48 hours later showed large infarctions with cerebral edema in all 10 patients (Jordan 1998) (Figures 6A, 6D, and Table 4).

Table 3. NIHSS scores at initial presentation of 16 RAWOD patients. All patients had severe to profound deficits. Scores were virtually identical for those presenting before and after 3 hours as shown (Lyden et al. 2001).

| | n | MNIHSS | Equivalent NIHSS |
|----------------|----|--------|------------------|
| Mean | 16 | 8.75 | 31 |
| Range | 16 | 6–11 | 21–38 |
| ACI ≤ 3 hours | 8 | 8.6 | 30 |
| ACI 3–24 hours | 8 | 8.9 | 31 |

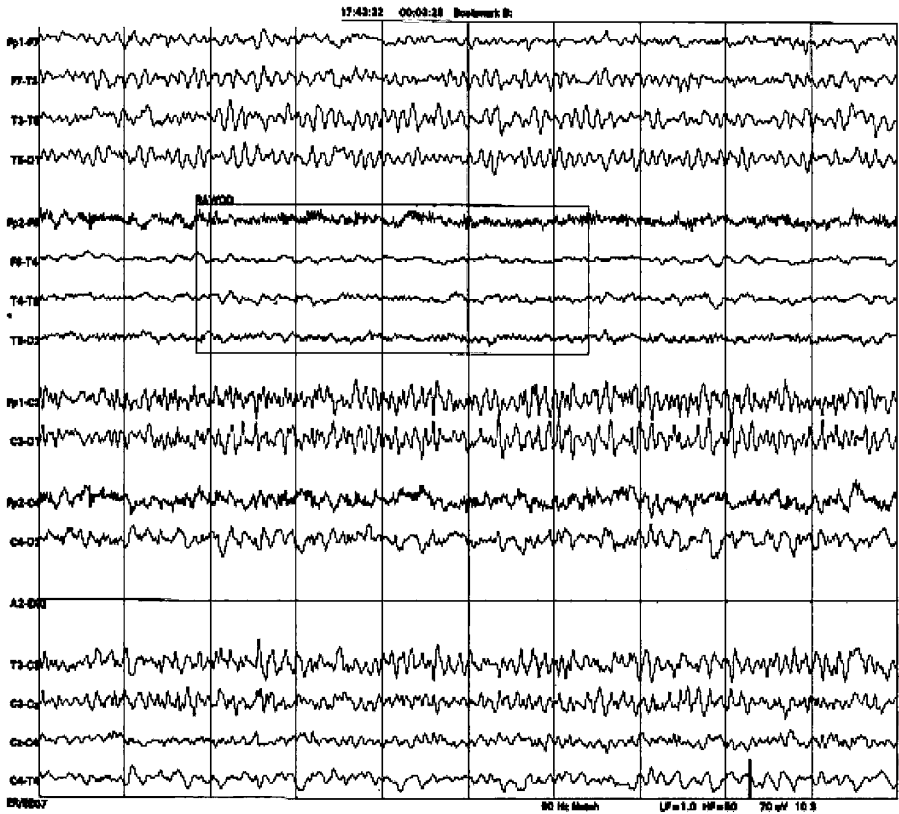


FIG. 5. RAWOD pattern with marked attenuation of all frequencies in the right hemisphere including delta activity (box) in a patient with acute left hemiplegia. (Reprinted with permission from Jordan 2004)

Early XenonCT CBF Studies in RAWOD Patients. Six RAWOD patients were studied using XeCTCBF. All showed extensive volumes of profound hemisphere ischemia below infarct levels. This widespread involvement correlated with large, fixed infarcts in each patient. In half of these patients, the initial CT scan did not show an acute infarction (Figure 6C and Table 5).

Median Nerve Somatosensory Evoked Potentials in RAWOD Patients. Two patients with RAWOD had early median nerve SEPs and both showed absent cortical responses over the affected hemisphere (Figure 7). In AIS, absent cortical SEPs correlate with profound reductions of ipsilateral CBF, severe infarctions, permanent contralateral hemiplegia, and poor prognosis (Zeman and Yiannikas 1989).

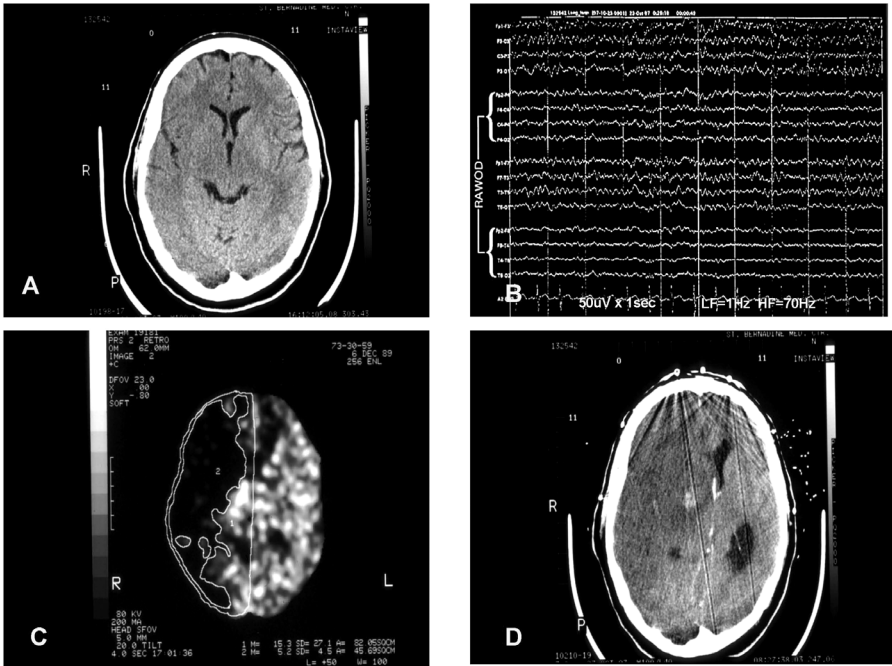


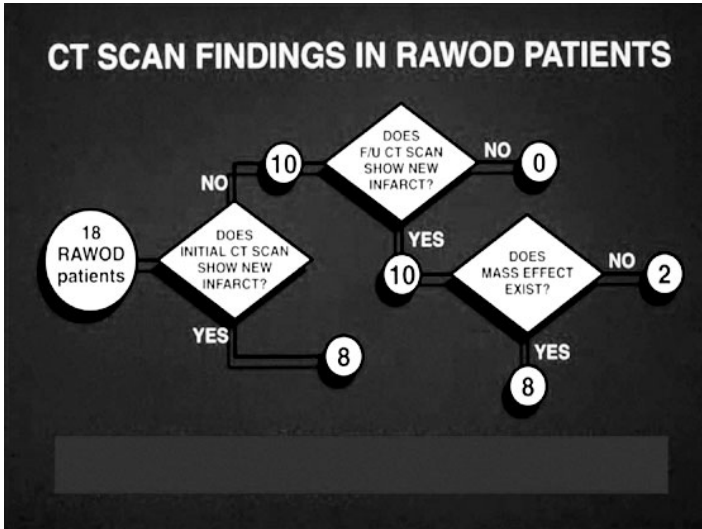
FIG. 6. A–D. CT scan and EmEEG in massive AIS. (A) Initial CT scan in a patient with acute left hemiplegia. It was interpreted as normal, but there are probably early ischemic changes in the right Sylvian fissure. (B) EmEEG shows attenuation of all frequencies over the right hemisphere without delta (i.e., RAWOD). (C) XeCTCBF done at the same time as initial CT scan confirms severe and extensive right oligemia. (D) CT Scan done 36 hours later shows massive right hemisphere edema with midline shift. The EmEEG correlated more closely with the acute cerebral blood flow finding than did the initial CT scan. (Reprinted with permission from Jordan 2004)

TCD Findings in RAWOD Patients. Six RAWOD patients were studied with acute TCD (Figure 8). Five had marked ICA-MCA velocity and morphologic abnormalities ipsilateral to RAWOD: two had MCA occlusions, one had high-grade stenosis of ICA siphon, and two had ICA-MCA blunted waves and markedly low velocities (less than 20 cm/sec). There was one normal study.

Implications of RAWOD for tPA Thrombolysis

One third of RAWOD patients fulfilled NINDS criteria for intravenous tPA thrombolysis (NINDS rt-tPA Stroke Study Group 1995). However, since RAWOD indicates that the stroke is massive and irreversible, thrombolytic treatment would be

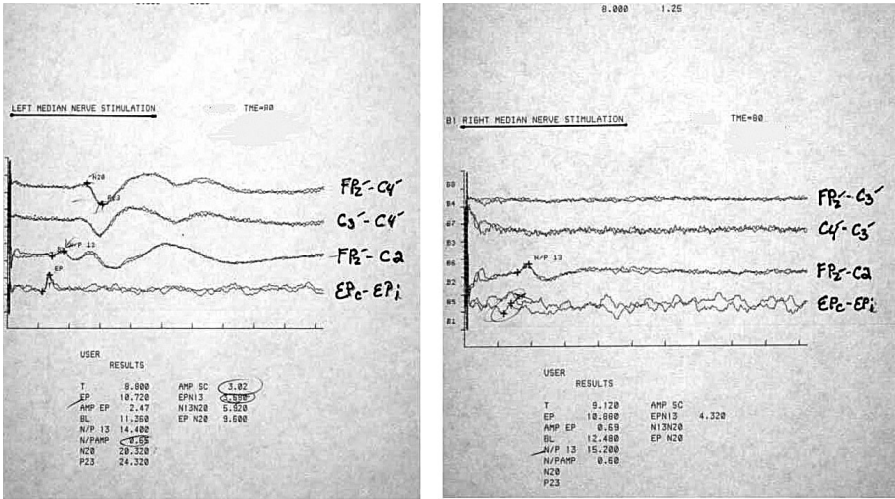
Table 4. Flow chart indicating that 10/18 (56%) RAWOD patients had no acute infarction on their initial CT scans. All 10 of these showed extensive new infarcts on the follow-up CT scan, and 80% of these infarctions showed mass effect. (Reprinted with permission from Jordan 2004)



of no benefit to these patients and could carry grave risks of ICH. While the RAWOD study did not include thrombolysis patients, we believe that RAWOD may identify patients who have unfavorable risk-benefit profiles for tPA treatment. This possibility can be tested by including EmEEG in therapeutic trials of AIS.

Table 5. XeCTCBF data in six RAWOD patients. (V_i = percent volume of infarcted tissue in the affected hemisphere; $mCBFi$ = weighted mean cerebral blood flow (CBF) in the ischemic region.) The mean V_i was greater than 50% of the ipsilateral hemisphere volume. The average $mCBF$ was substantially below the infarct threshold (10–12 mL/100 g/min). Three of the six patients had no AIS visible on their initial CT Scans. NIHSS scores in all indicated severe clinical deficits. (Reprinted with permission from Jordan 2004)

| Patient | MINHSS (NIHSS) | V_i (%) | $mCBFi$ (cc/100 gm/min) | Infarct on Initial CT |
|--------------|----------------|------------|-------------------------|-----------------------|
| 1 | 10 (35) | 52.9 | 10.5 | + |
| 2 | 10 (35) | 47 | 6.8 | + |
| 3 | 8 (28) | 60.6 | 10.1 | – |
| 4 | 8 (28) | 43.4 | 10.0 | + |
| 5 | 10 (35) | 53.9 | 5.7 | – |
| 6 | 10 (35) | 49.8 | 8.3 | – |
| Mean results | 9.3 (33) | 51.2 ± 6.6 | 8.6 ± 2.2 | |



A

B

FIG. 7. (A and B) Median Nerve SEP study from patient with RAWOD over the left hemisphere. (A) shows normal cortical response in the right hemisphere from left median nerve stimulation. (B) shows absent cortical response in the left hemisphere from right median nerve stimulation.

Implications of RAWOD for Cerebral Edema

Of the 18 RAWOD patients, at least 75% suffered massive cerebral edema with a mortality rate of 67% (12/18). All fatalities were due to cerebral herniation and surviving patients had poor outcomes. The findings suggest that RAWOD may be useful for selecting AIS patients who are at high risk for developing malignant cerebral edema. If true, RAWOD could help in the timely identification of patients for close surveillance as well as early initiation of preventive and therapeutic interventions for cerebral edema. These include intracranial pressure monitoring, osmotic agents, hypertonic saline, hypothermia, barbiturate coma, and decompressive hemicranectomy (Steiner et al. 2001). This suggestion can be tested by including EmEEG in therapeutic trials for cerebral edema in AIS.

CONCLUSION

The most commonly used diagnostic tools for AIS are the neurological exam, CT Scan, and MRI. There are significant limitations to their diagnostic sensitivities for selecting patients for thrombolysis and cerebral edema treatment.

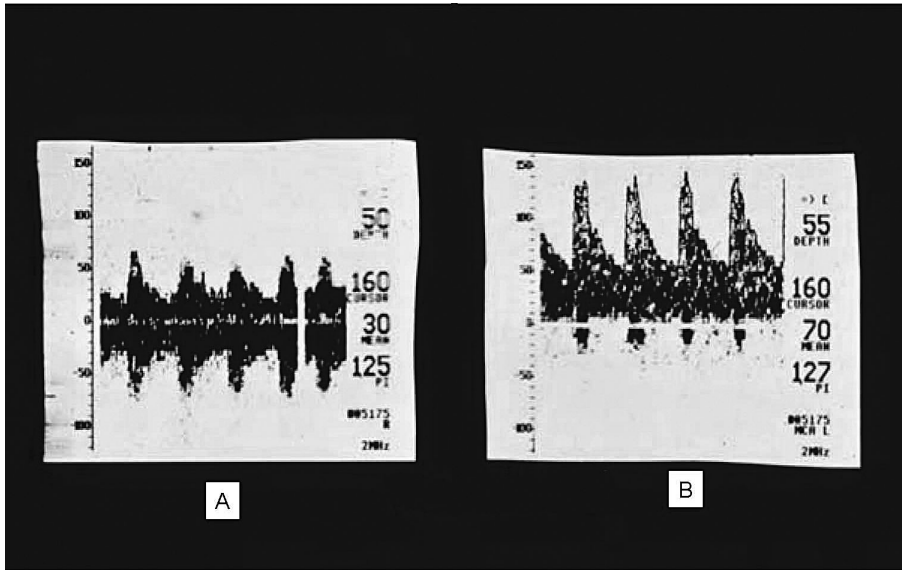


FIG. 8. (A and B) Transcranial Doppler study in a patient with RAWOD over the right hemisphere. (A) demonstrates greater than 50% reduction in blood flow velocity in the right MCA compared to the left MCA (B) In addition, the wave morphology seen in (A) is blunted and shows an abnormal bidirectional pattern of flow, presumably due to turbulence from intraluminal clot.

RAWOD is a distinctive EEG pattern in AIS characterized by marked attenuation of all frequencies including delta activity in the ischemic hemisphere. It indicates extensive and irreversible ICA/MCA distribution infarction and a high risk for malignant cerebral edema. RAWOD identifies a subgroup of patients who may not be suitable for tPA thrombolysis, but may be appropriate candidates for early cerebral edema treatment. These observations can be confirmed by including EmEEG in therapeutic trials of AIS.

Address reprint requests to: Anita Schneider, R. EEG/EP T., CNIM, Jordan NeuroScience, Inc., Suite 316, 399 East Highland Avenue, San Bernardino, CA 92404.

REFERENCES

- Alexandrov AV, Molina CA, Grotta JC, Garami Z, Ford SR, Alvarez-Sabin J, Montaner J, Saqqur M, Demchuk AM, Moya LA, Hill MD, Wojner AW; CLOBUST Investigators. Ultrasound-enhanced systemic thrombolysis for acute ischemic stroke. *N Engl J Med* 2004; 351:2170–78.
- American Heart Association. Heart Disease and Stroke Statistics, 2005 Update, on the Internet at <http://www.americanheart.org/presenter.jhtml?identifier=3000333>. Accessed January 2005.

- Astrup J, Siesjö BK, Symon L. Thresholds in cerebral ischemias—the ischemic penumbra. *Editorial. Stroke* 1981; 12:723–25.
- Beaulieu C, de Crespigny A, Tong DC, Moseley ME, Albers GW, Marks MP. Longitudinal magnetic resonance imaging study of perfusion and diffusion in stroke: evolution of lesion volume and correlation with clinical outcome. *Ann Neurol* 1999; 46:568–78.
- Burger KM, Tuhim S. Antithrombotic trials in acute ischaemic stroke: a selective review. *Expert Opin Emerg Drugs* 2004; 9:303–12.
- Cohn HR, Raines RG, Mulder DW, Neumann MH. Cerebral vascular lesions: electroencephalographic and neuropathologic correlations. *Arch Neurol* 1948; 60:163–81.
- Courville CB. Etiology and pathogenesis of laminar cortical necrosis; its significance in evaluation of uniform cortical atrophies of early life. *AMA Arch Neurol Psychiatry* 1958; 79:7–30.
- Daube J, Harper CM, Litchy W. Intraoperative Monitoring. In: Daly D and Pedley T, editors. *Current practice of clinical electroencephalography*, 2nd edition. New York: Raven Press; 1990. Chapter 23.
- Ebersole J. Cortical Generators and EEG Voltage Fields. In: Ebersole JS and Pedley TM, editors. *Current practice of clinical electroencephalography*, 3rd edition. New York: Lippincott Williams and Wilkins; 2003. p. 12–31.
- Furlan A. Intra-arterial thrombolysis for acute stroke. *Cleve Clin J Med* 2004; 71 Suppl 1:S31–8.
- Furlan AJ, Katzan IL, Caplan LR. Thrombolytic therapy in acute ischemic stroke. *Curr Treat Options Cardiovasc Med* 2003; 5:171–80.
- Gloor P, Ball G, Schaul N. Brain lesions that produce delta waves in the EEG. *Neurology* 1977; 326–33.
- Ingvar DH, Sjolund B, Ardo A. Correlation between dominant EEG frequency, cerebral oxygen uptake and blood flow. *Electroencephalogr Clin Neurophysiol* 1976; 41:268–76.
- Jordan KG. Continuous EEG and evoked potential monitoring in the neuroscience intensive care unit. *J Clin Neurophysiol* 1993; 10:445–75.
- Jordan KG. Regional attenuation without delta (RAWOD): a distinctive early EEG pattern in acute cerebral infarctions (SACI). *Neurology* 1998; 50(suppl 1):A43.
- Jordan KG. Emergency EEG and continuous EEG monitoring in acute ischemic stroke. *J Clin Neurophysiol* 2004; 21:341–52.
- Jordan KG, Stringer WA. Correlative xenon enhanced CT cerebral blood flow (XeCTCBF) and EEG to functionally stratify acute cerebral infarction. *Neurology* 1991; 41(suppl 1):336.
- Lansberg MG, Thijs VN, O'Brien MW, Ali JO, de Crespigny AJ, Tong DC, Moseley ME, Albers, GW. Evolution of apparent diffusion coefficient, diffusion-weighted, and T2-weighted signal intensity of acute stroke. *AJNR Am J Neuroradiol* 2001; 22:637–44.
- Lyden PD, Lu M, Levine SR, Brott TG, Broderick J. NINDS rtPA Stroke Study Group. A modified National Institute of Health Stroke Scale for use in stroke clinical trials: preliminary reliability and validity. *Stroke* 2001; 32:1310–17.
- MacDonnell RAL, Donnan GA, Bladin PF, Berkovic SF, Wriedt CH. The electroencephalogram and acute ischemic stroke. Distinguishing cortical from lacunar infarction. *Arch Neurol* 1998; 45:520–24.
- Marquardsen J, Harvald B. The electroencephalogram in acute cerebrovascular lesions. A report of 50 cases verified at autopsy. *Neurology* 1964; 14:275–82.
- Mori K, Nakoa Y, Yamamoto T, Maeda M. Early external decompressive craniectomy with duroplasty improves functional recovery in patients with massive hemispheric embolic infarction: timing and indication of decompressive surgery for malignant cerebral infarction. *Surg Neurol* 2004; 62:420–29.
- Nagata K, Tagawa K, Hiroi S, Shishido F, Uemura K. Electroencephalographic correlates of blood flow and oxygen metabolism provided by positron emission tomography in patients with cerebral infarction. *Electroencephalogr Clin Neurophysiol* 1989; 72:16–30.
- NINDS Stroke Study Group. Tissue plasminogen activator for acute ischemic stroke. *N Engl J Med* 1995; 333:1581–87.
- Robertson SC, Lennarson P, Hasan DM, Traynelis VC. Clinical course and surgical management of massive cerebral infarction. *Neurosurgery* 2004; 55:55–61.

- Semple P, Sacco R. An Atlas of Stroke. 2nd edition. New York: Parthenon Publishing Group; 1999. p. 17–18.
- Sharbrough FW, Messick JM Jr, Sundt TM Jr. Correlation of continuous electroencephalograms with cerebral blood flow measurements during carotid endarterectomy. *Stroke* 1973; 4: 674–83.
- Smajlovic D, Sinanovic O. Sensitivity of the neuroimaging techniques in ischemic stroke. *Med Arh* 2004; 58:282–84.
- Somford DM, Marks MP, Thijs VN, Tong DC. Association of early CT abnormalities, infarct size, and apparent diffusion coefficient reduction in acute ischemic stroke. *AJNR Am J Neuroradiol* 2004; 25:933–38.
- Steiner T, Ringleb P, Hacke W. Treatment options for large hemispheric stroke. *Neurology* 2001; 57:S61–8.
- Sundt TM Jr, Sharbrough FW, Piepgras DG, Kearns TP, Messick JM Jr, O'Fallon WM. Correlation of cerebral blood flow and electroencephalographic changes during carotid endarterectomy with results of surgery and hemodynamics of cerebral ischemia. *Mayo Clin Proc* 1981; 56: 533–43.
- Tanne D, Kasner SE, Demchuk AM, Koren-Morag N, Hanson S, Grond M, Levine SR. Markers of increased risk of intracerebral hemorrhage after intravenous recombinant tissue plasminogen activator therapy for acute ischemic stroke in clinical practice: the Multicenter rt-PA Stroke Survey. *Circulation* 2002; 105:1679–85.
- Vespa PM, Nuwer MR, Juhasz C, Alexander M, Nenov V, Martin N, Becker, DP. Early detection of vasospasm after acute subarachnoid hemorrhage using continuous EEG ICU monitoring. *Electroencephalogr Clin Neurophysiol* 1997; 103:607–15.
- Wood JH, Polyzoidis KS, Epstein CM, Gibby GL, Tindall GT. Quantitative EEG alterations after isovolemic hemodilution augmentation of cerebral perfusion in stroke patients. *Neurology* 1984; 34:764–68.
- Zeman BD, Yiannikas C. Functional prognosis in stroke: use of somatosensory evoked potentials. *J Neurol Neurosurg Psychiatry* 1989; 52:242–47.