



Contents lists available at ScienceDirect

Journal of Hand Therapy

journal homepage: www.elsevier.com/locate/jht

Increase of weight-bearing capacity of patients with lesions of the TFCC using a wrist brace

A. Asmus, Dr. med.^{a,1}, M. Salloum^{a,1}, W. Medeiros OTR, CHT (retired)^b, M. Millrose, Dr. med.^c, A. Obladen, Dr. med.^a, L. Goelz, Dr. med.^d, J. Diehl, Professor^e, A. Eisenschenk, Professor^{a,f}, A. Ekkernkamp, Professor^f, S. Kim, Dr. med.^{f,g,*}

^aAbteilung für Hand-, Replantations- und Mikrochirurgie, Unfallkrankenhaus Berlin, Berlin, Germany

^bWendy Medeiros, Pahoa, HI, United States

^cDepartment of Trauma Surgery and Sports Orthopaedics, Berufsgenossenschaftliche Unfallklinik Murnau, Murnau am Staffelsee, Germany

^dInstitut für Radiologie und Neuroradiologie, Unfallkrankenhaus Berlin, Berlin, Germany

^eInstitut für Mathematik und Informatik, Greifswald, Germany

^fKlinik und Poliklinik für Unfall-, Wiederherstellungschirurgie und Rehabilitative Medizin, Universitätsmedizin Greifswald, Greifswald, Germany

^gLeibniz Institut für Plasmaforschung und Technologie (INP Greifswald), Greifswald, Germany

ARTICLE INFO

Article history:

Received 6 April 2020

Revised 7 December 2020

Accepted 21 March 2021

Available online xxx

Keywords:

TFCC

Ulnar variance

Wrist

Brace

WristWidget

Weight bearing

ABSTRACT

Study design: Retrospective cross-sectional case series.

Background: Lesions of the triangular fibrocartilage complex (TFCC) can result in pain during axial load and unstable distal radioulnar joint (DRUJ). Conventional wrist orthoses decrease initial pain sufficiently but also prevent any movement during recovery and do not contribute to the stabilization of the DRUJ.

Purpose: In this retrospective analysis, we tested if the weight-bearing capacity of patients with lesions of the triangular fibrocartilage complex was increased by wearing a brace that stabilizes the distal radioulnar joint.

Methods: Twenty-three patients had an arthroscopically confirmed TFCC lesion. We compared preoperative dynamic weight-bearing capacity of both hands with and without a commercially available wrist brace (WristWidget). Subgroup analysis was performed for stability of the distal radioulnar joint and etiology of the TFCC lesion. The dynamic ulnar variance was measured in a modified weight bearing test. We used parametric tests for normally distributed values.

Results: The weight-bearing capacity of the hand with TFCC lesion was significantly lower than of the control hand (16 versus 36 kg; $p < 0.001$). The relative load of the affected hand compared to the unaffected hand increased from 48 % (CI 37-60, SD 27) to 59 % (CI 47-72, SD 29) with a brace. The device had no effect on the control hand. Twelve patients with unstable DRUJ had a lower weight-bearing capacity compared to the eleven with stable joint. The percentage improvement with bracing was higher for those with unstable joints (versus stable) and traumatic lesions (versus degenerative).

Conclusion: The use of a wrist brace significantly increases the weight-bearing capacity and therefore the maximum tolerated axial load of patients with a lesion of the TFCC. Patients with traumatic lesion or unstable DRUJ tend to show lower values than with degenerative lesions or stable joints.

© 2021 The Authors. Published by Elsevier Inc.

This is an open access article under the CC BY-NC-ND license (<http://creativecommons.org/licenses/by-nc-nd/4.0/>)

Information for additional footnote or declaration section. This information is provided in the preprint: Trial registration: DRKS (German Clinical Trials Register): DRKS00020350; Date of registration: 30.12.2019; WHO-UTN: U1111-1245-4189.

Conflicts of interest: Wendy Medeiros: Inventor and distributor of the WristWidget. All other authors declare no conflict of interest.

Funding: This study received no external funding and was performed using the institutional and private budget.

* Corresponding author: Tel.: +4917630734911. Universitätsmedizin Greifswald, Klinik und Poliklinik für Unfall-, Wiederherstellungschirurgie und Rehabilitative Medizin, Ferdinand-Sauerbruch-Straße, 17475 Greifswald Germany.

E-mail address: kims@uni-greifswald.de (S. Kim).

¹ A. Asmus and M. Salloum contributed equally to this work.

0894-1130/\$ – see front matter © 2021 The Authors. Published by Elsevier Inc. This is an open access article under the CC BY-NC-ND license

(<http://creativecommons.org/licenses/by-nc-nd/4.0/>)

<https://doi.org/10.1016/j.jht.2021.03.006>

Please cite this article as: A. Asmus, M. Salloum, W. Medeiros OTR, CHT (retired) et al., Increase of weight-bearing capacity of patients with lesions of the TFCC using a wrist brace, Journal of Hand Therapy, <https://doi.org/10.1016/j.jht.2021.03.006>

Introduction

The triangular fibrocartilage complex (TFCC) contributes to the stability of the distal radioulnar joint (DRUJ) and axial stability of the forearm.¹⁻³ Lesions of the TFCC may manifest with ulnar sided wrist pain during axial load and DRUJ instability.⁴ Clinical tests include testing for pain on pressure in the fovea ulnaris, forced ulnar deviation, and assessment of DRUJ stability among others.⁵ As diagnostic imaging such as MRI might show false negative results, the arthroscopic examination is the standard for diagnosing and treating TFCC-lesions.⁵ According to the site and shape, the Palmer classification differentiates between traumatic and degenerative lesions.⁶ Especially ulnar-sided traumatic lesions with rupture of the foveal attachment (Palmer 1B, Atzei 2, and 3) might lead to instability of the DRUJ.^{7,8} The reconstructive surgery can be done arthroscopically or open and should be performed within 3 months but may be possible up to 2 years after trauma.⁸ If the patient chooses a nonsurgical treatment, the forearm can be splinted in supination for 4 weeks which can be followed by a wrist splint for 2 weeks.⁹ In patients with stable DRUJ, a conservative treatment with splinting and pain medication showed comparable results to the arthroscopic treatment.¹⁰

From our experience, pain during axial load is a major cause for inability to work in patients with either traumatic or degenerative lesions of the TFCC. Conventional wrist splints decrease initial pain sufficiently but also prevent any movement during recovery. Furthermore, they do not contribute to the stabilization of the DRUJ.

According to the convex-concave rule, dorsal wrist pain might be caused by inhibited gliding of carpal bones.^{11,12} Taping has been shown to decrease dorsal wrist pain by restricting midcarpal and intercarpal joint movement and improving gliding of the palmar bones.¹³

In this study we retrospectively analyzed the effect of a wrist brace that consists of two parallel tapes that stabilize the distal radioulnar joint on the preoperative weight-bearing capacity of patients who had a confirmed TFCC-lesion in arthroscopy.

Materials and Methods

Our database listed 23 patients who were admitted between 01/2019 and 12/2019 for wrist arthroscopy with suspected TFCC lesions who had persistent pain or DRUJ instability after failed conservative therapy which included forearm splinting, NSAIDs and physiotherapy. There was no selection regarding sex. Information on gender is not collected during preoperative presentation. Eligible patients performed the weight-bearing test with and without a wrist brace preoperatively and had an arthroscopically confirmed TFCC-lesion. The wrist brace was a standardized commercially available brace (WristWidget, Hawaii, USA) which consists of 2 parallel velcro-straps that embrace the distal forearm proximally and distally of the ulnar head (Fig. 1). The brace was applied by the patients and correct placement was checked by a hand surgeon. We analyzed onset and anamnesticly suspected etiology of symptoms, hand dominance, side of complaint, and the score of the DASH-questionnaire.¹⁴ Data of physical examination of both hands included the range of motion of the wrist, grip strength, as well as tenderness of the TFCC (Fovea sign) and painful ulnar deviation of the affected hand. For the weight-bearing test,¹⁵ patients were asked to place the wrist in the middle of the scale with extended arms and increase load using their body weight until pain was not tolerated (Fig. 1 and Online Resource 1). The maximum weight that could be reached with and without brace was documented for both hands. Static and dynamic ulnar variance of both hands were measured on preoperative X-rays using a modified weight-bearing test in most cases. For this purpose, the patient closed his fist around

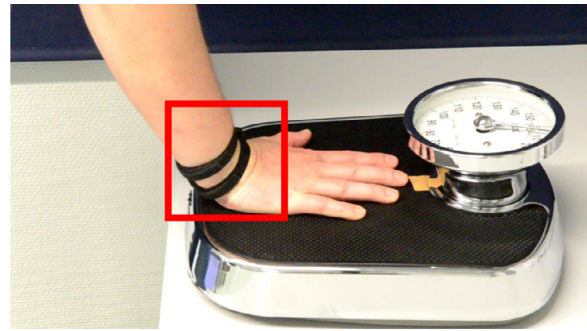

Fig. 1. The weight-bearing test with attached WristWidget.

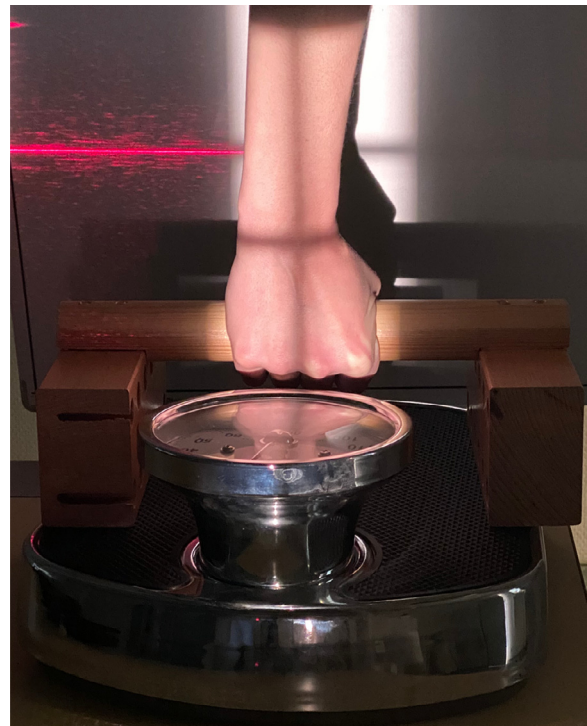

Fig. 2. Examination of the dynamic ulnar variance with weight-bearing test.

a wooden bar while giving axial load on the examination table (Fig. 2). For cases who had an MRI, the TFCC-lesion was classified as suspicious for traumatic or degenerative origin. The type of TFCC lesion and need for operative stabilization of the distal radioulnar joint by TFCC-reconstruction, refixation or ulnar shortening were obtained from surgery records.

The local ethics committee reviewed and approved the retrospective study [BB103/19]. We obtained informed consent from all patients for the use and publication of their data.

Values are rounded to the first decimal or integers depending on the variable. Determination of variable distribution was performed visually, by Kolmogorov-Smirnov-test and by Q-Q Plot. Normally distributed values are presented with mean, 95% confidence interval (CI) of the mean and standard deviation (SD), not normally distributed values with median and interquartile range (IQR). For normally distributed values, the paired t-test for comparison of the affected hand with the contralateral (control) hand and unpaired t-test for comparisons between patients was used. Categorical variables were tested using Fisher's exact for expected counts less than five. A P value of $\leq .05$ was considered significant and

Table 1

ROM: sum of extension/flexion/ulnar duction/radial duction in degrees, paired t-test

Clinical test	Affected hand		Control hand		P	n
	Mean (SD)	CI	Mean (SD)	CI		
Handgrip strength [kg]	22 (12)	17-27	34 (11)	29-39	<.001	22
ROM [degree]	153 (32)	138-167	190 (23)	180-200	<.001	22
PS [degrees]	156 (18)	148-164	169 (5)	167-171	.005	22
Dynamic ulnar variance [mm]	0.42 (0.7)	0.07-0.78	1.19 (0.9)	0.77-1.6	.003	18
Weight-bearing test [kg]	16 (9)	12.2-19.8	36 (12)	30.8-41.5	<.001	23

PS = sum of pronation/supination in degrees. Statistic test was performed using Mann-Whitney-U.

CI = 95%-confidence interval of the mean; SD = standard deviation.

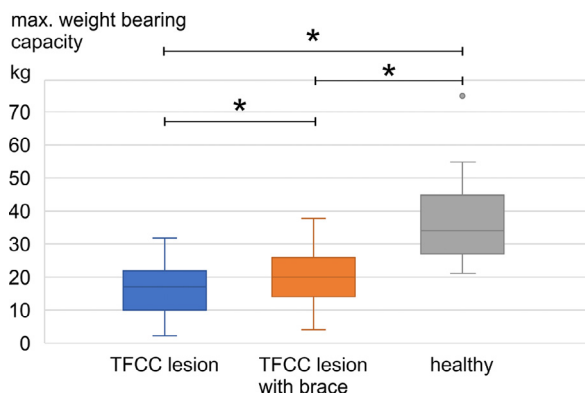


Fig 3. Absolute weight-bearing test results. The weight-bearing test showed a significantly lower weight-bearing capacity of the side with TFCC lesion compared to the control hand ($n = 23$, $P < .001$, paired t-test). Using the brace, the affected side reached a significantly higher maximum load ($n = 23$, $P < .001$, paired t-test). The affected side with brace could not reach the load of the control side ($n = 23$, $P < .001$, paired t-test). Using the Bonferroni correction for multiple comparisons, the adjusted significance level was 0.016.

adjusted in case of multiple comparisons for the main hypothesis. For subgroup analysis, only P values are given with no statement about significance. As not all tests were performed for each patient, the number of included cases is presented for the statistical tests. Agreement between the MRI report and the intraoperative finding regarding the differentiation on the type of lesion was determined by Cohen's kappa.

Results

We included 14 female and nine male patients with a mean age of 45 (SD 13) years at the time of symptom onset and presented at a median of 214 days (IQR 235) after onset. The mean preoperative DASH score was 47 (CI 38-56, SD 17).

All patients were right hand dominant; the lesion was located on the right side in 15 cases. On the day of examination, 16 patients remembered a trauma, 14 (61 %) described a painful pronation, and 19 (83 %) a painful supination. Ulnar deviation of the affected hand was painful in 18 cases. The fovea sign was positive in 13 (57 %) patients. Five patients had a positive, nine patients a neutral, and nine patients a negative static ulnar variance in pre-operative x-ray of the affected hand.

Values of the clinical examination are shown in Table 1.

The absolute measured values in the weight-bearing test with and without brace in comparison with the control are significantly different (Fig. 3). The relative load of the affected hand compared to the control hand increased from 48 % (CI 37-60, SD 27) to 59 % (CI 47-72, SD 29; $n = 23$, $P < .001$, paired t-test).

The control side showed no significant difference for values obtained with and without brace (36 kg CI 39-40, SD 13 vs 35

kg CI 31-42 SD 12, $n = 22$, $P = .325$, paired t-test). The weight-bearing capacity during X-ray compared to the standard test was significantly lower for the control hand (23 kg CI 17-29, SD 8, $p < 0.001$, paired t-test) and the affected hand (14 kg CI 10-18, SD 8, $p = 0.036$, paired t-test). The affected hand could bear 61% of the control hand during weight-bearing test, and 54% during the modified weight-bearing test for X-ray. The relationship was not significantly different ($n = 18$, $P = .47$, paired t-test). The maximum weight-bearing capacity during X-ray was significantly lower on the affected hand (13 kg CI 9.5-17.9, SD 8.4) compared to the control hand (23 kg CI 17.5-28.7, SD 11.3) kg ($n = 18$, $P < .001$, paired t-test).

Twenty-two patients had a preoperative MRI with 1.0 or 1.5 T which showed a suspected traumatic lesion in 16 cases. The agreement between MRI and intraoperative result for the differentiation of traumatic and degenerative lesions was moderate with a kappa of 0.556.

All following results are only given with P value without significance threshold because of multiple comparisons with the same sample.

Hand grip strength was different between female (27 kg CI 23-32 SD 8) and male patients (44 kg CI 39-48 SD 6) on the healthy side ($n = 22$, $P < .001$, t-test) and affected side (female 17 kg CI 12-23, SD 9; male 29 kg CI 19-39; $n = 22$, $P = .027$, t-test). This is reflected in the weight bearing test of the healthy side (female 30 kg CI 26-33 SD 5, male 45 CI 34-56 SD 15; $n = 23$, $P = .002$, t-test), but not on the affected side (female 15 kg CI 9-20 SD 9, male 19 kg CI 12-25 SD 9; $n = 23$, $P = .231$). Female patients showed a smaller absolute increase of weight bearing capacity of the affected hands (2.8 kg CI 2.0-3.7 SD 1.4) than male patients (5.4 kg CI 3.2-7.7 SD 2.9; $n = 23$, 0.10) but no difference of relative increase (female 34% CI 12-55 SD 36, male 41 % CI 13-69 SD 37; $n = 23$, $P = .642$).

On X-ray, the dynamic ulnar variance was lower on the affected side (0.42 mm CI 0.07-0.78 SD 0.7) compared to the control side (1.2 mm CI 0.77-1.62 SD 0.86; $n = 18$, $P = .005$, paired t-test).

Twelve patients needed an operative stabilization for DRUJ-instability. Comparison of the relative gain with the brace showed a difference. Values are shown in Table 2. The relative load of the affected hand with unstable DRUJ compared to the control hand increased from 35% (CI 20-49, SD 23) to 46% (CI 47-72, SD 29), the load of the hand with stable DRUJ from 62% (CI 47-79, SD 24) to 73% (CI 56-90, SD 25).

The comparison between patients with degenerative and traumatic lesions determined by arthroscopy is shown in Table 3. Ten of 16 patients with a traumatic lesion and two of seven with a degenerative lesion had an unstable DRUJ. The relative load of the affected hand with a traumatic TFCC lesion compared to the control hand increased from 40% (CI 26-53, SD 26) to 51% (CI 36-66, SD 28), the load of the hand with a degenerative lesion from 68% (CI 49-87 SD 21) to 78% (CI 58-98, SD 21). Static ulnar variance was not associated with traumatic or degenerative lesions in our sample ($n = 23$, $P = .193$, Fisher's exact).

Table 2
Comparison between stable and unstable DRUJ

Distal radioulnar joint	Unstable		Stable		P	n
	Mean (SD)	CI	Mean (SD)	CI		
Age at onset [years]	45 (11)	37-52	47 (14)	38-57	.631	23
DASH score	46 (19)	32-59	48 (14)	34-63	.798	16
Handgrip strength on affected side [kg]	18.6 (8)	13-24	25.4 (15)	15-35	.201	22
Weight-bearing on affected side [kg]	11.3 (6.0)	7.5-15.2	21.1 (8.6)	15.3-26.9	.005	23
Weight-bearing with brace [kg]	15.5 (6.7)	11.2-19.7	24.7 (9.5)	18.4-31.1	.013	23
Absolute gain wearing the brace [kg]	4.1 (2.6)	2.4-5.8	3.6 (2.2)	2.1-5.1	.580	23
Relative gain with brace compared to without (%)	47.8 (38)	24-72	24.7 (27)	7-43	.113	23
Weight-bearing test during X-ray [kg]	10.4 (5.7)	0.4-1.8	17.0 (0.7)	0.7-1.9	.100	18
Dynamic ulnar variance [mm]	0.36 (0.5)	-0.3-0.74	0.49 (0.9)	-0.21-1.18	.704	18
	Median	IQR	Median	IQR		
Time between onset and presentation [days]*	172.5	232	257	542	.379	23

All other values were tested using the unpaired t-test.

SD = standard deviation; CI = 95%-confidence interval of the mean; IQR = interquartile range.

The significance threshold was not defined due to multiple comparisons with the same sample.

* Values for 'Time between onset and presentation' are not normally distributed and given with median and interquartile range. Statistic test was performed using Mann-Whitney-U.

Table 3
Comparison between traumatic and degenerative TFCC-lesion

Arthroscopic finding	Traumatic		Degenerative		P	n
	Mean (SD)	CI	Mean (SD)	CI		
Age at onset [years]	42 (12)	35-48	55 (9)	47-63	.016	23
DASH score	44 (18)	33-55	56 (10)	40-71	.232	16
Handgrip strength on affected side [kg]	19 (12)	12-25	29 (9)	21-37	0.050	22
Weight-bearing on affected side [kg]	13 (7)	9-17	23 (8)	16-30	.008	23
Weight-bearing with brace [kg]	17 (8)	13-21	27 (9)	19-35	.016	23
Absolute gain caused by the brace [kg]	4.0 (2.6)	2.6-5.4	3.7 (2.0)	1.9-5.5	.823	23
Relative gain with brace compared to without (%)	45.2 (38)	25-66	16.6 (6)	11-22	.009	23
Weight-bearing test during X-ray [kg]	11 (6)	7-16	17 (11)	8-27	.141	18
Dynamic ulnar variance [mm]	0.28 (0.7)	-0.19-0.75	0.64 (0.7)	-0.03-1.32	.309	18
	Median	IQR	Median	IQR		
Time between onset and presentation [days]*	173	185	382	764	.006	23

All other values are given as mean with standard deviation and were tested using the unpaired t-test.

SD = standard deviation; CI = 95%-confidence interval of the mean, IQR: interquartile range.

The significance threshold was not defined due to multiple comparisons with the same sample.

* Values for 'Time between onset and presentation' are not normally distributed and given with median and interquartile range. Statistic test was performed using Mann-Whitney-U.

Discussion

Our study showed that the wrist brace could significantly increase the maximum tolerated axial load by reducing the pain of wrists with TFCC lesions. The brace had no effect on the control hand.

The results show a tendency that patients with unstable DRUJ have a smaller weight-bearing capacity without aid. With the brace, patients with unstable DRUJ might have a higher gain than those with stable joint. This might be due to articular stabilization of the DRUJ by the circumferential straps and prevention of translational movement. As all included patients had ulnar sided wrist pain with arthroscopically confirmed lesion of the TFCC, the DRUJ might be clinically stable in manual testing. But translational movement might be still painful in such individuals and explain the effect in patients with stable DRUJ.

After the 'Press test' which used the body weight on arm rests,¹⁶ the 'Push Off' test was developed in which the patient would lean on a grip dynamometer to obtain quantitative results for follow up examinations.¹⁷ We used an analogue scale as it is less expensive and can show the maximum possible load (dynamic test). The load on both hands is reduced during the modified weight-bearing test for X-ray as the hand is placed differently. But they show the same relation between both hands and relative values might be comparable. A weight bearing study using a defined load of 18.1 kg described a correlation of a 1 mm increase

of ulnar variance with occurrence of an intraarticular pathology.¹⁸ This result could not be reproduced in this study because an axial load of 18 kg could not be reached by the participants during X-ray with our examination setup.

Even though female and male patients showed different values for grip strength and weight bearing capacity, the relative gain of the WristWidget seemed not to be different. For further sex-based examinations, the relative gain should be used.

While patients with an unstable DRUJ presented earlier than those with a stable joint, patients with a degenerative lesion of the TFCC presented later than those with a traumatic lesion. Patients with a degenerative lesion are stronger in all strength tests of the affected hand, maybe due to preserved stability as the lesion is located centrally. Patients with a traumatic lesion might suffer from stronger exertional pain which might also be reflected in the smaller dynamic ulnar variance compared to the control hand during X-ray. This contrasts with cadaveric examinations where progressively unstable DRUJ is positively correlated with dynamic ulnar variance.³

A study on ulnocarpal impaction found no difference in static ulnar variance between the symptomatic and contralateral wrist.¹⁹ Static ulnar variance had no influence on the clinical results in our sample.

Even though patients with a traumatic lesion had a lower weight-bearing capacity than those with a degenerative lesion, the absolute gain was identical. As the relative gain is higher, patients

with a traumatic lesion might experience more gain in strength while those with a degenerative lesion come closer to values of the control hand.

A more detailed subgrouping according to the lesion site (Palmer) or using the Atzei-classification would need a larger sample. The agreement between the MRI report and surgeon regarding the etiology and classification of TFCC lesions was only moderate which might in parts be attributed to the diverse quality of MRI imaging (eg, magnetic field strength of 1.0 or 1.5 T, application of contrast medium) or the subjective factor of both the radiologist and the surgeon which was shown in reviews of diagnostic accuracy.^{20,21}

As the wrist brace is easy to apply and may ease the pain in patients with traumatic lesions of the TFCC, it can be recommended for patients who are hesitant or not fit for operation.

We are aware of the low statistical power due to the small number of participants. The presented values were used for effect size estimation and power analysis for a prospective study registered under the same trial number DRKS00020350 available at the German Clinical Trials Register. We want to assess the effect of the wrist widget in patients with traumatic TFCC-lesions with unstable DRUJ. As we are focusing on the underlying pathology and possible use of the wrist brace for diagnostic purposes, we might compare different braces later.

Availability of data and material

The data is available at Mendeley Data.

Kim, Simon; Asmus, Ariane; Salloum, Mouataz (2020), "Wrist-Widget retrospective 2019", Mendeley Data, v2 <http://dx.doi.org/10.17632/ctyv7mjoy6v.2>

Ethical approval

The ethics committee of the University Medicine of Greifswald approved the retrospective data collection and analysis (BB103/19).

Consent to participate and for publication

Written consent for retrospective data collection, analysis and publication of data and media was obtained from each patient.

Acknowledgments

We thank Damon Kim and Jamie G for their support.

Supplementary materials

Online Resource 1: The weight-bearing test with attached WristWidget.

Supplementary material associated with this article can be found, in the online version, at doi:[10.1016/j.jht.2021.03.006](https://doi.org/10.1016/j.jht.2021.03.006).

References

1. Lees VC. Functional anatomy of the distal radioulnar joint in health and disease. *Ann R Coll Surg Engl*. 2013;95:163–170.
2. Gupta R, Allaire RB, Fornalski S, Osterman AL, Lee TQ. Kinematic analysis of the distal radioulnar joint after a simulated progressive ulnar-sided wrist injury. *J Hand Surg Am*. 2002;27:854–862.
3. Zhu AF, Burns G, Siljander B, Waljee JF, Ozer K. The role of triangular fibrocartilage complex in axial stability of the forearm. *J Wrist Surg*. 2018;7:404–408.
4. Vezeridis PS, Yoshioka H, Han R, Blazar P. Ulnar-sided wrist pain. Part I: anatomy and physical examination. *Skeletal Radiol*. 2010;39:733–745.
5. Kirchberger MC, Unglaub F, Muhldorfer-Fodor M, et al. Update TFCC: histology and pathology, classification, examination and diagnostics. *Arch Orthop Trauma Surg*. 2015;135:427–437.
6. Palmer AK. Triangular fibrocartilage complex lesions: a classification. *J Hand Surg Am*. 1989;14:594–606.
7. Skalski MR, White EA, Patel DB, Schein AJ, RiveraMelo H, Matcuk Jr GR. The traumatized TFCC: an illustrated review of the anatomy and injury patterns of the triangular fibrocartilage complex. *Curr Probl Diagn Radiol*. 2016;45:39–50.
8. Mathoulin CL. Indications, techniques, and outcomes of arthroscopic repair of scapholunate ligament and triangular fibrocartilage complex. *J Hand Surg Eur Vol*. 2017;42:551–566.
9. Henry MH. Management of acute triangular fibrocartilage complex injury of the wrist. *J Am Acad Orthop Surg*. 2008;16:320–329.
10. Sander AL, Sommer K, Kaiser AK, Marzi I, Frank J. Outcome of conservative treatment for triangular fibrocartilage complex lesions with stable distal radioulnar joint. *Eur J Trauma Emerg Surg*. 2020.
11. Norkin CC, White DJ. Measurement of joint motion: a guide to goniometry. FA Davis; 2016.
12. Neumann DA. Kinesiology of the musculoskeletal system—e-book: foundations for rehabilitation. Elsevier Health Sciences; 2013.
13. Kim GS, Weon JH, Kim MH, Koh EK, Jung DY. Effect of weight-bearing wrist movement with carpal-stabilizing taping on pain and range of motion in subjects with dorsal wrist pain: a randomized controlled trial. *J Hand Ther*. 2019.
14. Germann G, Harth A, Wind G, Demir E. [Standardisation and validation of the German version 2.0 of the Disability of Arm, Shoulder, Hand (DASH) questionnaire]. *Unfallchirurg*. 2003;106:13–19.
15. Barlow SJ. A non-surgical intervention for triangular fibrocartilage complex tears. *Physiother Res Int*. 2016;21:271–276.
16. Lester B, Halbrecht J, Levy IM, Gaudinez R. Press test" for office diagnosis of triangular fibrocartilage complex tears of the wrist. *Ann Plast Surg*. 1995;35:41–45.
17. Vincent JJ, MacDermid JC, Michlovitz SL, et al. The push-off test: development of a simple, reliable test of upper extremity weight-bearing capability. *J Hand Ther*. 2014;27:185–190 quiz 191.
18. Ozer K, Zhu AF, Siljander B, Lawton JN, Waljee JF. The effect of axial loading on ulnar variance. *J Wrist Surg*. 2018;7:247–252.
19. Mwatirura T, Daneshvar P, Pike J, Goetz TJ. Clinical and radiographic correlates for the treatment of ulnocarpal impaction. *J Wrist Surg*. 2019;8:192–197.
20. Low S, Erne H, Pillukat T, Muhldorfer-Fodor M, Unglaub F, Spies CK. Diagnosing central lesions of the triangular fibrocartilage as traumatic or degenerative: a review of clinical accuracy. *J Hand Surg Eur Vol*. 2017;42:357–362.
21. Yoshioka H, Burns JE. Magnetic resonance imaging of triangular fibrocartilage. *J Magn Reson Imaging*. 2012;35:764–778.