

Vestibular Incision Subperiosteal Tunnel Access (VISTA) 1-week after surgery using StellaLife Recovery Kit

Description

Female age 71 c/o sensitivity due to generalized gingival recession on lower arch. Vista tunneling technique was used after harvesting autograft from palate.

Method

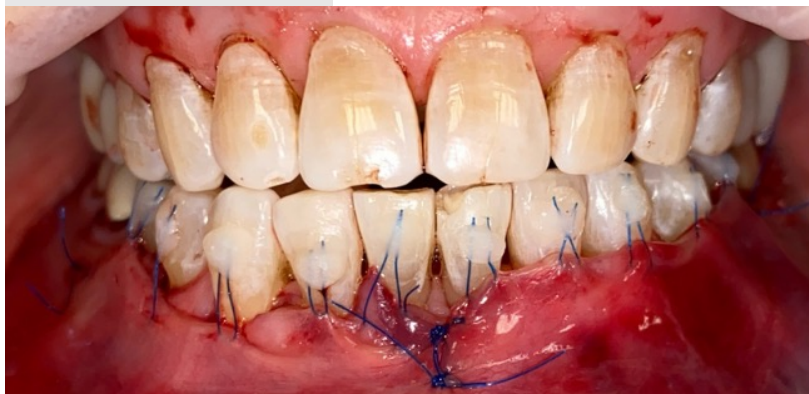
StellaLife gel was applied immediately after surgery and patient was given the StellaLife Recovery kit to use 3x a day.

Conclusion

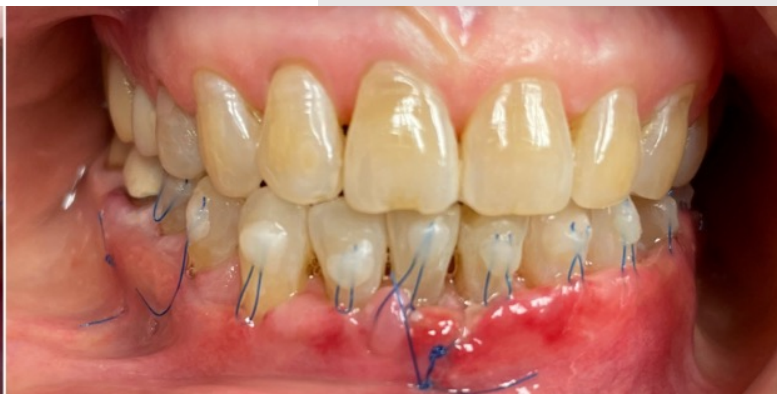At the 1-week follow-up appointment, a clinical evaluation revealed accelerated healing.

” We use Stella Life products for all our surgical procedures for better patient healing experience.”

Immediately after surgery



1-week post-op after VEGA Oral Kit



Courtesy of of Angelie Zamora DDS, MAGD.
smilesfamilydental.com/ • (817) 277-1971