

www.stellalifehealing.com



Dedicated to Oral Health Through INTELLIGENT HEALING® Better Oral Health. Naturally.

Series Case Report: December 2016
Posterior Vertical and Horizontal Alveolar Ridge Reconstruction
Using StellaLife® VEGA® Oral Care Recovery Kit for post-op management

Walter Tatch, DDS, FACOMS

CONTACT: 800.828.7265 or info@stellalifehealing.com

Case Report: Posterior Vertical and Horizontal Alveolar Ridge Reconstruction

- **Materials and Methods:**

- 45 y/o ASAll male underwent advanced bone reconstruction using Ti-reinforced membrane and BMP/Miner-Oss.
 - Pre-op: 2 gm of Amoxicillin.
 - Post-op: Amoxicillin, Norco and VEGA Oral Care Recovery Kit.
- Patient was seen for 1 week follow-up and reported no pain and no swelling. Exam revealed advanced healing (equivalent of anticipated few weeks post-op) and minimal edema.

- **Conclusion:**

- Patient exhibited advanced Post-Op healing, quick resolution of post-op edema and good analgesia control using StellaLife® VEGA® Oral Care Recovery Kit (10 days regimen).

Fig. 1: Advanced Alveolar Atrophy L Posterior Ridge. Alveolar Height 6.2 mm in the Area of Mental Foramen.

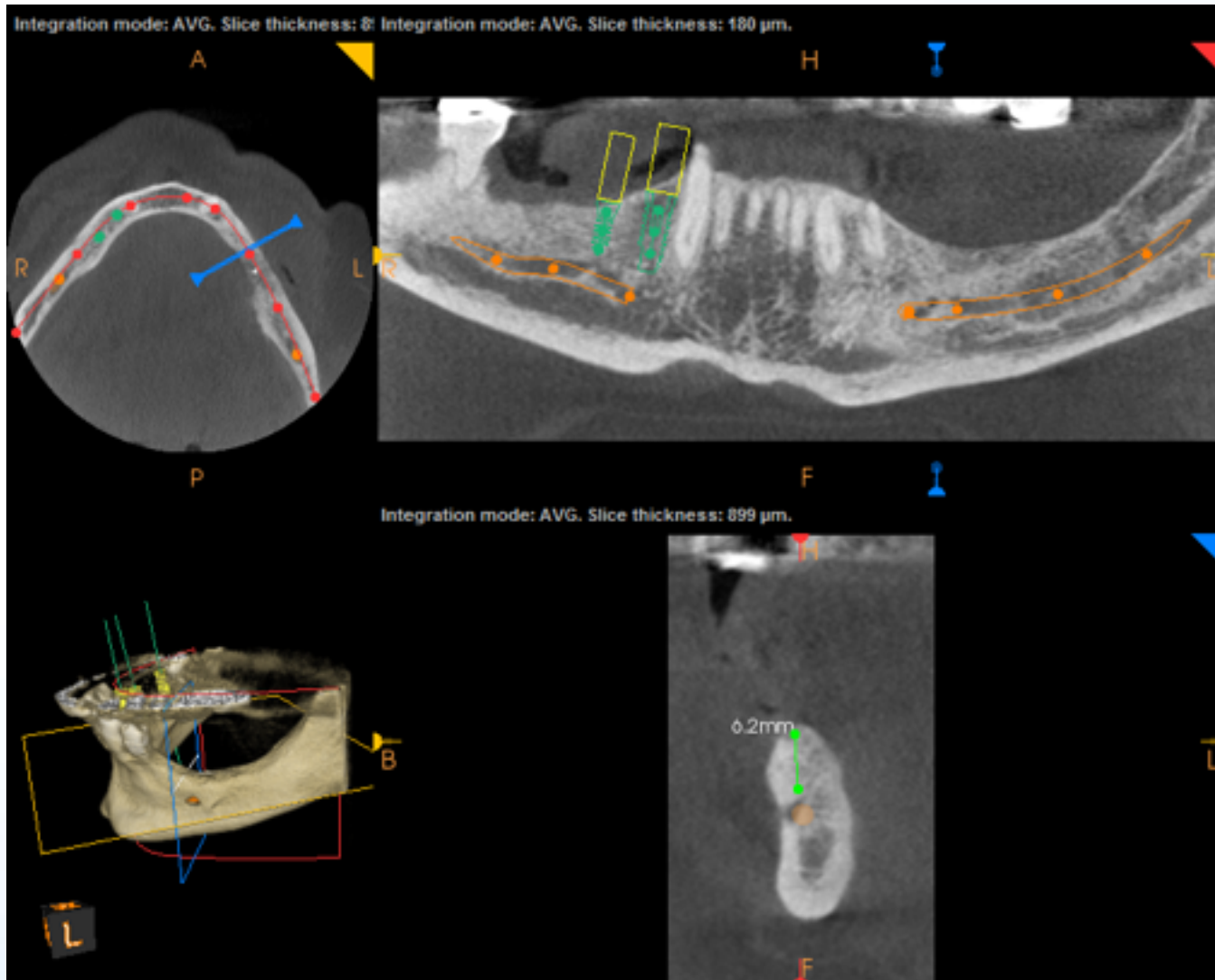


Fig. 2: Intra-Op Photo Showing the Extent of Reconstruction

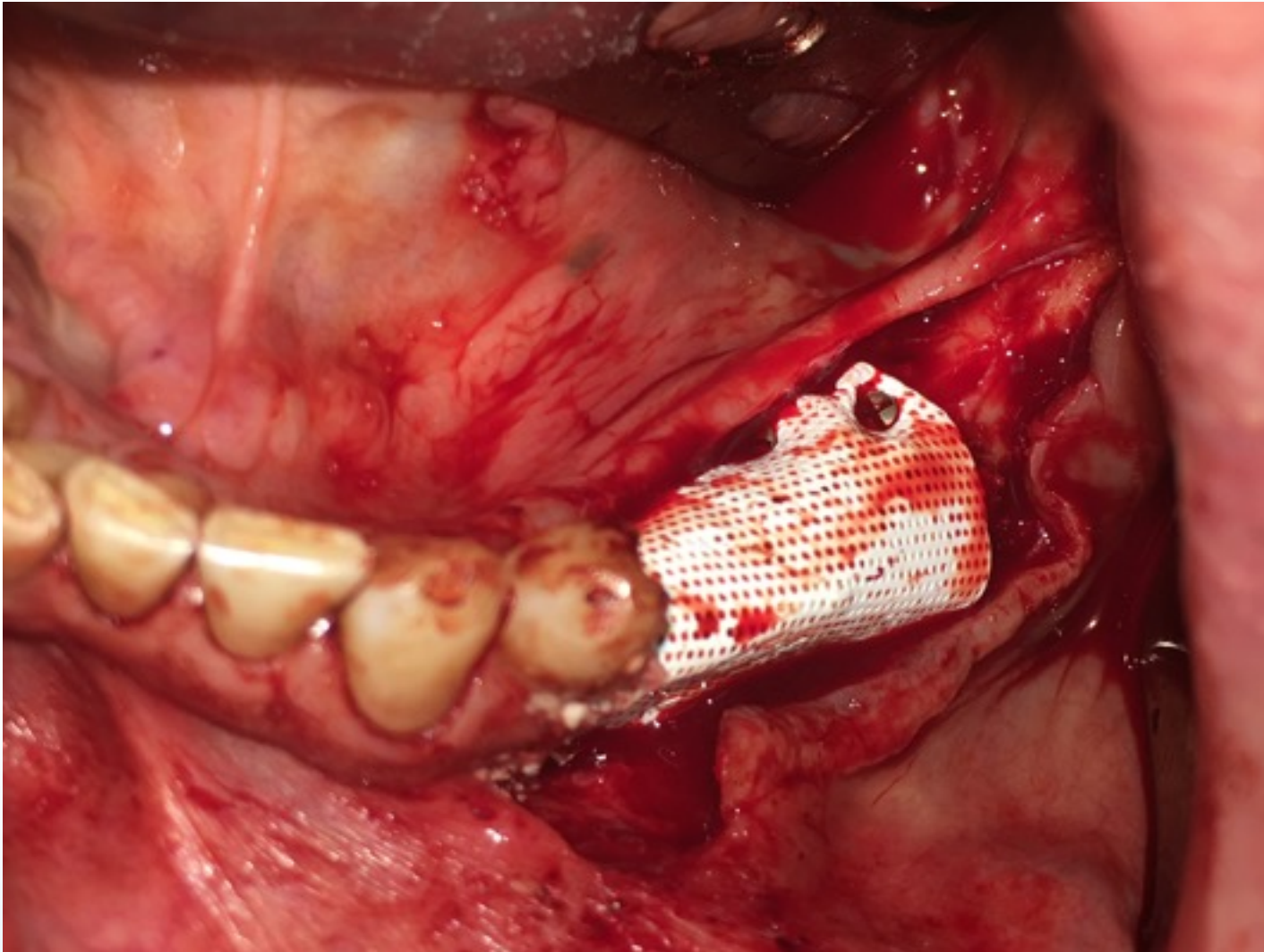


Fig. 3: Immediate Post-Op Showing Flap Closed

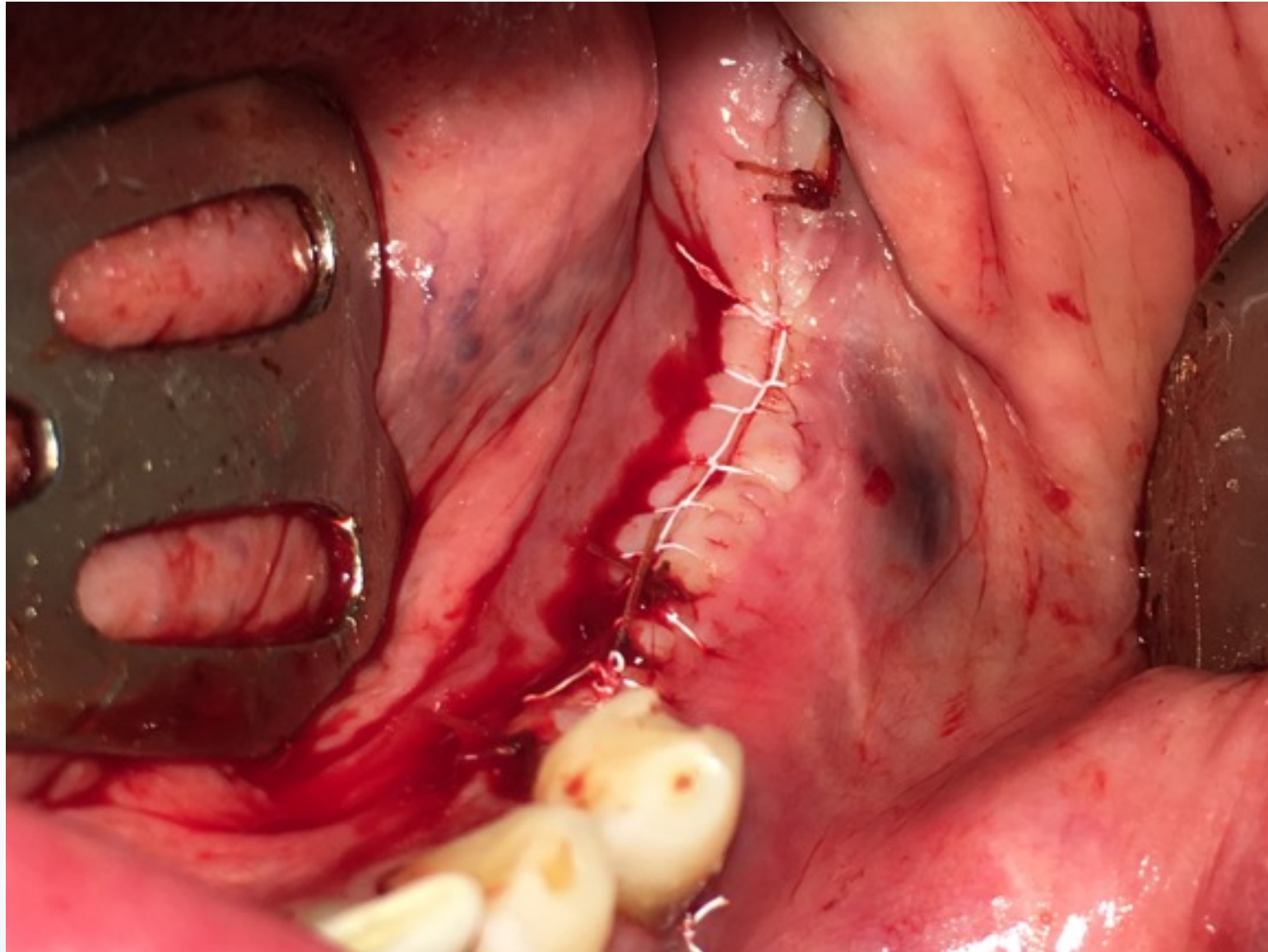


Fig. 4a: 1 Week Post-Op CT.

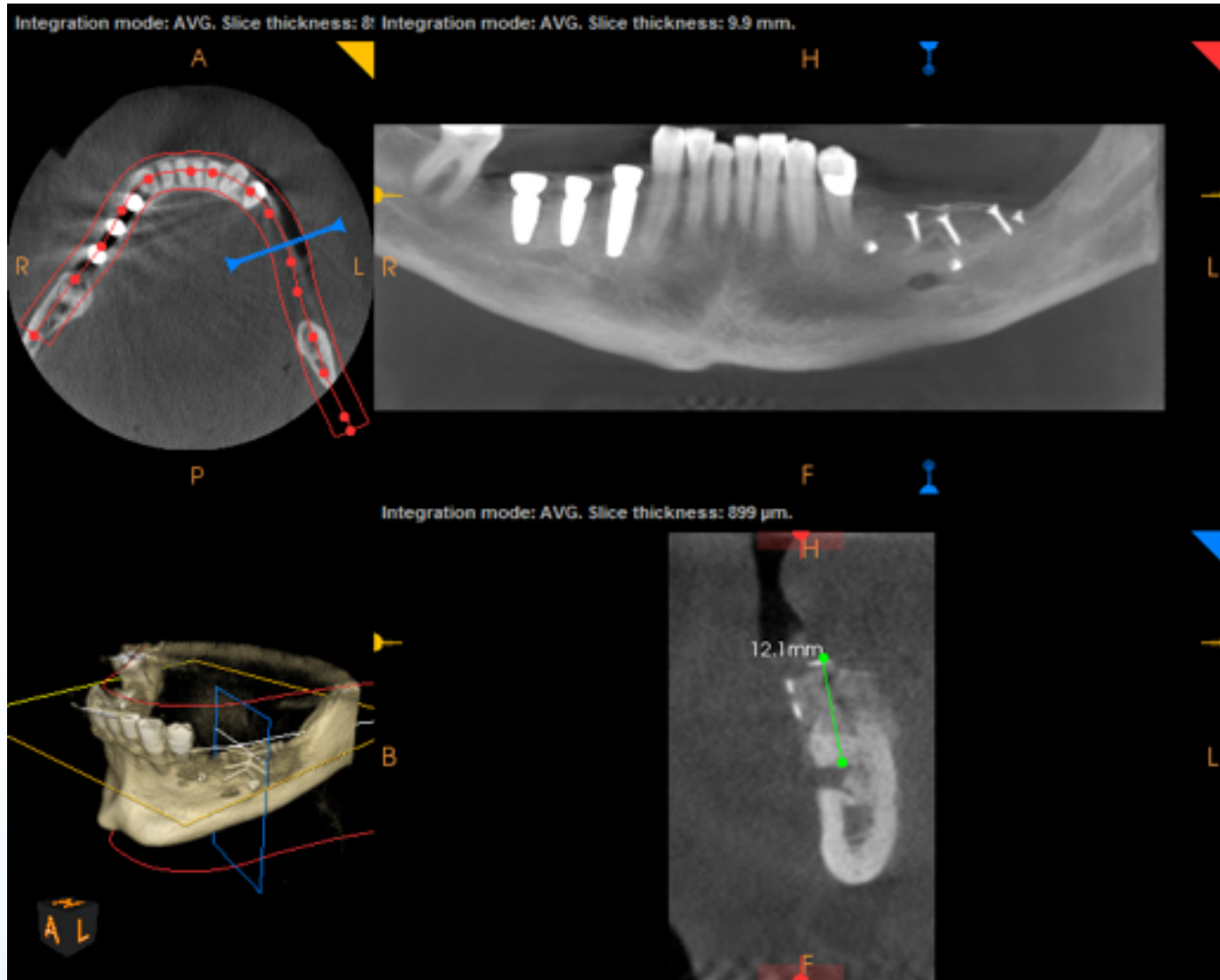
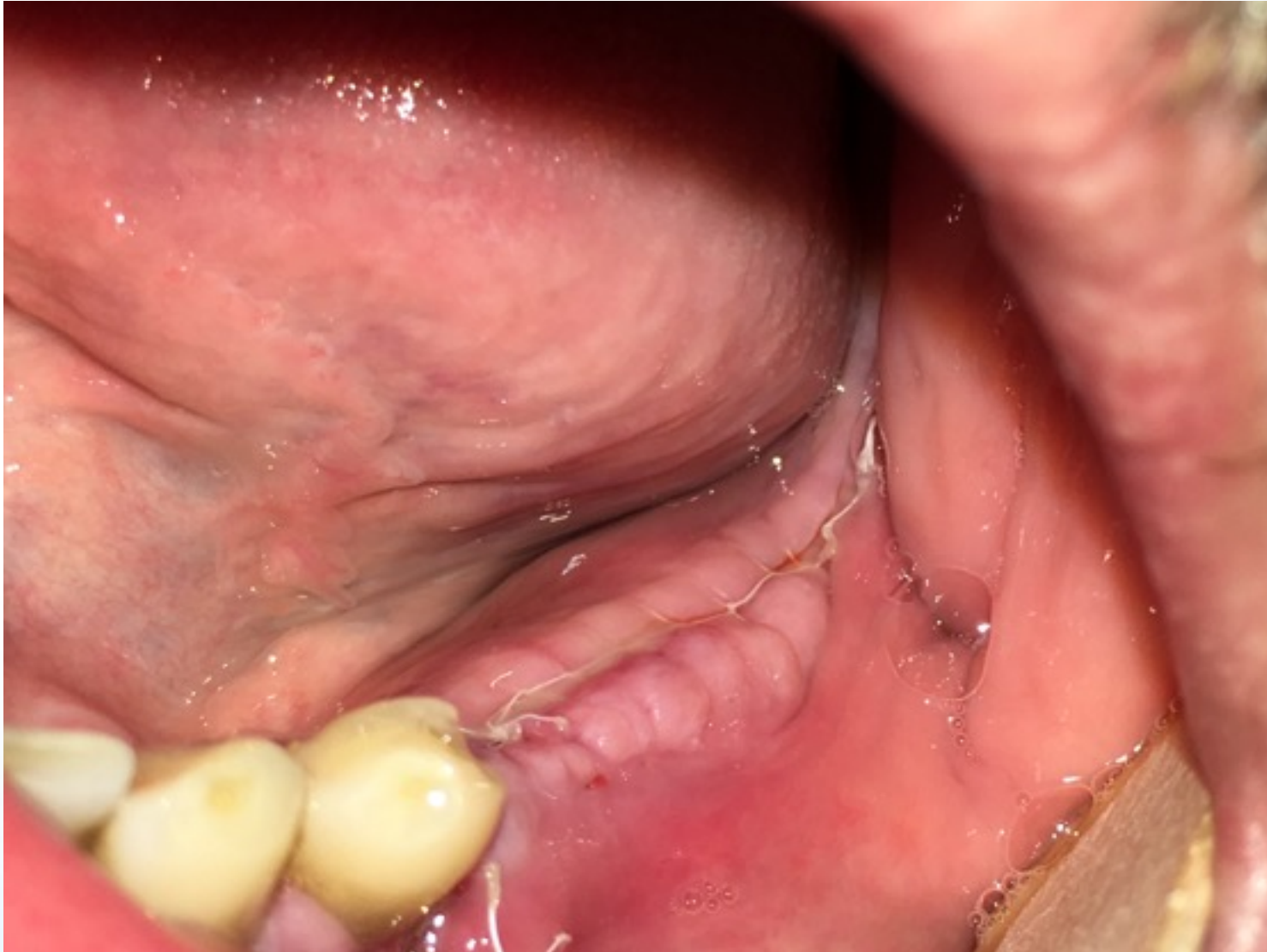

Fig. 4b: 1 Week Post-Op Clinical Photo. Minimal Edema and Normal Appearing Tissue.



StellaLife® Confidential Proprietary. VEGA® and Intelligent Healing® are trademarks of StellaLife®, Inc. All rights reserved.