

www.stellalifehealing.com



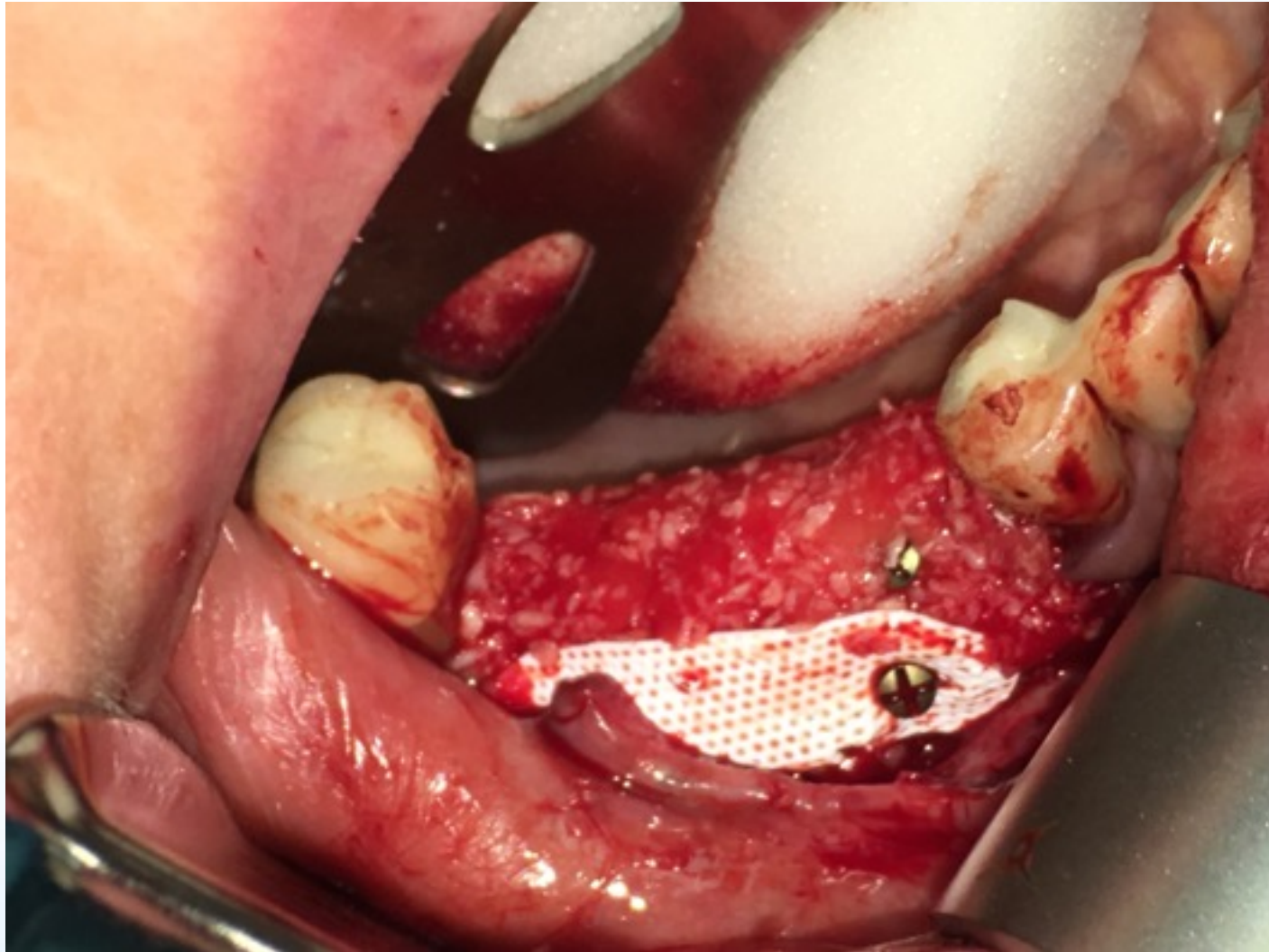
Dedicated to Oral Health Through INTELLIGENT HEALING™ Better Oral Health. Naturally.

Series Case Report: November 2016
Use of VEGA Recovery Kit after BMP bone graft reconstruction

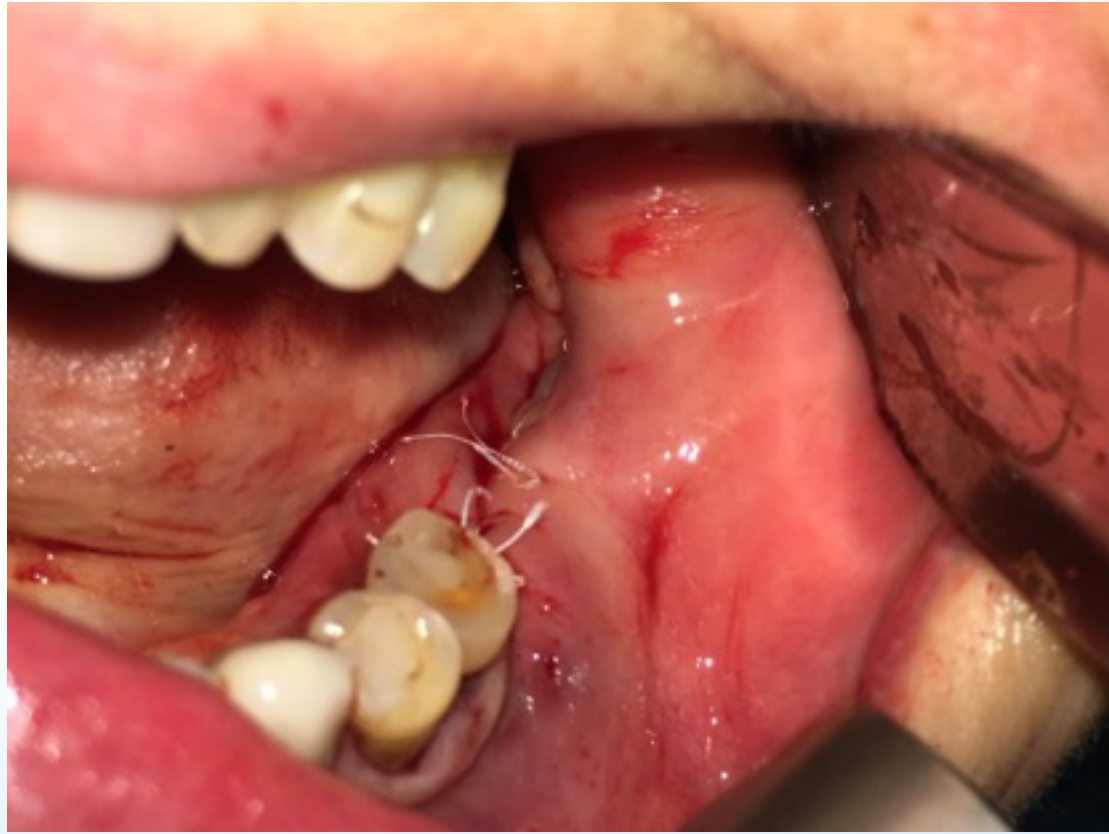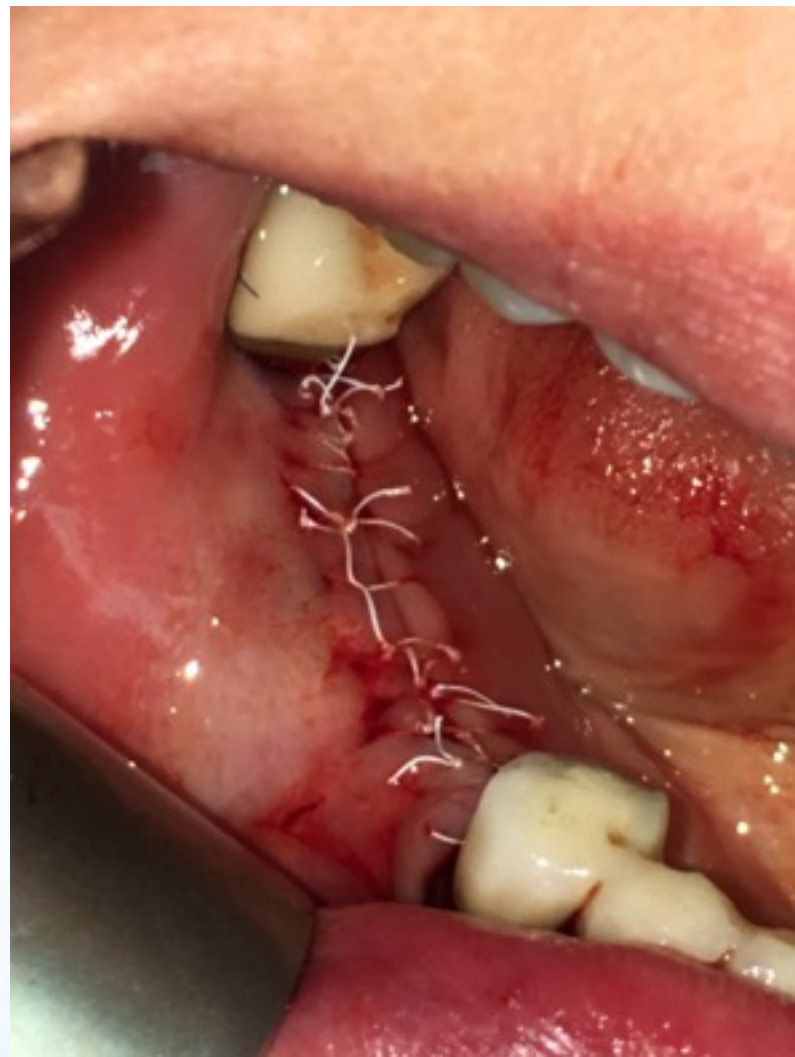Walter Tatch, DDS, FACOMS

CONTACT: 800.828.7265 or info@stellalifehealing.com

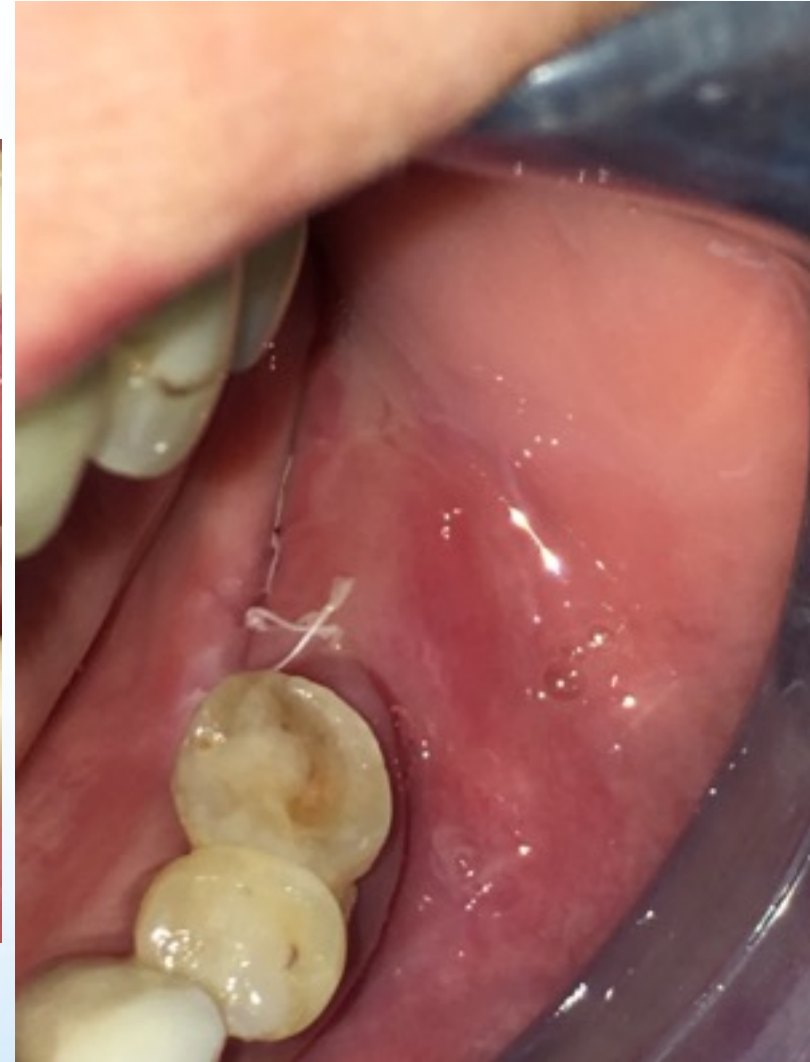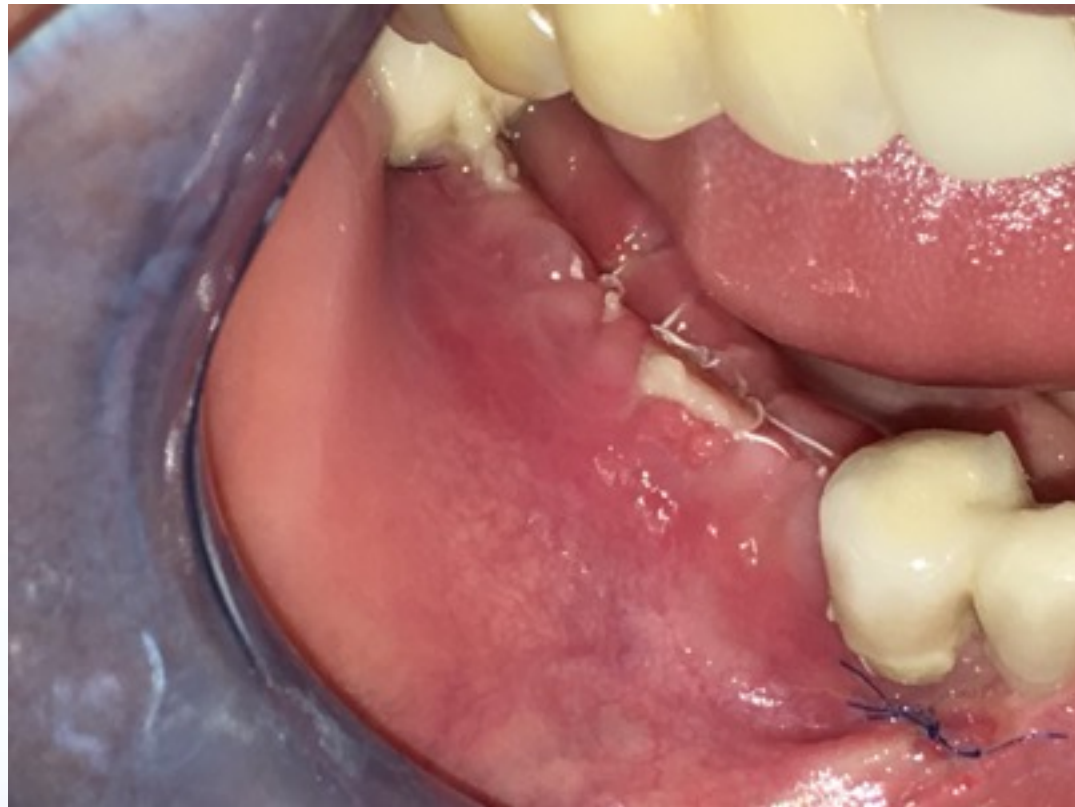Patient with advanced alveolar atrophy underwent bilateral reconstruction with BMP/titanium mesh



Immediate Post-Op: patient anticipated to have advanced swelling for 2+ weeks



1 Week Post-op: Patient showing minimal swelling. Accelerated Healing Observed Equivalent to 2-3 weeks



Summary: Bilateral Mandibular reconstruction with BMP and Ti mesh/ membrane

- Patient was using VEGA Recovery Kit (10 days regimen)
- Patient experienced significantly less post-op swelling
 - One week post-op, patient's swelling was 85-90% resolved
 - Accelerated reduction in swelling observed
 - Peak swelling was 30-50% less than usually anticipated
- Less pain medication
 - Only 4 Norco pain pills taken for post-op pain management