

# Gingival Lesion Removal: Post-op pain management and accelerated healing using StellaLife

## Description

37 y/o patient with non-contributory medical history presented for removal of a gingival lesion. The patient reported that lesion was removed twice previously but recurred.

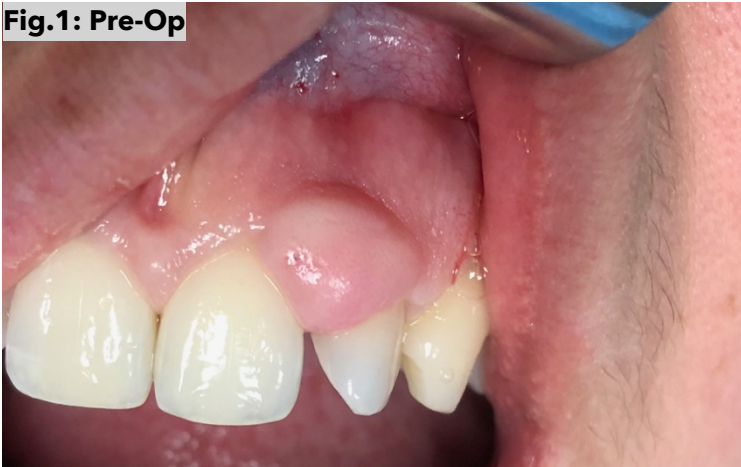## Method

After a clinical evaluation, the decision was made to perform a wide resection of the lesion. The differential diagnosis included fibroma, POF. The Patient was placed on StellaLife VEGA Recovery Kit starting 3-days prior the surgery for post-op management. No other prescriptions were issued.

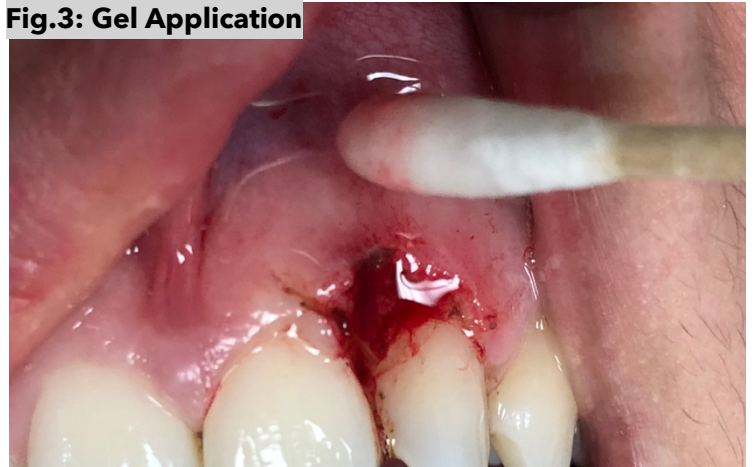
## Conclusion

The patient was seen for 5 days post-op visit. A clinical evaluation revealed accelerated healing (Fig.4). The patient reported no discomfort and stated that StellaLife was adequate for post-op pain management. The StellaLife VEGA Oral Care Recovery Kit provided the pain management and accelerated healing by secondary intention after resection of a gingival lesion.

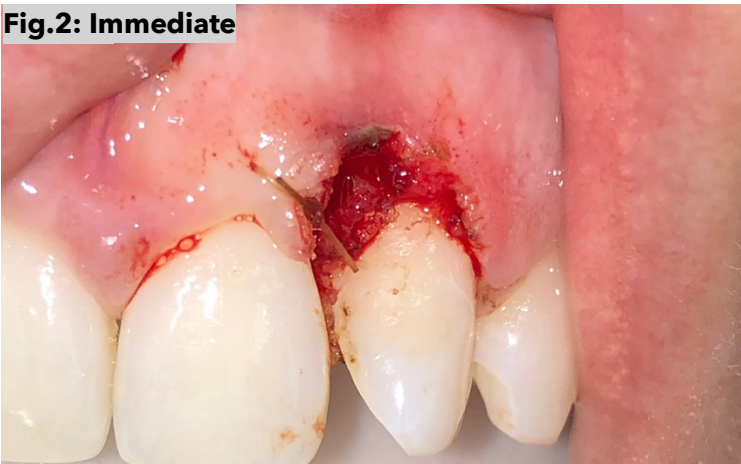**Fig.1: Pre-Op**



**Fig.3: Gel Application**



**Fig.2: Immediate**



**Fig.4: 5 Days Post-Op**

