

www.stellalifehealing.com



Dedicated to Oral Health Through INTELLIGENT HEALING® Better Oral Health. Naturally.

**Five Case Series Report: Vertical and Horizontal Alveolar Ridge Reconstruction
Using StellaLife® VEGA® Oral Care Recovery Kit for post-op healing.**

Walter Tatch, DDS, FACOMS

Updated: October, 2017

CONTACT: 800.828.7265 or info@stellalifehealing.com

Case Report: Vertical and Horizontal Alveolar Ridge Reconstruction

- **Materials and Methods:**

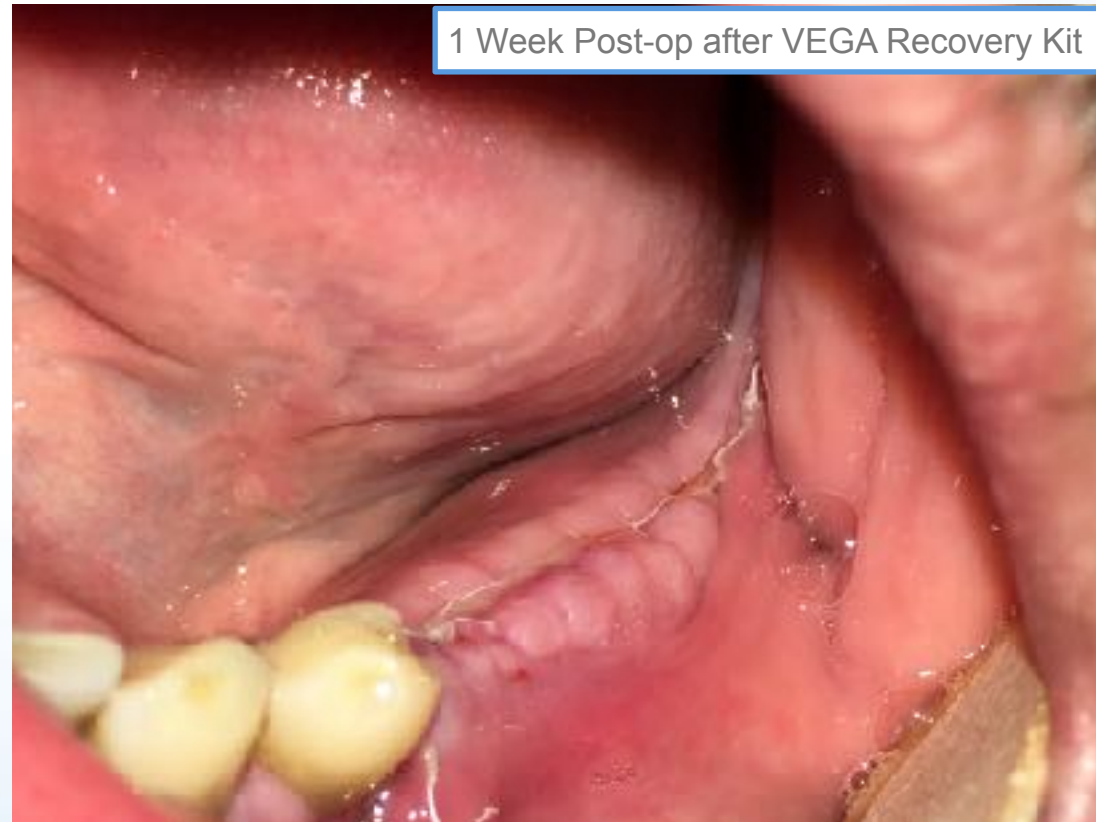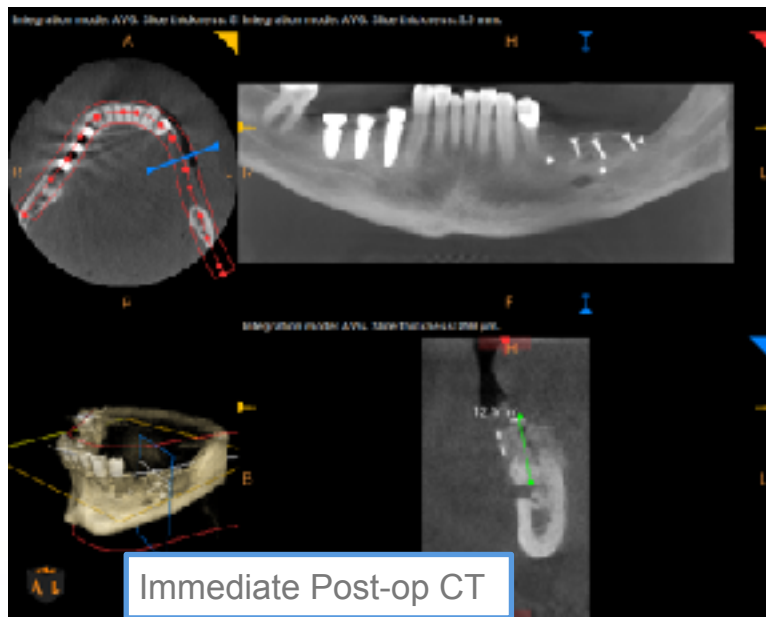
- Five patients ranging in age 45-60 y/o, ASAll, one male, four females underwent advanced bone reconstruction using Ti-reinforced membrane and BMP/Miner-Oss.
 - Pre-op: 2 gm of Amoxicillin.
 - Post-op: Amoxicillin, Norco and VEGA Oral Care Recovery Kit.
- Patients were seen for 1 week follow-up and reported no pain, minimal to no swelling.

- **Results:** Exam revealed advanced healing (equivalent of anticipated few weeks post-op) and no edema.

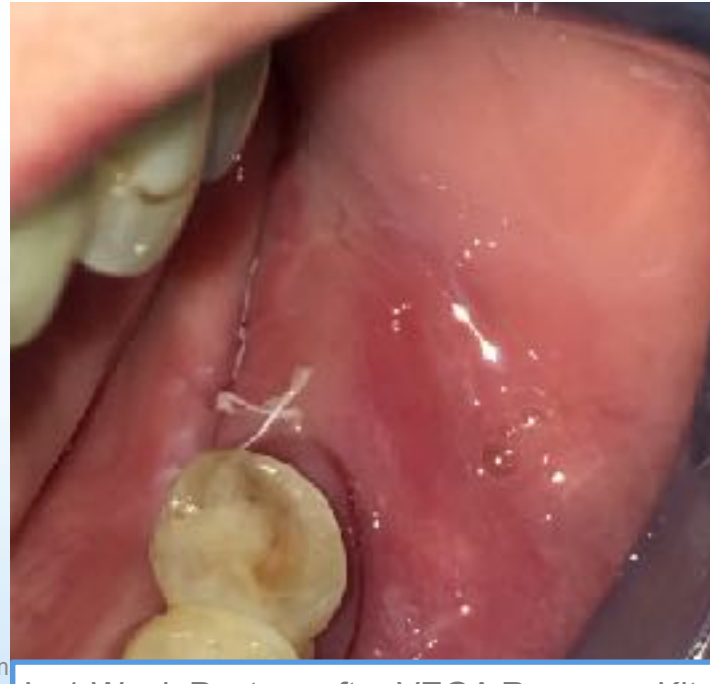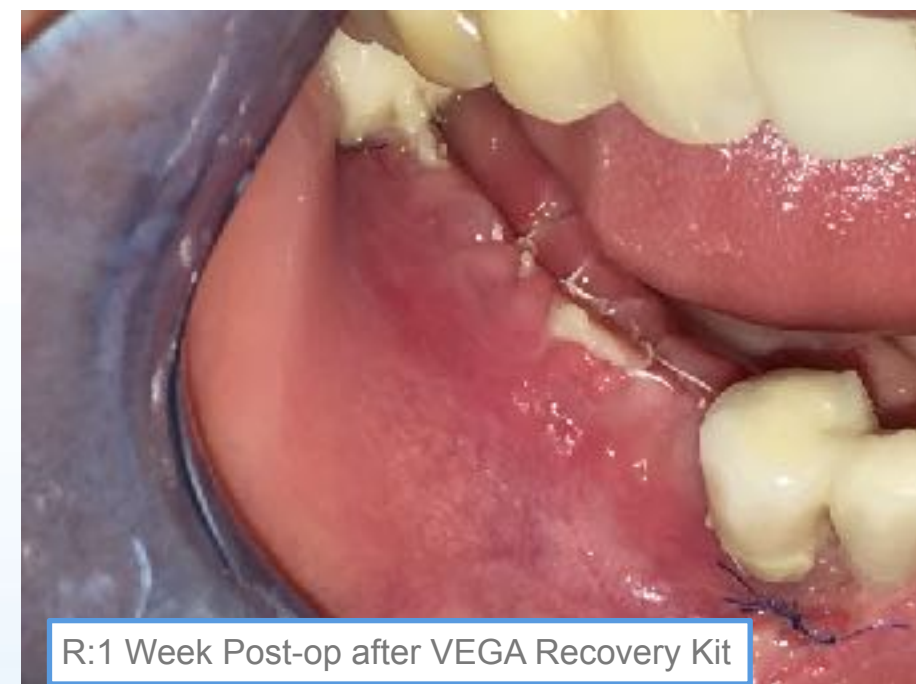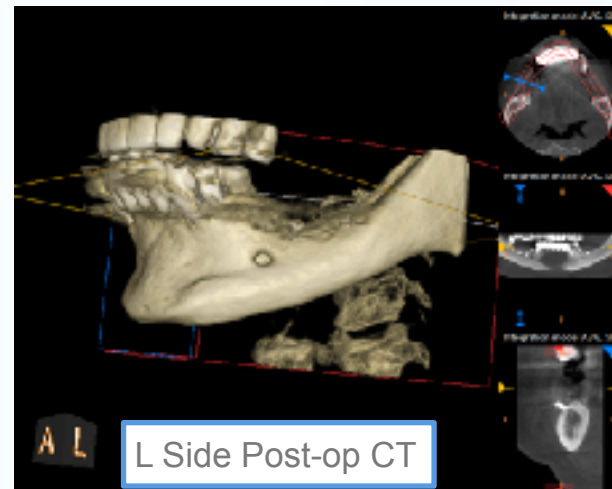
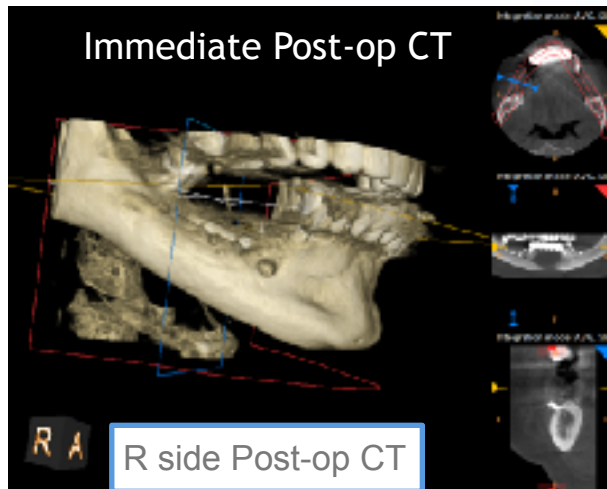
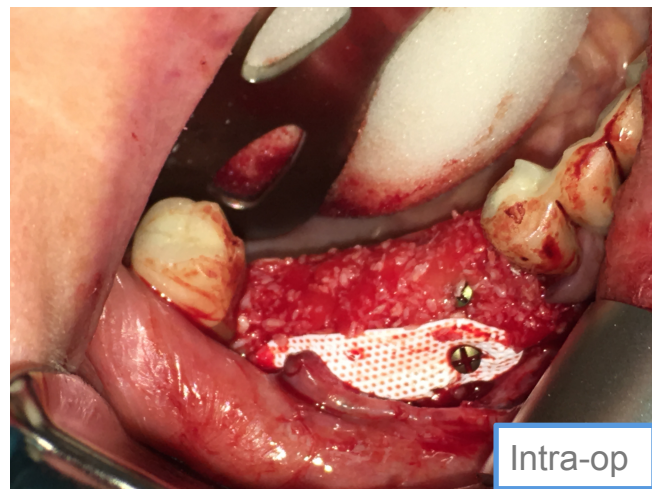- **Conclusion:**

- Patients exhibited advanced Post-Op healing, quick resolution of post-op edema and good analgesia control using StellaLife® VEGA® Oral Care Recovery Kit (10 days regimen).

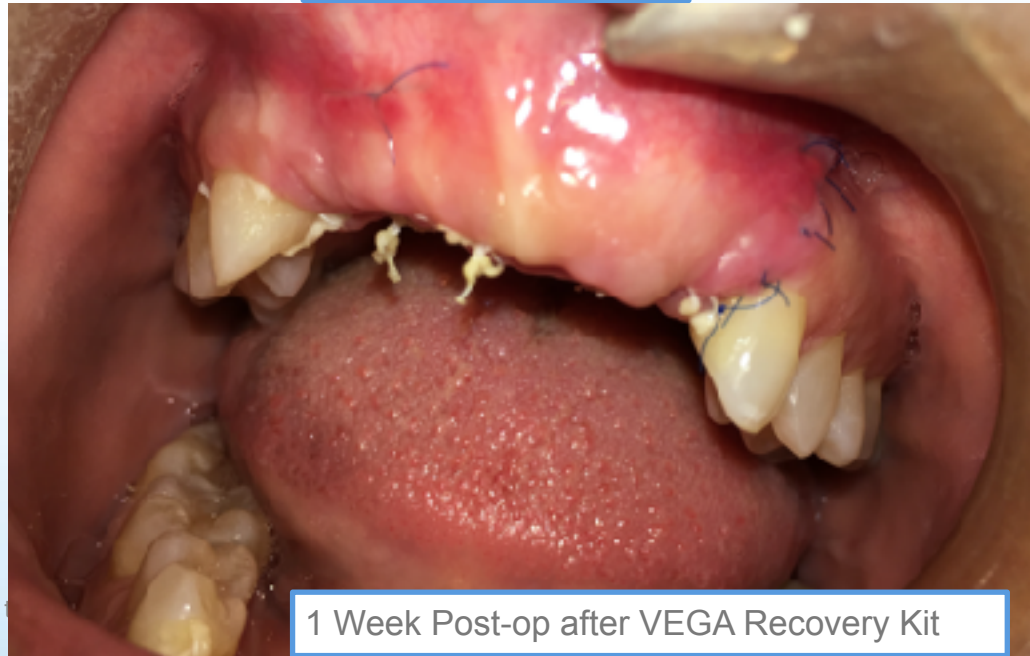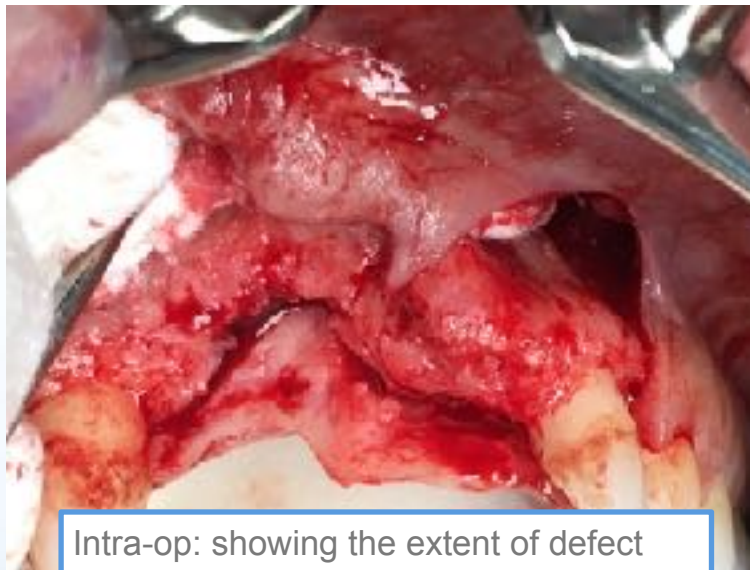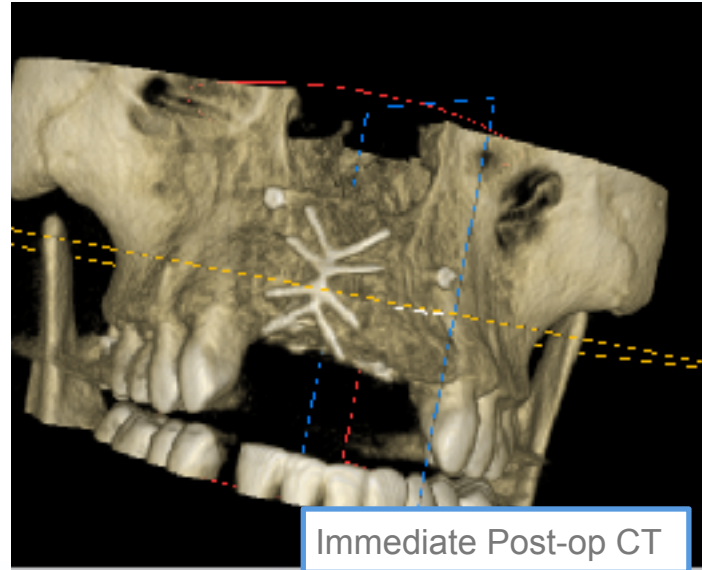
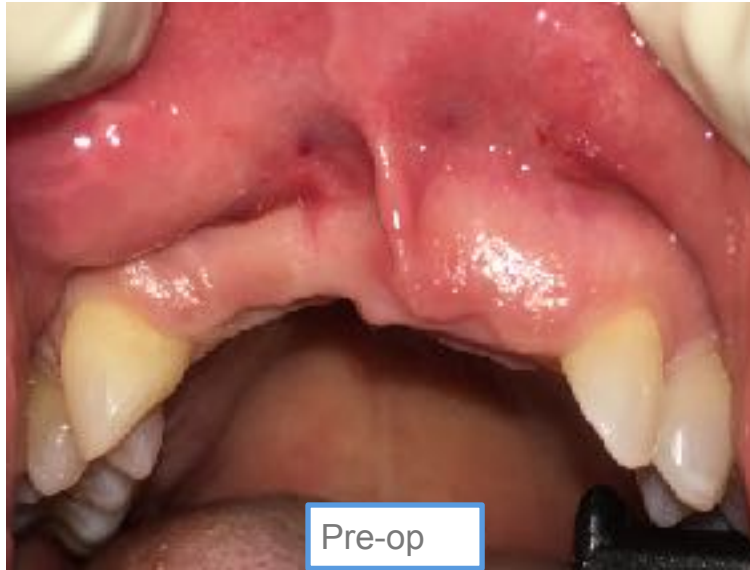Case 1: Vertical and Horizontal Alveolar Ridge Reconstruction



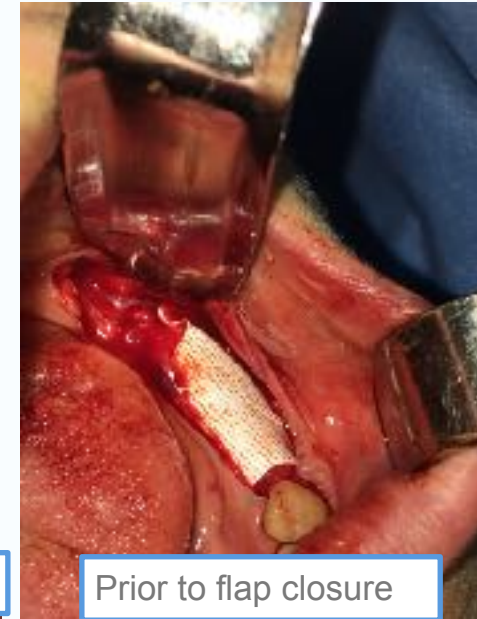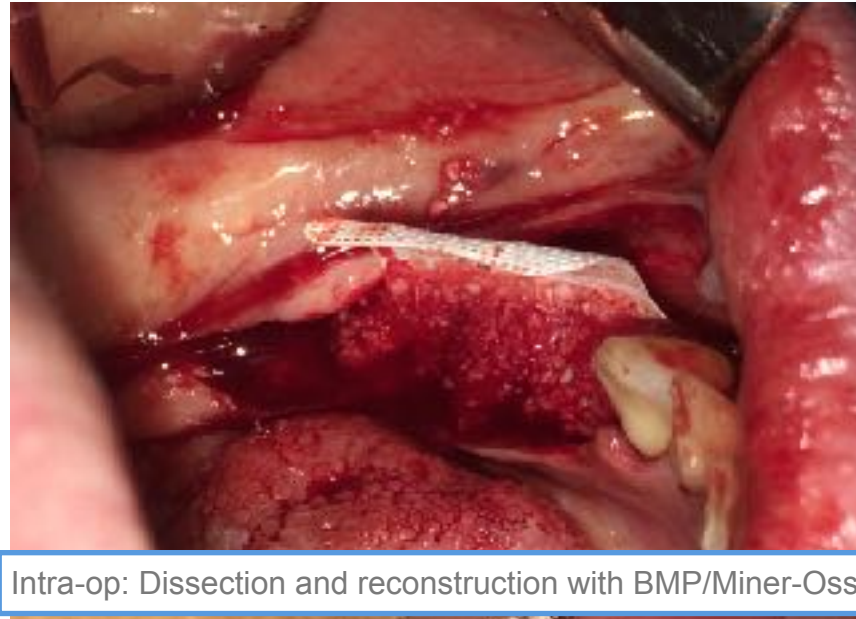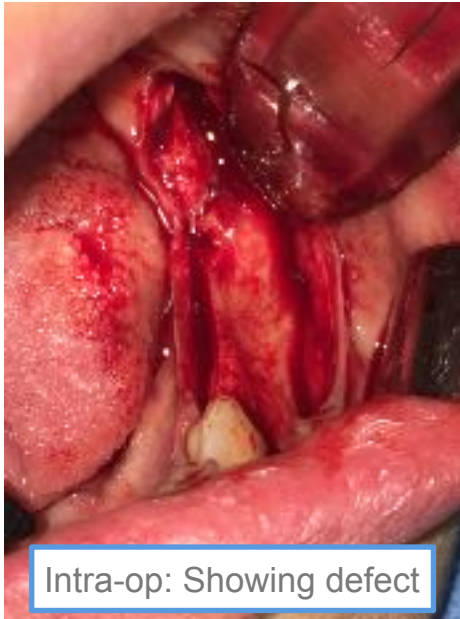Case 3: Vertical and Horizontal Alveolar Ridge Reconstruction



Case 4: Anterior Vertical and Horizontal Alveolar Ridge Reconstruction



Case 5: Vertical and Horizontal Alveolar Ridge Reconstruction



Post-op: In-office application of VEGA Gel

