



Effects of kinesiotaping versus non-steroidal anti-inflammatory drugs and physical therapy for treatment of pes anserinus tendino-bursitis: A randomized comparative clinical trial

Kaynoosh Homayouni, Shima Foruzi & Fereshte Kalhori

To cite this article: Kaynoosh Homayouni, Shima Foruzi & Fereshte Kalhori (2016): Effects of kinesiotaping versus non-steroidal anti-inflammatory drugs and physical therapy for treatment of pes anserinus tendino-bursitis: A randomized comparative clinical trial, The Physician and Sportsmedicine, DOI: [10.1080/00913847.2016.1199251](https://doi.org/10.1080/00913847.2016.1199251)

To link to this article: <http://dx.doi.org/10.1080/00913847.2016.1199251>



Accepted author version posted online: 08 Jun 2016.
Published online: 22 Jun 2016.



Submit your article to this journal [↗](#)



Article views: 22



View related articles [↗](#)



View Crossmark data [↗](#)

CLINICAL FEATURE
ORIGINAL RESEARCH

Effects of kinesiotaping versus non-steroidal anti-inflammatory drugs and physical therapy for treatment of pes anserinus tendino-bursitis: A randomized comparative clinical trial

Kaynoosh Homayouni, Shima Foruzi and Fereshte Kalhori

Department of Physical Medicine and Rehabilitation, Shiraz University of Medical Sciences, Shiraz, Iran

ABSTRACT

Objective: Pes anserinus tendino-bursitis is a condition caused by repetitive friction over the bursa or direct trauma to knee joint and it presents with proximal medial tibial pain and swelling. The aim of this study is to determine the effects of kinesiotaping in comparison with naproxen and physical therapy in treatment of pes anserinus tendino-bursitis.

Methods: In a randomized comparative clinical trial 56 patients with clinical diagnosis of pes anserinus tendino-bursitis were randomly assigned to kinesiotaping and naproxen/physical therapy (28 patients in each group). Kinesiotaping on the tender area in the form of space-correction (lifting) technique was used and repeated for three times with a one-week interval. Another group received naproxen (250mg TID for 10 days) and ten sessions of daily physical therapy. The visual analog scale (VAS) was used for evaluation of pain. The depth of swelling of the area was measured with sonography before and after treatment. Wilcoxon signed ranks test has been used for determining the influence of interventions on pain (VAS) and swelling scores in each group. The ANCOVA (Analysis of covariance) test was applied for comparing the influence of interventions on VAS and swelling scores after adjustment for co-variables.

Results: At end of the study, 27 patients remained in the kinesiotaping group and 19 patients in naproxen/physical therapy group. Treatment with kinesiotaping significantly decreased the pain ($P=0.0001$) and swelling scores ($P=0.0001$) in comparison with naproxen/physical therapy after adjustment for baseline characteristics. Kinesiotaping was safe without any complications except for a mild local skin irritation in one patient.

Conclusion: Kinesiotaping is more effective than naproxen plus physical therapy in reduction of pain and swelling in patients with pes anserinus tendino-bursitis.

Clinical trial registration: www.ClinicalTrials.gov identifier is NCT01680263

ARTICLE HISTORY

Received 10 March 2016
Revised 28 May 2016
Accepted 6 June 2016
Published online
23 June 2016

KEYWORDS

Athletic tape; knee joint; bursitis; tendinopathy; sports medicine

Introduction

The pes anserinus is a mixed tendon formed by coalescence of the sartorius, gracilis, and semitendinosus tendons; it inserts onto the proximal anteromedial tibia about 5 cm distal to the medial tibial joint line [1–3]. When the three muscles that form the pes anserinus were contracted, it results in knee flexion and tibial internal rotation [4]. The pes anserinus bursa lies deep to the pes anserinus tendon, which serves to reduce friction between the superficially located pes anserinus tendon, and structures including the medial tibia and the medial collateral ligament that lies deep to it [2]. Pes anserinus tendino-bursitis, first described in 1937, is a condition caused by repetitive friction over the bursa or direct trauma [4,5]. The prevalence of pes anserinus tendino-bursitis is variable (2.5–70%) in patients with knee pain [1–4,6–26]. Based upon clinical experience and limited available evidence, risk factors for pes anserinus tendino-bursitis include female sex, obesity, diabetes, knee osteoarthritis, and knee malalignment [27]. The variable prevalence in the literature is

probably due to studies in different populations with diverse prevalence of risk factors. Clinical presentation of the disease is usually proximal medial tibial pain and swelling 4–5 cm distal to the medial tibial joint line. Ascending or descending stairs or rising from a seated position may aggravate their symptoms. Patients with this condition have tenderness to palpation in the region of their pes anserinus bursa and may have local edema [1,13]. Diagnosis of pes anserinus tendino-bursitis is clinical, but diagnostic studies such as ultrasonography, computed tomography, and magnetic resonance imaging can be used to diagnose this condition [21–28].

The treatment of pes anserinus tendino-bursitis includes refraining from aggravating activities, local modalities such as heat, ice, ultrasound, iontophoresis, phonophoresis, electrical stimulation, transcutaneous electrical nerve stimulation (TENS), nonsteroidal anti-inflammatory drugs (NSAIDs) and injections with either corticosteroids or local anesthetics [1,3,5–7,9,14,16,18,21–26].

Kinesio Tape, also called Kinesio Tex Tape, is the original elastic adhesive tape developed by Dr. Kenzo Kase in 1979. It is a new treatment modality with unproven effect for various musculoskeletal injuries [29,30]. Kinesiotaping is a cotton strip with an acrylic adhesive that is used for treating athletic injuries and a variety of physical conditions. The therapeutic effect of the tape is to relax the overused muscles. Advocates claim that the wave pattern found on the kinesiotaping has a lifting effect on the skin which can diminish swelling and inflammation via improving circulation and reduce pain by removing pressure from pain receptors.

The aim of this study is to compare the effectiveness and safety of kinesiotaping with other traditional therapy (naproxen plus physical therapy) for the treatment of pes anserinus tendino-bursitis.

Patients and methods

Design

A prospective randomized comparative single-blind clinical trial was designed (Figure 1). The Local Research Ethics Committee of Shiraz University of Medical Sciences approved the study (CT-2012-106). After explanation of the exact nature of the study, a written informed consent was signed by each participant. Weight (kg) and height (m) were measured for calculation of body mass index (BMI). Soft tissue sonography of the pes anserinus bursa was used over the medial aspect of tibia below the medial tibial joint line. The interventions were conducted at the Physical Medicine and Rehabilitation Clinic in Shiraz University of Medical Sciences, Shiraz, Iran, between February and June 2014. The dependent variables, visual analog scale (VAS), and swelling scores were measured at baseline and after interventions by one blinded physiatrist.

Sample size

Sample size was calculated using the G*Power version 3.1.7 (Heinrich–Heine–University) software [31]. Significance level was set at 0.05 and an effect size of 0.65 with two-sided calculation was used. By these assumptions, to achieve a power of 0.95, a total sample size of 36 participants was necessary. Conservatively, 56 subjects were recruited due to our previous experiences.

Patients

A total of 60 patients with clinical diagnosis of pes anserinus tendino-bursitis who referred to the Physical Medicine and Rehabilitation Clinic in Shiraz University of Medical Sciences were screened for eligibility. The inclusion criteria were (1) age of 20–70 years, (2) confirmation of the clinical diagnosis of pes anserinus tendino-bursitis by one expert physiatrist, and (3) duration of symptoms for more than 3 months. The exclusion criteria were previous history of surgery on the knee joint, recent trauma to the affected knee joint, systemic, and rheumatic diseases like diabetes mellitus and rheumatoid arthritis, and a history of NSAIDs induced acid-peptic disease. One participant had a history of recent trauma and three patients were under treatment for rheumatoid arthritis. Fifty-six patients with mean age of 49.9 ± 6.7 years entered into the study by a simple drawing of lots and were randomly assigned in 1:1 ratio to parallel groups (28 patients in each group), including a kinesiotaping and a naproxen/physical therapy group. To have a random allocation, each patient received a number written on paper which was unknown to researchers that allowed participants' assignment to the intervention groups. One patient in kinesiotaping group had lost the follow-up. In naproxen/physical therapy group, three patients had lost the follow-up due to unknown reason, three patients discontinued the naproxen due to dyspepsia, and three patients did not

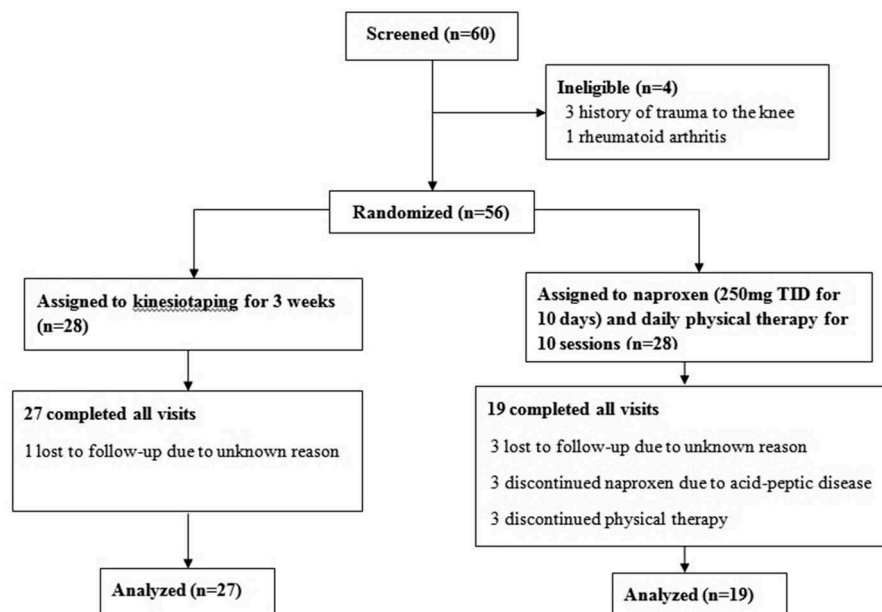


Figure 1. Flow diagram of the study, showing numbers of participants who were randomly assigned, received the intended treatment, and were analyzed for the outcomes.

Table 1. Baseline characteristics of the pes anserinus tendino-bursitis patients ($n = 46$).

	Kinesiotaping group ($n = 27$)	Naproxen + physical therapy group ($n = 19$)	<i>P</i> -value
Age (years)	49.85 ± 6.8	50.0 ± 6.6	0.955
Sex (male/female)	4/23	2/17	0.671
Duration of symptoms (months)	4.85 ± 1.0	4.58 ± 0.9	0.396
Body mass index (kg/m ²)	28.32 ± 1.7	27.94 ± 1.9	0.463
VAS	8.07 ± 2.4	6.63 ± 3.0	0.117
Swelling score	2.13 ± 0.7	2.42 ± 0.6	0.824

VAS: Visual analog scale.

complete the physical therapy sessions. Finally, 46 patients (27 in the kinesiotaping group and 19 in naproxen/physical therapy group) were remained in the study. The baselines characteristics of all participants are shown in Table 1.

Interventions

The kinesiotaping was applied for 3 weeks over the tender area with space-correction technique. As shown in Figure 2, the space-correction (lifting) technique was used to create more space directly above the area of pain and swelling. The increased space created reduces pressure by lifting the skin away from the injured site. Kinesiotaping was repeated three times with a 1-week interval. Another group received treatment with naproxen (250 mg TID for 10 days) and 10 sessions of daily physical therapy. The physical therapy was applied for all patients by one physiotherapist with use of hot pack, TENS, and phonophoresis. All of the participants were advised to have a relative rest and reduce the strain on the injured knee, avoid climbing stairs, prolonged knee flexion position of less than 90°, and other irritating activities. In each session, the adherence of participants to these instructions was monitored and reminded by physiotherapist.

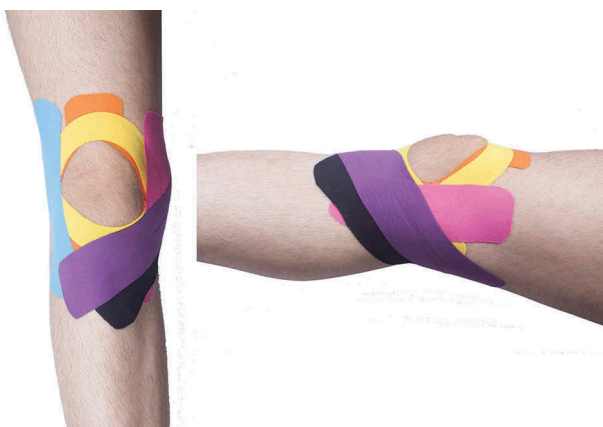

Figure 2. Kinesiotaping of knee joint for pes anserinus tendino-bursitis with space-correction technique.

Measurements and outcomes

BMI was calculated as the ratio of body weight to height squared. The pain was evaluated by standard pain VAS. The swelling score was determined with use of soft tissue sonography. The maximum depth of edematous area was measured in supine position with a high-frequency (10 MHz) linear array transducer and graded as score 1: <0.5 cm; score 2: 0.5–1 cm, and score 3: >1 cm. The primary outcome measures included differences in VAS score and swelling score before and after end of interventions. The secondary outcome measure was the number of participants with adverse events. All of the participants were evaluated by one expert physiatrist blinded to treatment allocations at the beginning and end of the study.

Statistical procedures

The statistical analysis was performed using SPSS for Windows (version 16.0, SPSS Inc., Chicago, IL). The data were evaluated for normal distribution by Kolmogorov–Smirnov test. Due to non-normal distribution of the data, the Mann–Whitney test was used for comparison of baseline characteristics between treatment groups and the Wilcoxon signed ranks test has been used for determining the influence of treatment modalities on pain (VAS) and swelling scores in each group. The ANCOVA (Analysis of covariance) test was applied for comparing the influence of interventions on VAS and swelling scores after adjustment for baseline data including age, gender, BMI, duration of symptoms as co-variables. A *P* value of less than 0.05 was considered as significant.

Results

In both treatment groups there was a significant decrease in pain (VAS) score (kinesiotaping group: $Z = -4.56$, $P = 0.0001$; naproxen/physical therapy group: $Z = -3.45$, $P = 0.001$) and swelling score (kinesiotaping group: $Z = -4.69$, $P = 0.0001$; naproxen/physical therapy: $Z = -4.14$, $P = 0.0001$) (Table 2).

Although both therapeutic interventions were effective for treatment of pes anserinus tendino-bursitis, the kinesiotaping

Table 2. The mean VAS and mean swelling score before and after treatment in both intervention groups.

Variables	Kinesiotaping group ($n = 27$)		Naproxen + physical therapy group ($n = 19$)	
VAS (baseline)	8.07 ± 2.4	$Z = -4.56$	6.63 ± 3.0	$Z = -3.45$
VAS (after treatment)	1.29 ± 1.6	P value = 0.0001	3.53 ± 2.7	P value = 0.001
Δ VAS	6.78 ± 1.9		3.11 ± 2.8	
Swelling score (baseline)	2.13 ± 0.7	$Z = -4.69$	2.42 ± 0.6	$Z = -4.14$
Swelling score (after treatment)	0.48 ± 0.61	P value = 0.0001	1.26 ± 0.9	P value = 0.0001
Δ Swelling score	1.80 ± 0.6		1.26 ± 0.5	

VAS: Visual analog scale.

was significantly more effective on reduction of pain (VAS) ($P = 0.0001$) and swelling scores ($P = 0.0001$) after adjustment for baseline characteristics including age, gender, BMI, duration of symptoms, baseline VAS, and swelling scores as co-variables.

The kinesiotope had no complications and only one patient had mild local skin irritation that followed the complete treatment course. Three patients in the naproxen/physical therapy group have developed dyspepsia and discontinued the naproxen.

Discussion

According to the results of this study, both interventions (kinesiotope and naproxen/physical therapy) are effective for treatment of pes anserinus tendino-bursitis with decreasing pain and swelling. Comparison of treatment modalities revealed that kinesiotope is more effective than naproxen/physical therapy.

Lack of administration of drugs for the whole period and lack of attendance in physical therapy periods are the major reasons for treatment failure of many inflammatory musculoskeletal system disorders. Perhaps the superiority of kinesiotope to medical treatment is because there is less need to the patient's cooperation in kinesiotope therapy. Another reason which shows kinesiotope is more effective than medical treatments is due to its function on the knee that is independent of the patient's activity. Kinesiotope was continuously applied during all of the patient's activity and has its continuous influence even if the patient performs activities which cause pressure on the tendons. The manufacturer claims that the kinesiotope method is a rehabilitative taping technique that is designed to facilitate the body's natural healing process while providing support and stability to muscles and joints without restricting the body's range of motion as well as providing extended soft tissue manipulation to prolong the benefits of manual therapy administered within the clinical setting. Kinesiotope alleviates pain and facilitates lymphatic drainage by lifting the skin microscopically. This lifting increases interstitial space and allowing for a decrease in inflammation of the affected areas and reducing pressure while enabling a more effective flow of blood and lymphatic fluid in and out of the target area [Kinesio Taping® Method. Available at <http://www.kinesiotaping.com>], although there is no evidence for this. The obtained effects of kinesiotope are probably from continuous local pressure and restriction of specific movements. However, in patients who receive medical and physical treatment, there is more risk of pressure on their tendons which are inflamed and do not have any external protection.

To the best of our knowledge, there is no clinical trial to show the effectiveness of kinesiotope for treatment of pes anserinus tendino-bursitis. Bici et al. evaluated the effects of kinesiotope on functional performance of basketball players with chronic inversion ankle sprains and improvements were seen in some functional performance tests [32]. Another study on patients with mechanical neck pain compared the effectiveness of cervical spine thrust manipulation and

kinesiotope applied to the neck and revealed that both modalities exhibited similar reductions in neck pain intensity and disability and similar changes in active cervical range of motion [33].

This is a randomized single-blind clinical trial for comparison of two different modalities for treatment of pes anserinus tendino-bursitis. All of the patients were evaluated before starting the interventions and for outcome measures by one expert physiatrist blinded to the treatments. With regard to the patients' pain before and after treatment, in both groups the pain decreased after treatment. But the amount of pain reduction in the kinesiotope group was much more than the naproxen/physical therapy group. This supports the effect of kinesiotope on pain reduction by removing pressure from pain receptors. The local swelling (edema) that was evaluated with soft tissue sonography was decreased after treatment in both groups. The reduction was also more obvious in the kinesiotope group, which supports the effect of kinesiotope on decreasing inflammation. It should be noted that there are some limitations in this study. The sample size was small and the patients had a short-term follow-up. In addition, it would have been better to have more objective assessment results. The study design was single-blinded and did not include a placebo group to rule out placebo effect or natural changes over time as potential reasons for the improvements achieved in both groups.

Conclusion

This comparative clinical study shows that kinesiotope can be an effective, nonaggressive treatment without any adverse effect for pes anserinus tendino-bursitis and is superior to naproxen plus physical therapy. With regard to the side effects of NSAIDs and contraindications of their prescription in specific situations such as acid-peptic disease and renal failure, it seems that use of kinesiotope in treatment of pes anserinus tendino-bursitis may be a suitable treatment modality. Further randomized, double-blind, placebo-controlled clinical trials with a larger sample and longer follow-up are needed for confirmation of the effects and safety of kinesiotope for treatment of pes anserinus tendino-bursitis.

Acknowledgements

The authors wish to thank the participants in this study. We thank Dr. Najaf Zare, the statistician, for his kind help in statistical analysis at the Center of Clinical Research Development at the Nemazee Teaching Hospital. We are grateful to S. Hannan Kashfi (MA in English teaching and faculty of Larestan School of Medical Sciences) for his valuable cooperation in English proofreading of the manuscript.

Declaration of interest

The authors have no relevant affiliations or financial involvement with any organization or entity with a financial interest in or financial conflict with the subject matter or materials discussed in the manuscript. This includes employment, consultancies, honoraria, stock ownership or options, expert testimony, grants or patents received or pending, or royalties.

References

1. Yoon HS, Kim SE, Suh YR, et al. Correlation between ultrasonographic findings and the response to corticosteroid injection in pes anserinus tendinobursitis syndrome in knee osteoarthritis patients. *J Korean Med Sci.* 2005;20:109–112.
2. Marra MD, Crema MD, Chung M, et al. MRI features of cystic lesions around the knee. *Knee.* 2008;15:423–438.
3. Handy JR. Anserine bursitis: a brief review. *South Med J.* 1997;90:376–377.
4. Rennie WJ, Saifuddin A. Pes anserine bursitis: incidence in symptomatic knees and clinical presentation. *Skel Radiol.* 2005;34:395–398.
5. Moschowitz E. Bursitis of sartorius bursa, an undescribed malady simulating chronic arthritis. *JAMA.* 1937;109:1362.
6. Abeles M. Anserine bursitis. *Arthr Rheum.* 1986;29:812–813.
7. Brookler MI, Mongan ES. Anserina bursitis. a treatable cause of knee pain in patients with degenerative arthritis. *Calif Med.* 1973;119:8–10.
8. Unlu Z, Ozmen B, Tarhan S, et al. Ultrasonographic evaluation of pes anserinus tendino-bursitis in patients with type 2 diabetes mellitus. *J Rheumatol.* 2003;30:352–354.
9. Uson J, Aguado P, Bernad M, et al. Pes anserinus tendinobursitis: what are we talking about? *Scand J Rheumatol.* 2000;29:184–186.
10. Cohen SE, Mahul O, Meir R, et al. Anserine bursitis and noninsulin dependent diabetes mellitus. *J Rheumatol.* 1997;24:2162–2165.
11. De Miguel Mendieta E, Cobo IT, Usón JJ, et al. Clinical and ultrasonographic findings related to knee pain in osteoarthritis. *Osteoarthritis Cartilage.* 2006;14:540–544.
12. Fireman HH. Don't forget anserine bursitis [comment]. *CMAJ.* 2001;165:1300.
13. Forbes JR, Helms CA, Janzen DL. Acute Pes anserine bursitis: MR imaging. *Radiology.* 1995;194:525–527.
14. Gnanadesigan N, Smith RL. Knee pain: osteoarthritis or anserine bursitis? *J Am Med Directors Assoc.* 2003;4:164–166.
15. Hall FM, Joffe N. CT imaging of the anserine bursa. *Am J Roentgenol.* 1988;150:1107–1108.
16. Hemler DE, Ward WK, Karstetter KW, et al. Saphenous nerve entrapment caused by PES anserine bursitis mimicking stress fracture of the tibia. *Arch Phys Med Rehab.* 1991;72:336–337.
17. Hill CL, Gale DR, Chaisson CE, et al. Periarticular lesions detected on magnetic resonance imaging: prevalence in knees with and without symptoms. *Arthr Rheum.* 2003;48:2836–2844.
18. Kang I, Han SW. Anserine bursitis in patients with osteoarthritis of the knee. *South Med J.* 2000;93:207–209.
19. Koh WL, Kwek JW, Quek ST, et al. Clinics in diagnostic imaging. Pes anserine bursitis. *Singapore Med J.* 2002;43:485–491.
20. Maheshwari AV, Muro-Cacho CA, Pitcher JD Jr. Pigmented villonodular bursitis/diffuse giant cell tumor of the pes anserine bursa: A report of two cases and review of literature. *Knee.* 2007;14:402–407.
21. McCarthy CL, McNally EG. The MRI appearance of cystic lesions around the knee. *Skel Radiol.* 2004;33:187–209.
22. Muchnick J, Sundaram M. Radiologic case study. Pes anserine bursitis. *Orthopedics.* 1997;20(1100):092–4.
23. Nokes SR, Smith T. Acute pes anserine bursitis. *J Ark Med Soc.* 2007;104:112.
24. Voorneveld C, Arenson AM, Fam AG. Anserine bursal distention: diagnosis by ultrasonography and computed tomography. *Arthritis Rheum.* 1989;32:1335–1338.
25. Zeiss J, Coombs RJ, Booth RL Jr., et al. Chronic bursitis presenting as a mass in the pes anserine bursa: MR diagnosis. *J Comp Assisted Tomogr.* 1993;17:137–140.
26. Larsson LG, Baum J. The syndrome of anserina bursitis: an overlooked diagnosis. *Arthritis Rheum.* 1985;28:1062–1065.
27. Alvarez-Nemegyei J. Risk factors for pes anserinus tendinitis/bursitis syndrome: a case control study. *J Clin Rheumatol.* 2007;13:63.
28. Clapp A, Trecek J, Joyce M, et al. Radiologic case study. Pes anserine bursitis. *Orthopedics.* 2008;31(306):407–408.
29. Morris D, Jones D, Ryan H, et al. The clinical effects of Kinesio® Tex taping: a systematic review. *Physiother Theory Pract.* 2013;29(4):259–270.
30. Mostafavifar M, Wertz J, Borchers J. A systematic review of the effectiveness of kinesio taping for musculoskeletal injury. *Phys Sportsmed.* 2012;40(4):33–40.
31. Faul F, Erdfelder E, Lang AG, et al. G*Power 3: a flexible statistical power analysis program for the social, behavioral, and biomedical sciences. *Behav Res Methods.* 2007;39:175–191.
32. Bicipi S, Karatas N, Baltaci G. Effect of athletic taping and kinesio-taping® on measurements of functional performance in basketball players with chronic inversion ankle sprains. *Int J Sports Phys Ther.* 2012;7(2):154–166.
33. Saavedra-Hernández M, Castro-Sánchez AM, Arroyo-Morales M, et al. Short-term effects of kinesiotaping versus cervical thrust manipulation in patients with mechanical neck pain: a randomized clinical trial. *J Orthop Sports Phys Ther.* 2012;42(8):724–730.