



The Centre for
Biofield Sciences

Integrated Health

**ELECTRODOT ELECTROMAGNETIC HARMONISER
RESEARCH 2009**

DOCUMENT CONTENTS

- General Article of Research,
- Abstract,
- Methodology,
- Result and conclusion,
- Research Case Studies, Experimental Group,
- Research Case Studies, Control Group.

GENERAL ARTICLE

Introduction

The following document is a full version of the research project undertaken during February - March 2009 in India at the World Peace Centre, MIT College, Pune.

STUDY OBJECTIVE:

To determine the efficacy of the electroDOT (SolarWind) Electromagnetic Harmoniser over negative effects of use of mobile phone.

TIME PERIOD OF THE STUDY:

February-April 2009.

PRIMARY DATA COLLECTION:

Centre for Biofieldsciences.

AIM

The aim of this research project is to examine the changes in energy fields and chakras so as to prove the efficacy of electrodot (SolarWind) Electromagnetic Harmonisers over negative effects of mobile phone use. The following three established devices were chosen to be used for the comparison between before and after scans:

1 POLYCONTRAST INTERFERENCE PHOTOGRAPHY (PIP)

2 GAS DISCHARGE VISUALISATION (GDV)

3 RESONNANT FIELD IMAGING (RFI)

The Doctors& Researchers working on the project were monitoring all the tests and ensured that the co-relation between the tests with the three devices was carried out perfectly according to the protocol and standard norms & conditions.

ABSTRACT

- **Research co-coordinators:**

Dr.Thornton Streeter

Dr.Anuja Ranade

Dr.Aniruddha Gandhi

Dr.Bhagyashri Nilkanth

Dr.Vaibhav Lunkad.

- **Facilitated by:**

Shivali Dandekar

Sudhir Neurgaoankar

A K Zutshi

Bapu Sanap

Mrs.Anjali

ABOUT ELECTRODOT (SOLARWIND) HARMONISERS:

The electroDOT (SolarWind) electromagnetic harmoniser has been developed to counteract the harmful effects of electromagnetic fields produced by the electronic equipment we use.

Daily exposure to EMF`s has an impact on our life, vitality levels, energy levels and health. We can produce an objective assessment of these impacts through PIP, GDV and RFI scanning techniques.

METHODOLOGY

100 subjects were scanned, who have been using mobile phones over a period of 1 year. Participants were selected randomly through local newspaper advertisements and university notices.

Each participant was booked in for two appointments each lasting around 1 hour. Initially they arrived at the clinic and were assigned a participant number to maintain confidentiality. They completed consultation consent forms and then underwent the first round of three scans.

All these participants were then rescanned with the same three devices, again in a random order, on second visit.

Visit 1: Subject was clear of immediate exposure to mobile phone radiation for at least one hour.

RFI (resonant frequency imaging), GDV (Gas discharge visualization) and PIP (Poly contrast interference photography), scans were carried out.

The following PIP scans were done on day 1.

PIP 1: 'Before' scan - without mobile or electroDOT

PIP 2: Subject holding mobile on standby without electroDOT.

PIP 3: Mobile without electroDOT during call.

PIP 4: Mobile on standby- electroDOT introduced

PIP 5: Mobile with electroDOT during call - after 30 seconds

PIP 6: Mobile with electroDOT during call – after 1 min

PIP 7: Mobile with electroDOT during call – after 5 min

A mobile with electroDOT attached was given to the subject to use for a period of 2 days, followed by:

Visit 2: GDV and RFI repeat/after scans were done.

PIP 8: 'After' scan – without mobile or electroDOT

CONTROL GROUP:

-Similar looking disc (in size and shape) was cut out of card board/white board.

-As a part of our standard procedure, subjects were given a rough idea about the harmonizer and its use. (This was also reacquired so as to obtain a verbal and a written consent so that the data can be used for research and analysis purpose.)

- The subjects did not have any idea about the protocol or expected outcome.

- The study carried out was single blind and the doctor/researcher doing scans knew in which group the subject was (experimental/ control), but the subjects were not aware about the group in which they were.

For information on the scanning techniques used in this study, please see reference links below

Polycontrast Interference Photography

<http://www.biofieldsciences.com/biofieldsciences.com/PIP.htm>

Gas Discharge Visualisation

<http://www.biofieldsciences.com/biofieldsciences.com/GDV.htm>

Resonant Field Imaging

<http://www.biofieldsciences.com/biofieldsciences.com/RFI.htm>

TOTAL ENROLMENT:

| | |
|------------------------------|---------------------------|
| Total No. of subjects | 100 |
| Control | 10 |
| Experimental | 90 |
| Age | 21-70yrs |
| Sex | male or female |

Scans were carried out and analysed by leading experts in the specific imaging technology. Most of the results were qualitative and cross comparison was complex. However, overall there were significant positive changes in all 3 assessment techniques. (See Appendix for case specific examples).

RESULTS

Scans were obtained of 100 participants. Each case was individually examined & analyzed.

The results obtained support the effectiveness of the electroDOT over negative effects of mobile phone radiations.

- **PIP scans showed positive change in 87 participants out of 90.**
- **Two (2) of these 90 scans showed negative changes.**
- **One(1) of these 90 participants showed absolutely no change in the scans.**
- **The GDV and RFI scans show results in correlation with PIP.**

| Control | Positive Change | Negative Change | No Change |
|----------------|------------------------|------------------------|------------------|
| 10 | 87 | 2 | 1 |

CONCLUSIONS

- **It seems crystal clear that the electroDOT/ SolarWind Electromagnetic Harmoniser has a profound effect on individuals so as to reduce harmful effects of electromagnetic radiations (EMF).**
- **In addition to the analysis part of the data, during experiments changes witnessed in the biofield were unusually strongly positive when regular mobile (without electroDOT) was replaced by mobile with electroDOT.**
- **From this research we can conclude that the electroDOT is a very effective means of neutralizing negative effects of electromagnetic radiations from mobile phones.**
- **Maximum changes were seen in the heart, solar plexus and brow chakras along with significant positive change in the biofield.**
- **During the use of electroDOT, calming frequencies like blue were seen predominantly in the field. Prolonged use was seen to increase the vibrancy of chakras and reduce stress patterns seen on face as pooled red energy.**
- **Predominance of harmonious green and pink frequencies increase with prolonged use of the electroDOT on the mobile phone.**
- **Blocked charkas, especially the brow and solar plexus are seen to open up. Red congested energy is replaced by green or violet healing energy.**
- **Positive effects are also seen over lung fields in some of the cases.**

ADDENDA

20 SAMPLE CASE STUDIES

Case Study 1: Positive Change

PIP :



Subject holding mobile on standby without electrodot

The field is characterized by orange and green in somewhat equal proportion. This is s/o high mental activity. Red energy congestion can be seen in the liver and colonic area.

Mobile without electrodot During call

The patterns here are same. No appreciable change has been noticed.

Mobile on standby- electrodot introduced

Here we can see changes in the energy field. The yellow has been replaced by green. Blue, which is a soothing frequency, can be seen in the Aura. Liver area shows improvement.






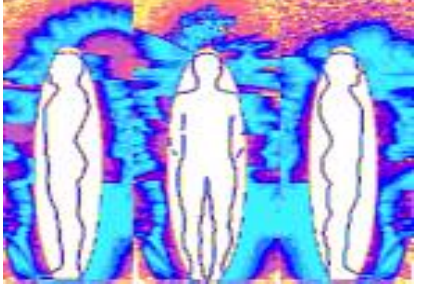


with electrodot on mobile. After 30 secs (during call)

The changes here are quite marked. An intense green of high density can be seen. This is a positive sign as green is a frequency of balance and on PIP can be interpreted as a health reference.

Mobile with electrodot during call. After 1 min

This green is accompanied by calming pink. Subsequently green becomes denser. Low energy congestion has marginally reduced.

Mobile with electrodot during call - After 5 mins

| | |
|--|---|
|  |  |
| <p>Before exposure to electrodot (16.03.2009)</p> | <p>After 2days using electrodot (19.03.2009)</p> |
| <p>Analysis: The 1st scan shows a lot of yellow. This is because of high mental activity. This is accompanied by low orange. Brow chakra is seen to be distorted. Red, low energy congestion can be seen in the abdominal area. The 2nd scan shows positive change. Yellow has been replaced by green. This can indicate reduced mental activity. The Brow chakra shows positive change. It shows good alignment and thereby good activity. Overall effects suggest that hyperactivity in the mind has reduced and it has become calm. Minimal changes on physical level can be seen.</p> | |
| <p style="text-align: center;">GDV</p> | <p style="text-align: center;">GDV</p> |
| <p>Before exposure to electrodot</p> | <p>After using electrodot for two days</p> |
|  |  |
| <p>Analysis: Leaks are seen at level of heart solar and splenic chakra. Absence of energy at level of left lower limb is seen. After use of electrodot aura appears to be much more organized and symmetrical.</p> | |
| <p style="text-align: center;">RFI</p> | <p style="text-align: center;">RFI</p> |
| <p>Before exposure to electrodot:</p> | <p>After using electrodot for two days</p> |
|  |  |
| <p>Analysis: positive shift from dull red to vibrant indigo is seen in crown. Replacement of low energy in brown colour with blue is seen in throat chakra which is a positive sign.</p> | |

Case study 12: Positive Change

PIP :



Subject holding mobile on standby without electrodot

The field is characterized by calming pink and green. It also has low orange energy. Stress pattern can be seen on the face. Low red energy congestion can be seen in the solar plexus, navel plexus and ascending colon.

Mobile without electrodot During call

Few changes are seen here. Solar plexus has become green. Rests of the patterns are similar.

Mobile on standby- electrodot introduced

Positive changes seen here on using the electrodot are remarkable. The whole pattern has radically changed. We can now see positive green and blue. The orange has reduced a lot. It is seen as a small band at the periphery.




with electrodot on mobile. After 30 secs (during call)

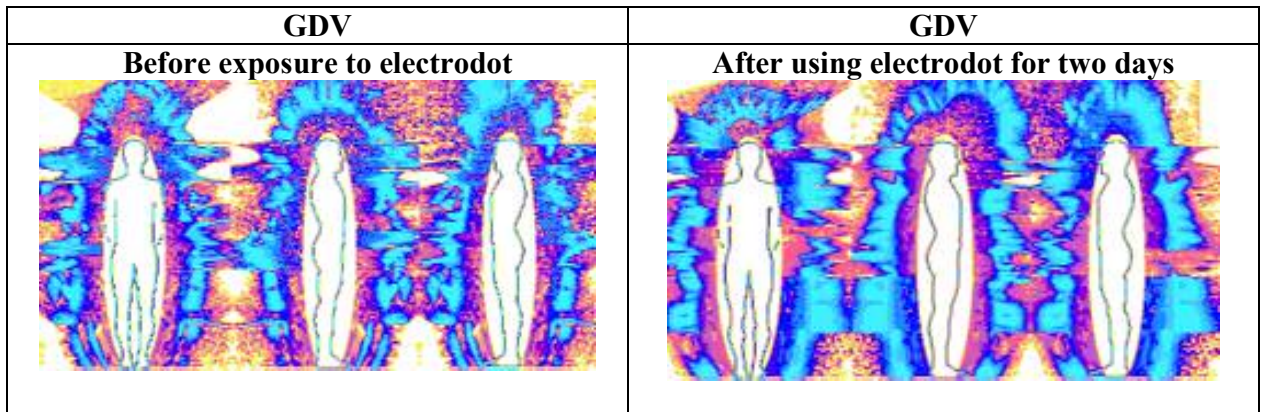
Mobile with electrodot during call. After 1 min

Mobile with electrodot during call. After 5 min


The above mentioned changes remain consistently throughout the call. Congested low energy in the navel and colonic area has reduced. Brow has opened up.



Analysis: As compared to the before scan we can see that positive green has conspicuously increased. The field has also become more vibrant. Few changes can be seen in the Brow and Throat.



Analysis: Distortion in crown has reduced significantly. There is a possibility of energies rearranging themselves.



Analysis: Brow and heart chakra have turned green in colour which is positive along with splenic chakra has reverted back to its original orange colour.

Case Study 19: Positive Change

PIP :



Subject holding mobile on standby without electrodot

Energy field is showing general positive energy. Solar plexus is showing red coloured low energy.

Mobile without electrodot During call

Congestion in the solar plexus has increased indicated by red colour.

Mobile on standby- electrodot introduced

Positive green and healing blue is increasing in the biofield. Solar plexus is receiving



with electrodot on mobile. After 30 secs (during call)



Healing blue is increasing in the biofield. Solar plexus is receiving more positive energy.

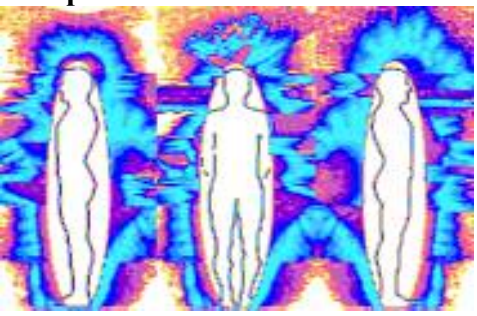
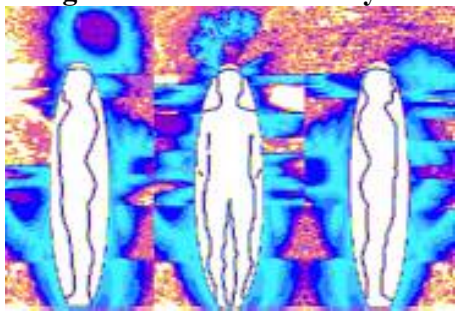
Mobile with electrodot during call. After 1 min



Solar plexus and Navel chakra are opening up by receiving.

Mobile with electrodot during call. After 5 min

Positive green is increasing In biofield and solar and Navel chakras.


| | |
|---|--|
|  |  |
| <p>Before exposure to electrodot</p> | <p>After using electrodot for 2days</p> |
| <p>Analysis: Solar plexus and Navel chakras are becoming more vibrant and opening with positive green.</p> | |

| | |
|---|---|
| <p>GDV</p> | <p>GDV</p> |
| <p>Before exposure to electrodot</p>  | <p>After using electrodot for two days</p>  |
| <p>Analysis: Energy leak from heart chakra and navel chakra has reduced. Not positive changes found in energy levels in legs. Aura has become much more vibrant.</p> | |

| | |
|--|---|
| <p>RFI</p> | <p>RFI</p> |
| <p>Before exposure to electrodot</p>  | <p>After using electrodot for two days</p>  |
| <p>Analysis: Over all shift from red low energy to violet is seen. Violet is a healing colour and is appositive sign.</p> | |

Case Study 35: Positive Change

PIP :



Subject holding mobile on standby without electrodot


Lungs field and solar plexus show red coloured congestion. Biofield shows overall positive energy.

Mobile without electrodot During call

Positive green colour in the bio filed has reduced.

Mobile on standby- electrodot introduced

Solar plexus and lungs field are getting more positive energy. Healing blue is increasing along with positive green in the biofield.



with electrodot on mobile. After 30 secs (during call)

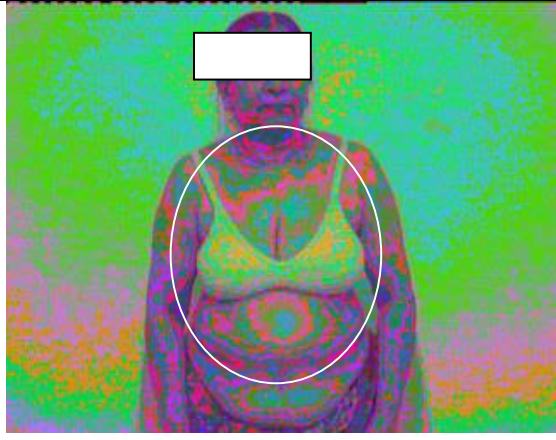

Solar plexus is opening up as it is getting more positive energy.


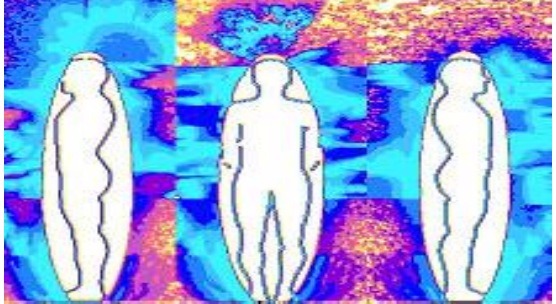
Mobile with electrodot during call. After 1 min



Healing energy goes on increasing along with positive green.

Mobile with electrodot during call. After 5 min

Congestion near heart chakra has started reducing.


| | |
|--|--|
|  |  |
| <p>Before exposure to electrodot</p> | <p>After using electrodot for 2days</p> |
| <p>Analysis: low coloured orange energy is getting replaced with vibrant green.</p> | |

| | |
|--|--|
| <p>GDV</p> | <p>GDV</p> |
| <p>Before exposure to electrodot</p> | <p>After using electrodot for two days</p> |
|  |  |
| <p>Analysis: Restoration of energy at level of crown. Aura appears to be much more symmetrical and vibrant.</p> | |

| | |
|--|---|
| <p>RFI</p> | <p>RFI</p> |
| <p>Before exposure to electrodot</p> | <p>After using electrodot for two days</p> |
|  |  |
| <p>Analysis: Restoration of positive blue energy at level of les is seen. Redistribution of energy is seen with minimal positive changes.</p> | |

Case Study 29: Positive Change

PIP :



Subject holding mobile on standby without electrodot

Subtle combinations of green and blue are seen in field. Congestion is seen over solar.

Mobile without electrodot During call

Decrease in calming blue as effect of electro magnetic radiations is seen.

Mobile on standby- electrodot introduced

Sudden increase in blue is seen which proves efficacy of electrodot.



with electrodot on mobile. After 30 secs (during call)




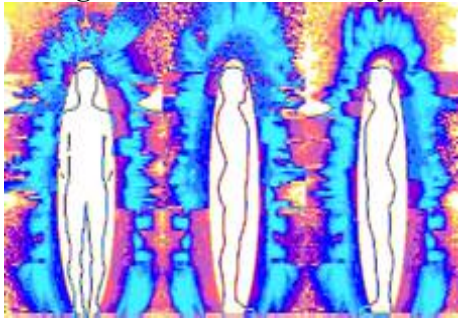


Solar has opened up with replacement of red with green energy.

Mobile with electrodot during call. After 1 min

Increase in density of green is seen with further increase in solar

Mobile with electrodot during call. After 5 min

Marked increase in blue calming frequency with vibrant solar is seen.

| | |
|--|---|
|  |  |
| <p>Before exposure to electrodot (14.03.2009)</p> | <p>After using electrodot for 2 days (17.03.2009)</p> |
| <p>Analysis: General energy in the aura shows positive changes as the pulling indicated by orange is replaced by positive green. Red coloured congestion seen in throat chakra is replaced by Indigo, which is a positive change. Congestion in Navel Chakra indicated by red is getting replaced by positive green. Minor low energy changes are seen in the solar plexus and Brow chakra may be due to mild stress during scan.</p> | |
| <p>GDV</p> | <p>GDV</p> |
| <p>Before exposure to electrodot</p> | <p>After using electrodot for two days</p> |
|  |  |
| <p>Analysis: Rearranging of energy is seen. Distortion of crown chakra has reduced.</p> | |
| <p>RFI</p> | <p>RFI</p> |
| <p>Before exposure to electrodot</p> | <p>After using electrodot for two days</p> |
|  |  |
| <p>Analysis: Brown low energy in crown and brow shows replacement with indigo and blue respectively. Low energy near legs has been replaced by healing blue.</p> | |

Case Study 22: Positive Change



PIP :



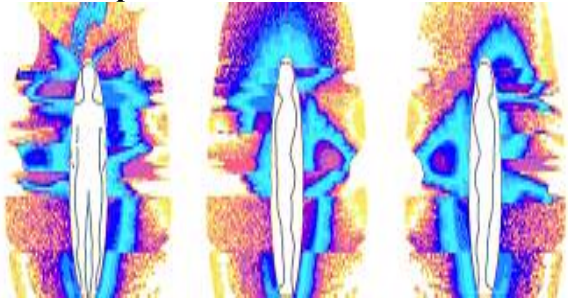
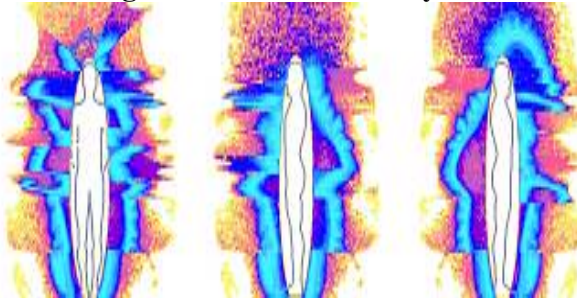
| | | |
|---|--|---|
| <p>Subject holding mobile on standby without electrodot</p> <p>Orange colour has started increasing in the biofield. Navel chakra and solar plexus are showing low energy.</p> | <p>Mobile without electrodot During call</p> <p>Orange coloured low energy increases. Congestion near solar plexus and Navel chakra has started increasing.</p> | <p>Mobile on standby-electrodot introduced</p> <p>Orange coloured low energy is getting replaced by healing blue and positive green.</p> |
|---|--|---|





| | | |
|---|---|--|
| <p>with electrodot on mobile. After 30 secs (during call)</p> <p>Congestion in the solar plexus is decreasing. Biofield is also getting positive energy.</p> | <p>Mobile with electrodot during call. After 1 min</p> <p>Lung fields are receiving more positive energy. Solar plexus is opening up by receiving positive energy.</p> | <p>Mobile with electrodot during call - After 5 mins</p> <p>Solar plexus is becoming vibrant.</p> |
|---|---|--|

| | |
|---|--|
|  |  |
| <p>Before exposure to electrodot (23.03.2009)</p> | <p>After using electrodot for 2 days (26.03.2009)</p> |

Analysis: Red coloured orange energy is replaced by positive green and healing blue. Solar plexus and Navel chakras are receiving more positive energy as red coloured congestion is replaced by positive green.

| | |
|--|--|
| GDV | GDV |
| <p>Before exposure to electrodot</p> | <p>After using electrodot for two days:</p> |
|  |  |
| <p>Analysis: Energy leak from lower part of the leg decreases. Rearranging of energy is seen. Distorted crown shows positive changes.</p> | |

| | |
|--|--|
| RFI | RFI |
| <p>Before exposure to electrodot</p> | <p>After using electrodot for two days:</p> |
|  |  |
| <p>Analysis: Low energy over crown and brow show positive shift to blue and violet which are healing colors. Throat and heart chakra also show positive change from grey to blue.</p> | |

Case Study 41: Positive Change

PIP :



Subject holding mobile on standby without electrodot

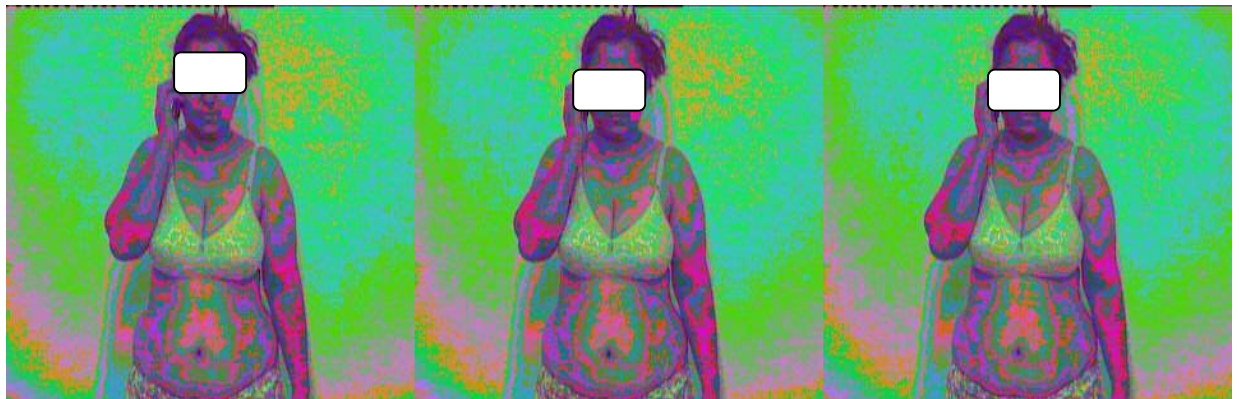Overall energy levels are good. Minimal congestion of energy is seen in solar. Low frequency in form of orange is seen in the biofield.

Mobile without electrodot during call

Increase in yellow in the aura is seen. This is definitely a negative sign, it might be due to electromagnetic radiations.

Mobile on standby- electrodot introduced

Appearance of blue and complete absence of yellow in the field shows the efficacy of dots in reduction of EM radiations. Reduction in congestion over solar is also seen.




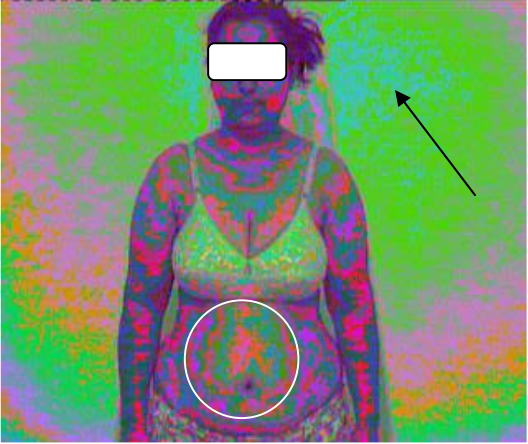
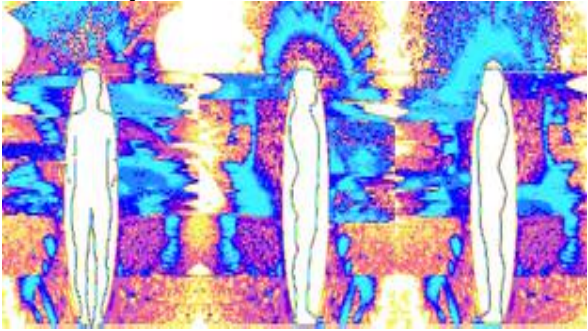



with electrodot on mobile. After 30 secs (during call)

Mobile with electrodot during call. After 1 min

Mobile with electrodot during call - After 5 mins

Field appears to be enlarged. Some positive changes appear to have reverted back. Low energy is seen in the field.

Density of blue and green has increased slowly.

| | |
|--|---|
|  |  |
| <p>Before exposure to electrodot (04.03.2009)</p> | <p>After using electrodot for 2days(07.03.2009)</p> |
| <p>Analysis: Low orange frequency along with congested solar have been replaced by positive green and blue positive frequencies. Solar is slowly showing positive changes.</p> | |
| <p style="text-align: center;">GDV</p> | <p style="text-align: center;">GDV</p> |
| <p>Before exposure to electrodot</p>  | <p>After using electrodot for two days</p>  |
| <p>Analysis: Completely distorted emission is seen from crown chakra which appears to be quite settled after use of electrodot. Leaks on several levels especially heart and solar are replenished with significant reappearance of energy at level of legs bilaterally.</p> | |
| <p style="text-align: center;">RFI</p> | <p style="text-align: center;">RFI</p> |
| <p>Before exposure to electrodot</p>  | <p>After using electrodot for two days:</p>  |
| <p>Analysis: Positive shift from red to green is seen in brow chakra. Green is health reference. Low energy at level of legs in form of red is replenished by healing blue which is good.</p> | |

Case Study 52: Positive Change

PIP :



Subject holding mobile on standby without electrodot

Marked pooling of energy over left colonic area is seen along with congestion over right lung field. The biofield appears to be good with combination of blue and green.

Mobile without electrodot During call

The bad effects of EM radiations can be clearly seen with appearance of low orange energy in the field. Congestion over left shoulder has increased.

Mobile on standby-electrodot introduced

Calming frequency in form of blue has appeared which is a positive sign.





with electrodot on mobile. After 30 secs (during call)

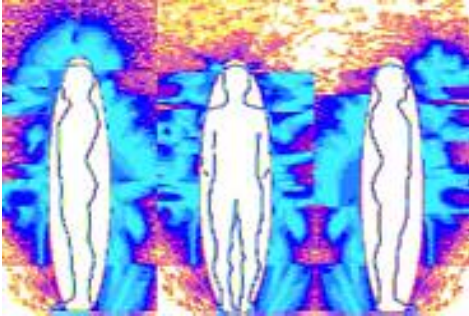

Persistence of blue is seen with redistribution of low energy in abdominal area.



Mobile with electrodot during call. After 1 min

No significant changes are seen

Mobile with electrodot during call. After 5 min

| | |
|---|--|
|  |  |
| <p>Before exposure to electrodot (17.03.2009)</p> | <p>After using electrodot for 2days(20.03.2009)</p> |
| <p>Analysis: The biofield appears to be good initially with combination of blue and green, which in later case the field gets expanded with significant increase in density and vibrancy of calming blue, this proves efficacy of electrodot over prolonged period of use.</p> | |

| | |
|--|---|
| <p style="text-align: center;">GDV</p> | <p style="text-align: center;">GDV</p> |
| <p>Before exposure to electrodot</p> | <p>After using electrodot for two days</p> |
|  |  |
| <p>Analysis: Absence of energy was seen in before scan, after use of electrodot restoration of energy at level of crown is seen. Reappearance of energy at level of legs is also noticed.</p> | |

| | |
|---|--|
| <p style="text-align: center;">RFI</p> | <p style="text-align: center;">RFI</p> |
| <p>Before exposure to electrodot</p> | <p>After using electrodot for two days</p> |
|  |  |
| <p>Analysis: Positive shift is seen in crown where low dull yellow is replaced by vibrant green. Similar changes are seen at level of throat and splenic chakra. Negative energy over hands and legs has been replaced by positive green and blue.</p> | |

Case Study 61: Positive Change

PIP :




| | | |
|---|---|---|
| <p>Subject holding mobile on standby without electrodot</p> <p>Congestion is seen in solar plexus chakra and lung fields. Aura appears to be balanced with calming blue.</p> | <p>Mobile without electrodot During call</p> <p>Increase in low, orange energy is seen in fields. No other significant changes are seen.</p> | <p>Mobile on standby- electrodot introduced</p> <p>Redistribution of energy is seen with increase in density of calming subtle blue.</p> |
|---|---|---|

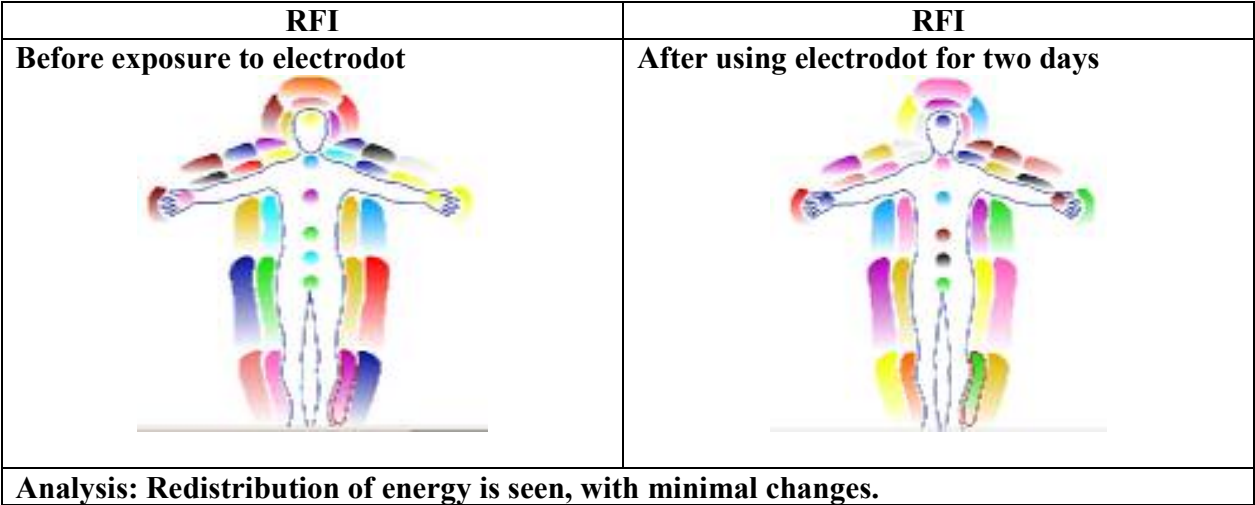



| | | |
|--|---|---|
| <p>with electrodot on mobile. After 30 secs (during call)</p> | <p>Mobile with electrodot during call. After 1 min</p> | <p>Mobile with electrodot during call. After 5 min</p> |
|--|---|---|

| | |
|---|---|
| <p>Stress pattern over face appears to be reduced along with increase in density of blue.</p> | <p>Pooling of solar plexus is reducing. Congestion in lung fields is also decreasing after prolonged use of mobile with electrodot.</p> |
|---|---|



Analysis: There is appearance of minimal yellow in aura. Yellow so close to head also indicates increased mental activity. Congestion in lung fields has significantly reduced.



Case Study 43: Positive Change

PIP :



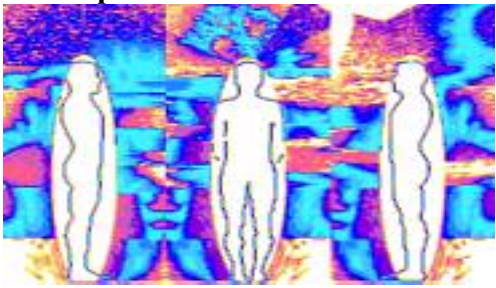
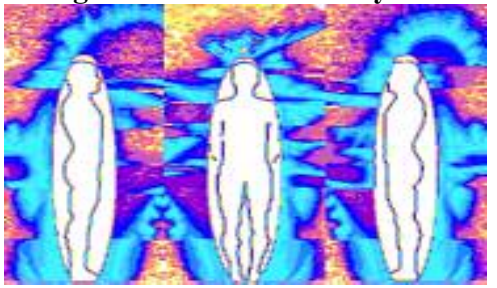




| | | |
|--|---|---|
| <p>Subject holding mobile on standby without electrodot</p> <p>Biofield consists of subtle combination of pink and green. Solar is partially blocked.</p> | <p>Mobile without electrodot During call</p> <p>Solar becomes completely blocked possibly due to bad effects of EM radiations.</p> | <p>Mobile on standby- electrodot introduced</p> <p>Reappearance of green can be seen in the field. Solar has again started opening up.</p> |
|--|---|---|



| | | |
|--|---|---|
| <p>with electrodot on mobile. After 30 secs (during call)</p> | <p>Mobile with electrodot during call. After 1 min</p> | <p>Mobile with electrodot during call. After 5 min</p> |
|--|---|---|

| | |
|--|--|
| <p>Subtle pink or lavender is progressively increasing which is a positive sign.</p> | <p>Sudden change in field is seen. Field has become very vibrant with green and calming frequencies of blue.</p> |
|--|--|

| | |
|---|---|
|  |  |
| <p>Before exposure to electrodot (11.03.2009)</p> | <p>After using electrodot for 2days(14.03.2009)</p> |
| <p>Analysis: healthy biofield with combinations of lavender and green is seen initially, but with prolonged use of electrodot dominance of vibrant green has increase along with appearance of calming blue frequencies.</p> | |
| <p>GDV</p> | <p>GDV</p> |
| <p>Before exposure to electrodot</p>  | <p>After using electrodot for two days</p>  |
| <p>Analysis: Energy leak from Navel Chakra has reduced. Energy leak from back has reduced. Biofield has become much more symmetrical.</p> | |
| <p>RFI</p> | <p>RFI</p> |
| <p>Before exposure to electrodot</p>  | <p>After using electrodot for two days</p>  |
| <p>Analysis: Crown shows shift from low yellow colour to indigo which is its original colour. Reduction in congestion of leg area and hear, solar chakra is see.</p> | |

Case Study 68: Positive Change

PIP :

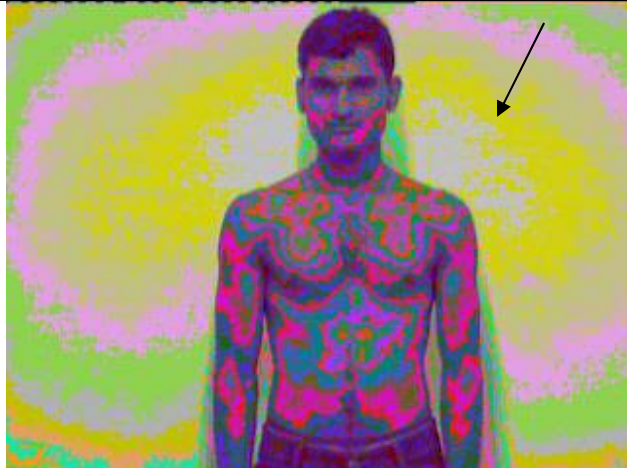


| | | |
|---|--|---|
| <p>Subject holding mobile on standby without electrodot</p> <p>The field is characterized by dense yellow. This is s/o of heightened electrical activity of the brain.</p> | <p>Mobile without electrodot during call</p> <p>The pattern is similar.</p> | <p>Mobile on standby- electrodot introduced</p> <p>A lot of white can be seen here. This is cosmic energy that appears in the field when he uses mobile with electrodot. These are compensating higher vibrations.</p> |
|---|--|---|

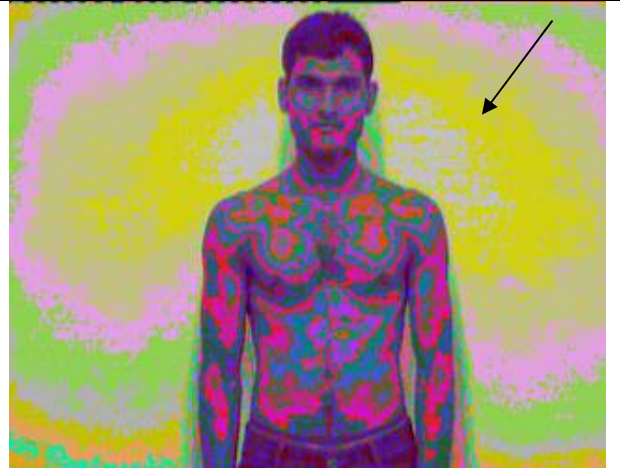

| | | |
|--|---|---|
| <p>with electrodot on mobile. After 30 secs (during call)</p> | <p>Mobile with electrodot during call. After 1 min</p> | <p>Mobile with electrodot during call - After 5 mins</p> |
|--|---|---|

This pattern is similar to earlier one. After this we can see that the pattern is going towards balance and instead of predominance of any one colour, we can see a combination of yellow, green and white.

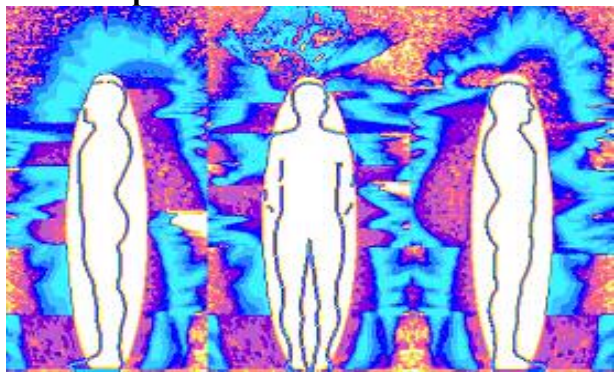
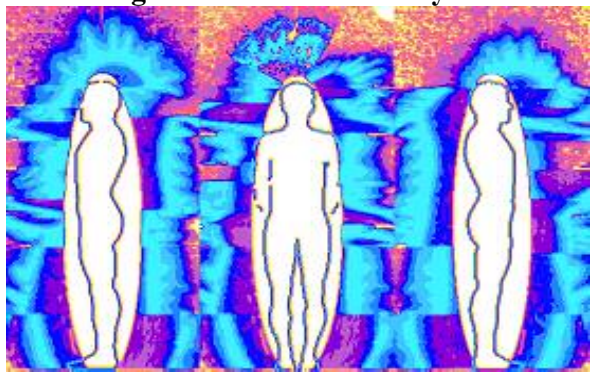




Before exposure to electrodot (21.03.2009)



After using electrodot for 2days (24.03.2009)

Analysis: The general patterns are somewhat similar. Brow shows positive change. Congestion in the abdominal area has reduced. Solar plexus shows more of violet. This is s/o healing going on.

| GDV | GDV |
|---|--|
| <p>Before exposure to electrodot</p>  | <p>After using electrodot for two days</p>  |
| <p>Analysis: No significant changes are observed except decrease in leaks for back.</p> | |

| RFI | RFI |
|--|---|
| <p>Before exposure to electrodot</p>  | <p>After using electrodot for two days</p>  |
| <p>Analysis: No significant positive change is seen except in heart chakra.</p> | |

Case Study 69: Negative Change

PIP :



| | | |
|---|---|---|
| <p>Subject holding mobile on standby without electrodot</p> <p>Biofield shows subtle combination of green and blue which is a calming frequency.</p> | <p>Mobile without electrodot During call</p> <p>Low orange energy in the biofield has increased which might be result of EM radiations</p> | <p>Mobile on standby- electrodot introduced</p> <p>Reduction in low energy with use of electrodot can be seen.</p> |
|---|---|---|



| | | |
|---|--|--|
| <p>with electrodot on mobile. After 30 secs (during call)</p> <p>Changes appear to have reverted back with appearance of low orange.</p> | <p>Mobile with electrodot during call. After 1 min</p> <p>Positive shift is seen.</p> | <p>Mobile with electrodot during call. After 5 min</p> <p>Unstable changes are seen with appearance of orange in field.</p> |
|---|--|--|

| | |
|--|--|
| | |
|--|--|


| | |
|---|--|
| | |
| <p>Before exposure to electrodot (23.03.2009)</p> | <p>After using electrodot for 2days (26.03.2009)</p> |
| <p>Analysis: Not very positive changes are seen. Low orange is seen in after scan. Congestion in solar appears to have increased.</p> | |

| | |
|--|---|
| <p>GDV Before exposure to electrodot</p> | <p>GDV After using electrodot for two days</p> |
| | |
| <p>Analysis: Distortion and energy leak at level of crown has increased. The field has become much more distorted, asymmetrical.</p> | |

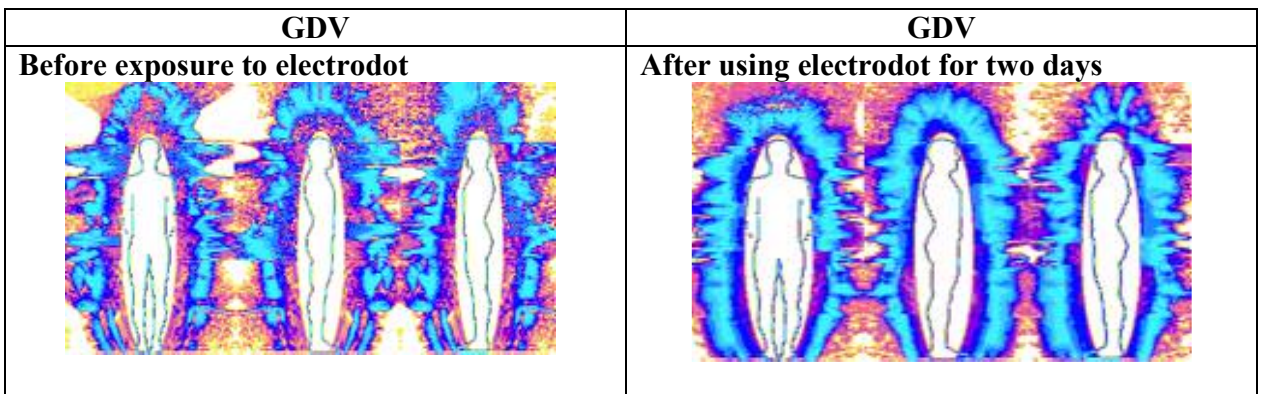
| | |
|---|---|
| <p>RFI Before exposure to electrodot</p> | <p>RFI After using electrodot for two days</p> |
| | |
| <p>Analysis: Not very positive change is seen, except in throat chakra where shift from yellow to blue is seen.</p> | |

Case Study 71: Positive Change


| PIP : | | |
|--|---|--|
|  |  |  |
| <p>Subject holding mobile on standby without electrodot</p> <p>General biofield shows calming blue which is a good sign but slight low energy orange band can be seen</p> | <p>Mobile without electrodot during call</p> <p>General biofield shows calming blue, which is good but there is increased in the low energy orange band.</p> | <p>Mobile on standby-electrodot introduced</p> <p>Low energy orange band has reduced after the use of electrodot. No significant changes are seen on the chakra level.</p> |
|  |  |  |
| <p>with electrodot on mobile. After 30 secs (during call)</p> <p>Low energy orange band has reduced. General biofield shows positive calming blue.</p> | <p>Mobile with electrodot during call. After 1 min</p> <p>General biofield becomes more vibrant after the use of the electrodot.</p> | <p>Mobile with electrodot during call - After 5 mins</p> <p>General biofield shows more vibrancy after the use of the electrodot. Solar plexus shows more positive green.</p> |



Analysis: General biofield becomes more vibrant after the use of electrodot. Solar plexus shows more positive green which is a good sign. Appearance of blue is a positive sign.



Analysis: Distortion at level of crown has reduced. Leaks have reduced. Over all distortion has reduced and aura appears to be much more symmetrical.



Analysis: Energy at level of crown and legs show positive shift from low red and orange to blue and violet which are healing colors. The vibrancy of heart and solar chakra has increased.

Case Study 74: Positive Change

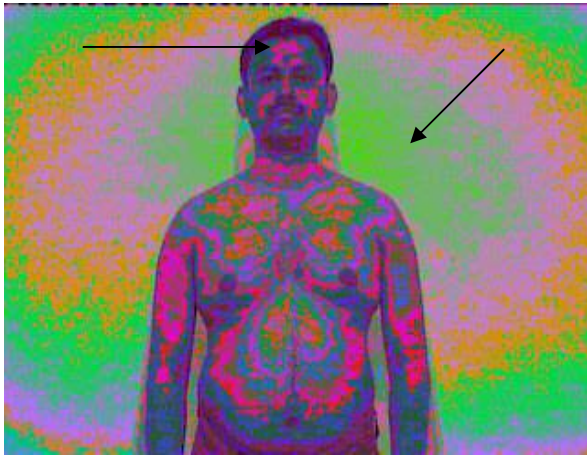PIP:



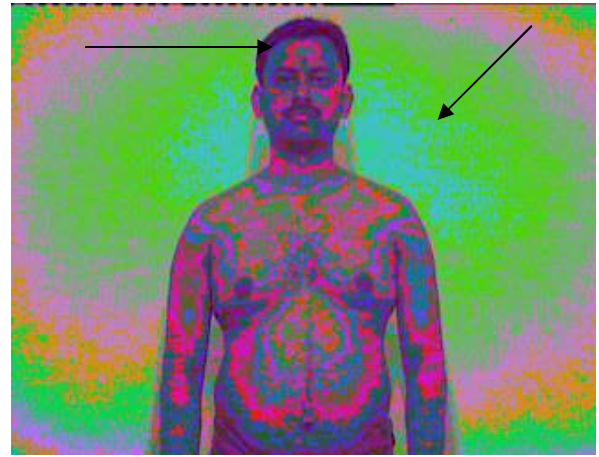
| | | |
|---|---|--|
| <p>Subject holding mobile on standby without electrodot</p> <p>General biofield shows positive green & calming blue color. Brow chakra shows congestion. Congestion in the middle lobe of left lung can be seen. Solar plexus is mildly congested.</p> | <p>Mobile without electrodot during call</p> <p>General biofield shows reduction in the positive green color during call. Congestion in the solar plexus & middle lobe of left lung has reduced.</p> | <p>Mobile on standby-electrodot introduced</p> <p>General biofield shows increase in the positive green color. Solar plexus & lung field shows positive changes. Brow shows congestion.</p> |
|---|---|--|



| | | |
|---|--|--|
| <p>with electrodot on mobile. After 30 secs (during call)</p> <p>No significant changes can be seen.</p> | <p>Mobile with electrodot during call. After 1 min</p> <p>Vibrancy of the biofield has increased after the use of dot's as calming blue appears in the field.</p> | <p>Mobile with electrodot during call. After 5 min</p> <p>General biofield has increased as calming blue increases after the use of electrodot.</p> |
|---|--|--|

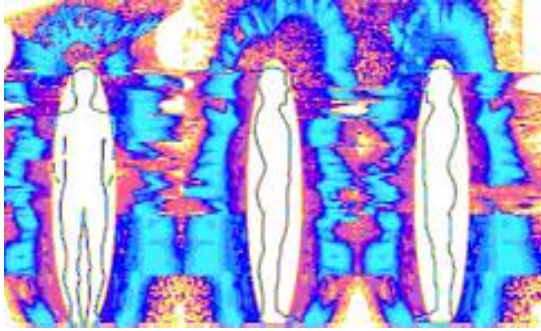
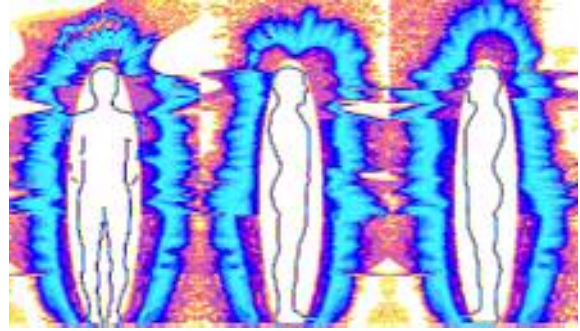


Before exposure to electrodot (02.03.2009)





After using electrodot for 2days(05.03.2009)

Analysis: General Biofield becomes more vibrant as calming blue increases after the use of electrodot. Brow chakra shows positive changes.

| GDV | GDV |
|---|--|
| <p>Before exposure to electrodot</p>  | <p>After using electrodot for two days</p>  |

Analysis: Minimal distorted emissions seen at crown level initially which have become aligned. Break in energy field is seen at level of legs, solar and spleen which appears to be restored after prolonged use of electrodots.

| RFI | RFI |
|--|---|
| <p>Before exposure to electrodot</p>  | <p>After using electrodot for two days</p>  |

Analysis: Chakras show a positive shift to lavender colour. Legs which has low energy in form of brown has been replaced by vibrant blue. Here showing negative shift from blue to grey.

Case Study 88: Positive Change

PIP :



Subject holding mobile on standby without electrodot

The green field is good. It also has calming blue. There are a few areas of energy imbalance seen particularly in sinus, throat, liver, heart & left shoulder.

Mobile without electrodot during call.

Similar changes are seen in biofield. Congestion in solar plexus has slightly increased. Congestion in heart has slightly reduced.

Mobile on standby-electrodot introduced

Appearance of calming blue shows positivity in the energy field. Congested low energy in left shoulder has reduced.



with electrodot on mobile. After 30 secs (during call)


Similar changes can be seen.

Mobile with electrodot during call. After 1 min

Here some positive changes can be seen in the bio-field as blue which is calming colour appears in the bio-field. Positive changes can be seen in left shoulder.

Mobile with electrodot during call. After 5 min

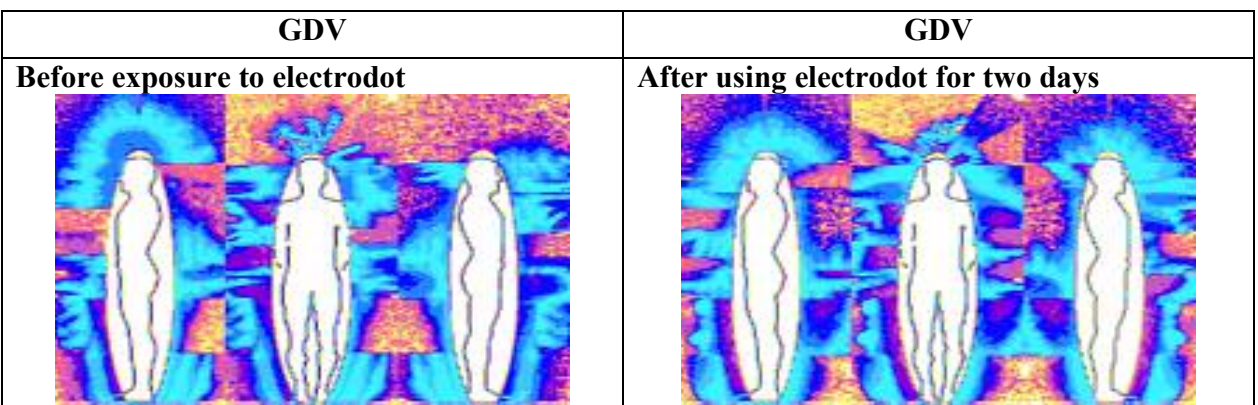
Congestion in the solar plexus has reduced.




Before exposure to electrodot

After using electrodot for 2days

Analysis: Bio-fields show positive changes as vibrant green & calming blue healing energies have increased. The Solar chakra has opened up as congestive red colour is replaced by positive green. Mixed changes are seen in some area. Thus after applying electrodot good positive changes are seen in the bio-fields.



Analysis: Energy leak from solar plexus has reduced. Possibility of energy rearranging maybe because of prolonged use of electrodot. Distortion of crown has reduced.



Analysis: Replacement of low energy at level of crown by blue is a positive sign.

Case Study 93: Positive Change

PIP :



Subject holding mobile on standby without electrodot

Subject appears to be in good health both at physical and energy level. Mild congestion in right lung is seen. Field is characterized by subtle green and white .

Mobile without electrodot During call

Reduction in green in the field on the side of use of mobile.

Mobile on standby- electrodot introduced

Reappearance of green is seen on using electrodot which is a positive sign.





with electrodot on mobile. After 30 secs (during call)

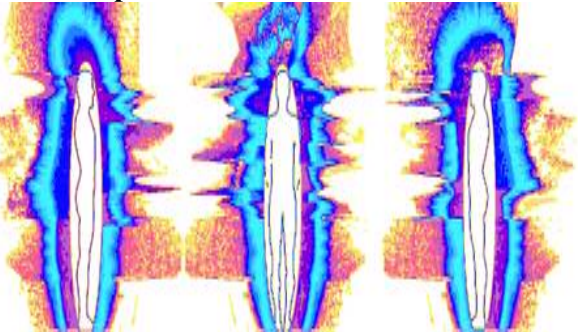
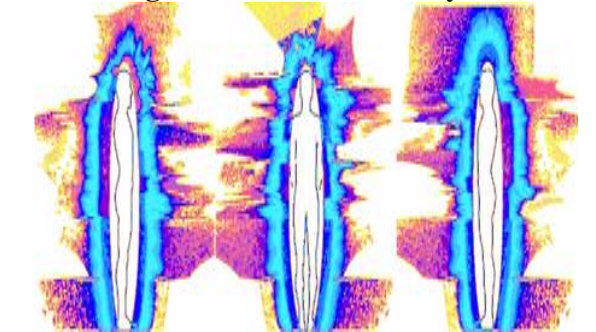
No significant change is seen.



Mobile with electrodot during call. After 1 min

Definite increase in green which is a positive sign is seen.

Mobile with electrodot during call. After 5 min

| | |
|---|--|
|  |  |
| Before exposure to electrodot (10.03.2009) | After using electrodot for 2days(13.03.2009) |
| Analysis: Shift in colours in the field from low or negative yellow and orange to subtle combination of white and green is a positive sign. | |

| | |
|---|---|
| GDV Before exposure to electrodot | GDV After using electrodot for two days |
|  |  |
| Analysis: Energy near heart chakra has reduced. There is a possibility of energy rearranging. The field is much more continues and symmetrical. | |

| | |
|---|--|
| RFI Before exposure to electrodot | RFI After using electrodot for two days |
|  |  |

Analysis: Low energy in throat, brow, heart and solar has been replaced by vibrant blue which is a positive sign. Appearance of violet and blue indicate a healing frequency.

Case Study 97: Other

PIP :



Subject holding mobile on standby without electrodot

Stress is seen over the face. The bio field consists mostly of green which is a positive sign.

Mobile without electrodot During call

Low energy banding, orange has increased in the field. Congestion in chest also has increased.

Mobile on standby- electrodot introduced

Green has appeared with use of electrodot. Brow also has started opening up.



with electrodot on mobile. After 30 secs (during call)

Mobile with electrodot during call. After 1 min

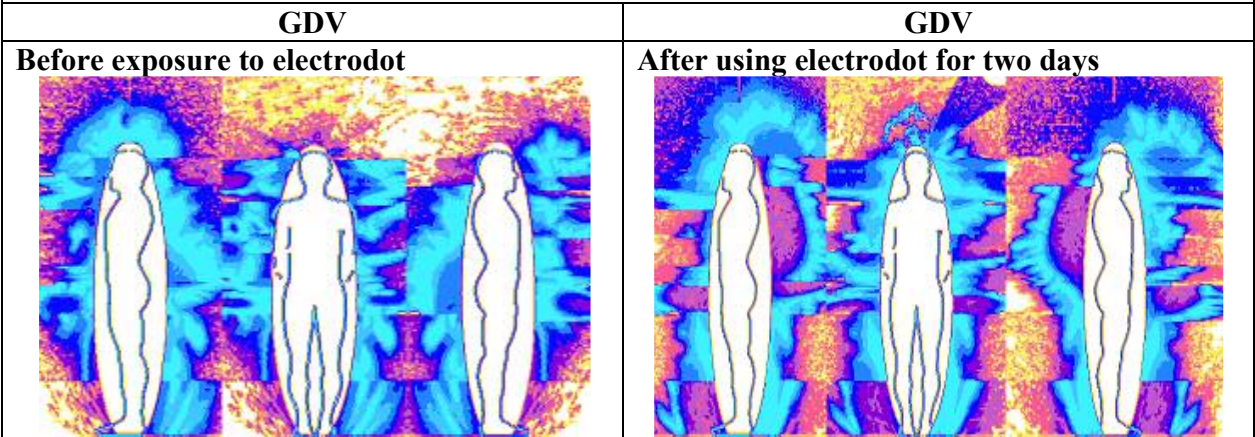
Mobile with electrodot during call. After 5 min

No significant changes are seen

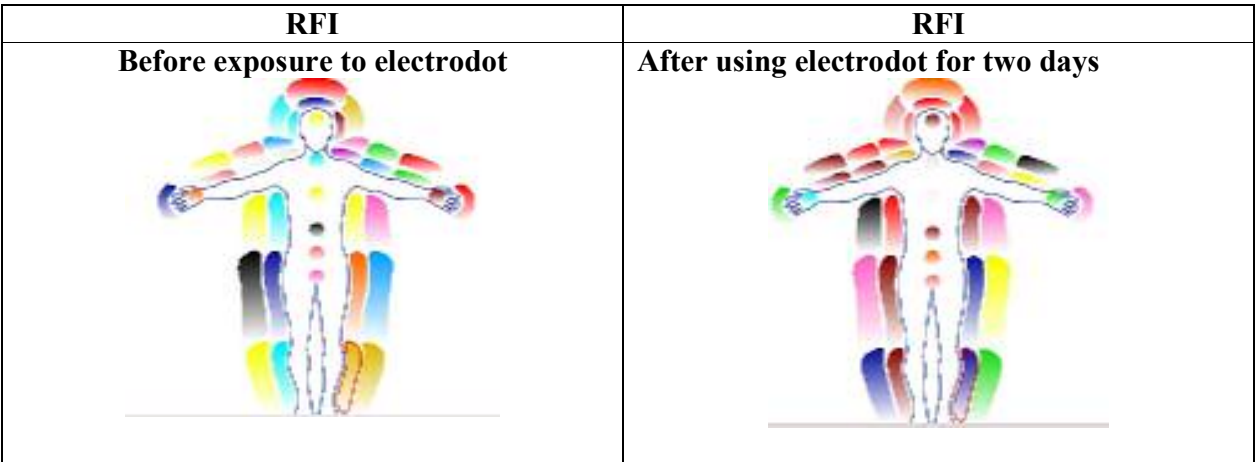
Changes seem to have reverted back. Brow shows similar congestion as scan 1. The bio field also consists of low energy.



| | |
|---|---|
| Before exposure to electrodot (4.03.2009) | After using electrodot for 2days (7.03.2009) |
| Analysis: Not much conspicuous change in before and after pictures seen. | |



Analysis: Almost absence of energy is seen in before scan. The energy seems to be reappearing at level of crown in after scan. No other significant changes are seen.



Analysis: No significant changes are seen.

Control Group (With electrodot blank)

Case Study 77

PIP :



Subject holding mobile on standby without electrodot

General biofield is good. It shows golden yellow & calming pink which are positive colours. Congestion in the solar plexus, left shoulder, throat, upper jaw can be seen.

Mobile without electrodot during call

Similar changes can be seen in the biofield.

Mobile on standby- electrodot introduced

Similar changes can be seen in the biofield. Low energy in the solar has slightly reduced.



with electrodot on mobile. After 30 secs (during call)



Energy field becomes more vibrant Similar changes can be seen in the solar plexus & left shoulder.

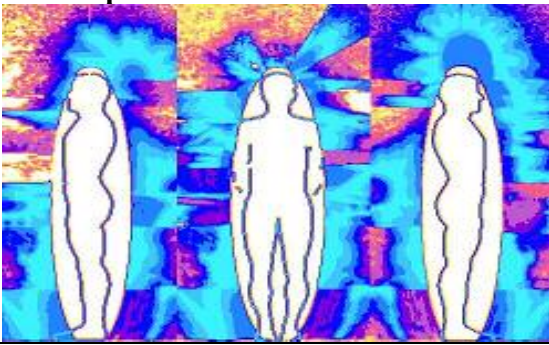
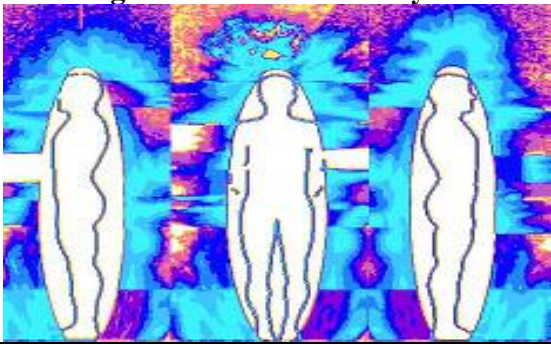
Mobile with electrodot during call. After 1 min



Minimal changes can be seen in the biofield.

Mobile with electrodot during call - After 5 mins

Minimal changes can be seen.

| | |
|---|--|
|  |  |
| <p align="center">Before exposure to electrodot</p> | <p align="center">After using electrodot for 2days</p> |
| <p>Analysis: General biofield shows dominance of pink. Minimal changes in congestion in the upper lobe of right lung is seen. Congestion in the solar plexus has slightly increased.</p> | |

| | |
|--|--|
| <p align="center">GDV</p> | <p align="center">GDV</p> |
| <p align="center">Before exposure to electrodot</p>  | <p align="center">After using electrodot for two days</p>  |
| <p>Analysis: Minimal changes are seen at level of crown where reappearance of energy can be seen. Leaks do not show significant change.</p> | |

| | |
|---|---|
| <p align="center">RFI</p> | <p align="center">RFI</p> |
| <p align="center">Before exposure to electrodot</p>  | <p align="center">After using electrodot for two days</p>  |
| <p>Analysis: Minimal changes are seen at level of crown where shift is seen from red to brown, rest of the scan just shows redistribution of energy.</p> | |

Control Group (With electrodot blank)
Case Study 80

PIP :





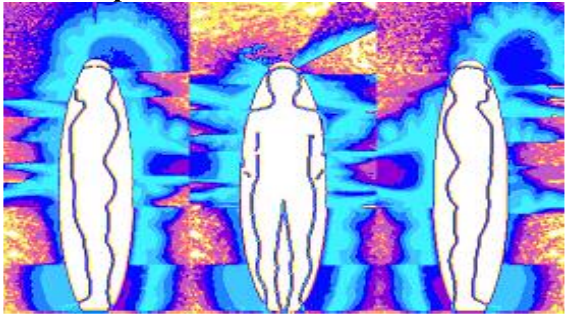
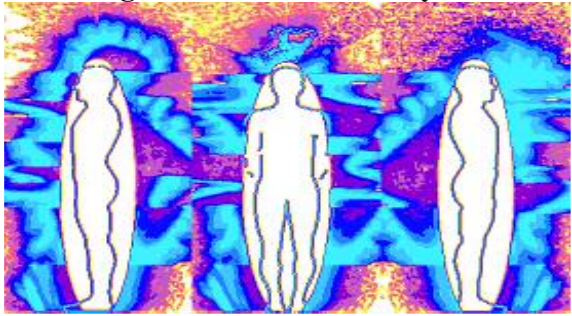
| | | |
|---|--|--|
| <p>Subject holding mobile on standby without electrodot</p> <p>General biofield shows imbalance. Congestion in the throat, liver region & navel chakra can be seen</p> | <p>Mobile without electrodot During call</p> <p>No significant changes are seen</p> | <p>Mobile on standby- electrodot introduced</p> <p>No significant changes are seen.</p> |
|---|--|--|





| | | |
|--|---|---|
| <p>with electrodot on mobile. After 30 secs (during call)</p> <p>No significant changes are seen.</p> | <p>Mobile with electrodot during call. After 1 min</p> <p>No significant changes are seen.</p> | <p>Mobile with electrodot during call. After 5 min</p> <p>No significant changes are seen.</p> |
|--|---|---|

| | |
|--|--|
| | |
|--|--|

| | |
|---|--|
|  |  |
| <p>Before exposure to electrodot (16.03.2009)</p> | <p>After using electrodot for 2days (19.03.2009)</p> |
| <p>Analysis: Congestion in the throat and left sinus has reduced after the use of electrodot. Minimal reduction in yellow is seen in the biofield.</p> | |

| | |
|---|--|
| <p style="text-align: center;">GDV</p> <p>Before exposure to electrodot</p>  | <p style="text-align: center;">GDV</p> <p>After using electrodot for two days</p>  |
| <p>Analysis: Distortion over crown has decreased minimally. Redistribution of energy can be seen with minimal changes.</p> | |

| | |
|--|---|
| <p style="text-align: center;">RFI</p> <p>Before exposure to electrodot</p>  | <p style="text-align: center;">RFI</p> <p>After using electrodot for two days</p>  |
| <p>Analysis: Minimal changes are seen in the biofield, however chakras show positive shift from low energies to healing blue.</p> | |

Control Group (With electrodot blank)
Case Study 82



PIP :

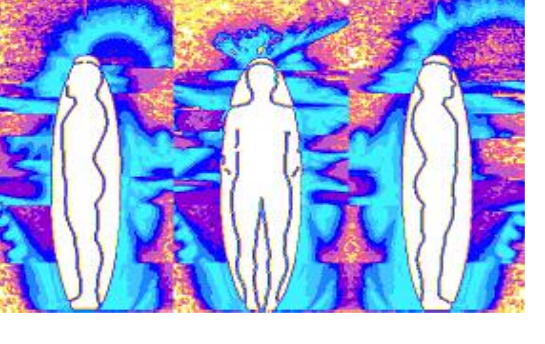
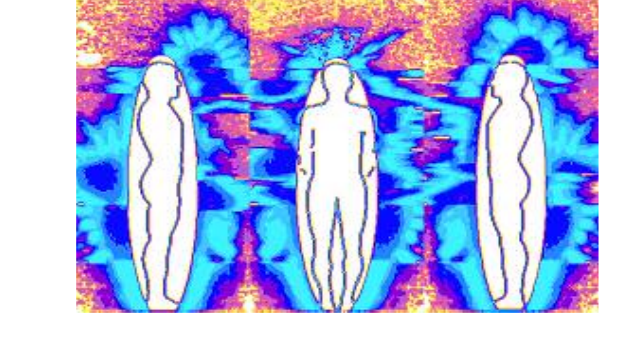




| | | |
|--|---|--|
| <p>Subject holding mobile on standby without electrodot</p> <p>Biofield shows calming pink and yellow along with typical stress pattern.</p> | <p>Mobile without electrodot During call</p> <p>Minimal increase in vibrancy of yellow is seen.</p> | <p>Mobile on standby- electrodot introduced</p> <p>No significant change seen.</p> |
|--|---|--|



| | | |
|--|---|---|
| <p>with electrodot on mobile. After 30 secs (during call)</p> <p>No significant change during call</p> | <p>Mobile with electrodot during call. After 1 min</p> <p>No significant change during call</p> | <p>Mobile with electrodot during call. After 5 min</p> <p>Minimal changes are seen even during increased call duration.</p> |
|--|---|---|

| | |
|--|--|
|  |  |
| <p align="center">Before exposure to electrodot</p> | <p align="center">After using electrodot for 2 days</p> |
| <p>Analysis: The before and after scans do not show much change. Redistribution of energy is seen in lung fields.</p> | |

| | |
|---|---|
| <p align="center">GDV</p> <p>Before exposure to electrodot</p> | <p align="center">GDV</p> <p>After using electrodot for two days</p> |
|  |  |
| <p>Analysis: redistribution of energy is seen along with reappearance of energy at level of legs. No other significant changes are seen.</p> | |

| | |
|--|--|
| <p align="center">RFI</p> <p>Before exposure to electrodot</p> | <p align="center">RFI</p> <p>After using electrodot for two days</p> |
|  |  |
| <p>Analysis: Rearrangement of energy in form of red to orange and yellow is seen at level of legs. Heart and splenic show negative shift from blue to grey.</p> | |

Centre for Biofield Sciences

The World Peace Centre

MIT College

Paud Road

Kothrud

Pune – 411 038

India

+91 (0) 20 2545 8748

cbspune@biofieldsciences.com

www.biofieldsciences.com

PhiHarmonics Ltd

4 Lotus Cottages

Stoke Gabriel

Totnes

TQ9 6SL

Devon

United Kingdom

+44 (0) 1803 782826

info@electrodots.co.uk

www.electrodots.co.uk