

## CASE STUDY

# Brody

Labrador Retriever

9 Years Old

Neutered Male

## Cancer Risk Level

Low

## Cancer Risk Value

RISK VALUE  
-0.044

Low

Moderate

High

-0.3

.04

.1

.3

## Use Case

Seemingly healthy senior dog (9 yrs old)  
Aid-in-Diagnosis

## Clinical Assessment

Large mass was noted on spleen

## Reason for Testing with Oncotect

The vet wanted to confirm or deny the suspicion of cancer before opting for more expensive, invasive diagnostic tests

## Oncotect Test Results

The Risk Value came at -.044, which is considered low risk.  
Oncotect's screening denied the suspicion of cancer.

## Next Steps

Splenuctomy was recommended and performed, and mass was benign.



## CASE STUDY

# Cassie

Schnoodle 9 Years Old Spayed Female

### Cancer Risk Level

Low

### Cancer Risk Value

RISK VALUE  
-0.043



### Use Case

Seemingly healthy senior dog (9 yrs old)  
Aid-in-Diagnosis

### Clinical Assessment

Large mass was noted on liver  
via an ultrasound

### Reason for Testing with Oncotect

The vet wanted to confirm or deny the suspicion of  
cancer before opting for more expensive, invasive  
diagnostic tests

## Oncotect Test Results

The Risk Value came at -.043, which is considered low risk.  
The vet thought it was less likely to be metastatic.  
Oncotect's screening denied the suspicion of cancer.

## Next Steps

Biopsy was recommended and performed, and mass was benign.





## CASE STUDY

# Lucy

Terrier Mix

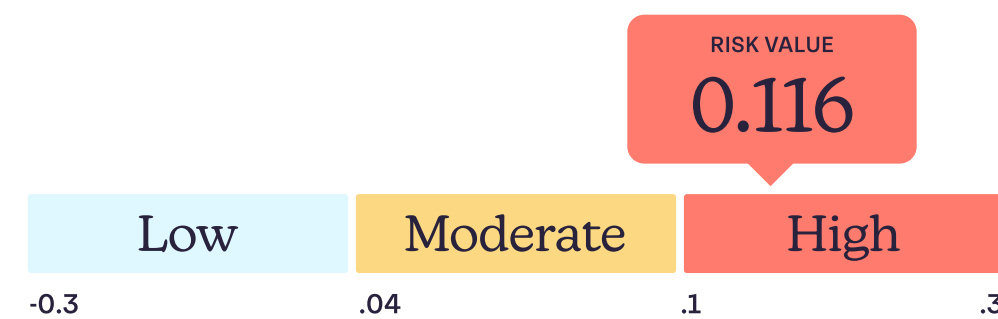
12 Years Old

Spayed Female

### Cancer Risk Level

High

### Cancer Risk Value



### Use Case

Seemingly healthy senior dog (12 yrs old) came in for an annual wellness check

### Clinical Assessment

Lucy had a bump on her side that was aspirated as a MCT

### Reason for Testing with Oncotect


The vet wanted to confirm or deny the suspicion of MCT before opting for more expensive, invasive diagnostic tests

## Oncotect Test Results

The Risk Value came at .116, which is considered high risk. Oncotect's screening confirmed the vet's suspicion of MCT.

## Next Steps

The vet recommended an abdominal ultrasound to check cancer elsewhere. The owner has decided not to follow up due to the patient's age.



## CASE STUDY

# Wylie

Labrador Retriever

12 Years Old

Spayed Female

### Cancer Risk Level

Low

### Cancer Risk Value

RISK VALUE  
0.002

Low

Moderate

High

-0.3

.04

.1

.3

### Use Case

Monitoring tool

### Clinical Assessment

MCT was successfully removed.

### Reason for Testing with Oncotect

The vet wanted to confirm if cancer spread to other areas.

## Oncotect Test Results

The Risk Value came at .002, which is considered low risk.

The vet was assured that MCT was successfully removed and didn't spread.

## Next Steps

Continue to monitor closely.

The patient has been healthy since the screening.