

# Treating a Quadriplegic's Non-Healing Wound with Fentonite®-Based Products

## PATIENT'S BACKGROUND

EG is currently an 80-year-old male with multiple health issues that affect his ability to heal by primary intention.

In addition to being a quadriplegic, he suffers from PAD, anxiety, cerebral vascular disease, type-2 diabetes, gastrointestinal reflux, hyperlipidemia, hypertension, and cerebral vascular disease. The patient also suffered an ischemic stroke.

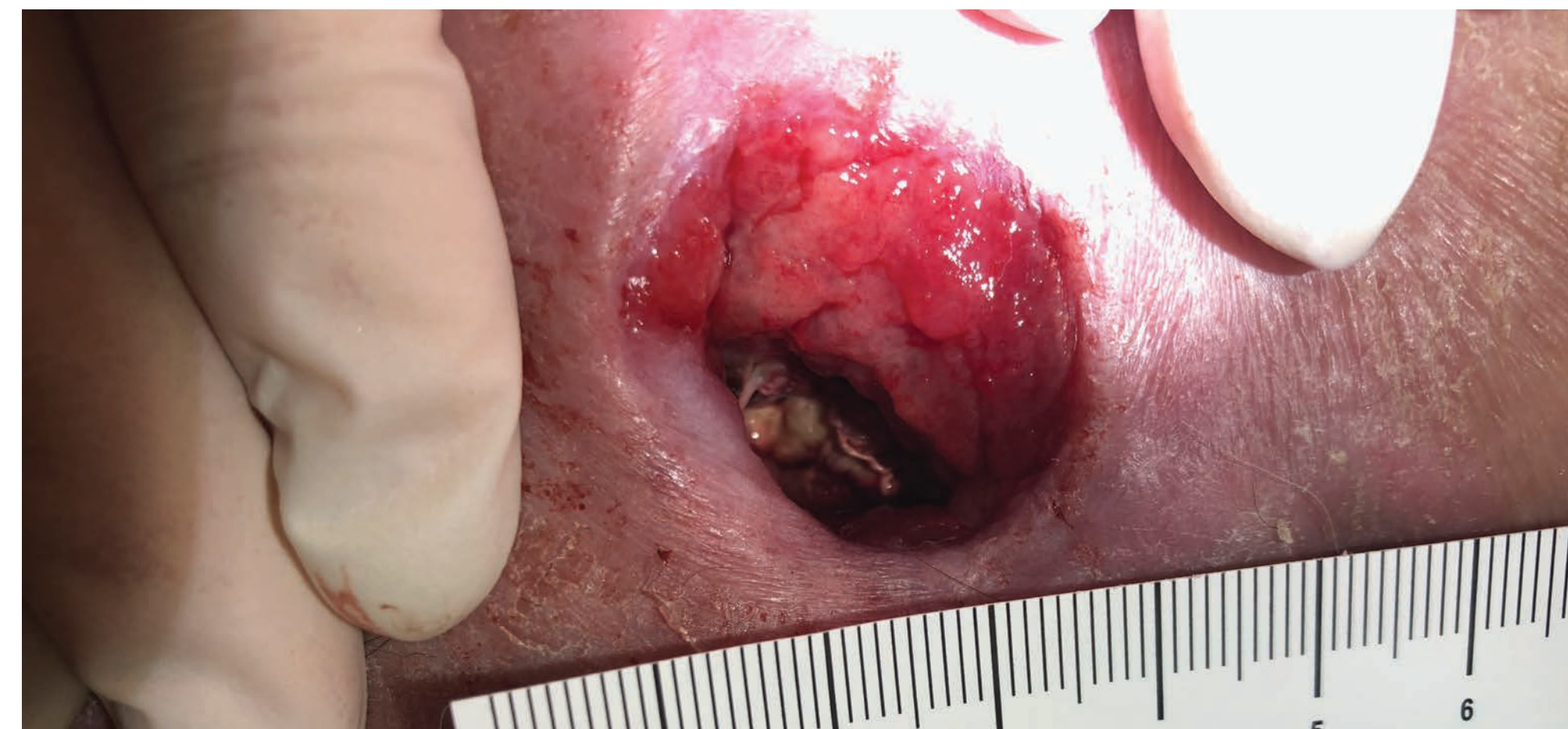
## TREATMENT HISTORY FOR SACRAL WOUND

In early May of 2022 the wound vac treatments were discontinued and the patient's care plan was changed to cleansing with BioRelease® Wound Cleanser and treating with AgFresh Wound Hydrogel with Fentonite and silver.

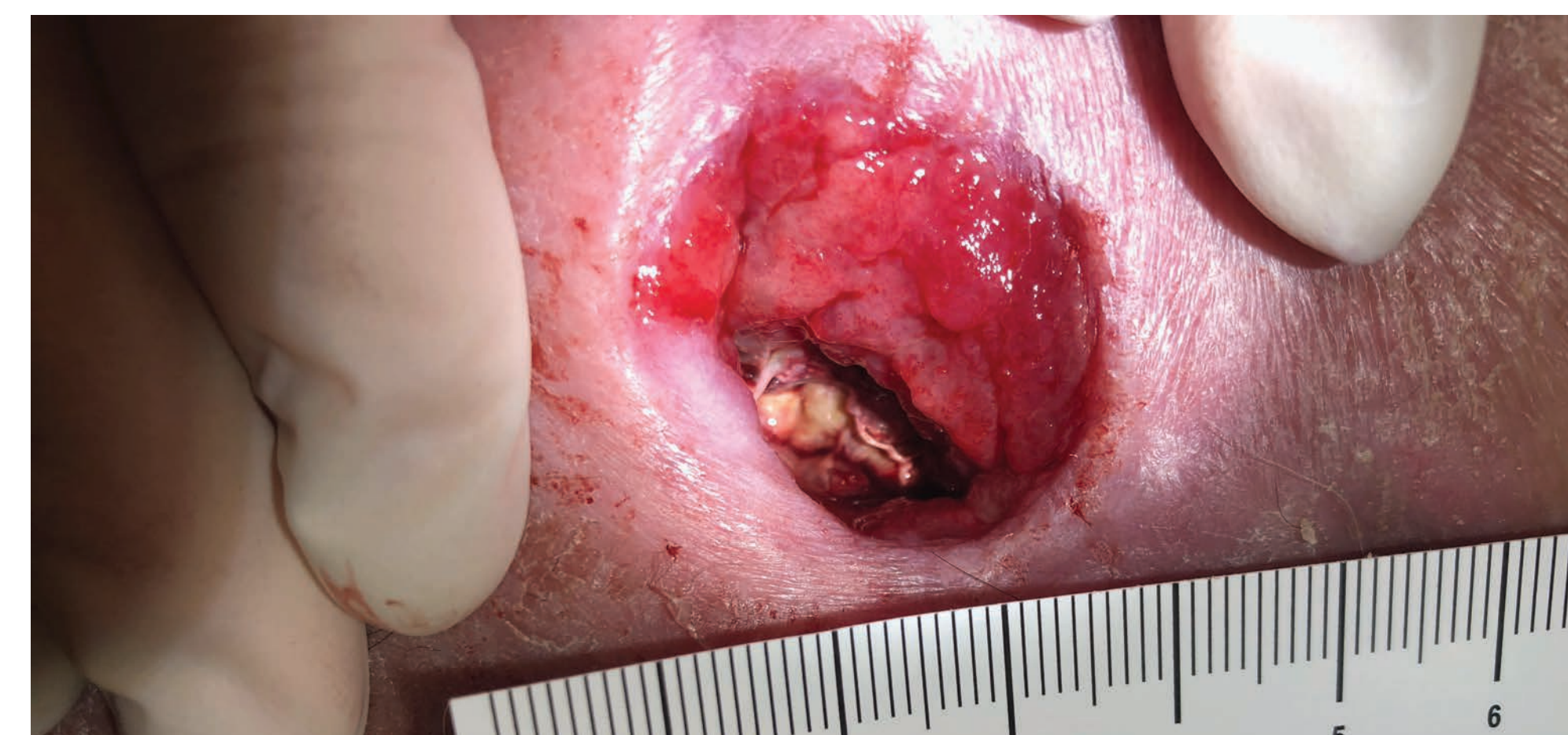Between May 15th and September 17th the patient was seen 3 times a week for observation and dressing changes. By June the patient's wound had started to heal again. Between July and early September the wound showed excellent progress and the depth and width of the wound was substantially resolved. The final patient visit to the wound clinic was late September at which time the patient's wound was completely healed and the patient was released from our care.

## TREATMENT AND PROGRESS OF WOUND

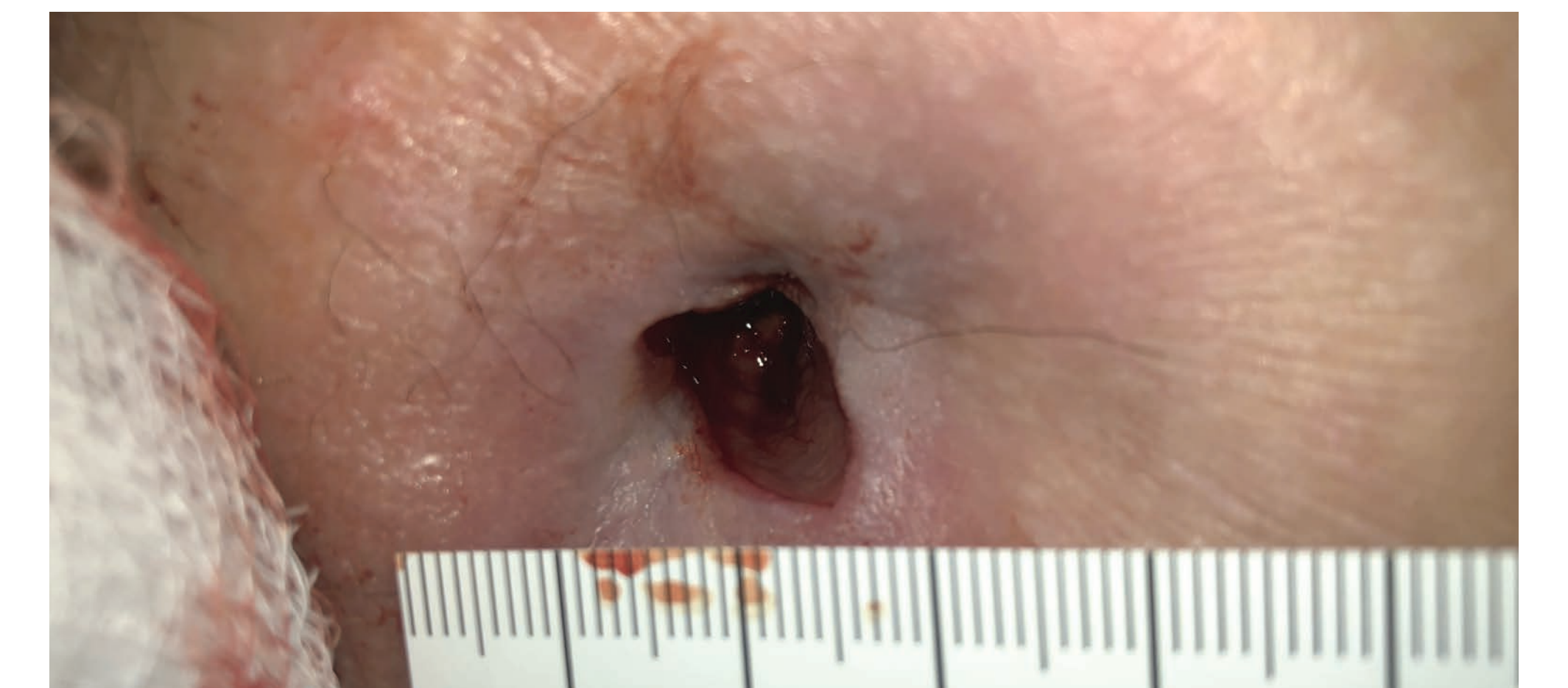12/16/21 – PRE-TREATMENT



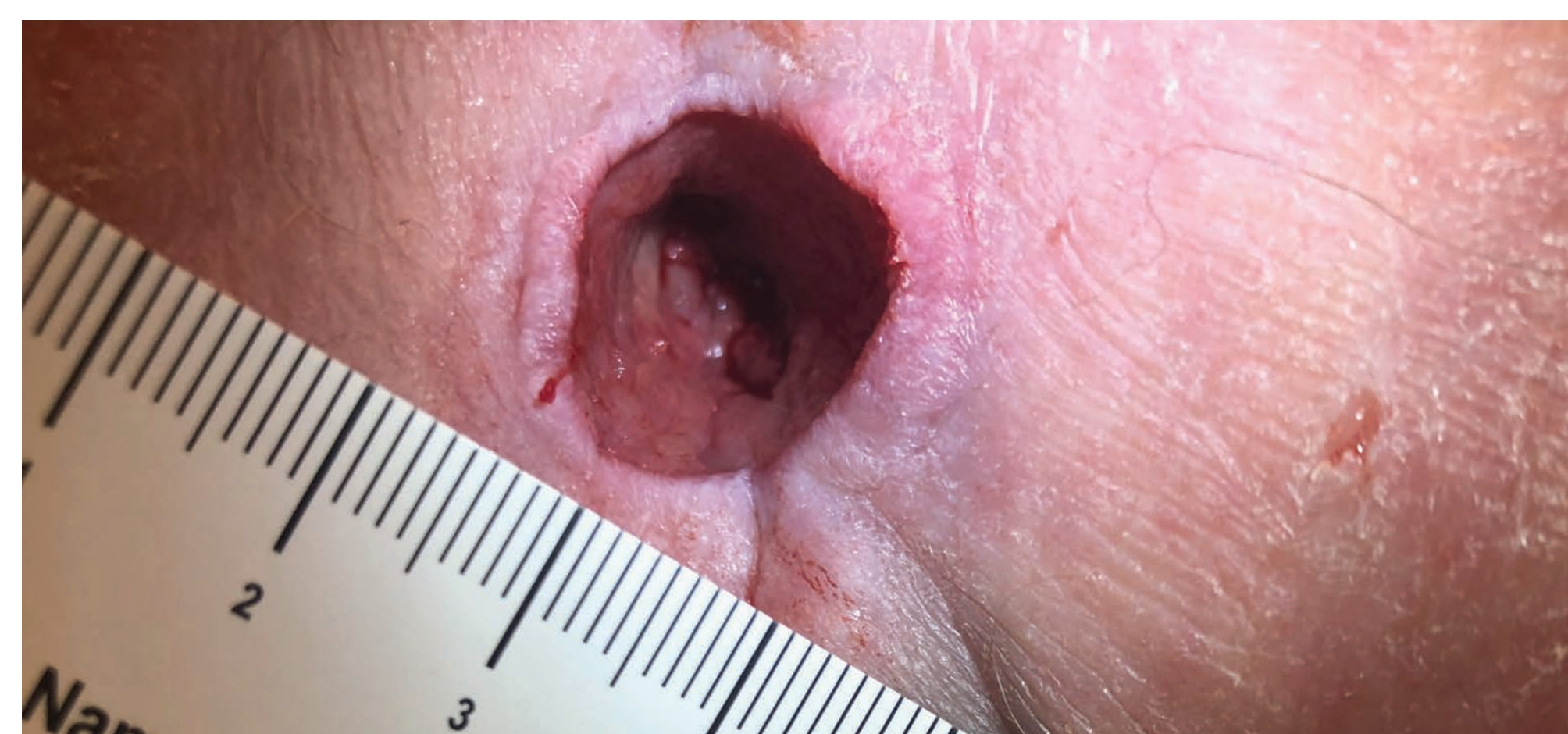12/16/21 – PRE-TREATMENT



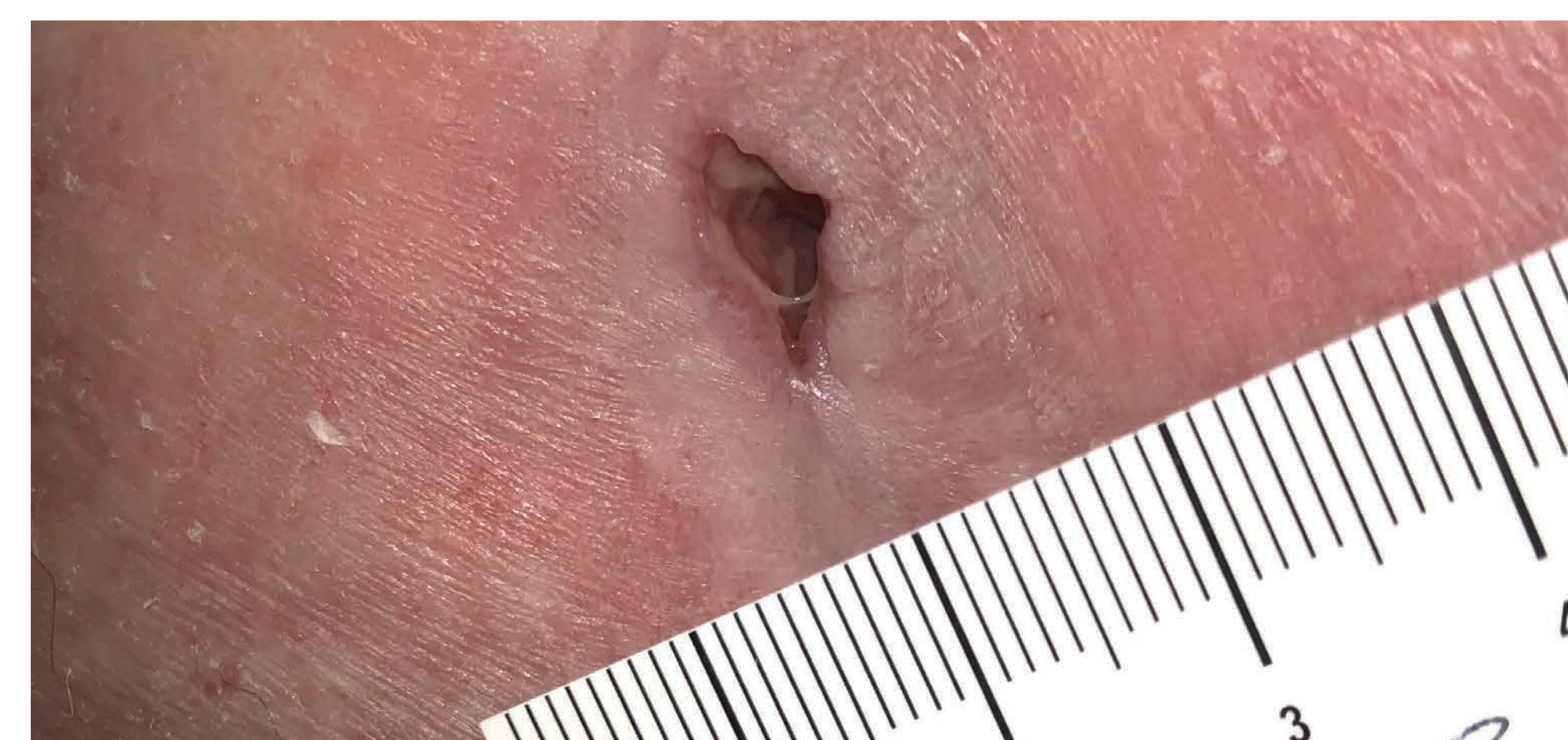2/1/22 – PRE-TREATMENT



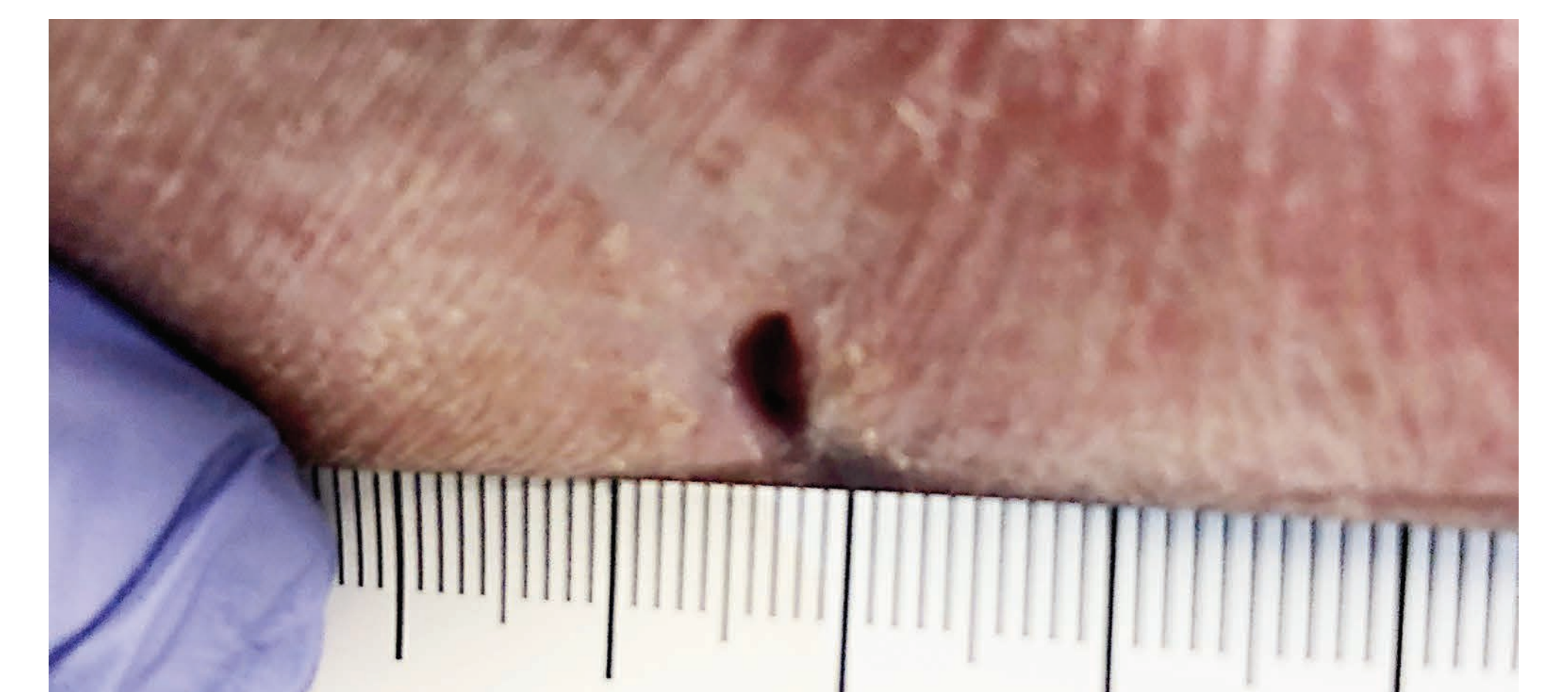
5/15/22 – McCORD TREATMENT



7/26/22 – McCORD TREATMENT



9/17/22 – McCORD TREATMENT



## IMPORTANT PATIENT HISTORY NOTE

When the wound gauze packing failed to achieve the desired results the patient was scheduled for a rotational flap procedure to cover the ischial ulcer. The patient preferred not to have surgery and elected for a second opinion

at my facility knowing that I had options not available elsewhere. The surgery, with everything considered would cost the system close to \$100,000 and would require the patient to endure extensive 3 to 6 month recovery. The

patients care was transferred to our facility and we initiated a care plan using the wound VAC. When the healing stagnated, it was decided to try the products with Fentonite® as a better course of action.

## PATIENT'S ECONOMIC STUDY

EG has paraplegia with a stage 4 sacral ulcer that has been treated since 2017 with no significant improvement. The patient was treated with standard care and wound VAC before starting Fentonite and BioRelease.

### Previous costs and treatments lasted six years:

1. Office Visits: \$57,600
2. Home Healthcare: \$150,000
3. Debridement Costs: \$60,200
4. Wound VAC: \$9,000
5. Product Cost: \$14,400

**Approximate total: \$291,200**

### New Treatment Protocol:

The patient was changed to: **BioRelease & Fentonite (AgFresh)**  
The wounds were cleaned, and dressings were changed 3x a week.

### Costs After Six Months of Treatment

1. Office Visits: \$2,480
2. Debridement: \$4,560
3. Product Cost: \$1,000

**Approximate total: \$7,040**

**The original treatment was 3.5 times more expensive per month than the McCord System, and the McCord System healed 12 times faster!**



**INVESTIGATORS**  
**Michael Lavor, MD**  
Medical Director of Saguro Wound Care Clinic  
**Jessica Barcelo, CCMA**  
Medical Assistant