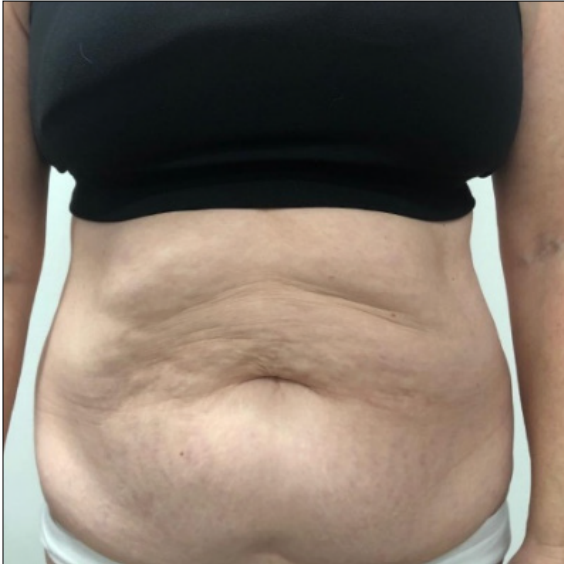


# Tummy Tuck

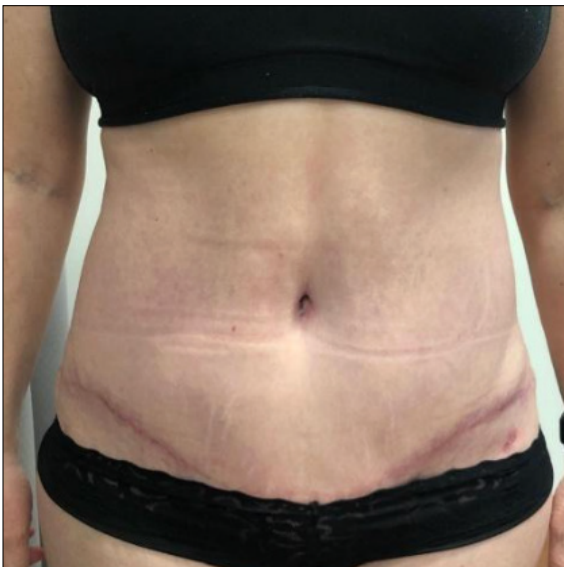
## Case Study 1

A 56-year-old patient presented themselves for abdominoplasty post four pregnancies in 3 years, and weight loss. Dr. Dool and the patient decided on a traditional abdominoplasty with liposuction of the bilateral flanks, bilateral axilla and lateral thorax.

Before



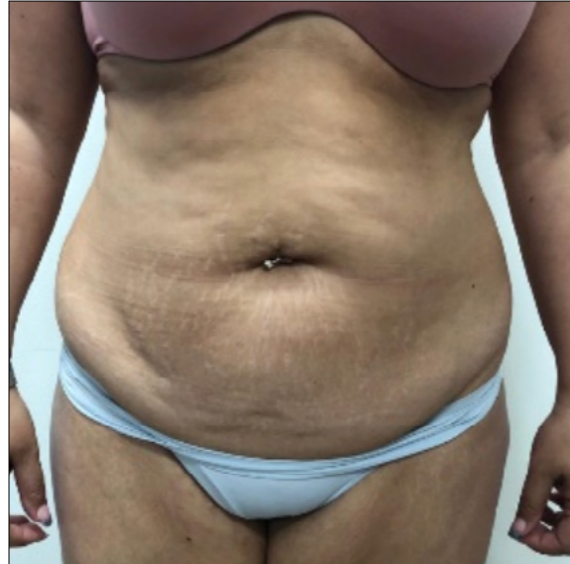After



## Case Study 2

A 34-year-old presented themselves for consideration of abdominoplasty with liposuction of medial thighs. Dr. Dool and the patient decided on a lipoabdominoplasty with liposuction to the medial thighs.

Before



After

