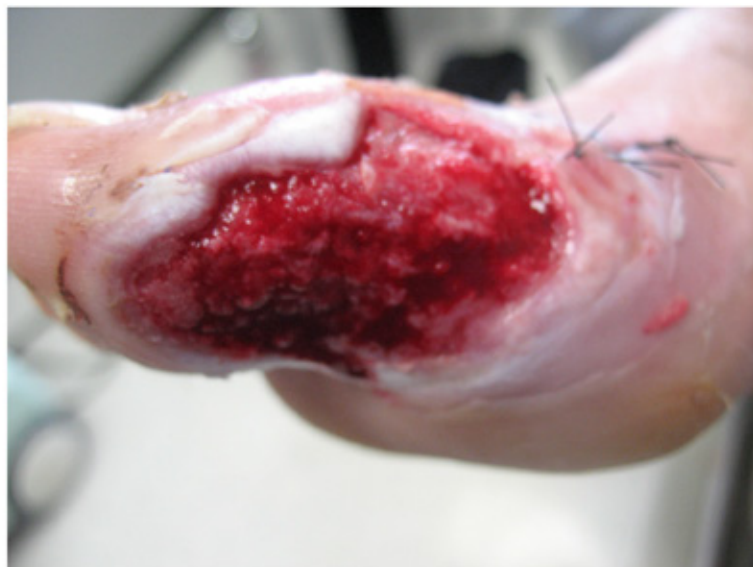

REPORTS ON ABL PRODUCTS

Lullove Diabetic Toe Ulcer Study



THE NEXT GENERATION IN WOUND DRESSINGS



Day 1
4.2 x 3.4 x 0.2 cm

Patient Summary

33-year-old patient was seen in the hospital for an infected right great toe ulceration. Patient has had previous history of diabetic foot infections and this was his 3rd occurrence on this foot. Patient had extreme pain to his right foot on clinical presentation. 2.0 diameter ulcer to medial aspect of right great toe. 4 cm tunnel from proximal plantar 1st MPJ to distal plantar right great toe. No probing to bone identified.

PMH: IDDM (x 26 years); depression; asthma; left great toe amputation (2012)

Allergies: Erythromycin and iodine

Clinical Course

Operative treatment included debridement and incision/drainage of abscess. Application of SilvrSTAT® changed every 3 days.

EL-6



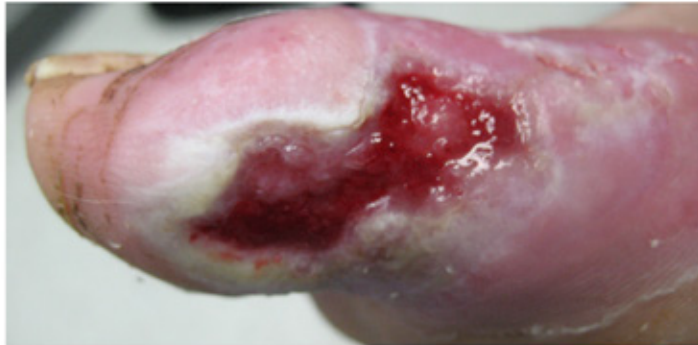www.SilvrSTAT.com
Toll Free Ph: 877-272-6924

REPORTS ON ABL PRODUCTS

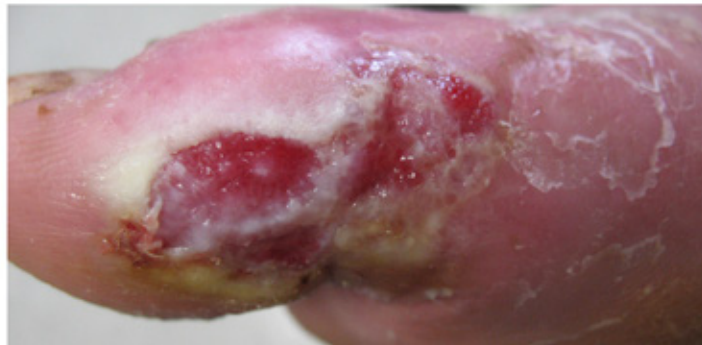
Lullove Diabetic Toe Ulcer Study *(continued)*



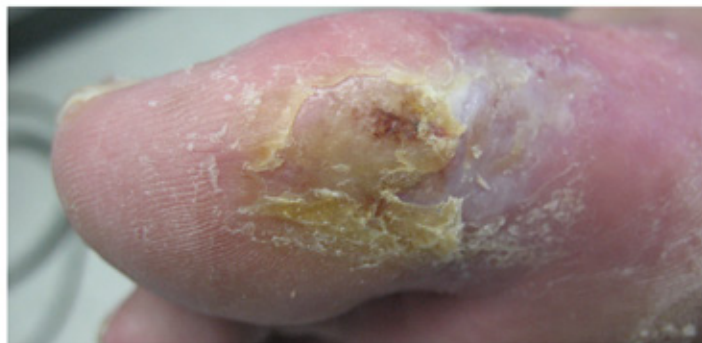THE NEXT GENERATION IN WOUND DRESSINGS



Day 8
3.5 x 2.5 x 0.15 cm



Day 18
1.5 x 2.0 x 0.15 cm



Day 25

EL-6



www.SilvrSTAT.com

Toll Free Ph: 877-272-6924