

A Pilot Study to Determine Penile Oxygen Saturation Before and After Vacuum Therapy in Patients with Erectile Dysfunction After Radical Prostatectomy

R. Charles Welliver Jr, MD,* Clay Mechlin, MD,† Brianne Goodwin, MS, MPH,‡ Joseph P. Alukal, MD,§ and Andrew R. McCullough, MD¶

*Division of Urology, Southern Illinois University School of Medicine, Springfield, IL, USA; †Urology Associates of Central Missouri, Columbia, MO, USA; ‡Albany Law School, Albany, NY, USA; §Department of Urology, New York University School of Medicine, New York, NY, USA; ¶Division of Urology, Albany Medical College, Albany, NY, USA

DOI: 10.1111/jsm.12445

ABSTRACT

Introduction. Provoked and spontaneous nocturnal erections are thought to play a role in maintenance of male sexual health through oxygenation of the corpus cavernosa. Conversely, hypoxia is thought to be an etiological factor in the pathogenesis of cavernosal fibrosis and long-term erectile dysfunction. It has been hypothesized that the early penile hypoxia after radical prostatectomy (RP) may lead to fibrosis and consequently a decrease in stretched penile length and long-term erectile dysfunction.

Aim. The aim of this study was to assess the changes in penile tissue oxygenation with vacuum erection device (VED) use.

Methods. Twenty men between 2 and 24 months following RP were enrolled prospectively. Each man cycled a VED to achieve full erection 10 consecutive times over a period of approximately 2 minutes without constriction ring.

Main Outcome Measures. Tissue oximetry was measured at baseline and immediately after VED using a tissue oximeter at five sites: right thigh, right corpora, glans, left corpora, and left thigh. Additional measurements were captured over the course of an hour.

Results. Mean age and time from surgery was 58.2 years and 12.6 months, respectively, and the average Sexual Health Inventory for Men score was 7. Use of the VED significantly increased both glanular and corporal oximetry relative to the baseline values for the entire 60 minutes. An initial increase of 55% was seen in corporal oxygenation with VED use.

Conclusions. This is the first study demonstrating that a single, brief application of the VED without a constriction ring results in significant improvement in penile oxygen saturation. The use of a VED has significant benefits for patients both with regard to cost and invasiveness when compared with other penile rehabilitation protocols. **Welliver RC Jr, Mechlin C, Goodwin B, Alukal JP, and McCullough AR. A pilot study to determine penile oxygen saturation before and after vacuum therapy in patients with erectile dysfunction after radical prostatectomy. J Sex Med 2014;11:1071–1077.**

Key Words. Erectile Dysfunction; Oximetry; Vacuum Erection Device; Penile Rehabilitation; Prostate Cancer; Radical Prostatectomy

Introduction

Radical prostatectomy (RP) is a common treatment for localized prostate cancer. Despite nerve sparing prostatectomy and the magnification

allowed by robotically assisted laparoscopic approach, true preservation of erectile function is rare. Most men will experience some degree of erectile dysfunction (ED) after RP. The etiology of the long-term ED is thought to be a combination

of nerve and vascular injury with secondary cavernosal apoptotic myopathy. Even after nerve sparing prostatectomy, there is an immediate loss of nocturnal penile tumescence (NPT) and generally a refractory period where erectile function is lost [1].

In previous animal and human studies of cavernous nerve injury, early corporal fibrosis has been demonstrated after RP [2–4]. With this nerve injury and the disruption of both provoked erections and normal NPT, there is a prolonged hypoxic state leading to fibrosis [5]. Penile hypoxia and fibrosis in Vignozzi's [6] bilateral cavernous nerve ablation rat model was noted with sildenafil administration improving this hypoxic state. In summation, these studies point toward a correlation with cavernous nerve injury, hypoxia, and increasing damage to the corporal tissue while in this hypoxic state.

Early postoperative therapy with intracavernosal injection (ICI) of prostaglandin E-1 was the first pharmacologic intervention to have demonstrated a beneficial effect on the return of erectile function [7]. After this seminal work was published, there was an increased interest to preserve erectile function using pharmacologic treatments. The theory behind these treatments was that ICI allowed an increase in oxygenation in the corporal tissue with a subsequent decrease in fibrosis. Based on these findings, numerous penile rehabilitation strategies have been described including the use of phosphodiesterase type 5 inhibitors (PDE5is), ICI, intraurethral alprostadil (TUA), steroids, and the vacuum erection device (VED) [8–10]. Currently, there is no consensus as to the preeminent rehabilitative regimen although the VED was the second most commonly used in a recent survey of American Urological Association members [11].

The VED is the only non-pharmacologic strategy among these choices and has recently undergone resurgence as a treatment for ED [12]. In 2006, the Food and Drug Administration (FDA) granted extended labeling for the VED indicating that the product could be used to create and maintain erections by providing arterial blood to the penis during recovery from prostatectomy and thus aid in maintaining preoperative sexual function. This was the first device or drug to be cleared by the FDA for this specific indication. Despite its approval by the FDA for penile rehabilitation after RP, there have never been any studies demonstrating improved penile oxygenation with the VED. An earlier study concluded

that VED use (with constriction band) may actually lead to a relatively hypoxic state [13]. Nonetheless, contemporary studies using VED in early penile rehabilitation have shown improvement in preservation of penile length after RP as well as some benefit in the return of erectile and sexual function [14–16]. An animal study provided some insight into this problem as mice underwent VED therapy for 4 weeks after bilateral cavernous nerve injury. The use of a VED preserved markers of erectile function through avoidance of antihypoxic and antifibrotic pathways [17]. In another study looking at VED use in mice after nerve injury, the benefits to cavernous blood oxygenation were demonstrated [18]. Despite these encouraging findings, there are no standard protocols for VED use especially with respect to the daily frequency/duration or length of rehabilitation.

We undertook a pilot study to examine the short-term effects of VED on penile oxygenation and possibly show a physiologic rationale for the use of the VED in men after RP. We hypothesized that these men would have a significant increase in penile oxygenation with the use of VED.

Material and Methods

Twenty men with normal preoperative erectile function were recruited after RP. Institutional review board approval was obtained at the senior author's institution at the time of the study. Excluded subjects included those with a significant history of cardiovascular disease in the last 6 months, those with any anatomical penile deformity, any disease contraindicating the use of PDE5is, and those that had used erectogenic aids within 7 days of the screening visit. The subject self-administered the Sexual Health Inventory for Men (SHIM) before RP and at time of study entry. All men had normal erectile function (SHIM >21) before RP. All surgeries were performed with the open, bilateral nerve sparing technique by the same surgeon.

Under supervision by the study nurse, the men were instructed on VED use to achieve a visually maximum erection. The men then cycled the VED 10 times over an approximately 2-minute period while under supervision of the study nurse in office. No constriction ring was used during the device cycling or at any point in the study. The 2-minute period was chosen as a practical point as men are in the habit of brushing their teeth for a 2-minute period twice daily. By using the VED in

Table 1 Total number of measurements per site

	Pre- VED	Immediate	5 minutes	15 minutes	30 minutes	60 minutes
Thigh	310	327	328	303	293	316
Glans	142	133	133	138	141	131
Corpora	259	265	244	259	258	243

this way, they could easily incorporate the VED exercise in their daily routine.

The Osbon ErecAid Vacuum Therapy System was used by all patients in the study and provided for them at no charge by TIMM Medical Technologies, Inc. (Eden Prairie, MN, USA). TIMM Medical Technologies, Inc. had no influence on study design or data analysis. The FDA-approved ViOptix ODISsey™ tissue oximeter (Fremont, CA, USA) was used as a noninvasive measurement of penile oximetry.

Tissue oxygen saturation was measured before VED use and then immediately after VED use. The oximeter was used at five sites: right thigh, right corpora, glans penis, left corpora, and left thigh. The sites were marked for reproducibility, and measurements taken from the corpora were done on the lateral sides at a distance of approximately 2 cm from the base of the penis. The oximeter measures and records the oxygenation at 4-second intervals. At least five measurements were captured at each site as per the previously published technique [19]. Measurements were then repeated at each site at 5, 15, 30, and 60 minutes after VED use. A total of 4,223 measurements were recorded (Table 1). These measurements were averaged in their respective groups to obtain a single measurement of each site at each time period. For final analysis, the left and right corpora and thigh measurement were averaged together into a single corporal and thigh value. The measurements taken at the patient's thigh were used as controls.

The ODISsey™ tissue oximeter uses near-infrared (NIR) and infrared wavelengths to analyze the percent oxygen saturation of hemoglobin in tissue. In these wavelengths, the light is scattered in the structure of the tissue and minimally absorbed by the skin, water, and other biologic tissues, which allows penetration into the tissue [20]. The oxygenated and deoxygenated hemoglobins primarily absorb the light but have a proclivity for different wavelengths [21]. Evaluation of the reflected and absorbed light allows the probe to obtain clinical information on the

tissue. Previous studies done on both ex vivo and in vivo testing showed a high correlation ($r = 0.9937$) between the blood gas measurements and measured oxygenation [22]. The ODISsey™ oximeter emits light from two different sources and after traveling through the tissue the light is collected by four different photo detectors for analysis. The probe measures to a tissue depth of 1 cm with the penile skin being only millimeters thick [23].

Statistical analysis was done using the commercially available JMP® statistical analysis program version 9 (available from SAS Institute Inc., Cary, NC, USA). Repeated measures analysis of variance (ANOVA) was used for each location to find if there was a significant effect of the procedure with time. Dunnett's method was used to assess whether the oxygen saturations at the recorded time points were different from those immediately before VED use. A *P* value of less than 0.05 was considered statistically significant.

Results

The mean patient age was 58 years old. The mean time from RP to study entrance was 12.6 months (range 2–24 months). The mean SHIM score at the time of study entrance was 7.

Percent saturation for both the glans and corpora had a statistically significant increase over the baseline pre-VED use level for all time points ($P < 0.001$) (Figure 1, Figure 2A–C). There was a 55% increase in the oxygenation seen in the corpora with VED use (Table 2). While there was some decay of corpora and glanular oxygenation during the study, the increases were statistically significant for the entirety of the study when compared with baseline (even 60 minutes after VED use).

Repeated measures ANOVA showed a significant effect of time. Dunnett's method showed that all individual time points were significant vs. the initial time point for the glans and corporal measurements.

Table 2 Percent change in oxygen saturation at tissue sites (percent change compared with baseline)

	Immediate	5 minutes	15 minutes	30 minutes	60 minutes
Thigh	–1	8	10	6	9
Glans	20	19	17	9	7
Corpora	55	54	45	39	18

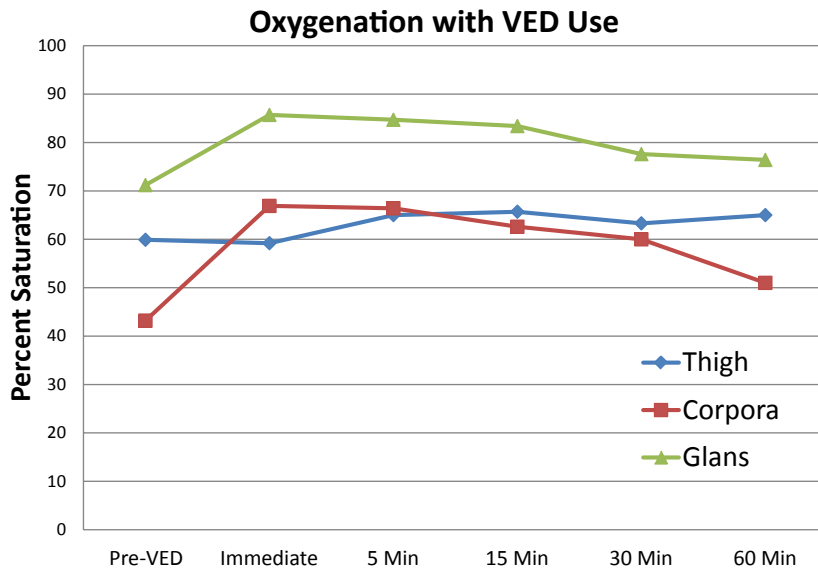


Figure 1 Tissue oxygenation after 2 minutes/10-cycle application of VED. VED = vacuum erection device

Surprisingly, the measurements at the thigh were significant at the 5- and 15-minute time points (Figure 2C). This was most likely due to a nonstandardization of patient activity during the time of the measurements. For example, patients were allowed to walk around the room or clinic and did not remain still for the entire study. While this did achieve statistical significance, it is likely not clinically significant.

Attempts to stratify results based on patient characteristics like time from surgery or patient age were unable to be completed with any statistical meaning because of the overall small size of this pilot study.

Discussion

ED is a common finding in men after RP. Due to this undesired complication, there has been an interest in penile rehabilitation in an effort to dampen the morbidity of RP with regard to ED. Oral PDE5i, ICI, IUA, and VED are all possible treatment options for patients wishing to undergo penile rehabilitation.

The rationale for penile rehabilitation is to prevent the relative hypoxia seen in the corporal tissue after the loss of spontaneous erections. This hypoxia leads to progressive fibrosis and histologic changes that are associated with both penile shortening and poor erections. Even if erectile function later returns, the penis may have already undergone significant pathological changes. Additionally, the fibrotic changes that occur during this

period of hypoxia can be irreversible and lead to long-term ED.

This study reports measured oxygen saturation changes seen with the use of a VED as part of a penile rehabilitation program. Hopefully, these transient increases in oxygen saturation mimic the intermittent increases in oxygen saturation seen with spontaneous and nocturnal erections and will lead to better long-term sexual function.

A previous study revealed the resting oxygenation of men with and without ED [19]. In men with some degree of ED (SHIM ≤ 21), an average oxygenation of 47.1% was demonstrated. Men with a SHIM greater than 21 had a statistically better mean oxygenation (57.5%). In men who achieved erection through ICI, oxygenation increased to an average of 78.5%. The 67% tissue oxygenation seen in this study directly after VED use verified that these impotent men can at least transiently increase their oxygenation to a level between the resting state of men who achieved frequent spontaneous erection and men with a pharmacologically induced erection.

We acknowledge that the lack of a sham group in this study is a limitation. Even without a sham group in this study, it provides a “proof of concept” that the VED can lead to an increase in corporal oxygenation.

The effect of the overlying skin and subcutaneous tissues above the corporal bodies on the oximetry readings is largely unknown but thought to be of a minor influence. A model using hyperthermia to cause vasodilation of the overlying skin while

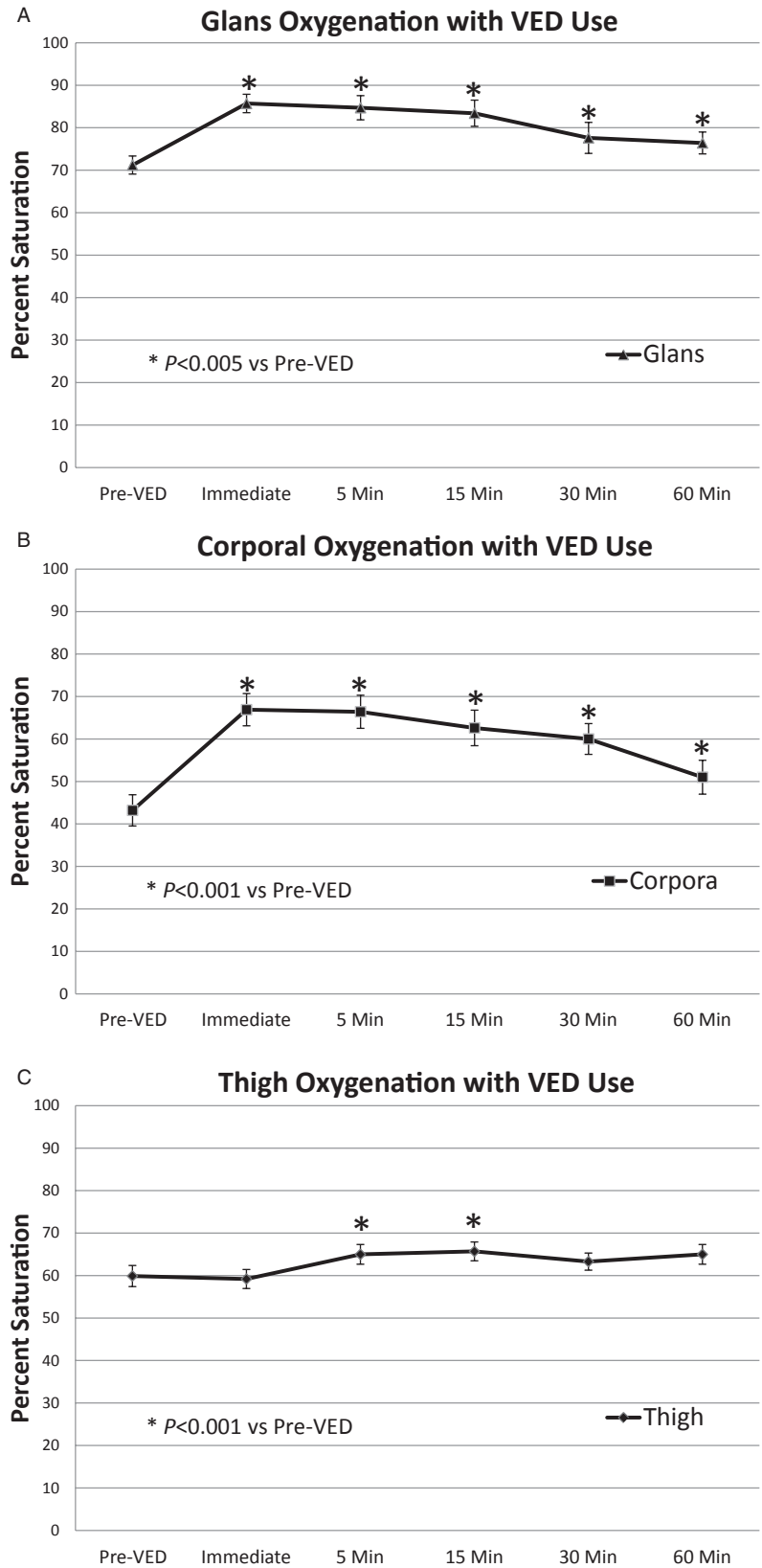


Figure 2 Oxygenation at individual tissue sites: (A) glans, (B) corpora, and (C) thigh. Error bars represent standard error of the mean. VED = vacuum erection device

measuring deep muscle oximetry showed no influence of the skin hyperemia on deeper tissue measurements [24]. These findings are encouraging in that they show that the hyperemia that may be caused by the effects of the VED on the overlying skin and subcutaneous tissue are likely not significant to the measured values of the corporal oxygenation.

NIR spectroscopy is a promising, noninvasive tool for measuring oxygenation and has been used by a variety of disciplines for differing clinical purposes. Plastic surgery literature has shown the device to be helpful in breast-free flap monitoring wherein the NIR spectrometer demonstrated the hypoxia and resulting reoxygenation with flap elevation, transfer, and anastomosis to blood supply. Additionally, after vascular re-anastomosis, NIR spectroscopy indicated venous thrombosis before clinically apparent, allowing for expeditious salvage of the flap [25]. In a study specific to urology, NIR spectroscopy was able to correctly diagnose testicular torsion in all 16 cases as verified by surgical exploration [26].

Conclusion

This study demonstrates an acute significant improvement in corporal and glans oxygen saturation after a brief application of VED. This pilot study provides a physiologic rationale for VED use in penile rehabilitation after RP. The VED is a less invasive and less expensive option compared with alternative rehabilitation protocols. Consideration should be given to routinely incorporating the VED into penile rehabilitation in all patients after RP as it is a noninvasive tool and not dependent on nerve integrity.

Corresponding Author: R. Charles Welliver Jr, MD, Southern Illinois University, 301 North Eighth St, PO Box 19665, Springfield, IL 62794, USA. Tel: 217-545-7285; Fax: 217-545-7305; E-mail: rwelliver@siu.edu

Conflict of Interest: R.C. Welliver Jr, C. Mechlin, and B. Goodwin report no conflicts of interest. J.P. Alukal: Meeting Participant/Lecturer for Lilly and Auxilium. Research and Education financed by Coloplast. A.R. McCullough is a meeting participant or Lecturer for Auxilium, Lilly and Endo. Investment Interest in Pfizer. Owner/Product development with MebMD. Consultant or Advisor for Repros and Coloplast. Scientific Study or Trial with Antares, Slate, Vivus, Auxilium.

Statement of Authorship

Category 1

(a) Conception and Design

Joseph P. Alukal; Andrew R. McCullough; R. Charles Welliver Jr

(b) Acquisition of Data

Brianne Goodwin; Andrew R. McCullough

(c) Analysis and Interpretation of Data

R. Charles Welliver Jr; Clay Mechlin; Andrew R. McCullough

Category 2

(a) Drafting the Article

R. Charles Welliver Jr

(b) Revising It for Intellectual Content

R. Charles Welliver Jr; Clay Mechlin; Joseph P. Alukal; Andrew R. McCullough

Category 3

(a) Final Approval of the Completed Article

R. Charles Welliver Jr; Andrew R. McCullough

References

- McCullough AR, Levine LA, Padma-Nathan H. Return of nocturnal erections and erectile function after bilateral nerve-sparing radical prostatectomy in men treated nightly with sildenafil citrate: Subanalysis of a longitudinal randomized double-blind placebo-controlled trial. *J Sex Med* 2008;5:476–84.
- Klein LT, Miller MI, Buttyan R, Raffo AJ, Burchard M, Devris G, Cao YC, Olsson C, Shabsigh R. Apoptosis in the rat penis after penile denervation. *J Urol* 1997;158:626–30.
- Iacono F, Giannella R, Somma P, Manno G, Fusco F, Mirone V. Histological alterations in cavernous tissue after radical prostatectomy. *J Urol* 2005;173:1673–6.
- User HM, Hairston JH, Zelner DJ, McKenna KE, McVary KT. Penile weight and cell subtype specific changes in a post-radical prostatectomy model of erectile dysfunction. *J Urol* 2003;169:1175–9.
- Moreland RB. Is there a role of hypoxemia in penile fibrosis: A viewpoint presented to the Society for the Study of Impotence. *Int J Impot Res* 1998;10:113–20.
- Vignozzi L, Morelli A, Filippi S, Vannelli GB, Mungai S, Marini M, Boddi V, Forti G, Maggi M. Effect of sildenafil administration on penile hypoxia induced by cavernous neurotomy in the rat. *Int J Impot Res* 2008;20:60–7.
- Montorsi F, Guazzoni G, Stambli LF, DaPozzo LF, Nava L, Barbieri L, Rigatti P, Pizzini G, Miani A. Recovery of spontaneous erectile function after nerve-sparing radical retropubic prostatectomy with and without early intracavernous injections of alprostadil: Results of a prospective, randomized trial. *J Urol* 1997;158:1408–10.
- Teloken P, Mesquita G, Montorsi F, Mulhall J. Post-radical prostatectomy pharmacological penile rehabilitation: Practice patterns among the international society for sexual medicine practitioners. *J Sex Med* 2009;6:2032–8.
- Mulhall JP, Bivalacqua TJ, Becher EF. Standard operating procedure for the preservation of erectile function outcomes after radical prostatectomy. *J Sex Med* 2013;10:191–203.
- Porst H, Burnett A, Brock G, Ghanem H, Guiliano F, Glina S, Hellstrom W, Martin-Morales A, Salonia A, Sharlip I, The

- ISSM Standards Committee for Sexual Medicine. SOP conservative (medical and mechanical) treatment of erectile dysfunction. *J Sex Med* 2013;10:130–71.
- 11 Tal R, Teloken P, Mulhall JP. Erectile function rehabilitation after radical prostatectomy: Practice patterns among AUA members. *J Sex Med* 2011;8:2370–6.
 - 12 Brison B, Seftel A, Sadeghi-Nejad H. The resurgence of the vacuum erection device (VED) for the treatment of erectile dysfunction. *J Sex Med* 2013;10:1124–35.
 - 13 Broderick GA, McGahan JP, Stone AR, White RD. The hemodynamics of vacuum constriction erections: Assessment by color Doppler ultrasound. *J Urol* 1992;147:57–61.
 - 14 Raina R, Agarwal A, Ausmundson S, Lakin M, Nandipati KC, Montague DK, Mansour D, Zippe CD. Early use of vacuum constriction device following radical prostatectomy facilitates early sexual activity and potentially earlier return of erectile function. *Int J Impot Res* 2006;18:77–81.
 - 15 Dalkin BL, Christopher BA. Preservation of penile length after radical prostatectomy: Early intervention with a vacuum erection device. *Int J Impot Res* 2007;19:501–4.
 - 16 Köhler TS, Pedro R, Hendlin K, Utz W, Ugarte R, Reddy P, Makhlof A, Ryndin I, Canales BK, Weilland D, Nakib N, Ramani A, Anderson JK, Monga M. A pilot study on the early use of the vacuum erection device after radical retropubic prostatectomy. *BJU Int* 2007;100:858–62.
 - 17 Yuan J, Lin H, Li P, Zhang R, Luo A, Berardinelli F, Dai Y, Wang R. Molecular mechanisms of vacuum therapy in penile rehabilitation: A novel animal study. *Eur Urol* 2010;58:773–80.
 - 18 Lin HC, Yan WL, Zhang JL, Dai YT, Wang R. Penile rehabilitation with a vacuum erectile device in an animal model is related to an antihypoxic mechanism: Blood gas evidence. *Asian J Androl* 2013;15:387–90.
 - 19 Padmanabhan P, McCullough AR. Penile oxygen saturation in the flaccid and erect penis in men with and without erectile dysfunction. *J Androl* 2007;28:223–8.
 - 20 Wahr JA, Tremper KK, Samra S, Delpy DT. Near-infrared spectroscopy: Theory and applications. *J Cardiothorac Vasc Anesth* 1996;10:406–18.
 - 21 Wray S, Cope M, Delpy DP, Wyatt JS, Reynolds EO. Characteristics of the near infrared absorptions spectra of cytochrome aa3 and haemoglobin for the noninvasive monitoring of cerebral oxygenation. *Biochim Biophys Acta* 1988;933:184–92.
 - 22 Xu X, Zhu W, Padival V, Xia M, Cheng X, Bush R, Christenson L, Chan T, Doherty T, Iatridis A. Validation of NIRS in measuring tissue hemoglobin concentration and oxygen saturation on ex vivo and isolated limb models. *Proc SPIE* 2003;4955:369–78.
 - 23 Mao JM, Xu R, Lash B, Wright L. Quantitative evaluation of ViOptix's tissue oximeter in an ex-vivo animal model. *Proc SPIE* 2008;6849:1–12.
 - 24 Mancini DM, Bolinger L, Li H, Kendrick K, Chance B, Wilson JR. Validation of near-infrared spectroscopy in humans. *J Appl Physiol* 1994;77:2740–7.
 - 25 Keller A. Non-invasive tissue oximetry for flap monitoring: An initial study. *J Reconstr Microsurg* 2007;23:189–97.
 - 26 Burgu B, Aydogdu O, Huang R, Soygur T, Yaman O, Baker L. Pilot feasibility study of transscrotal near infrared spectroscopy in the evaluation of adult acute scrotum. *J Urol* 2013;190:124–9.