

Protective Role of BioGeometry Against Indoor Pollutants of Some Egyptian Building Materials in Adult Male Rats

¹Nevin E. Sharaf, ²Mohamed Samir El-Sawy, ²Fateheya M. Metwally,
³Zakaria El-Khayat and ⁴Abdel-Razik Farag

¹Environmental and Occupational Medicine Department,
National Research Centre, Dokki, Giza, Egypt

²Department of Architecture, Faculty of Engineering, Misr International University Cairo, Egypt

³Department of Biochemistry, National Research Centre, Dokki, Giza, Egypt

⁴Department of Pathology, National Research Centre, Dokki, Giza, Egypt

Abstract: Good buildings should satisfy principles of durability, utility and beauty. Recently, to be sustainable to the surrounding environment, to be healthier to their occupants and lately to be able to heal and harmonize the negative energy fields created by modern technology. The significance of indoor climate for health and comfort has been emphasized, as people spend about 90% of their time indoors, especially the children and elders. The number of complaints about the quality of indoor air has increased. These complaints have been coined with the term Sick Building Syndrome. Complaints are likely related to the increased use of variety of materials in building, furnishing, with decreased ventilation inside homes. BioGeometry is one of the new energy quality sciences that emerged in architecture as a response to the hazards of modern technology. Based on physics of quality, the revolutionary science of bioGeometry uses the energy principles of geometric form to introduce natural balance to the different energy-qualities found in any living system. This study was done to assess the health effects resulted from housing of adult male rats in buildings with microclimate, which are termed "sick buildings" due to accumulation of various chemicals, organic substances and others, in these buildings and to study the effects of using biogeometric shapes, designed by bioGeometry principles, on reducing these harmful effects. The result of the present work revealed a protective role for the biogeometric shapes, in modulating the toxic and damaging effects of this microclimate on the lung, liver, kidney and thyroid tissues of the studied groups of rats. The mechanism by which these biogeometric shapes induce their effects could be attributed to the empowerment of the immune system and the support of self-healing. So, it is a form of protective energy balance that only indirectly affects the health and wellbeing.

Key words: Architecture • BioGeometry • Energy balance • Health effects • Indoor air • Protective role • Sickbuildings syndrome.

INTRODUCTION

According to Vitruvius, the Roman architect in the early 1st century AD, a good building should satisfy the three principles of durability, utility and beauty [1]. In the late 20th century a new concept was added to those, included the consideration of sustainability [2]. To satisfy these, a building should be constructed in a manner which is environmentally friendly in terms of the production of its materials, its impact upon the natural and built

environment of its surrounding area and the demands that it makes upon non-sustainable power sources. Present day architects try to incorporate new materials to transform the market toward healthier building materials, which enhance the health of the occupant. Also, new ideas by which buildings could be designed to heal and harmonize the negative energy fields created by modern technology [3]. In recent years, the significance of indoor climate for health and comfort has been emphasized, as people spend about 90% of their time indoors, especially

the children and elders [4]. Therefore, the quality of indoor air is even more important than outdoor air [5, 6]. The number of complaints about the quality of indoor air has increased; they are likely related to the increased use of synthetic organic materials in house and furnishing and the decreased ventilation in homes [7]. The complaints most frequently voiced with respect to sick buildings syndrome are irritations of the eye, nose and throat; cough and hoarseness of voice [8], headache, depression and mental fatigue [9]. In addition to synthetic organic materials used, radon was considered as one of the four principal categories of indoor pollution [10]. Maged and Ashraf [11] found that, the common building materials used for construction of houses in Egypt, are considered as one of the major sources of the radon gas in indoor environment. However, Melloni *et al.* [12] found that the health effects of low levels of exposure to indoor radon are very contradictory and building materials used, especially in home decoration make no significant contribution to indoor radon for a house with adequate air exchange [13]. In addition, Steck and Field [14] viewed that the concentration of radon alone may not be an adequate surrogate measure for lung cancer risk in all residential radon epidemiologic lung cancer studies.

BioGeometry is one of the new energy quality sciences that emerged in architecture as a response to the hazards of modern technology. BioGeometry was founded by Egyptian Architect and Scientist Dr. Ibrahim Karim (D.Sc./Dipl. Arch.-ETH, Zurich) after more than 30 years of research. Dr. Karim's breakthrough research identified a unique energy effect found in the energetic centers of all living systems. It is a science, which use shapes, colors, motion, orientations and sounds to balance the qualities at all levels of energy in the surrounding environment. Research in Bio-geometry was and still dedicated to the development of a new form of architecture that would enhance human biological system, by using a dimensioning system that produces subtle energy balancing effect in the environment through the proportional properties of shape [3]. BioGeometry is based on a growing body of scientific research and is an applied science by virtue of its successful applicability in numerous fields. BioGeometry energy-quality balancing solutions are being applied to architecture, telecom networks, industrial design, boats and airplanes to transmute the effects of environmental energy disturbances from sources such as electro-magnetic radiation, structural design and cosmic and earth-energy radiation. BioGeometry is also being applied in agriculture,

poultry, fish and livestock farming to increase productivity and quality, despite the reduction of artificial additives and treatments.

The Main Purposes of this Study Are:

- To assess the health effects of pollution from multiple and mixed emissions from a variety of products used in buildings.
- To study the effects of using biogeometric shapes, designed by biogeometry principles, on reducing the harmful effects from using some Egyptian building materials.

MATERIALS AND METHODS

Materials: Forty two adult male albino rats of the same age (3 months) and weighted between 110-120 g, obtained from the animal house colony of the National Research Center, Dokki, Giza, Egypt were used in this study. The animals were maintained in a controlled environment (22-25°C and 12 hours' light-12 hours' dark) with food and water freely available. All animals were kept in a stress less environment. After an acclimation period of one week, the animals were divided into three groups:

Group I: Fourteen adult male rats were housed in plastic cages and served as control group.

Group II: Fourteen adult male rats were housed in square cages 40 cm x 40 cm x 60 cm. These cages were built from the local Egyptian building materials (Red Brick Fayoum, Qena Cement, El Ahalia Ceramic and Kappy Painting) (Fig. 1).

Group III: Fourteen adult male rats were housed in the same design of cages of group II, using the biogeometry solutions (biogeometric shapes, designed by biogeometry principles) (Fig. 2a, b, c).

At the end of the experimental period (12 weeks), blood samples were collected from retro-orbital plexus of the individual of all groups after being fasted for 12 hours. Blood samples were left to clot and then centrifuged at 5000 r.p.m under cooling for 10 minutes to separate the sera for the following biochemical analysis. Then all animals were sacrificed and the organs: lung, liver and kidney were prepared for histological examination.

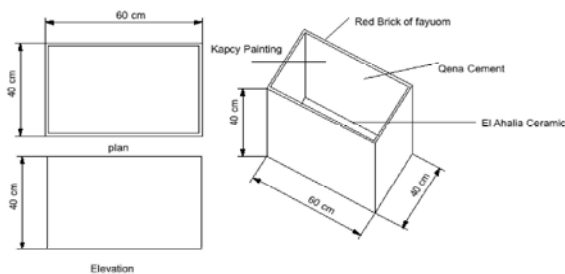


Fig. 1: Housing model of group II.

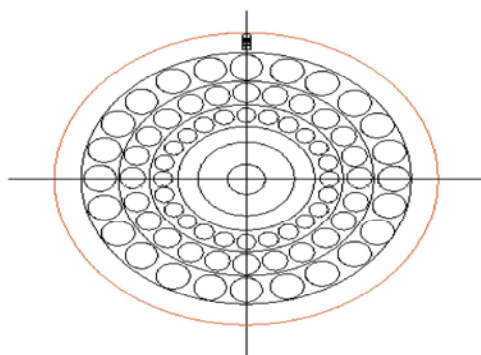


Fig. 2a: Showing the water tank designed by Dr. Mohamed Elsayy, to enhance the energy quality of water. Group 3 only had its water supply from this tank

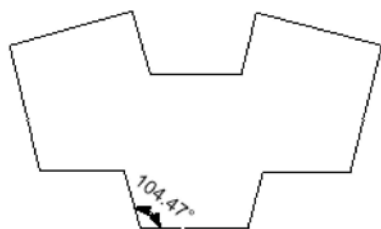


Fig. 2b: Showing the balancing wheel designed by Dr. Ibrahim Karim, to enhance the energy quality of materials. Group 3 only had its balancing materials through this wheel.

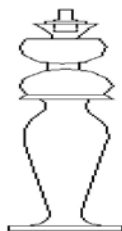


Fig. 2c: Showing the corner stand designed by Dr. Ibrahim Karim to enhance the energy quality of space. Group 3 only had its balancing quality through this form

Fig. 2: BioGeometry elements.

Methods: The Following Biochemical Analysis Was Done:

Determination of Serum Aminotransferase Enzyme Activities: Aspartate aminotransferase (AST) and alanine aminotransferases (ALT) according to the method described by Tietz [15] using Point Scientific kit, INC, USA.

Determination of Serum Creatinine: By using the method described by Bartels *et al.* [16], using Point Scientific kit, INC, USA.

Determination of the Thyroid Functions: By the quantitative measurement of thyroid stimulating hormone (TSH), which was carried out using the immunoradiometric assay of Fraser and Browning [17]. The total 3, 5, 3- triiodothyronine (T_3) and L- thyroxine (T_4) were quantitatively determined by the enzyme immunoassay procedure of Tietz [18] and Robbins [19], respectively, using Biochem Immunosystem kits, Italy.

Histopathological Studies: Lung, liver and kidney were removed and rapidly washed in saline solution to remove the blood then weighted and rapidly fixed in 10% neutral buffered formalin for 24 hours, then they were processed up in paraffin wax. Sections of $7\mu\text{m}$ thickness were prepared and stained with haematoxylin and eosin dye for studies.

RESULTS

As seen in Table 1, the tri-iodothyronine (T_3) and the L thyroxine (T_4) levels showed increase, while the TSH showed decrease in group II, but these differences were only significant for the level of T_3 , when compared to those of group I. However, the use of BioGeometry elements and shapes (Group III) had enhanced the thyrotoxicosis induced and the hormones reached nearly the levels of Group I. The difference was only significant for T_3 level. In the same Table, aspartate aminotransferase (AST) and alanine aminotransferase (ALT) levels were higher in group II, compared to group I, while those of group III showed decrease compared to group II, reaching nearly those of group I. These differences were not statistically significant. The serum creatinine levels in the three groups showed non-significant change.

Lungs: The lung section of group II showed that the lung septa were infiltrated by neutrophils and macrophages and thickened with the appearance of pulmonary edema

Table 1: Some biochemical parameters in the three groups of the study

GroupsParameters	Group I (Control)	Group II	Group III
T ₃ (ng/dl)	238.393 ± 26.895	543.7143** ± 89.2	247.679** ± 27.5
T ₄ (ng/dl)	0.724 ± 0.393	1.1491 ± 0.0442	0.7955 ± 0.462
TSH (μIU/ml)	0.1087 ± 0.122	0.0945 ± 0.01874	0.1121 ± 0.02027
AST (IU/L)	51.5 ± 9.929	77.8571 ± 8.018	52.143 ± 8.018
ALT (IU/L)	18.479 ± 0.872	27.7143 ± 1.267	18.4157 ± 0.56
S. Creatinine (mg/dl)	0.921 ± 0.197	0.960 ± 0.202	0.900 ± 0.257

Values are mean ± SD of 14 rats per group.

** Highly significant change (P<0.01) when the group compared with the control group.

* Highly significant change (P<0.01) when the group III compared with group II

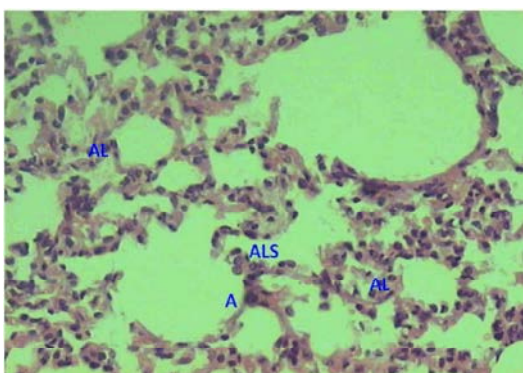


Fig. 3: Section of control rat (group I) showing normal structure of lung. Notice normal alveolar parenchyma: Terminal and respiratory bronchioles, alveolar ducts (AL), alveolar sacs (ALS), and a small artery (A) are shown (H&E X 100).

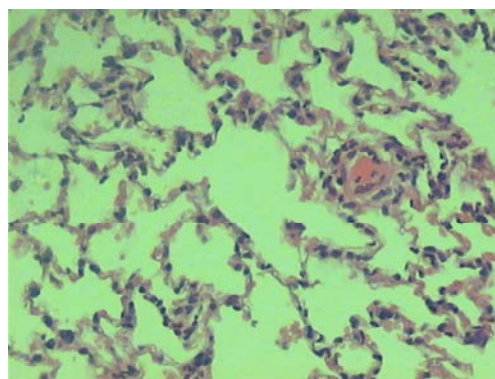


Fig. 5: Section of lung of rat of group III showing normal structure except focal pulmonary edema (H&E X 100).

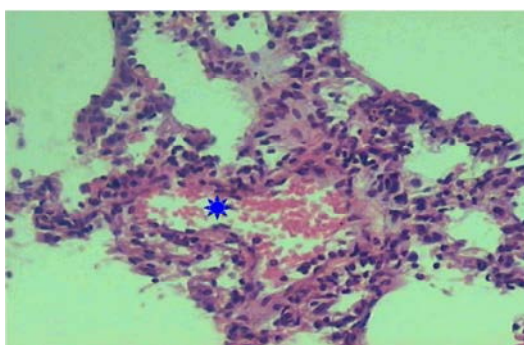


Fig. 4: Section of lung of rat of group II showing pulmonary edema (*): Eosinophilic fluid fills and septal thickening (H&E X 100).

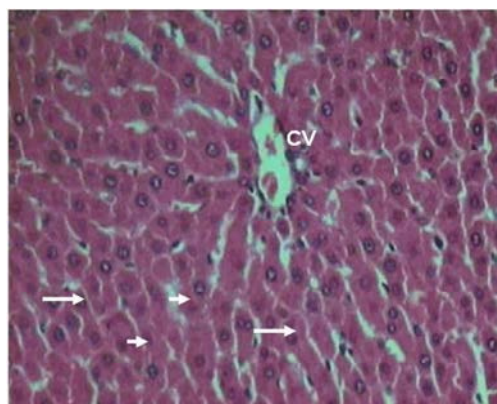


Fig. 6: Section of control rat liver (group I) showing normal structure of liver showing the hepatic lobules. Notice the central veins (CV), hepatocytes (arrows), and blood sinusoids (arrowheads) (H & E X 150).

(Fig.4) compared to those of group I (Fig. 3). On the other side the lung section of group III showed that the lung tissue appears more or less like normal one except some foci of pulmonary edema (Fig. 5).

Liver: Examination of liver sections of group II showed the following changes, when compared to the common characteristics of lobular organization (Fig. 6), dilatation

and congestion of the portal tract. The periportal necrosis of the hepatocytes that surround the portal area and mild areas of inflammatory cell infiltration were also noticed (Fig. 7). In some rats, liver showed fatty change, dilated and congested blood sinusoids (Fig. 8). In another, liver showed disturbance of the hepatic lobule and dilatation

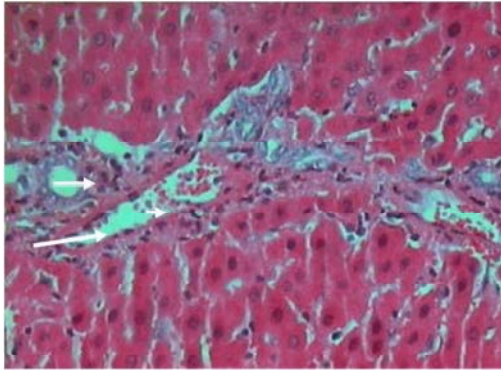


Fig. 7: Section of rat liver exposed to MHBM showing a portal tract with dilated and congested vein (arrow). Notice, the periportal necrosis of the hepatocytes that surround the portal area (long arrow), and the inflammatory infiltration (arrowhead) (H & E X 150).

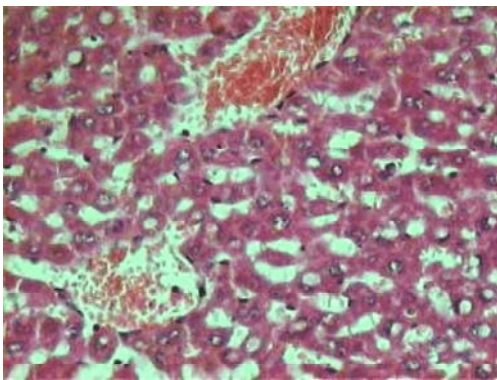


Fig. 8: Section of rat liver of group II showing fatty change (arrow). Notice the dilated and congested sinusoids (arrowhead) (H & E X 150).

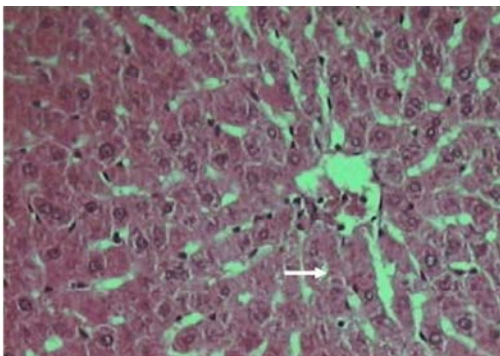


Fig. 9: Section of liver of rat receiving the effect of bioGeometry elements (group III) showing the hepatic lobules that appear more or less like normal one except slight dilatation of blood sinusoids (arrow) (H & E X 150).

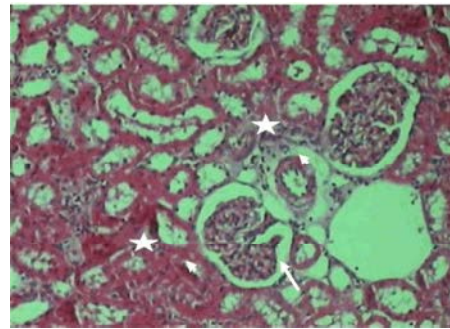


Fig. 10: Section of kidney of rat of group II showing glomeruli that revealed hypercellularity (astersik), extensive degeneration and congestion (arrow). Notice the dilated urinary spaces and some cellular debris in the tubules (arrowhead) (H & E X 150).

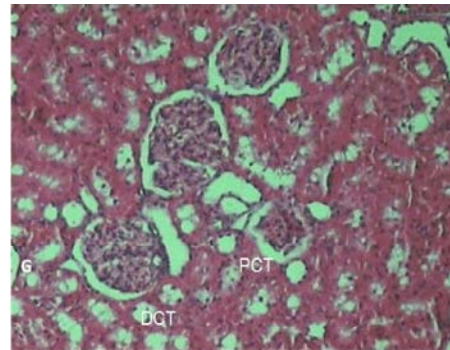


Fig. 11: Section the cortical tissue of the kidney of control rat group I showing renal corpuscle and renal tubules, proximal convoluted tubules (PCT) and distal convoluted tubules (DCT). Notice the glomerulus (G), urinary space (US) and Bowman's capsule (BC). (H & E X 150).

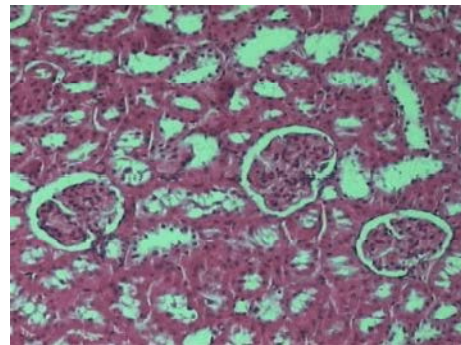


Fig. 12: Section of kidney of rat receiving the effect of biogeometry elements (Group III) showing glomeruli and renal tubules that appear more or less like normal one (H & E X 150).

and congestion of sinusoids. Focal necrosis of the hepatocytes, karyolitic or pyknotic nuclei and pale glassy cytoplasm were appeared. Congested portal areas were also seen. Histopathological examination of liver of rats of group III showed that the structure of hepatic lobules appeared more or less like normal one except slight dilatation of blood sinusoids (Fig. 9). On the other hand, portal tract appear more or less like normal one.

Kidneys: Kidney section of Group II, showed hemorrhagic areas present in the interstitial tissue (Fig.10). It demonstrated mild histological alterations in the form of interstitial dilatation associated with some cellular debris. The renal corpuscles showed different stages of glomerular degeneration and necrosis. These degenerative changes appeared in the form of hypercellularity, partial or complete glomerular degeneration. The renal corpuscles also, showed congestion and wide urinary spaces. Haemorrhagic areas and aggregation of lymphocyte infiltration were encountered in the tissues of the cortex. In comparison to that of group I (Fig. 11). Kidneys of (Group III) showed normal structure except some cellular debris in the tubules (Fig. 12). In other sections, the glomeruli and renal tubules appear more or less like normal one.

DISCUSSION

Changes in building industry during last 30 years in search of economic technologies and building materials ended in creating constructions with reduced ventilation. As a result, accumulation of various chemicals and volatile organic compounds (e.g. formaldehyde, NH₃, aromatic hydrocarbons), which irritate mucous membrane, promote intense infections and allergic diseases. Also people, especially children and elders, spend about 90% of their time indoors; therefore the quality of indoor air is even more important than outdoor air [20, 21]. Good indoor climate decreases the number of illnesses and sick-building syndrome symptoms and improves comfort and productivity [5]. BioGeometry shapes are designed to introduce harmony to the background energy waves. BioGeometrical shapes are two- or three-dimensional shapes, designed to interact with the energy fields of the earth to produce balancing effects on multiple levels of biological systems. It is a design language of shapes results in an empowerment of the immune system and supports self-healing. It is a form of protective energy balance that only indirectly affects the health and

wellbeing [3]. Our vital energy systems are in constant interaction with each other and with our environment, exchanging energy effects on all levels. These energy effects can be grouped or categorized in a qualitative scale according to their resonant and harmonic effects on biological energy systems. Based on a physics of quality, the revolutionary science of BioGeometry uses the subtle energy principles of geometric form to introduce natural balance to the different energy-qualities found in any living system.

The current study revealed clearly that housing of rats under the above mentioned conditions resulted in injury to the lungs represented by damage to the components of the alveolar wall, septal edema and endothelial cell alterations. This, could be attributed to the effects of solvents [22], they reported that histopathological examination of the lungs, in all species of animals exposed to the solvents revealed nonspecific inflammatory changes. Also, in this work, there was an evidence of interstitial inflammation, pneumonitis and varying degrees of lung congestion. Those changes are similar to that of fibrosing alveolitis, [23-26], with variability in time of onset of changes [27]. The last changes might be due to chemical emissions from the building material used leading to inflammatory changes in lungs. Selgrade and Gilmour [28] reported that, inhalation of trichloroethylene and chloroform, which are the main indoor pollutants, cause suppression of pulmonary host defenses and enhanced susceptibility to respiratory bacterial infection in mice. Also, Pariselli *et al.* [29] reported that volatile organic compounds (VOCs) belonging to the main air pollutants found in indoor environments, resulted in induction of an inflammatory lung response. Many authors concluded that FA could be considered not only an irritant but also serve as an adjuvant for the onset of asthma or asthma-like symptoms [30]. Furthermore exposure to air borne FA induces a significant increase in IL-8, which could lead to the initiation or pathogenesis of non-specific respiratory inflammation [31].

Many studies detected that, newly built or renovated schools had VOC levels and FA above the guideline values [32, 33, 7]. The latter added in their review that individual exposures strongly depend on indoor concentrations in houses and the health risk from indoor air pollutants was greater than that from outdoor pollutants [8]. Abbritti and Muzi [6] suggested further researches needed to be done studying the additive and the synergistic effects of mixtures of chemicals into the

indoor environment, in a trial to decrease the incidence of the building related illness or multiple chemical sensitivity, which has been increased during the past two decades [8, 20, 34]. Chen *et al.* [10] considered the combustion products, chemical and organic compounds, biological species and radon as the main principal elements of indoor pollutants. Maged and Ashraf [11] found that common building materials used for construction of houses in Egypt, are considered as one of the major sources of the radon gas in indoor environment. Generally speaking, building materials used, especially in home decoration make no significant contribution to indoor radon for a house with adequate air exchange [13]. Melloni *et al.* [12] concluded that effects of low levels of exposure to radon and the role of indoor radon are very contradictory. In addition, Steck and Field [14] viewed that the concentration of radon alone may not be an adequate surrogate measure for lung cancer risk in all residential radon epidemiologic lung cancer studies. The dose delivered to the lungs per unit radon exposure can vary significantly with exposure conditions.

Histopathological changes of the liver section of group II in the present study are in accordance with those mentioned in the study of Abdel Razik *et al.* [35]. They found that, liver cell death and cell infiltration in hepatic parenchyma due to solvents exposure to a total alcoholic extracts. A further support to our findings is reported by Xiao and Levin, [36]. They suggested that the multiple solvents present in paints and glues may produce liver injury and central-lobular necrosis, with or without steatosis. The severity of those effects is largely dependent on the level of exposure and the specificity of the compound. Serum enzymes primarily reflect acute disruption of cell membrane integrity (liver cell 'leaking') rather than uptake, metabolism, storage and excretion functions of the liver cells. Therefore, they cannot accurately reflect more subtle accumulative damage until late in the injury process. The failure of serum enzyme tests to identify the early phases or progression of liver injury has been shown in the study of Nunes de Paiva *et al.* [37] and El Hady *et al.* [38]. These tests have been criticized for non-specificity and poor positive predictive value in identifying true occupational liver injury. Moreover, they are thought to be of limited use for screening workers exposed to solvents [39]. Trichloroethylene (TCE) exposure through inhalation route induces hepatotoxicity in terms of marked necrosis with fatty changes and by modulating the lysosomal enzymes [40]. The results of Soni *et al.* [41] support the concept that the toxicity and repair for TCE are opposing

responses and that a dose-related increase in tissue repair represents a dynamic, quantifiable compensatory mechanism. The alanine aminotransferase (ALT) did not show a dose response at any of the time points studied. In vitro, addition of trichloroacetic acid, a metabolite of TCE to plasma, decreased the activities of ALT indicating that metabolites formed during TCE toxicity may interfere with plasma enzyme activities *in vivo* [41]. In addition, the study of Luo *et al.* [42] demonstrated that, there was a significant dose-response relationship existed between liver function abnormalities and the dimethylformamide (DMF) exposure among workers in Taiwan. Moreover, our results, agree with those previously reported by Guzelian *et al.* [43], who suggested that pericentral fatty liver with mild "reactive hepatitis" is the most likely diagnosis in workers exposed to solvents for which common causes of mild liver test abnormalities have been excluded.

On the contrary, it was found that injury of liver by organic solvents did not induce hepatic damage [44]. Oral TCE appears to have very limited capacity to cause liver injury in male rats. These might be related to the fact that TCE is apparently exhaled so quickly that there is relatively little time for its metabolic activation in the liver [45]. In addition to that, small and delayed increase in relative liver weight was observed in female rats following 10 days of inhalation of 6000 ppm 1, 2 dichloroethene (DCE) [46]. It appears that the central nervous system (CNS), kidneys and liver are the most likely target organs for DCE and DCE and most other VOCs are CNS depressants and lung irritants [47]. There was no apparent progression of organ damage during the sub chronic study, or appearance for adverse effects in the short-term exposures for DCE [48]. Nevertheless, Besnhofer *et al.* [49] found a minor degree of liver damage at the high dose. In this work kidney section of Group II, showed hemorrhagic areas present in the interstitial tissue. It is also demonstrated mild histological alterations in the form of interstitial dilatation associated with some cellular debris. The renal corpuscles showed different stages of glomerular degeneration and necrosis. These degenerative changes appeared in the form of hypercellularity, partial or complete glomerular degeneration. The renal corpuscles also, showed congestion and wide urinary spaces. Haemorrhagic areas and aggregation of lymphocyte infiltration were encountered in the tissues of the cortex. Exposure to organic solvents entails a risk of renal dysfunction [50]. The severity of those effects is largely dependent on the specificity and variability in the concentration of the environmental solvents and duration of exposure [51].

Trichloroethylene (TCE), an industrial and metal degreasing and paint remover solvent, is a major environmental contaminant that can cause severe damage to kidney, intestine, liver and brain; altered carbohydrate metabolism and suppressed antioxidant defense system [52]. Voss *et al.* [53] found a significant increase in albumin excretion in groups of workers exposed to various solvents (like toluene, styrene, aliphatic/aromatic hydrocarbon mixtures, tetrachloroethene, mixtures of chlorinated hydrocarbons) than in controls (group I). Besnhofer *et al.* [49] found that rats treated with high-dose of diethylene glycol which is a paint stripper got metabolic acidosis, increased BUN and creatinine, with marked kidney necrosis, noted by histopathology. Serum creatinine has a limited value in the detection of early renal damage and thus urinary enzymes such as NAG could be used as markers for early tubular injury, as a sensitive marker of early nephrotoxicity [54] in future liked design. In order to evaluate the exposure to the combined effect of some Egyptian buildings materials used and act as source of indoor air pollution, on certain biochemical parameters of rats, the thyroid function tests were assessed. The serum levels of (T₃) and (T₄) showed increase in adult male rats exposed to the combined hazards of tested building materials, but that increase was only significant for the level of T₃. The VOC's used affects the thyroid resulting in inflammatory tissue reactions. Meanwhile the apparent hypertrophy, a state of thyrotoxicity will be created and the production of T₃ will be enhanced and its conversion to T₄ is not retarded. That is why both T₃ and T₄ are increased. The same findings have been observed by Uzma *et al.* [55] and Saad *et al.* [56], who confirmed that hyperthyroidism is a great risk, resulting from exposure to solvents.

REFERENCES

- Rowland, D. and T.N. Howe, Vitruvius. Ten Books on Architecture. Cambridge University Press, Cambridge 1999, ISBN 0-521-00292-3.
- Rondanini, N., 1981. Architecture and Social Change Heresies II, Vol. 3, No. 3, New York, Neresies Collective Inc.
- Karim, I., 2007. Back to a Future for Mankind. Emerald Publishing, Cairo, Egypt, ISBN: 978-977-6232-01-3.
- Billionnet, C., D. Sherrill and I. Annesi-Maesano, GERIE study, 2012. Estimating the health effects of exposure to multi-pollutant mixture. *Ann. Epidemiol.* 22: 126-141.
- Maroni, M., 2004. Indoor air quality and occupational health, past and present. *G Ital Med. Lav. Ergon.* 26(4): 353-63.
- Abbritti, G. and G. Muzi, 2006. Indoor air quality and health in offices and other non-industrial working environments. *Med. Lav.*, 97(2): 410-7.
- Chikara, H., S. Iwamoto and T. Yoshimura, 2009. Indoor air pollution of volatile organic compounds: indoor/outdoor concentrations, sources and exposures. *Nihon Eiseigaku Zasshi.* 64(3): 683-8.
- Ando, M., 2002. Indoor air and human health--sick house syndrome and multiple chemical sensitivity. *Kokuritsu Iyakuin Shokuhin Eisei Kenkyusho Hokoku*, 120: 6-38.
- Lawrence, A.N., 2013. Urban air pollution & its assessment in Lucknow City-The second largest city of North India. *Sci. Total Environ.* 2013 Dec 4. pii: S0048-9697(13)01250-3.
- Chen, B.H., C.J. Hong, M.R. Pandey and K.R. Smith, 1990. Indoor air pollution in developing countries. *World Health Stat Q.*, 43(3): 127-38.
- Maged, A.F. and F.A. Ashraf, 2005. Radon exhalation rate of some building materials used in Egypt. *Environ. Geochem. Health*, 27(5-6): 485-9.
- Melloni, B., A. Vergnenègre, P. Lagrange and F. Bonnaud, 2000. Radon and domestic exposure. *Rev. Mal. Respir.* 17(6): 1061-71.
- Chen, J., N.M. Rahman and I. Abu Atiya, 2010. Radon exhalation from building materials for decorative use. *J. Environ. Radioact.* 101(4): 317-22.
- Steck, D.J. and R.W. Field, 2006. Dosimetric challenges for residential radon epidemiology. *J Toxicol. Environ. Health A.* 69(7): 655-64.
- Tietz, N.W., 1976. *Fundamentals of clinical Chemistry.* 2nd Ed. Philadelphia, W. B. Saunders Co. pp: 657.
- Bartles, H., M. Bohmer and C. Heirll, 1972. Serum creatinine determination without protein precipitation. *Clin. Chem. Acta*, 37: 193-197.
- Fraser, C.G. and M.C.K. Browning, 1985. Measuring serum thyrotropin. *Lancet.* 1: 816-817.
- Tietz, N.W., 1986. *Fundamentals of clinical Chemistry.* 2nd Ed. Philadelphia, W. B. Saunders Co. pp: 588.
- Robbins, J., 1971. Thyroxine-binding Protein in Serum. In Sunderman and Sunderman Editors. *Laboratory Diagnosis of Endocrine Diseases.* St. Louis (MO): Warren H. Green, Inc. pp: 211.
- Bogacka, E., 2002. Health threats for children in the modern building trade *Pol Merkur Lekarski*, 12(68): 143-6.

21. Colbeck, I., Z.A. Nasir and Z. Ali, 2010. Characteristics of indoor/outdoor particulate pollution in urban and rural residential environment of Pakistan. *Indoor Air*, 20(1): 40-51.
22. Billings, C.G. and P. Howard. 1994. Hypothesis: exposure to solvents may cause fibrosing alveolitis. *Eur. Respir. J.*, 7: 1172-1176.
23. Crofton, J. and A. Douglas, 1981. Diffuse Fibrosing Alveolitis and Honeycomb Lung. In: *Respiratory Diseases*. 3rd Ed. Oxford, Blackwell Scientific Publications, pp: 686-698.
24. Prendergast, J.A., R.A. Jones, L.J. Jenkins Jr and J. Siegel, 1967. Effects on experimental animals of long-term inhalation of trichloroethylene, carbon tetrachloride, 1, 1, 1-trichloroethane, dichlorodifluoromethane and 1, 1-dichloroethylene. *Toxicol. Appl. Pharmacol.*, 10: 270-289.
25. Plopper, C.G., D.M. Hyde and A.J. Weir, 1983. Centriacinar alterations in lungs of cats chronically exposed to diesel exhaust. *Lab. Invest.*, 49: 391-399.
26. Hyde, D.M., C.G. Plopper, A.J. Weir, *et al.* 1985. Peribronchiolar fibrosis in lungs of cats chronically exposed to diesel exhaust. *Lab. Invest.*, 52: 195-206.
27. Lykke, A.W.J., B.W. Stewart, P.J. O'Connell and S.M. Le Mesurier, 1979. Pulmonary responses to atmospheric pollutants. An ultrastructural study of fibrosing alveolitis evoked by petrol vapour. *Pathology*, 11: 71-80.
28. Selgrade, M.K. and M.I. Gilmour, 2010. Suppression of pulmonary host defenses and enhanced susceptibility to respiratory bacterial infection in mice following inhalation exposure to trichloroethylene and chloroform. *J. Immunotoxicol.*, 7(4): 350-6.
29. Pariselli, F., M.G. Sacco and D. Rembges, 2009. An optimized method for in vitro exposure of human derived lung cells to volatile chemicals. *Exp. Toxicol. Pathol.*, 61(1): 33-9.
30. Qiao, Y., B. Li, G. Yang, H. Yao, J. Yang, D. Liu, Y. Yan, T. Sigsgaard and X. Yang, 2009. Irritant and adjuvant effects of gaseous formaldehyde on the ovalbumin-induced hyperresponsiveness and inflammation in a rat model. *Inhal. Toxicol.*, 21(14): 1200-7.
31. Persoz, C., S. Achard, C. Leleu, I. Momas and N. Seta, 2010. An *in vitro* model to evaluate the inflammatory response after gaseous formaldehyde exposure of lung epithelial cells. *Toxicol. Lett.*, 195(2-3): 99-105.
32. Yura, A., M. Iki and T. Shimizu, 2005. Indoor air pollution in newly built or renovated elementary schools and its effects on health in children. *Nihon Koshu Eisei Zasshi*, 52(8): 715-26.
33. Arts, J.H., H. Muijser, C.F. Kuper and R.A. Woutersen, 2008. Setting an indoor air exposure limit for formaldehyde: factors of concern. *Regul. Toxicol. Pharmacol.*, 52(2): 189-94.
34. Wittczak, T., J. Walusiak and C. Pałczyński, 2001. Sick building syndrome. A new problem of occupational medicine. *Med. Pr.* 52(5): 369-73.
35. Abdel-Razik, A.F., I.E. Abdelsamid, M.I. Nasser, S.M. Elkousy and H. Hamdy, 2009. Chemical Constituents and Hepatoprotective activity of *Juncus subulatus*. *Rev. Latinoamer. Quim.*, 37(1): 32-46.
36. Xiao, J.Q. and S.M. Levin, 2000. The Diagnosis and Management of Solvent-Related Disorders. *American Journal of Industrial Medicine*, 37: 44-61.
37. Nunes de Paiva, M.J. and M.E. Pereira Bastos de Siqueira, 2005. Increased serum bile acids as a possible biomarker of hepatotoxicity in Brazilian workers exposed to solvents in car repainting shops. *Biomarkers*, 10(6): 456-63.
38. El-Hady, H.M., F. Metwally, M.F. El-Gendy, S. Elserougy and M.A. Helmy, 2012. Serum bile acid as a screening tool in workers occupationally exposed to mixtures of organic solvents. *Toxicology and Industrial Health*, pp: 1-8.
39. Giannini, E.G., R. Testa and V. Savarino, 2005. Liver enzyme alteration: a guide for clinicians. *Can. Med. Assoc. J.*, 172(3): 367-379.
40. Kumar, P., A.K. Prasad, B.K. Maji, U. Mani and K.K. Dutta, 2001. Hepatotoxic alterations induced by inhalation of trichloroethylene (TCE) in rats. *Biomed Environ Sci.*, 14(4): 325-32.
41. Soni, M.G., R.S. Mangipudy, M.M. Mumtaz and H.M. Mehendale, 1998. Tissue repair response as a function of dose during trichloroethylene hepatotoxicity. *Toxicol. Sci.*, 42(2): 158-65.
42. Luo, J.C., H.W. Kuo, T.J. Cheng and M.J. Chang, 2001. Abnormal liver function associated with occupational exposure to dimethylformamide and hepatitis B virus. *Occup. Environ. Med.*, 43(5): 474-82.
43. Guzelian, P., S. Mills and H.J. Fallon HJ. 1988. Liver structure and function in print workers exposed to toluene. *J. Occup. Med.*, 30(10): 791-6.

44. Rees, D., N. Soderlund, R. Cronje, E. Song, D Kielkowski and J. Myers, 1993. Solvent exposure, alcohol consumption and liver injury in workers manufacturing paint. *Scand. J. Work Environ Health*, 19(4): 236-44.
45. Bruckner, J.V., G.M. Kyle, R. Luthra, D. Acosta, S.M. Mehta, S. Sethuraman and S. Muralidhara, 2001. Acute, short-term, and subchronic oral toxicity of 1,1,1-trichloroethane in rats. *Toxicol. Sci.*, 60(2): 363-72.
46. Schwetz, B.A., B.K.J. Leong and P.J. Gehring, 1974. Embryo and fetotoxicity of inhaled carbon tetrachloride, 1, 1-dichloroethane and methyl ethyl ketone in rats. *Toxicol. Appl. Pharmacol.*, 28: 452-464.
47. Evans, E.B. and R.L. Balster, 1991. CNS depressant effects of volatile organic solvents. *Neurosci. Biobehav. Rev.*, 15: 233-241.
48. Muralidhara, S., R. Ramanathan, S.M. Mehta, L.H. Lash, D. Acosta, J.V. Bruckner, 2001. Acute, subacute and subchronic oral toxicity studies of 1,1-dichloroethane in rats: application to risk evaluation. *Toxicol. Sci.*, 64(1): 135-45.
49. Besenhofer, L.M., P.A. Adegboyega, M. Bartels, M.J. Filary, A.W. Perala, M.C. McLaren and K.E. McMartin, 2010. Inhibition of metabolism of diethylene glycol prevents target organ toxicity in rats. *Toxicol. Sci.*, 117(1): 25-35.
50. Jakubowski, M., 2005. Influence of occupational exposure to organic solvents on kidney function. *Int. J. Occup Med. Environ. Health*, 18(1): 5-14.
51. Stengel, B., S. Cenee, J.C. Limasset, J.C. Protois, A. Marcelli, P. Brochard and D. Hemon, 1995. Organic solvent exposure may increase the risk of glomerular nephropathies with chronic renal failure. *Int. J. Epidemiol.*, 24: 427-434.
52. Khan, S. and A.N.K. Yusufi, 2009. Effect of trichloroethylene (TCE) toxicity on the enzymes of carbohydrate metabolism, brush border membrane and oxidative stress in kidney and other rat tissues. *Food and Chemical Toxicology*, 47(7): 1562-1568.
53. Voss, J.U., M. Roller, E. Brinkmann and I. Mangelsdorf, 2005. Nephrotoxicity of organic solvents: biomarkers for early detection. *Int. Arch. Occup. Environ. Health*, 78(6): 475-85.
54. Hegazy, I.S., H. El-Raghi, A.M. Mahmmmed, S.A. Rizk, N.A. Badawy and H.M. Rashad, 2013. Studying the impact of organic solvents on kidney function in occupationally exposed workers. *J. Applied Sciences Research*, 9(4): 3233-3243.
55. Uzma, N., B.M.K.M. Salar, B.S. Kumar, N. Aziz, M.A. David and V.D. Reddy, 2008. Impact of organic solvents and environmental pollutants on the physiological function in petrol fill in workers. *International Journal of Environmental Research and Public Health*, 5: 139-146.
56. Saad-Hussein, A., A. H. Hamdy, H.M. Aziz and H.M. Abdallah, 2010. Thyroid functions in paints production workers and the mechanism of oxidative-antioxidants status. *Toxicol. Ind. Health*, 27(3): 257-63.