

# LEG ULCER FOR 39 YEARS

ULCUS CRURIS

After open multifragmentary fracture With infection as well as Osteomyelitis

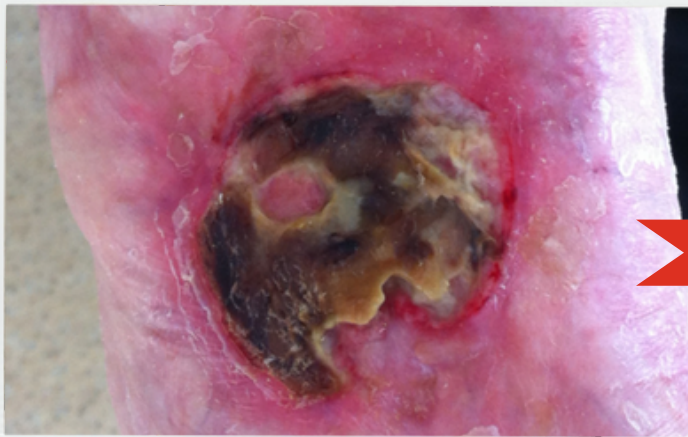
Leg ulcer since 1974 !!!!

Diameter: 10 cm

Age: 63 years

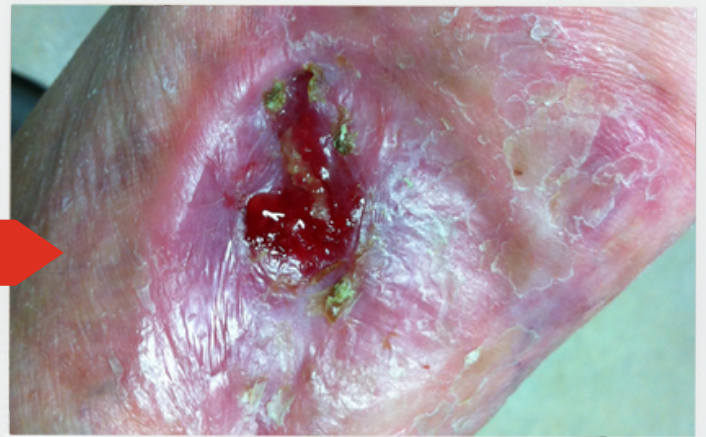
Therapy duration: 5 months

Modalities: 3 times a week for 20 min



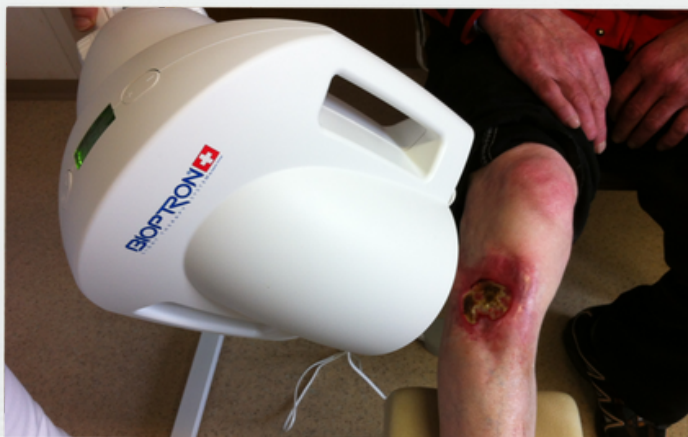**BIOPTRON**   
HYPERLIGHT THERAPY SYSTEM by Zeltex Group

March 2013

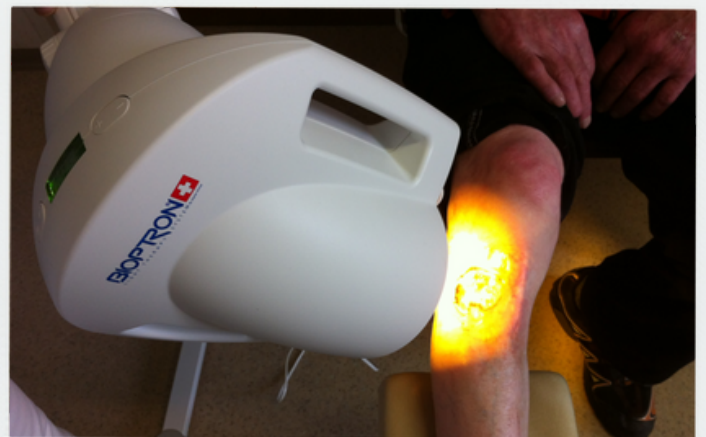

**BIOPTRON**   
HYPERLIGHT THERAPY SYSTEM by Zeltex Group

July 2013

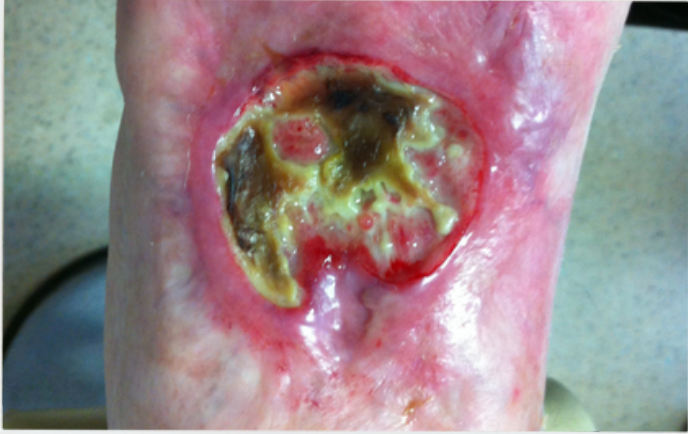

**BIOPTRON**   
HYPERLIGHT THERAPY SYSTEM by Zeltex Group

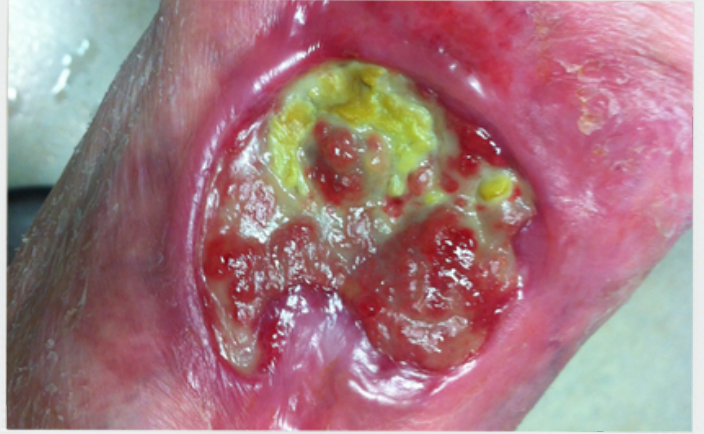

**BIOPTRON**   
HYPERLIGHT THERAPY SYSTEM by Zeltex Group

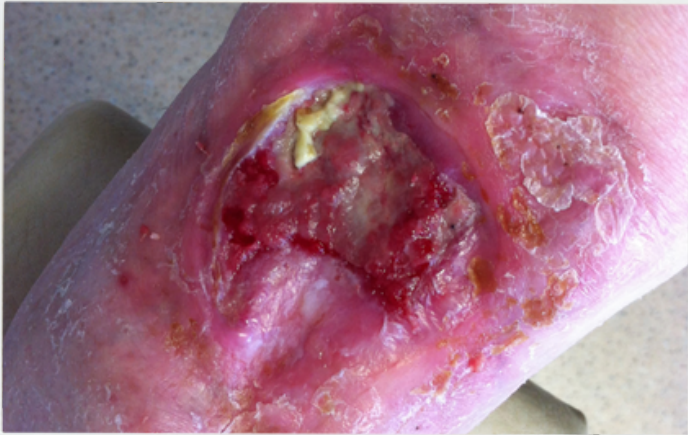




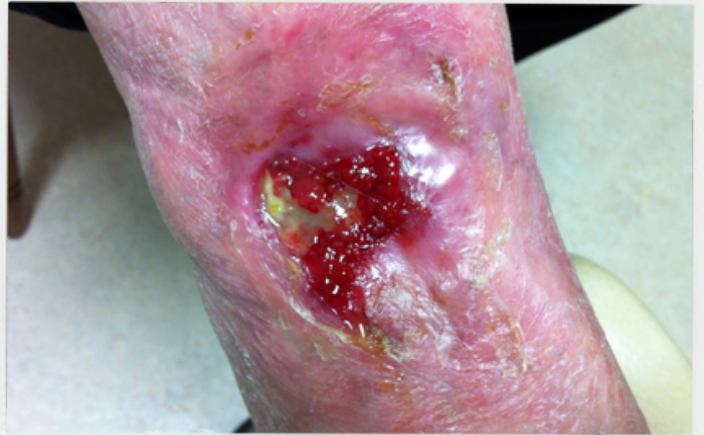**BIOPTRON**   
HYPERLIGHT THERAPY SYSTEM by Zeltex Group



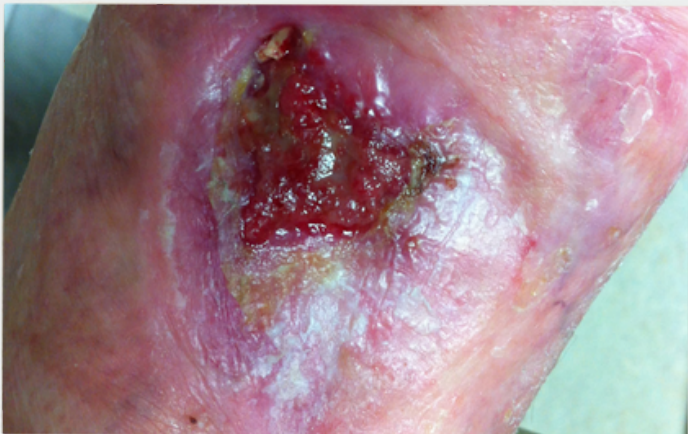
**BIOPTRON**   
HYPERLIGHT THERAPY SYSTEM by Zeltex Group



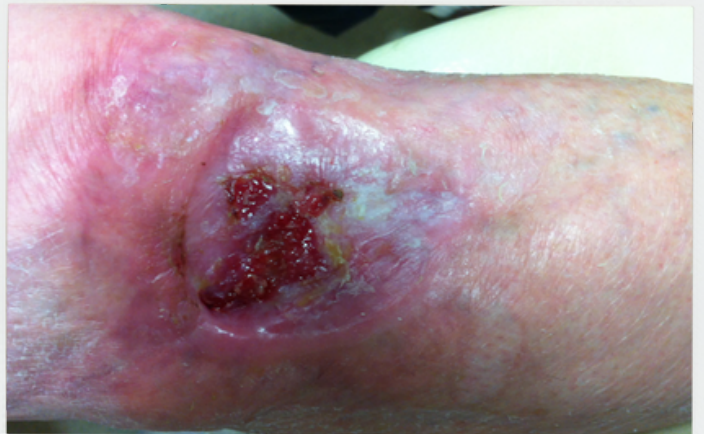**BIOPTRON**   
HYPERLIGHT THERAPY SYSTEM by Zeltex Group



**BIOPTRON**   
HYPERLIGHT THERAPY SYSTEM by Zeltex Group



**BIOPTRON**   
HYPERLIGHT THERAPY SYSTEM by Zeltex Group



**BIOPTRON**   
HYPERLIGHT THERAPY SYSTEM by Zeltex Group