

Addressing Lid Margin Disease

Getting to the crux of the problem with Cliradex®



By Neda Shamie, MD

Ocular surface disease is a complicated, multifaceted entity that often goes hand in hand with lid margin disease. Determining the root cause or causes in any given patient can be challenging. When treatment isn't on target from the start, patients suffer with their symptoms for longer than is perhaps necessary.

One way to get them on the road to ocular health sooner rather than later is to always include Demodex in the differential diagnosis when meibomian gland disease (MGD), rosacea, and/or ocular surface inflammation is noted.

Demodex is an ectoparasite that resides on skin, often harmlessly. However, when these microscopic mites multiply out of control, they are associated with many conditions, including blepharitis, rosacea, MGD, chalazia, and ocular surface inflammation¹ (Figure 1). They can transfer bacteria around the skin and ocular surface as well.

A Surprising Discovery

An experience I had with one of my

patients solidified, in my mind, the importance of diagnosing Demodex. The gentleman had undergone multiple corneal transplants and had come to me for a keratoprosthesis. He had severe rosacea, which we wanted to treat prior to surgery, but none of the typical treatments, such as oral doxycycline or mild topical steroid, were working. He went on to have a perforated cornea that subsequently required three emergency tectonic grafts.

It was clear that we simply were not addressing the root cause of his severe ocular surface inflammation despite our varied and aggressive treatment protocols. I knew I was missing the diagnosis and, thankfully, had heard about Demodex as a possible culprit in rosacea refractory to our typical treatment regimens.

I epilated two of the very few lashes still remaining on his inflamed and thickened lid margin and examined them under the microscope. I nearly jumped out of my seat at the sight of a family of mites wrapped around the lash as well as the one swimming away.

I treated him with tea tree oil, and for the first time in years his ocular surface was comfortable, less inflamed, and, best of all, his cornea stopped melting and remained stable. We were able to proceed with the keratoprosthesis surgery with great success, and 5 years later, he is stable and with an excellent long-term outcome.

I've treated many patients for Demodex since then, and it's easier now because of Cliradex, the lid-, lash-, and face-cleansing towelettes that

are a potent killer of these mites.

Cliradex contains 4-Terpineol, which is the most effective component of tea tree oil in eradicating Demodex, more effective than tea tree oil itself.² It's also less toxic, more comfortable, and more convenient for patients than tea tree oil.²

Tell-tale Signs

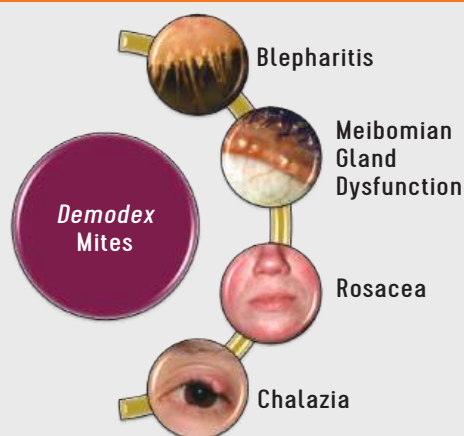
There are several tell-tale signs of Demodex: waxy collarettes around the base of the lashes, greasy scales on the lashes and lids, thickened meibum, hair loss in the lashes or eyebrows, and cutaneous pustules around the eyes. Demodex is more prevalent with age, but I've seen patients in their 20s have it, too.

The mites have a lengthy life cycle and some tend to hide deep in the meibomian glands, so I instruct patients to use Cliradex two to three times a day for at least 2 to 4 weeks. In some cases, the best results take 6 to 8 weeks to reach, and consistent use of the wipes is crucial. Patients seem to understand the need for this and are motivated to do it, sometimes even after their symptoms have resolved.

Seeing how effective Cliradex is against Demodex, I strongly recommend that it be used as a first-line treatment in any case where Demodex is suspected, either alone or in conjunction with therapies that target other aspects of the patient's condition. ■

Dr. Shamie is a corneal, cataract, and refractive surgery specialist at Advanced Vision Care in Los Angeles.

FIGURE 1



Demodex mites are linked to many lid margin and ocular surface diseases.

References

1. Cheng AMS et al. *Curr Opin Ophthalmol.* 2015;26(4):295-300.
2. Tighe S et al. *Transl Vis Sci Technol.* 2013;2(7):2.