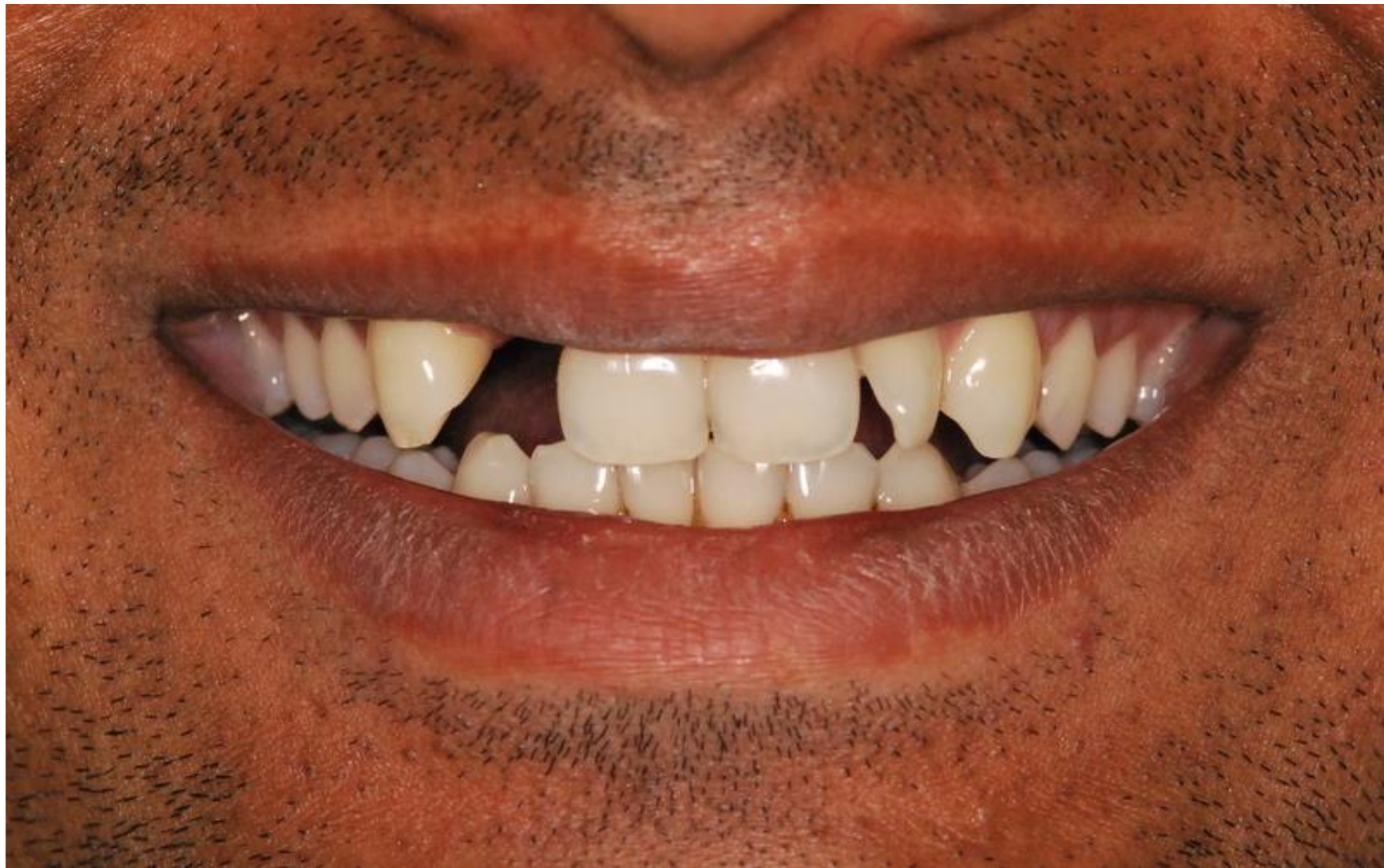
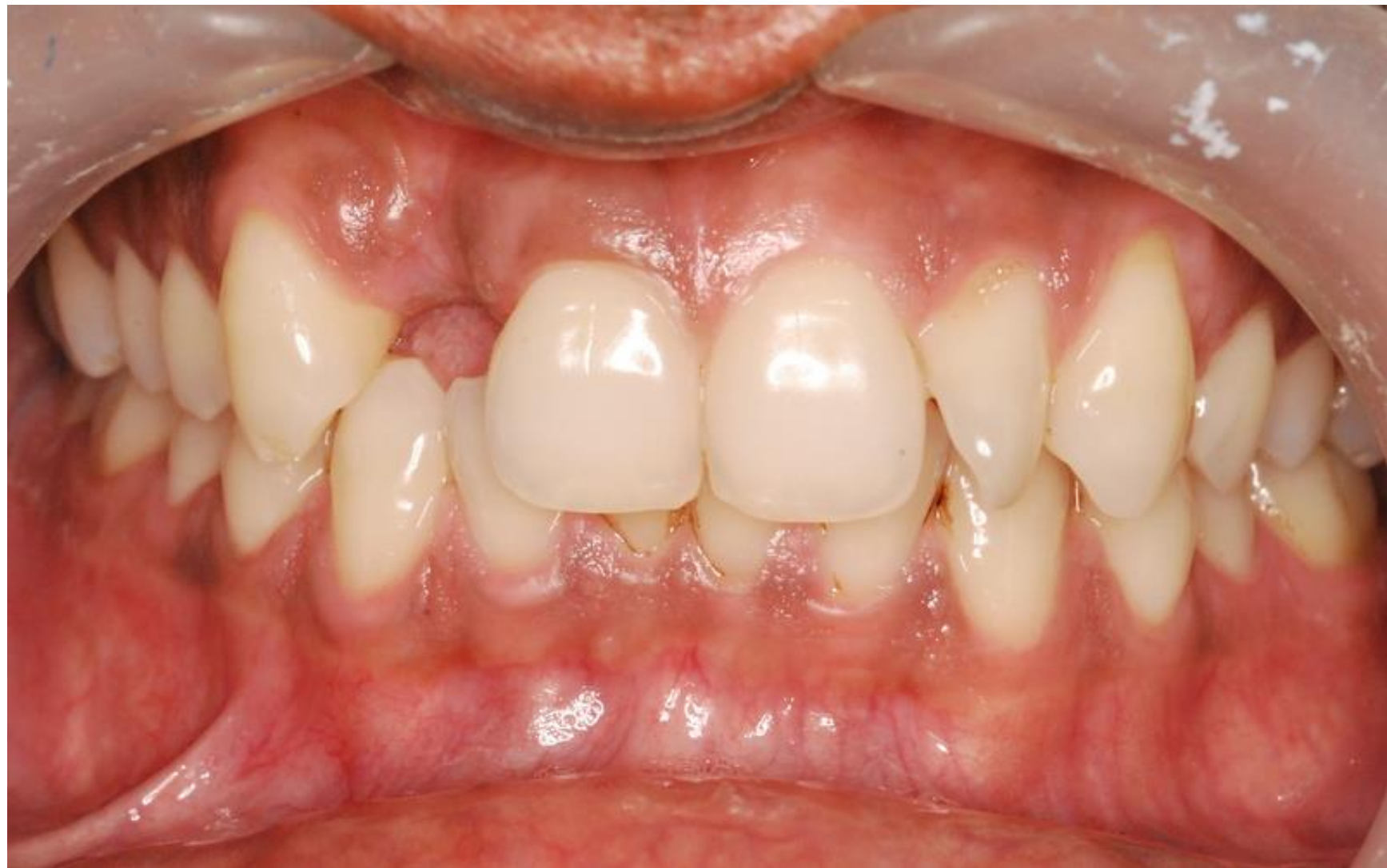
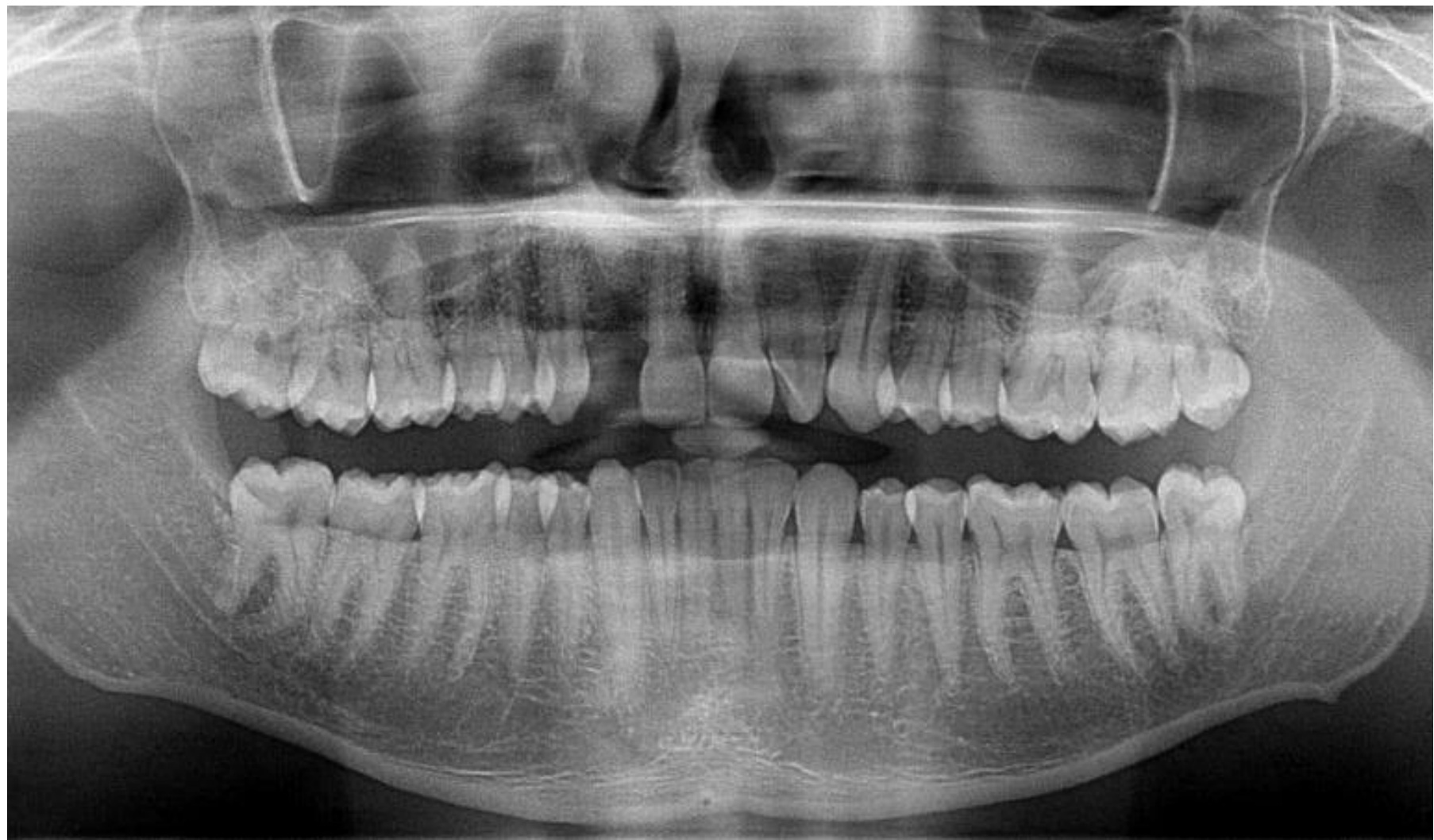Single Implant Case: Missing Lateral Incisor

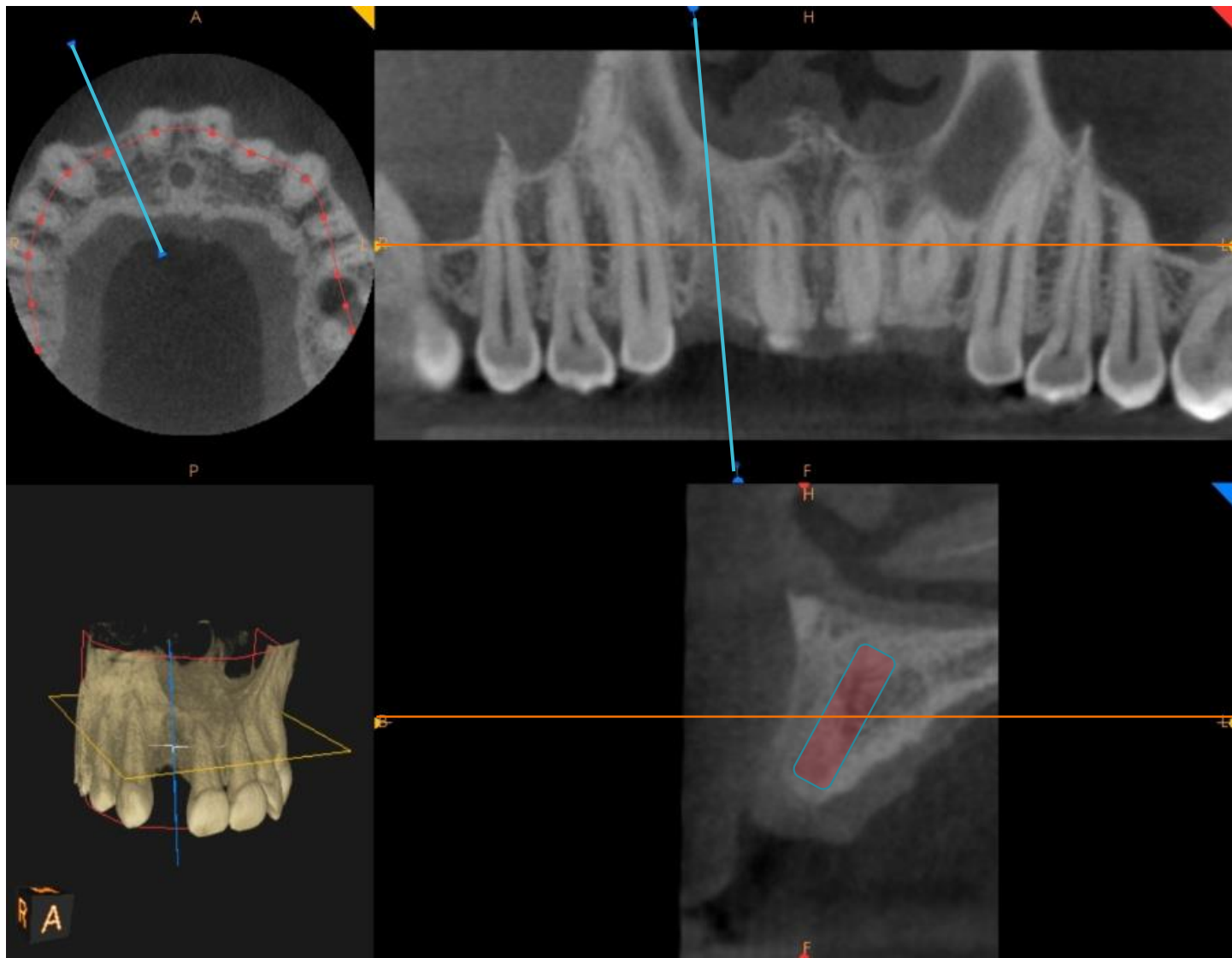
Case by : Dr. Nakul Rathi

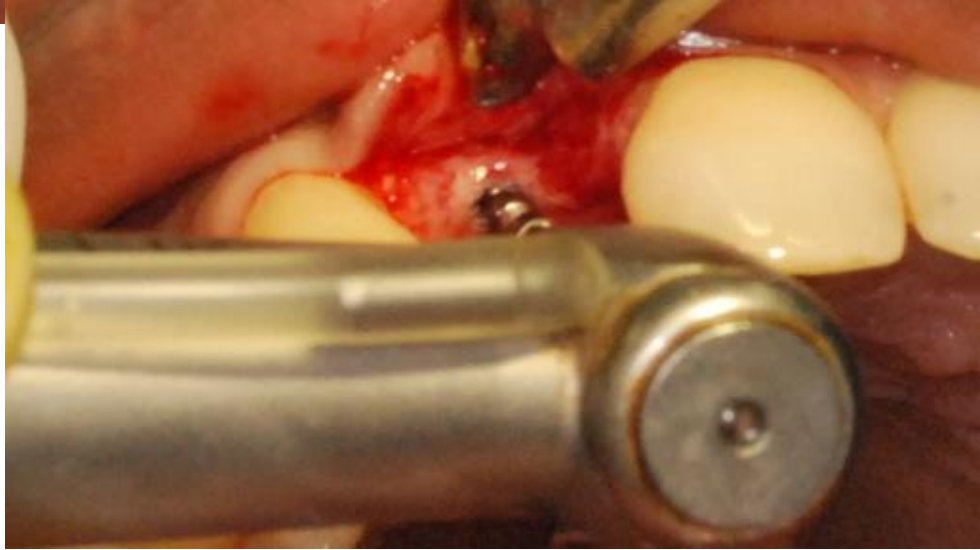
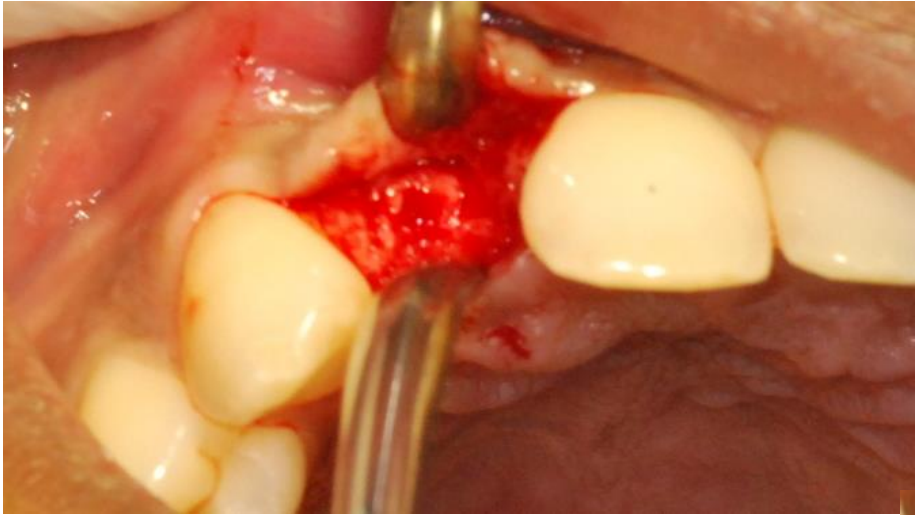
Lab Credits: Ms. Neelu Thapa

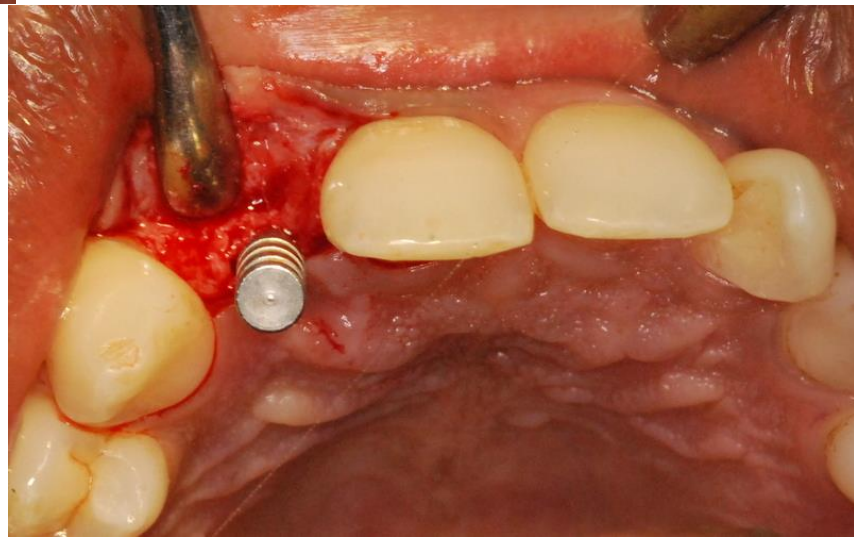
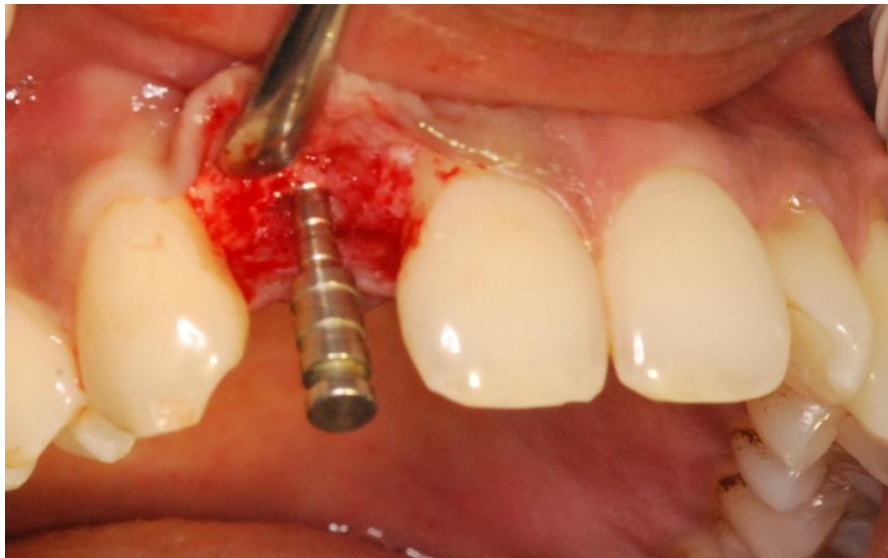

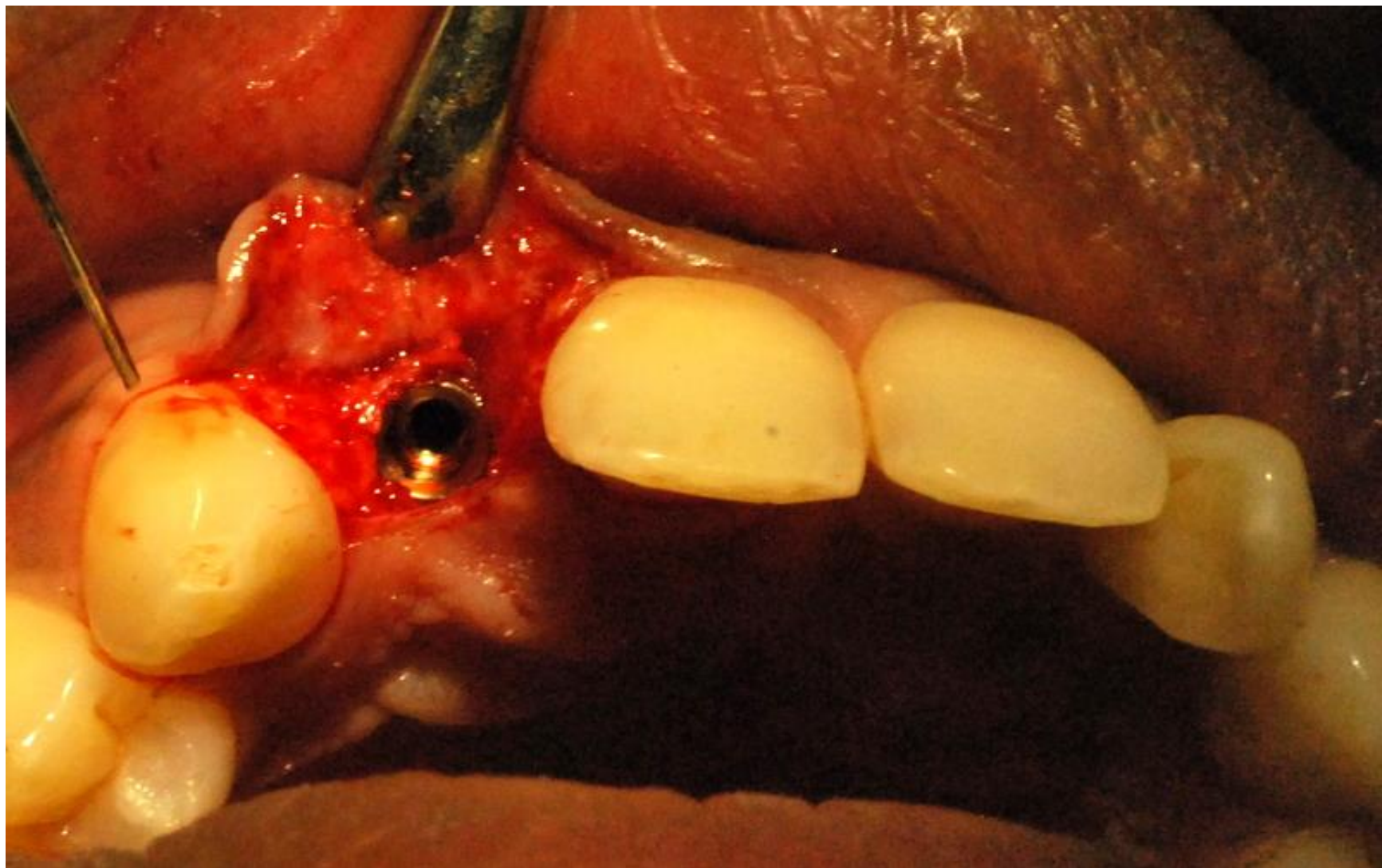



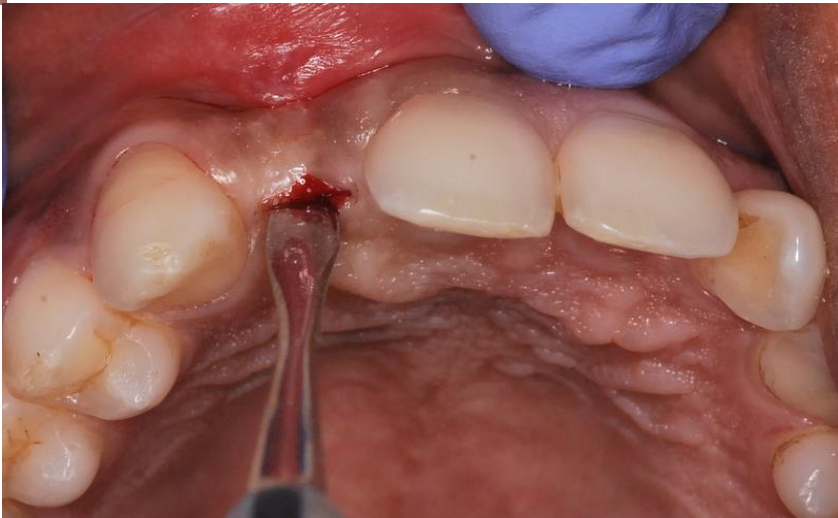
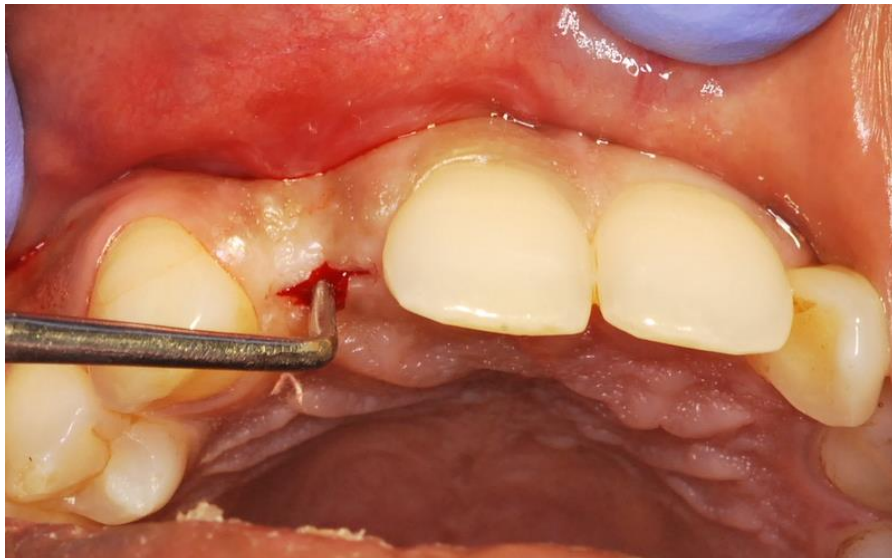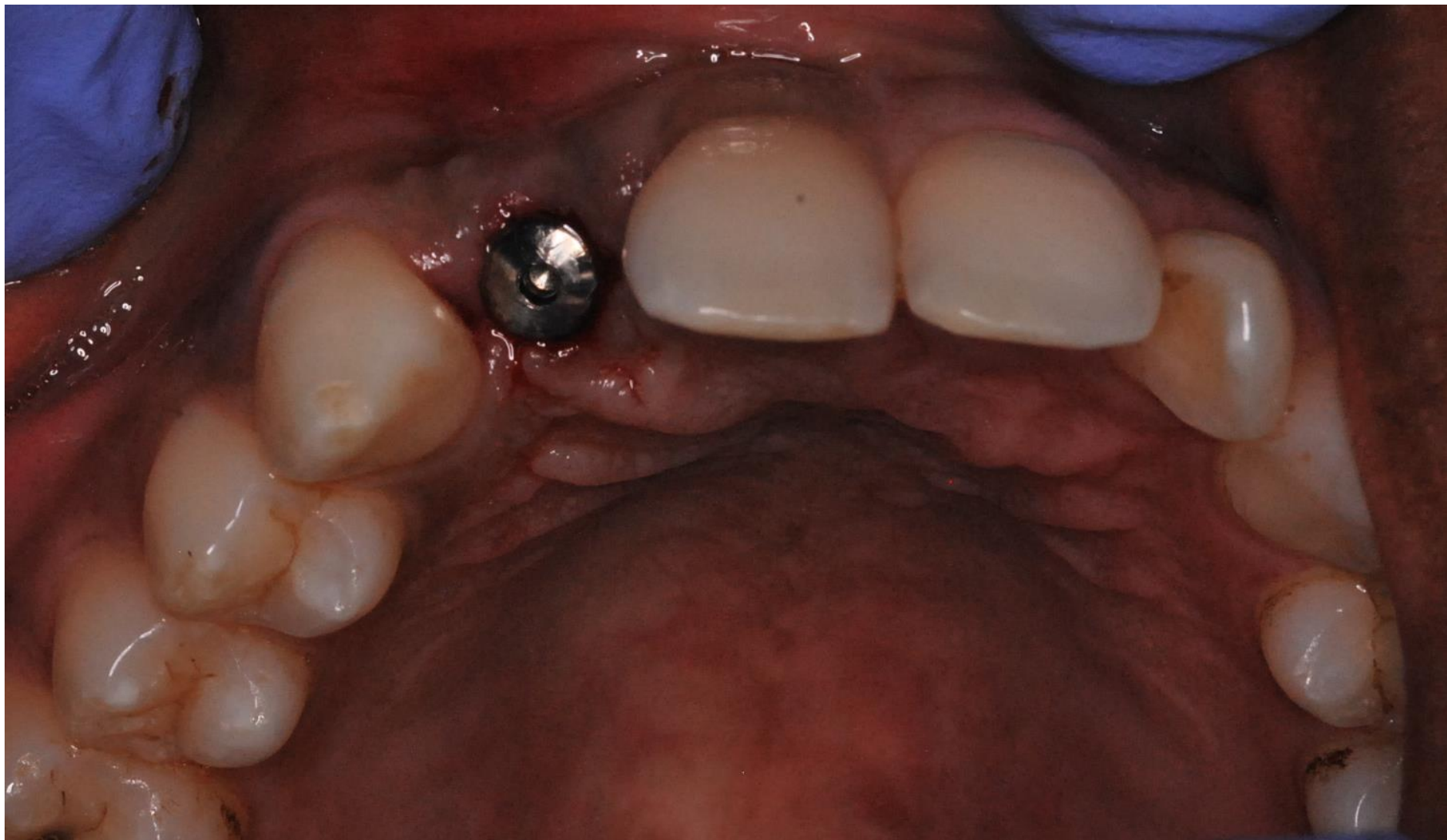


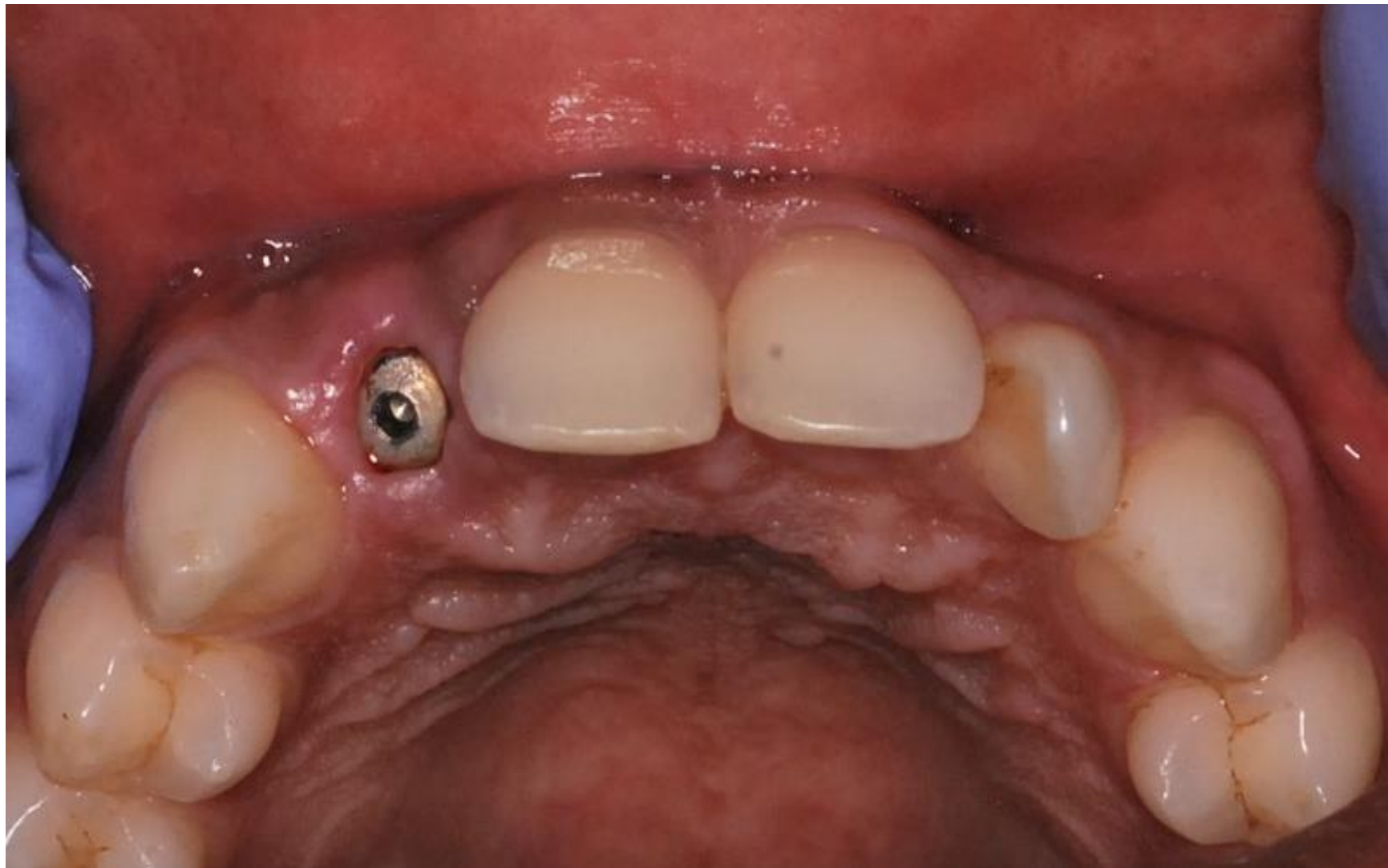












Closed Tray Impression

