Indications

PolyMem is indicated for a wide variety of full and partial thickness wounds including, but not limited to:

Acute wounds	Chronic wounds	Specialist wounds
• Abrasions • Bruising • First / second-degree burns • Skin tears • Surgical wounds • Trauma wounds	• Diabetic foot ulcers • Fungating wounds • Leg ulcers • Pressure ulcers (stages I-IV)	• Dermatological disorders (e.g. epidermolysis bullosa) • Donor and graft sites • Exposed tendons • Radiotherapy-induced skin damage

For infected wounds use PolyMem Silver

PolyMem dressing selection guide

Wound phase and Exudate level	Dry ◊◊◊◊	Low ♦◊◊◊	Moderate ♦♦◊◊	High ♦♦♦◊	Excessive ♦♦♦♦
Non-infected	PolyMem				
		For initial days of PolyMem usage	PolyMem MAX		
				PolyMem WIC + PolyMem MAX	
Critically colonised, infected, or infection risk**	PolyMem Silver				
				PolyMem Silver WIC	
Cavity and undermining	PolyMem WIC (non-infected)				
	PolyMem Silver WIC (critically colonised, infected and at risk)				

† For dry or non-exuding wounds, moisten the dressing or wound slightly with saline or water prior to application. This will help to activate the dressing component.

** PolyMem Silver dressings are suitable to use when visible signs of infection are present.

Proper medical treatment should be used to address the underlying cause of the infection.

References

1. Denyer J, Agathangelou C, White R, Ousey K, HariKrishna R et al (2015) PolyMem Made Easy. *Wounds International*. Available at https://www.woundsinternational.com/resources/details/polymem-dressings-made-easy. 2. Beitz AJ, Newman A, Kahn AR et al (2004) A polymeric membrane dressing with antinociceptive properties: analysis with a rodent model of stab wound secondary hyperalgesia. *J Pain* 5(1): 38–47. 3. Cutting KF, Vowden P, and Wiegand C (2015) Wound inflammation and the role of a multifunctional polymeric dressing. *Wounds International* 6(2): 41–6. 4. Benskin LL (2016) Polymeric membrane dressings for topical wound management of patients with infected wounds in a challenging environment: A protocol with 3 case examples. *Ostomy Wound Manage* 62(5): 42–50. 5. Kahn AR (2000) A superficial cutaneous dressing inhibits inflammation and swelling in deep tissues. *Pain Med* 1(2): 187.

Ordering Details:

PolyMem Non-Adhesive

Size	Pieces per box	Product code	PIP code	NHS code
8cm x 8cm	15	5033	326-9511	ELA301
10cm x 10cm	15	5044	326-9503	ELA303
13cm x 13cm	15	5055	326-9552	ELA305
17cm x 19cm	15	5077	326-9529	ELA306
10cm x 61cm Roll	4	5244	326-9545	ELA321
20cm x 60cm Roll	2	5824	363-2510	ELA407

PolyMem Adhesive

Size	Pieces per box	Product code	PIP code	NHS code
5cm x 5cm	20	203	326-8588	ELA297
8.9cm x 11.4cm	15	405	415-2070	ELA298
Oval #3 (5cm x 7.6cm)	20	8023	326-8646	ELA1156
Oval #5 (8.8cm x 12.7cm)	15	8053	326-8653	ELA313
Oval #8 (16.5cm x 20.9cm)	10	8086	326-8661	ELA1157
Sacral (18.4cm x 20cm)	10	3709	326-8711	ELA1158

PolyMem Finger/Toe

Size	Pieces per box	Product code	PIP code	NHS code
Size 1 (UK ring size H-Q)	6	4401	371-7915	ELA1159
Size 2 (UK ring size Q-Y)	6	4402	371-7931	ELA1160
Size 3 (UK ring size Y-Z+7)	6	4403	371-7923	ELA1161
Size 4	6	4404	386-4790	ELA1151
Size 5	6	4405	386-4808	ELA1162

PolyMem Max Non-Adhesive

Size	Pieces per box	Product code	PIP code	NHS code
11cm x 11cm	10	5045	326-8729	ELA1150
20cm x 20cm	5	5088	363-2502	ELA1149

PolyMem Max Adhesive

Size	Pieces per box	Product code	PIP code	NHS code
13.3cm x 13.3cm	15	606	415-2062	ELA1153

PolyMem Silver Non-Adhesive

Size	Pieces per box	Product code	PIP code	NHS code
10.8cm x 10.8cm	15	1044	328-5103	ELA1154
17cm x 19cm	15	1077	334-3035	ELA319

PolyMem Silver Adhesive

Size	Pieces per box	Product code	PIP code	NHS code
Oval #3 (5cm x 7.6cm)	20	1823	336-6242	ELA1163
Oval #5 (8.8cm x 12.7cm)	15	1853	336-6234	ELA1164

PolyMem Tube

Size	Pieces per box	Product code	PIP code	NHS code
7cm x 7cm	15	5333	363-2494	ELA1147
9cm x 9cm	15	5335	363-2478	ELA1148

PolyMem Silver WIC

Size	Pieces per box	Product code	PIP code	NHS code
8cm x 8cm	10	1333	346-7982	ELA1155

PolyMem WIC

Size	Pieces per box	Product code	PIP code	NHS code
8cm x 8cm	10	5733	346-7990	ELA1152

www.hrhealthcare.co.uk

h&r healthcare
delivering innovation

H&R Healthcare Ltd.
3 Redcliff Road, Melton Park, Melton, Hull HU14 3RS
T: +44 (0)1482 631606 E: customerservices@hrhealthcare.co.uk

POL005-2

PolyMem®

POLYMERIC MEMBRANE DRESSING
MODULATES INFLAMMATORY RESPONSE

h&r healthcare
delivering innovation

PolyMem®

A unique multifunctional polymeric membrane dressing, designed to facilitate healing, relieve pain and reduce inflammation.

POLYMERIC MEMBRANE DRESSING – MODULATES INFLAMMATORY RESPONSE

PolyMem dressings are a hydrophilic polyurethane matrix dressing with a mild, non-toxic wound cleanser, a soothing moisturiser, a superabsorbent and a semi-permeable film backing.*

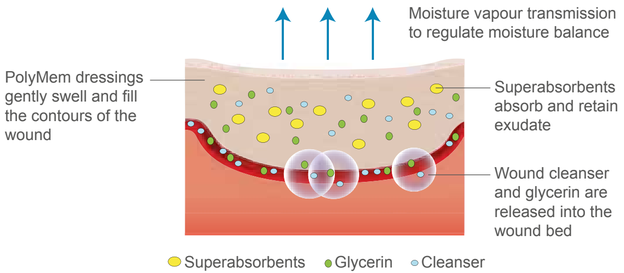

When PolyMem is applied to the wound, the dressing components work individually and synergistically to support wound healing and pain relief[1]

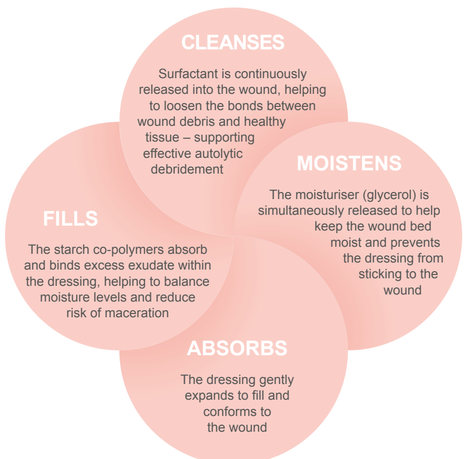

* Not included in cavity products.

Unique Polymeric Membrane benefits

Modulates inflammatory response

PolyMem manages and contains the inflammatory response at the initial wound site and reduces inflammation in the surrounding tissues.[2] The dressing has the ability to alter the actions of certain nerve endings (nociceptors).[2] This action is also effective in decreasing bruising, swelling and secondary injury by modulating the inflammatory response.[3,4]

Relieves pain

The unique combination of surfactant and glycerol contained in PolyMem not only keeps the wound clean, but it relieves soreness and reduces pain too. PolyMem is proven to provide an analgesic effect.[2,5]

Simplified dressing choice

Due to its multifunctional properties, PolyMem can replace dressings such as:

- Polyurethane or silicone foams
- Hydrocolloids
- Hydrogels
- Transparent films
- Alginates
- Traditional dressings

Protects from contamination

The semi-permeable polyurethane film backing helps prevent contaminants from entering the dressing or wound bed.

Multiple configurations

PolyMem comes in a variety of shapes and sizes to accommodate all kinds of patients and wounds while promoting comfort.



Cavity wound filler *Max* *Pink finger* *Roll* *Shapes* *Tube dressing*

Available in Silver

Made from small particle elemental, metallic silver - the dressing delivers all of the benefits of PolyMem, with the added antimicrobial effects - without releasing silver into the wound bed. An ideal choice for infected wounds.

Sliver

Clinical evidence

Case study 1 – Skin graft donor site

Day 1

Donor site immediately after harvesting the split skin graft. Local anesthesia used to minimise the bleeding.

The wound is immediately covered with PolyMem Max and secured with adhesive film.

Day 2

First dressing change. The dressing came off easily without causing any pain to the patient. No wound cleansing required.

Epithelialised skin graft donor site. The wound required only two dressing changes and one week to close. The patient was pain free the whole time.

Case study 2 – Crush injury

A middle-aged woman suffered a large wound when a concrete stone fell, crushing her right foot. Several weeks of treatment with local herbal poultices failed to produce any healing or halt the increasing infection. She arrived at the clinic with an avascular, eschar and slough filled, heavy-exudating, full-thickness wound, plus acute malaria. The patient's wound pain was constant and severe.

2 Oct:
7cm x 7cm x 0.3cm

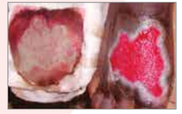

17 Oct:
6.7cm x 5.8cm
The wound is filling in quickly

17 Nov:
1.3cm x 2cm
The wound is filling in

After 9 weeks of treatment the wound healed

Results: Pain was greatly reduced and the wound infection resolved within a week. The wound moisture reduced and granulation tissue formed quickly. The wound closed and the patient was able to return to her home after 9 weeks.

Case study 3 – Venous hypertension ulcers

An 80-year-old woman with a deep, stalled venous leg ulcer for one month. Pain 5 (on 0-10 scale). There was no improvement.

11 Sept: PolyMem initiated
2.5cm x 1.6cm x 0.1cm
Pain 5 during dressing changes
70% granulation, 30% fibrin/slough

27 Sept:
1.8cm x 1cm x 0.1cm
Pain 0 during dressing changes
100% granulation tissue
Wound size decreasing rapidly

25 Oct:
Completely healed in only 6.5 weeks, despite the patients' advanced age, diabetes and habitual use of caffeine and nicotine

Results: After one week of PolyMem use, new granulation tissue was forming. The patient quickly became pain-free. After 6.5 weeks, the wound had healed.