

A next generation foam

AQUACEL® Foam Dressing

conformable
protect adaptability
absorption gentle
control exudate
quality of life
moisture adhesive
skin wear time
periwound removal
healing protection
comfort



PUBLISHED BY:

Wounds UK
Enterprise House
1-2 Hatfields
London SE1 9PG, UK
Tel: + 44 (0)20 7627 1510
Fax: +44 (0)20 7627 1570
www.wounds-uk.com

Wounds UK

© **Wounds UK 2012**

This document has been developed by Wounds UK and supported by an unrestricted educational grant from **ConvaTec UK**



ConvaTec

The views expressed are those of the authors and do not necessarily reflect those of ConvaTec

How to cite this document:

*A next generation foam:
AQUACEL® Foam Dressing.*
London: Wounds UK, 2012
8(4). Supplement. Available to
download from:
www.wounds-uk.com

NEXT GENERATION FOAM TECHNOLOGY

Authors:

Steven Bishop, Helen Shaw,
ConvaTec R&D, Global
Development Centre, Deeside,
UK

Pauline Beldon, Tissue Viability
Nurse Consultant, Epsom & St
Helier University Hospitals NHS
Trust, Sutton, Surrey

ROLE OF FOAM DRESSINGS

Foam dressings have been commercially available for over 30 years for the management of exuding wounds. However, the composition and mode of action of different foam dressings varies (Sussman, 2010), with different products claiming different methods of absorption and physical performance characteristics (Thomas, 2010).

Developments in foam dressing technology have focused on:


- increasing dressing moisture vapour transmission rate and absorbency to provide higher fluid handling capacities
- improving foam dressing adhesive characteristics, primarily by moving from acrylic based adhesives to atraumatic silicone based adhesives.

More recently, there has been significant debate regarding the use of foam dressings in clinical practice and there is still considerable confusion about their role and value in wound management (White et al, 2012). With a range of alternative dressings now available to clinicians, some may argue that we can manage wounds effectively without foam dressings, while others state that a foam dressing should always be included in formularies as they can manage exudate effectively when used appropriately (White et al, 2012). However, there is often a lack of high-quality evidence to support decision making and strategies are needed to support and educate nurses in measuring clinical outcomes and monitoring spend to help assess the effectiveness of foam dressings (White et al, 2012).

This debate, coupled with the identified potential to further enhance the performance capabilities of foam dressings, has driven the development of a new foam dressing incorporating Hydrofiber® Technology aimed at extending the use of foam dressings across a wide range of wound types.

INTRODUCING A NEW FOAM TECHNOLOGY

The new AQUACEL® Foam dressing comprises a protective top layer, an upper polyurethane absorbent foam pad and an integral Hydrofiber® wound contact layer with a silicone adhesive border:



Designing a dressing to manage exuding wounds

This new foam dressing design has been shown to have the following attributes:

- High fluid absorption, effective fluid retention and high fluid handling capacity (Pritchard et al, 2012)
- Effective moisture balance through a moisture retentive wound contact surface coupled with a high moisture vapour transmission rate (Bishop et al, 2003)
- Minimised lateral fluid spread onto surrounding skin aimed at protecting periwound skin from maceration (Bishop et al, 2003; Robinson, 2000)
- A low friction coefficient outer surface and foam core to provide protection to the underlying skin and wound tissue (Data on file, 2012)
- Gentle and atraumatic, sustained skin adhesion (Data on file, 2012).

The gelling Hydrofiber® wound contact layer provides a moist wound environment with no adhesive barrier between the Hydrofiber® and the wound surface. This is designed to provide an intimate contact with the entire wound surface (Pritchard et al, 2012; Robinson, 2000). This gelling wound interface is also designed to help soothe and reduce pain associated with the wound (Armstrong et al, 1995; Barnea et al, 2004; Caruso et al, 2006).

A specific hydrophilic polyurethane foam material was selected to match the hydrophilic nature of the Hydrofiber® wound contact layer and to ensure one-way fluid transmission from the gelled wound contact layer, up into the foam layer and then up to the polyurethane film surface for moisture vapour transmission.

What is Hydrofiber® Technology?

Hydrofiber® Technology is a patented technology in which fibres of high-quality cellulose are carboxymethylated, altering its structure to allow better absorbency and retention of fluid. These fibres are then processed to mesh them together to form a stable fleece layer. When exposed to fluid, the fibres swell to form a clear, soft, cohesive gel structure that closely conforms to the wound bed. As the fibres swell, the fluid and its contents (eg bacteria and other inflammatory cells and enzymes) are trapped and held within the dressing. In addition, the gelling action prevents lateral spread of fluid through the dressing to reduce the risk of maceration and promote a moist wound healing environment (Queen et al, 2011).

To improve the acceptability of the dressing, both clinician and patient needs were closely assessed in terms of the desired clinical performance and required cosmetic and touch/feel attributes of the dressing. Extensive work was then conducted with both in-house design teams and external design experts to ensure that the developed product best met those needs:

- Dressing colour was matched to the most preferred colour shade
- Dressing shape was designed to best fit around curved body surface contours
- Specially shaped dressings were designed for the difficult-to-dress heel and sacral areas
- Dressing feel during wear was assessed to ensure that, once the wound was covered and any wound pain had reduced, the patient would have the 'minimum sensation that they were wearing a dressing'. During these wear studies, several of the participants did forget that they were still wearing the dressing, further validating the dressing's ability to minimise pain during wear and at dressing removal (Data on file, 2012).

EVALUATING DRESSING PERFORMANCE

Laboratory studies have been conducted to measure the dressing's fluid absorbency, fluid retention, total fluid handling capacity, moisture vapour transmission rate, adhesiveness and bioadhesion (Pritchard et al, 2012; Data on file, 2012).

The AQUACEL® Foam dressing was found to be equivalent to other market-leading foam dressings in terms of total fluid handling capacity, but it was found to be superior in terms of fluid retention, control of lateral fluid spread and intimate contact with a simulated wound surface.

Bioadhesion

Bioadhesion is the *in vitro* adhesion of biological materials to a dressing. This is predictive of *in vivo* tissue adhesion to a dressing and the potential for a dressing to cause trauma to the tissue at dressing change.




Figure 1: Results of *in vitro* fluid retention comparative study

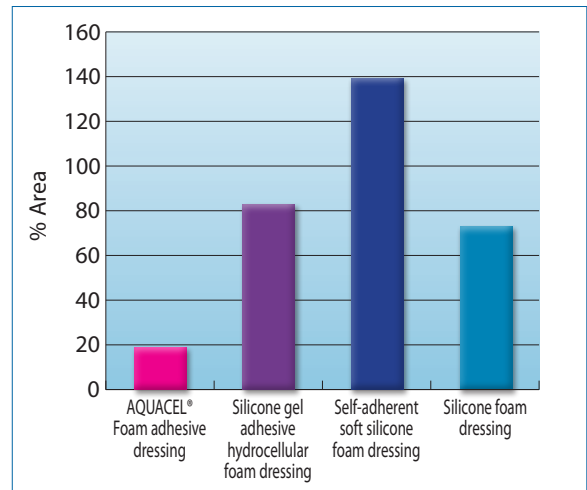


Figure 2: Results of *in vitro* lateral fluid spread comparative study

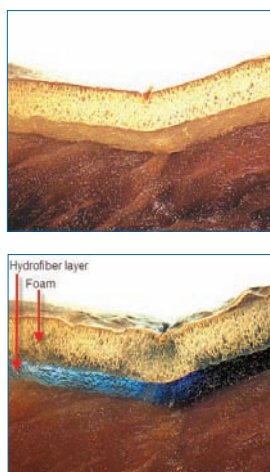


Figure 3: Pre- (top) and post-hydration (bottom) photos of AQUACEL® Foam dressing using a simulated wound tissue model (pork belly)

This means that there is no or very little dead space between the wound and the dressing where fluid may accumulate and bacteria may proliferate (Queen et al, 2011). The advanced silicone adhesive used within the AQUACEL® Foam dressing was shown *in vitro* to have a higher level of adhesiveness (predictive of dressing wear time), coupled with an atraumatic level of bioadhesion to keratinocyte cells (Data on file, 2012).

Fluid retention testing by adding 25ml of dyed physiological saline to the dressings, then applying a compression force equivalent to 40mmHg compression yielded the results shown in Figure 1 (Pritchard et al, 2012; Data on file, 2012).

Testing for the lateral spread of fluid across the wound contact layer was performed, involving the addition of 20ml of horse serum (to simulate wound exudate) to the dressing surface through an open vial (to simulate the wound area) for 60 seconds, followed by removal of any non-absorbed fluid to enable measurement of fluid spread outside the original 'wound area'. This testing gave the above results for % area spread outside of the original simulated wound area (Pritchard et al, 2012; Data on file, 2012) (Figure 2).

Intimate contact between the gelled Hydrofiber® wound contact surface and a simulated wound surface was shown *in vitro*, utilising pork belly tissue as the simulated wound surface and dyed physiological saline as the simulated exudate (Pritchard et al, 2012) (Figure 3).

Additional laboratory studies reported that (Data on file, 2012):

- The dressing retains its structural integrity after cutting, even when saturated with fluid
- The silicone adhesive border can be re-positioned and re-adhered to the skin, even after prior adhesion to surgical gloves
- The dressing acts as an effective barrier to viruses and bacteria, to assist in infection control programmes
- The dressing is waterproof, protecting the wound from incontinence episodes and allowing patients to shower and bathe
- The dressing can be left in place with no effect on Magnetic Resonance Imaging (MRI).

Dressing selection for effective exudate management

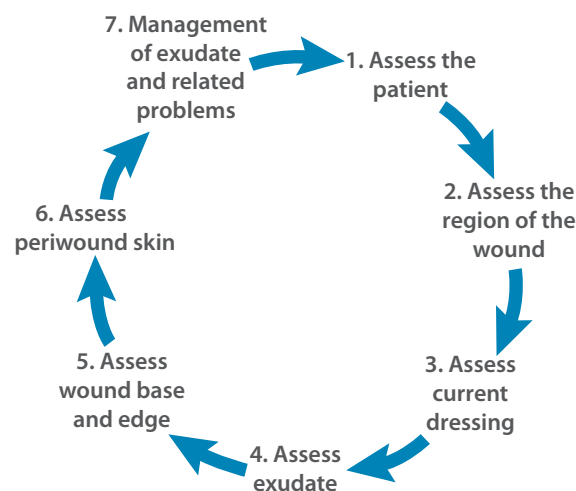
Key challenges in managing exuding wounds

- Maceration
- Wound pain
- Enlargement of the wound
- Protein loss/fluid electrolyte imbalance
- Delayed wound healing
- Local wound infection
- Soiled clothing and bedding
- Reduced quality of life

Effective exudate management can reduce time to healing, reduce exudate related problems such as periwound skin damage and infection, improve patients' quality of life, reduce dressing change frequency and clinician time, and so, overall, improve healthcare efficiency (Gardner, 2012).

A comprehensive assessment should underpin effective exudate management, and ideally should be integrated within a general wound assessment (Ousey and Cook, 2012; Figure 4). This should identify the aetiology of the wound, which may indicate the requirement to use more than a topical dressing, eg compression bandaging for a venous leg ulcer patient. The patient's nutritional and hydration status also need to be considered, since a heavily exuding wound affects the fluid balance and nutritional status, increasing demands for both food and fluids (Johnstone, 2007). In addition, an inappropriately managed exuding wound can lead to distress due to painful, macerated skin and wet clothing and resulting in disappointment and loss of faith by the patient, affecting the relationship between the patient and his/her healthcare professional (Anderson, 2012). Consequently it is vital that an appropriate wound dressing is selected that meets the individual patient's needs in exudate management as part of their wound management plan.

Figure 4: Integrated exudate assessment: Assess exudate in the context of the patient's medical and surgical history, wound history, environment and psychosocial status (from Romanelli et al, 2010)



Clinicians must consider whether a foam dressing is fit for purpose, in other words does it satisfy the selection criteria for exudate management.

Criteria for foam dressing selection, include:

- Remains *in situ* and intact throughout wear time
- Is comfortable, conformable and flexible
- Does not cause allergy or sensitivity
- Retains exudate when used in conjunction with another therapy, such as compression bandaging
- Is capable of sequestration of bacteria and other exudate components
- Remains *in situ* for long periods without leakage
- Is easy to apply and remove, without causing skin trauma/discomfort (WUWHs, 2007)

Choosing the appropriate dressing may help to improve clinical outcomes, reduce costs and improve patient quality of life and concordance (Romanelli et al, 2010).

Clinical application of a new foam dressing

WHEN IS AQUACEL® FOAM DRESSING INDICATED?

AQUACEL® Foam is suitable for a wide range of acute and chronic wounds producing exudate, regardless of the tissue within the wound bed. It can be used alone to manage shallow wounds and for wounds of any depth used in conjunction with other primary dressings. For example, in cavity wounds AQUACEL® or AQUACEL® Extra dressings can be used to lightly fill the cavity with AQUACEL® Foam applied as a secondary cover dressing.

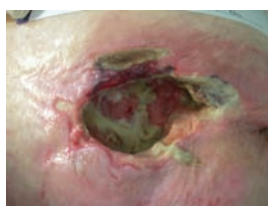

Figure 5: Sacral pressure ulcer presenting with a mixture of sloughy and clean healthy tissue and heavily exuding wound. AQUACEL® or AQUACEL® Extra™ dressings can be used to fill the cavity and AQUACEL® Foam dressing can be used as a secondary dressing to manage the exudate, allowing dressing changes on alternate days

AQUACEL® Foam dressing can be applied to wounds producing lower volumes of exudate, such as skin tears, minor lacerations and cuts and left *in situ* for a maximum wear time of seven days. In wounds such as diabetic foot ulcers, the dressing can be used under a total contact cast to enable longer wear time with a reduced risk of periwound skin maceration (Hilton, et al, 2004). Similarly AQUACEL® Foam non-adhesive dressing may be used under compression bandaging to reduce the risks of contact dermatitis. This may also allow patients to self-manage their leg ulcer under a compression hosiery kit (Beldon, 2006).

AQUACEL® Foam dressing can also be used on a wide range of acute and chronic wounds that produce moderate to high volumes of exudate, including leg ulcers, pressure ulcers, diabetic foot ulcers, burns, traumatic injuries such as pretibial lacerations, surgical wounds healing by secondary intention, donor sites and for exudate management in fungating tumours. While there is no contraindication to use on chronic, colonised wounds, the use of AQUACEL® Foam as a primary dressing on an infected wound should be directed by a specialist practitioner.

In wounds containing a mixture of tissue, such as a pressure ulcer which contains part necrotic/part granulation tissue and is undergoing autolytic debridement, AQUACEL® Foam dressing will absorb excess exudate, contain bacteria and debris, aiding removal of necrotic tissue to allow the wound to progress to healing. The presence of necrotic tissue or slough is not a contraindication to the use of AQUACEL® Foam dressing providing the wound bed is producing exudate.

AQUACEL® Foam dressing may be used immediately post injury/wound breakdown and continued until healing; however once a wound ceases to produce any exudate it will no longer be appropriate and an alternative dressing, such as a thin hydrocolloid, may be used.

IMPORTANCE OF REGULAR REVIEW

It is the healthcare professional's responsibility to continually evaluate a wound at each dressing change to ensure the frequency of dressing replacement is appropriate. For example, in a very heavily exuding wound, dressing changes must always be more regular than in a moderately exuding wound to avoid skin maceration, exudate leakage and patient distress. Continued wound assessment at each dressing change to observe exudate production should direct the clinician as to whether the continued use of AQUACEL® Foam dressing is appropriate.

IMPROVING OUTCOMES

This new foam technology has been used by clinicians on a range of wound types and a number of case studies are presented in this document. These show that AQUACEL® Foam dressing was able to manage exudate effectively in a wide range of wounds, including leg ulcers, pressure ulcers, diabetic foot ulcers, skin tears and surgical wounds, with the following clinical observations noted:

- Effective debridement of slough from the wound bed
- Improved condition of the periwound skin
- Reduced pain
- Reduced odour
- Improved wound progression
- Improved patient satisfaction, with fewer dressing changes.

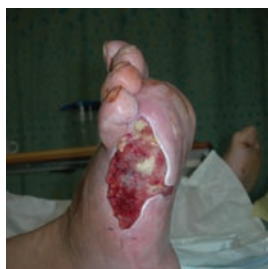

Figure 6: Diabetic foot wound. AQUACEL® Foam dressing is conformable and allows the patient to wear specialist footwear for mobilisation

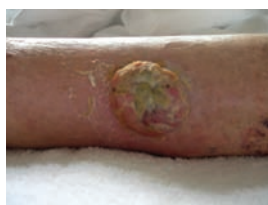

Figure 7: AQUACEL® Foam can be used on fungating wounds. Absorbing bacteria within the exudate can help to reduce odour

HELPING PATIENTS

Patients who self-managed their wounds found the dressings easy to apply and remove, reducing pain and anxiety at dressing changes, and that the dressing remained *in situ* with no movement or slippage from the wound site.

"I was dreading the dressing being taken off, previous dressings had stuck horribly and really hurt...I hardly felt it at all".

In addition, by containing the exudate with no strikethrough on outer bandages, patients can feel more confident about going out in public, helping to improve their quality of life. This may be especially important for those living with a chronic wound as many individuals struggle for control and independence. Patients and carers wishing to self-manage their wound at home should be fully supported, following the guidance of the lead clinician. This can be an extremely positive experience for individuals, allowing patients to have more control over their situation, with less dependence on the healthcare professional (International Consensus, 2012). Encouraging participation in their care is the first step in creating a successful therapeutic partnership, which can lead to improved satisfaction with care and better outcomes.

SUMMARY

Following thorough assessment of a patient's wound, clinical condition and frequency of dressing changes, AQUACEL® Foam dressing can be considered for the management of exuding wounds. The following case study evaluations describe its use in a range of wound types and clinical situations. These found that the dressing was easy to apply and remove, was effective in containing exudate and preventing periwound maceration. Patients were also able to shower and did not experience pain at dressing changes.

REFERENCES

- Anderson I (2012) Encouraging compliance and concordance in leg ulcer patients. *Wounds UK Supplement* 8(1): S6-S8
- Armstrong SH, Brown DA, Hill E, Ruckley CV (1995) A randomized trial of a new Hydrofiber dressing, AQUACEL, and an alginate in the treatment of exuding leg ulcers. Presented at 5th European Conference on Advances in Wound Management, Harrogate, UK
- Barnea Y, Amir A, Leshem D, et al (2004) Clinical comparative study of AQUACEL and paraffin gauze dressing for split-skin donor site treatment. *Ann Plast Surg* 53(2): 132-6
- Beldon P (2006) Avoiding allergic contact dermatitis in patients with venous leg ulcers. *Br J Community Nurs Suppl* 11(3): S6,8,10-12
- Bishop SM, Walker M, Rogers AA, Chen WY (2003) Importance of moisture balance at the wound-dressing interface. *J Wound Care* 12(4): 125-8
- Caruso DM, Foster KN, Blome-Eberwein SA, et al (2006) Randomized clinical study of Hydrofiber dressing with silver or silver sulfadiazine in the management of partial-thickness burns. *J Burn Care Res* 27(3): 298-309
- Data on File. ConvaTec 2012.
- Gardner S (2012) How to guide: managing high exudate wounds. *Wound Essentials Supplement*. 7:1. Available from: http://www.wounds-uk.com/pdf/content_10474.pdf
- Hilton JR, Williams DT, Beuker B, et al (2004) Wound dressings in diabetic foot disease. *Clin Infect Dis Suppl* 39: S100-3
- International Consensus (2012) *Optimising wellbeing in people living with a wound*. London: Wounds International. Available from: www.woundsinternational.com
- Johnstone E (2007) The role of nutrition in tissue viability. *Wound Essentials* 2:10-21
- Pritchard D, Jones, L, Brewer C, Martin J, Shaw H, Cochrane C (2012) Performance characterisation of a new foam dressing. Poster presentation at European Wound Management Association (EWMA); May 23-25, Vienna, Austria
- Queen D, Walker M, Parsons D, Rondas A. AQUACEL Ag dressings made easy. *Wounds International* 2(2). Available from: http://www.woundsinternational.com/pdf/content_9845.pdf
- Robinson BJ (2000) The use of a Hydrofiber dressing in wound management. *J Wound Care* 2000; 9(1): 32-4
- Romanelli M, Vowden K, Weir D (2010) Exudate management made easy. *Wounds International* 1(2). Available from: http://www.woundsinternational.com/pdf/content_8812.pdf
- Sussman G (2010) Technology Update: Understanding foam dressings. *Wounds International* 1(2). Available at: <http://www.woundsinternational.com/product-reviews/technology-update-understanding-foam-dressings/page-110/12>
- Thomas S (2010) Laboratory findings on the exudate-handling capabilities of cavity foam and foam-film dressings. *J Wound Care* 19(5):192-9
- White R, Gardner S, Cutting K, Waring M (2012) Wounds UK debate: What is the current status of foam dressings? *Wounds UK* 8 (3): 21-4
- World Union Wound Healing Societies (WUWHS) *Principles of best practice: Wound exudate and the role of dressings*. A consensus document. London: MEP Ltd 2007. Available from: http://www.woundsinternational.com/pdf/content_42.pdf

CASE STUDIES

CASE 1: LOWER LEG ULCER DUE TO MIXED DISEASE

Leanne Cook, Vascular Nurse Specialist; Clare Barker, Vascular Specialist Sister. Mid Yorkshire NHS Trust, Wakefield

BACKGROUND

An 86-year-old lady with mixed disease (arterial/venous) lower leg ulceration presented to the outpatient clinic. She had recently had an unsuccessful superficial femoral artery angioplasty and it was not possible to obtain an ABPI (ankle brachial pressure index) as she had no arterial pulses in her foot. Her past medical history included chronic obstructive pulmonary disease.

On presentation the lady described a history of deteriorating ulceration to the medial gaitor region of her right leg, which had been ongoing for the past four months. She complained of mild to moderate pain and a burning sensation around the base of her right ankle and heel. The ulcer was producing copious amounts of exudate and required daily dressings with cadexomer iodine paste, and several Surgipad surgical dressings (Johnson & Johnson), which were secured with wool and crepe bandages. This regimen was increasingly painful and distressing for the patient and was beginning to impact on her quality of life.

TREATMENT

On assessment the ulcer measured approximately 12cm x 10cm, with a central covering of sloughy tissue. The periwound skin was severely macerated and excoriated (Fig 1).

Following a vascular consultation, it was decided to treat the patient using modified compression as it was believed that there was an element of underlying venous disease due to the level of oedema and volume of exudate. Revascularisation was not possible and the only other treatment option was below knee amputation.

AQUACEL® Foam (21cm x 21cm) non-adhesive dressing was applied as a primary dressing and modified compression bandaging was commenced with the aim of reducing the wound exudate and to manage the localised maceration and excoriation. Due to the volume of exudate it was requested that the dressing was changed two days later by the district nursing team. At the next dressing change it was reported that there was no strikethrough to the outer bandage and the exudate was contained within the foam, which was not saturated. Dressing changes were decreased to twice weekly with fortnightly outpatient clinic reviews.

At follow up two weeks later, the wound showed signs of reducing slough and healthy granulation tissue (Fig 2). There was no further evidence of maceration and the periwound skin appeared healthy, allowing full assessment of the areas of ulceration. There were two areas of tissue loss, one measuring 5cm x 4cm and a smaller area measuring 2cm x 1cm. The patient reported minimal pain and the dressing was comfortable to wear. There was no strikethrough and her quality of life had improved.

At review a further three weeks later, the areas of ulceration had continued to improve. The wound bed was reducing in size with minimal slough evident (Fig 3). The smaller ulcer was nearly healed and now measured 1.5cm x 0.5cm and the larger ulcer measured 3cm x 2cm. The surrounding skin appeared healthy with no evidence of maceration. The exudate levels had continued to reduce and were now considered moderate. There was no strikethrough and the patient's pain was minimal, with pain-free dressing changes.

OUTCOME

AQUACEL® Foam dressing contributed to successful wound progression by effectively managing the wound, the surrounding skin and minimising pain and discomfort for the patient.

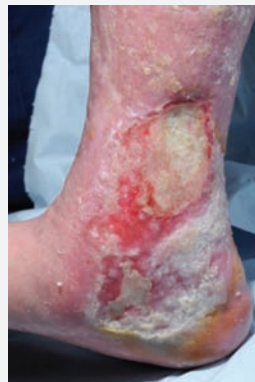

Figure 1. On presentation

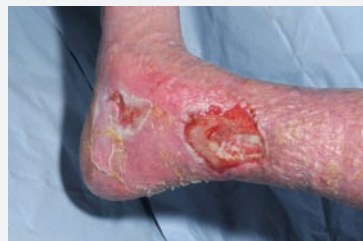

Figure 2. At review, 2 weeks later

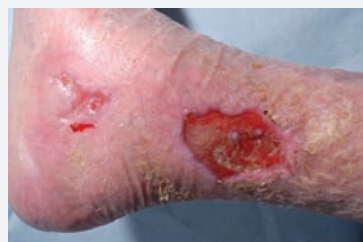

Figure 3. Wound at 5 weeks' treatment

CASE STUDIES

CASE 2: NECROTIC FOOT ULCER IN A PARAPLEGIC MALE

Rosalyn Thomas, Head of Podiatry, Morriston Hospital, Swansea, Wales

BACKGROUND

A 67-year-old paraplegic male presented as an inpatient with a large necrotic foot 'figure of eight' shaped ulcer on his left foot due to sunburn sustained while on holiday. It had initially presented as a blister, but it quickly turned black. The patient's wife dressed it with dry dressings until they returned to the UK and attended A&E where he was admitted to a medical ward at the end of June 2012. He was given IV antibiotics (teicoplanin).

He had been a paraplegic for over 30 years due to an accident at work and had previously had a foot ulcer that took four years to heal. Since that episode his wife had been vigilant in inspecting his feet daily and was distressed when this blister appeared.

The patient was referred to podiatric services for advice on appropriate dressing choice. Due to the leathery nature of the necrotic eschar (Fig 1), it was decided to use a hydrogel dressing to soften the eschar with a view to using larval therapy to biosurgically debride the wound. The wound care pathway was discussed with the patient and his wife prior to discharge home.

TREATMENT

The patient attended the Podiatry Outpatient Clinic two weeks later to initiate the larval therapy, returning two days later for their removal. The free range application was used as the extent of the wound was uncertain and the viability of the hallux was debatable (Fig 2).

The need to provide a moist wound environment, while promoting healthy granulation tissue was essential to close this wound. As the exudate levels were quite high, it was important to select a dressing that was absorbent and able to prevent maceration of the periwound skin. AQUACEL® Extra was used as the primary dressing and covered with AQUACEL® Foam adhesive dressing.

The patient's wife was happy to carry out the dressing changes between weekly visits to the department. Dressing changes were initially carried out on alternate days, but were changed to every three days. There was no strikethrough and no evidence of periwound erythema or trauma (Fig 4).

After just seven days there was no maceration to the margins of the wound and the wound bed was red and granulating with epithelialisation tissue migrating at the juncture of the two wound areas. As the wife was concerned about the odour from the wound, a tissue sample was taken, but this reported no significant bacterial growth. The malodour was controlled by adding CarboFlex over the hallux area together with the AQUACEL® Extra, covered with the AQUACEL® Foam dressing.

After two weeks the wound had decreased in size from one figure of eight wound measuring 19cm x 8cm to two wounds at three weeks measuring 6.5cm x 2cm on the dorsomedial aspect of the foot and 7.4cm x 4cm on the hallux. The ulcer continued to improve, with the migration of epithelial tissue between the two ulcer areas.

OUTCOMES

After four weeks of treatment, there was no maceration or periwound erythema, with migration of epithelial tissue dividing the wound into two. Once the dressing was discarded there was no malodour as all the exudate was locked in the dressing.

After nearly three months the wound has almost resolved and the exudate levels were very low (Fig 5). The patient and his wife were delighted that the wound had resolved so quickly. His wife remarked on the ease of application and removal of the dressings and that it remained in place with no movement or slippage from the wound site.

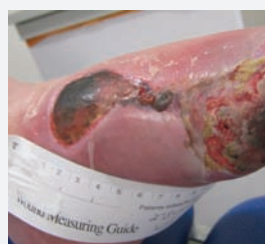

Figure 1. On presentation

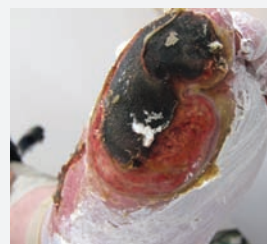

Figure 2. Pre-larval therapy

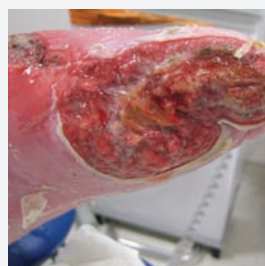

Figure 3. Post-larval therapy

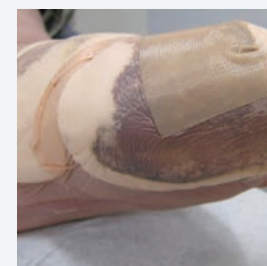

Figure 4. Dressing *in situ* after 3 days, with no strike-through and no periwound maceration on removal

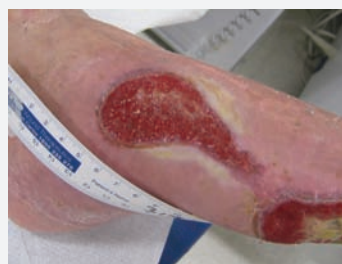

Figure 5. At three months

"I never thought that wound would heal, but it has..."

CASE 3: PRESSURE ULCERS AND MOISTURE LESIONS

Helen Wilkinson, Tissue Viability Nurse; Mark Collier, Lead Nurse/
Consultant, Tissue Viability, United Lincolnshire Hospitals NHS Trust,
Boston

BACKGROUND

This patient was a 71-year-old gentleman, who was registered blind, with a history of type 2 diabetes and schizophrenia. He had limited mobility to his right arm due to a brachial plexus injury. He lived alone. He collapsed at home and was believed to have been on the floor for six days before he was found by concerned neighbours and subsequently transferred to the local hospital.

On assessment, this gentleman had 24 pressure and moisture-related lesions, varying in degree of severity and size. The majority were full thickness with hard necrotic eschar present. It was initially agreed to manage five of the wounds with AQUACEL® Foam as these had begun to debride significantly more quickly than the others. The remaining wounds continued to be managed in accordance with the local wound management formulary. However, two of the wounds were discontinued from the evaluation as the dressing was no longer clinically indicated.

In choosing to use AQUACEL® Foam dressing, the prime wound management objectives were to:

- Facilitate debridement of sloughy tissue
- Manage exudate, preventing periwound skin damage and reducing the risk of further complications
- Minimise pain and discomfort at dressing changes.

TREATMENT

Wounds 1 and 3 had AQUACEL® dressing applied as a primary dressing due to increased levels of exudate, and all three wounds were covered with AQUACEL® Foam adhesive dressing. The patient was reviewed daily for the first few days.

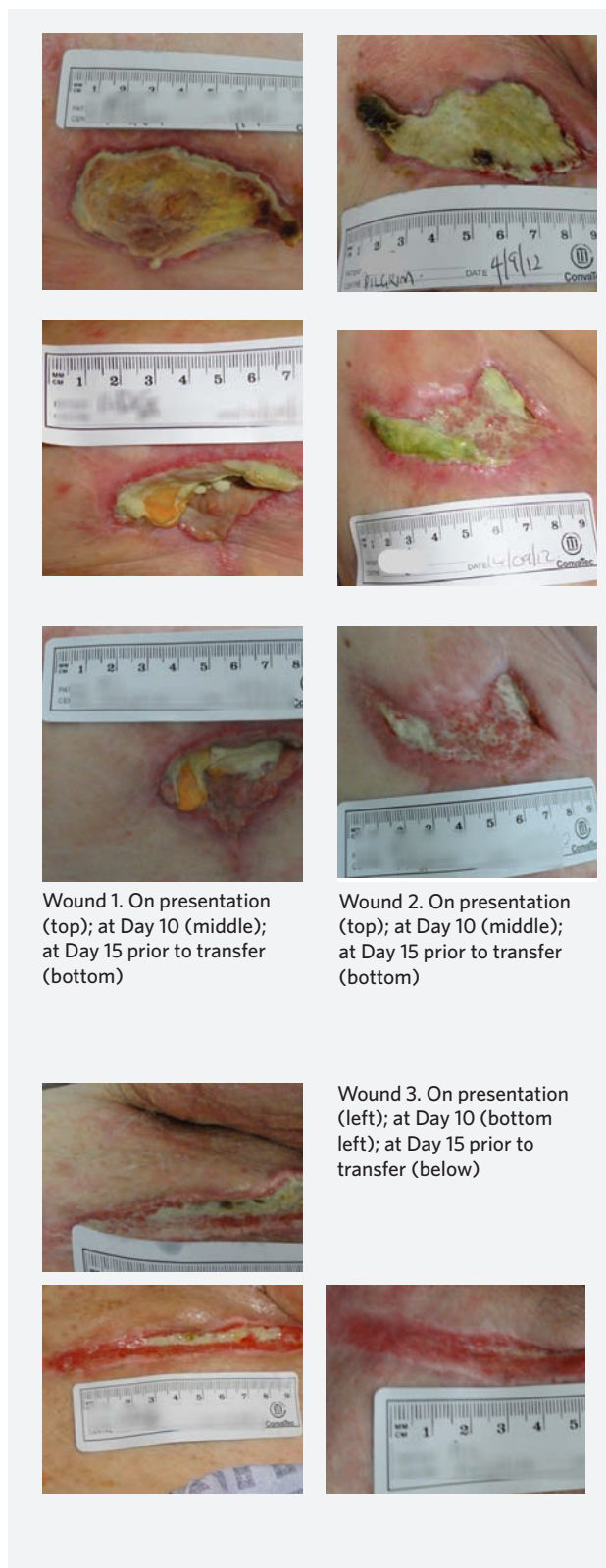
After two dressing changes Wound 3 no longer required the primary dressing as the exudate was managed by the AQUACEL® Foam dressing, and the regimen was amended to twice weekly changes. Wound 1, however, still needed a primary dressing as the devitalised tissue was autolysing, producing higher levels of exudate. Due to this wound's close proximity to Wound 2, both were redressed every 2-3 days.

OUTCOMES

Significant progress was noted in all three wounds within 15 days, after which the patient was transferred to an out of area community hospital.

Clinical observations noted that AQUACEL® Foam dressing:

- Facilitated debridement of slough
- Effectively contained moderate to high levels of wound exudate, although the frequency of changes needed increasing with 'wetter' wounds
- Improved the condition of the periwound skin
- Afforded pain-free dressing changes — the patient found it comfortable to wear and no pain was reported on dressing removal.



CASE STUDIES

CASE 4: DIABETIC FOOT ULCER

Angela Walker, Deputy Head of Podiatry, Birmingham Community Health NHS Trust, Birmingham

BACKGROUND

The patient was an 80-year-old gentleman with type 2 diabetes, which had been diagnosed 10 years previously. He had neuropathy, as a complication of the diabetes, and a history of previous foot ulceration. He was on oral medication for his diabetes, hypertension and cholesterol.

He presented with an ulcer on the plantar aspect of his left heel due to trauma and friction of footwear with a worn inner sole. The ulcer had been present for 12 months previous to podiatry input.

TREATMENT

The wound was managed initially for five weeks with AQUACEL® Extra dressing and a foam as a secondary dressing, as exudate levels were high and there were clinical signs indicating local infection. The patient was taking a course of oral antibiotics.

The ulcer size was initially 60mm x 30mm with a depth of 2mm. There was 50% coverage of sloughy tissue and 50% granulation tissue. The patient was provided with a soft cast heel cup and a temporary shoe. The wound was regularly sharp debrided.

After five weeks the wound had reduced in size (15mm x 12mm x 2mm) with 20% slough and 80% granulation tissue. Exudate levels were medium and there were no clinical signs of infection (Fig 1).

The patient was not experiencing any pain due to diabetic neuropathy. AQUACEL® Foam dressing was chosen to control the exudate and also to address the sloughy area of the wound. The ulcer was dressed twice weekly.

At dressing change, AQUACEL® Foam was found to be easy to remove. The periwound skin was healthy with 100% granulation tissue coverage. The wound size was 12mm x 10mm x 2mm, with medium exudate levels and no infection (Fig 2). The patient was still wearing a heel cast over the dressing. This regimen was continued to healing.

OUTCOMES

The wound reduced in size and the periwound skin was not macerated (Fig 3). Key components to healing this wound were debridement, pressure relief and appropriate dressing management to control the exudate. The patient was very satisfied with the outcome.

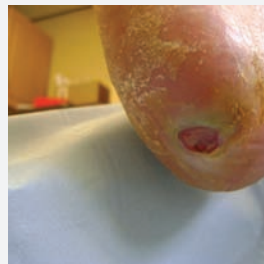

Figure 1. The wound at the start of treatment with AQUACEL® Foam

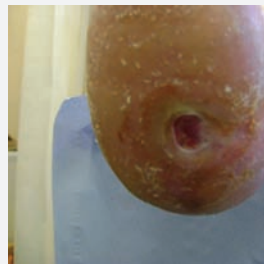

Figure 2. At 3 weeks of treatment with AQUACEL® Foam

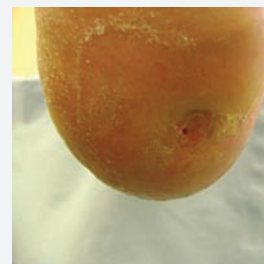

Figure 3. On completion of treatment with AQUACEL® Foam

"My skin normally itches when I have a plaster on me, this one doesn't make me itch at all..."

CASE 5: PAEDIATRIC SKIN TEAR

Dale Copson, Regional Clinical Specialist/Honorary Tissue Viability Nurse, ConvaTec UK

BACKGROUND

In terms of wound healing, tissue repair/regeneration is typically faster and often uncomplicated in most children, when compared to adults (Bale and Jones, 1996). However, children are potentially more sensitive to the effects of dressings and dressing changes if pain and discomfort is experienced, particularly when traditional adhesive dressings are used (Hollinworth and Collier, 2000; Hollinworth, 2005). Therefore, opportunities to minimise dressing effects for a child should be considered when deciding on the appropriate treatment regimen (Noonan et al, 2006).

The patient was a typically fit and well 11-year-old girl, who accidentally sustained a traumatic injury to her right leg while out playing. For her and her parents, the wound was very distressing in terms of its physical appearance and pain. She was also known to be sensitive to certain adhesive plasters, which often caused her skin to become red and irritated.

The wound was located on the lateral aspect of her right thigh. On initial assessment the wound was in a haemostatic state and presented as a V-shaped skin flap laceration, measuring 2cm x 2cm (at its widest points) and extended to the dermal layer. It was dark, dusky in colour and could not be realigned to its normal anatomical position (Fig 1). The wound was cleansed with normal saline; an attempt was made to re-approximate the skin flap as best possible, but this was abandoned as it was too distressing and painful for her.

TREATMENT

Consent was given by her parents for the wound to be managed with AQUACEL® Foam adhesive dressing. The management objectives in this instance were:

- To avoid localised epidermal irritation from the adhesive
- To facilitate moist wound healing
- Minimise pain, discomfort and trauma to the wound and surrounding skin on removal.

The patient was reviewed and the wound redressed twice weekly; at every review there was significant progress observed. By week 4 the wound had decreased in size to 1cm x 1cm, it was granulating and exudate levels were low (Fig 2). Due to significant progress, it was decided to continue weekly dressing changes with a thin hydrocolloid (DuoDERM® Extra Thin).

OUTCOMES

All of the wound management objectives agreed initially were achieved, with an endpoint of complete healing in six weeks (Fig 3). The young girl was able to shower with the dressing on and it remained in place. However, at dressing changes it was exceptionally easy to remove and the patient did not express any fear or anxieties at the thought of having the dressing reviewed. She described it as being 'painless' and thought it was 'great'.

This case study demonstrates that with the appropriate dressing, the clinical challenges associated with pain and discomfort when managing paediatric wounds can be addressed successfully.

References

- Bale S, Jones V (1996) Caring for children with wounds. *J Wound Care* 5(4):177-80
- Hollinworth H, Collier M (2000) Nurses' views about pain and trauma at dressing changes: results from a national survey. *J Wound Care* 9(8): 369-73
- Hollinworth H (2005) Pain at wound dressing-related procedures: a template for assessment. *World Wide Wounds*. Available online at www.worldwidewounds.com/2005/august/Hollinworth/Framework-Assessing-Pain-Wound-Dressing-Related.html
- Noonan C, Quigley S, Curley MA (2006) Skin integrity in hospitalized infants and children: a prevalence survey. *J Paed Nursing* 21(6):445-53

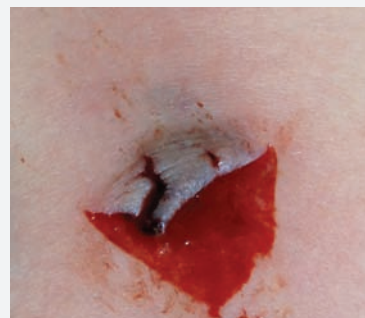

Figure 1.
On presentation

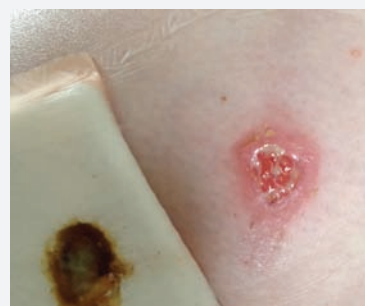

Figure 2. At week 4

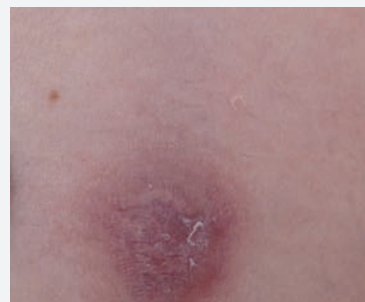

Figure 3. On completion of treatment with complete healing at six weeks

CASE STUDIES

CASE 6: INFECTED HIP WOUND AND ARM LACERATIONS

Sharon Bateman, Lead Nurse, Wound Care, South Tees Hospitals, NHS Foundation Trust, Middlesbrough
Dale Copson, Regional Clinical Specialist/Honorary Tissue Viability Nurse, ConvaTec UK

BACKGROUND

In July 2012 a 64-year-old gentleman was admitted to the local NHS Foundation Trust Hospital in an agitated state, pyrexial at 38.5°C and complaining of severe pain to his right hip.

His past medical history included type 2 diabetes (stable), diabetic retinopathy, hypertension, chronic renal disease stage 4, vascular disease, hypercholesterolemia and clinical depression. He was a smoker of 20 cigarettes a day.

It was later confirmed that he had an acute infected abscess, which required surgical intervention. He subsequently underwent drainage and surgical debridement of the infected site. The exposed cavity was packed with povidone-iodine soaked gauze and covered with an adhesive silicone foam dressing. Overnight the wound had exuded copious amounts of haemoserous fluid and was redressed by ward staff with an AQUACEL® dressing, two layers of surgical padding and several pieces of a soft adhesive surgical dressing.

On assessment: The right hip wound had continued to exude copious amounts of haemoserous fluid; it had leaked onto the periwound skin causing it to become inflamed and irritated. There was a slight malodour present and sloughy tissue was visible within the wound bed. It measured 9.5cm x 4.5cm x 6cm, with 85% granulation, 15% visible slough within the wound bed and slight malodour present.

Due to his confused mental status he had also sustained several skin lacerations to the thin fragile skin on his right forearm. These had been dressed with two pieces of soft adhesive surgical dressing and a piece of adhesive silicone foam secondary dressing. The exudate from these wounds had dried into the surgical dressings to such an extent that they had to be soaked and tentatively removed so as not to cause further trauma to the skin (Fig 1).

TREATMENT

Treatment goals for the hip were:

- Promote debridement of the sloughy tissue
- Manage exudate, preventing irritation to surrounding skin
- Minimise the risk of infection

Treatment goals for the arm were to reduce further trauma to the skin lacerations and surrounding fragile skin.

A 17.5cm x 17.5cm piece of AQUACEL® Foam adhesive dressing was placed over the multiple forearm lacerations and left *in situ* for 72 hours, after which the area no longer required the dressing and the skin was just kept hydrated with an emollient.

The hip wound was irrigated and cleansed with normal saline. The cavity was packed with two sheets of 10cm x 10cm AQUACEL® Ag at the base of the wound so as to reduce the risk of infection, with a further two sheets (10cm x 10cm) of AQUACEL® dressing to fill the remaining dead space. A 17.5cm x 17.5cm piece of AQUACEL® Foam adhesive was then applied as a secondary dressing.

The dressing remained in place for 72 hours. At dressing change, all the exudate had been contained, there was no malodour present and there was remarkable improvement in the periwound skin, with almost complete resolution of the surrounding redness. This regimen was continued for a further week (Fig 2).

The patient continued to be reviewed on a weekly basis with noticeable wound progression seen at each dressing change. At week 6, it measured 6cm x 3.8cm x 3.7cm and was being lightly packed (weekly) with two sheets of AQUACEL® (10cm x 10cm) and covered with a 10cm x 10cm AQUACEL® Foam adhesive dressing. His arm wounds went on to heal subsequently.

OUTCOMES

Using AQUACEL® Foam adhesive dressing and AQUACEL®, combined with an effective wound management regimen was undoubtedly a key factor in achieving wound progression. For this patient, the dressings not only effectively absorbed exudate, but also retained it (thus minimising periwound irritation). This is a key factor that must be considered when selecting any absorbent dressing together with the ability to stay in place, yet is easy and comfortable for the patient on removal. The patient commented that 'it was comfortable to wear' and that he 'didn't know he had it on'.

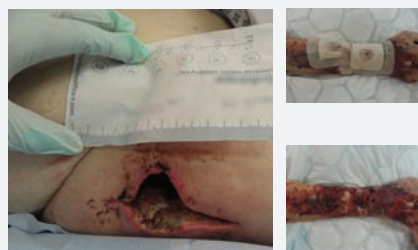

Figure 1. Following debridement and drainage of the right hip. The patient also sustained lacerations on right forearm

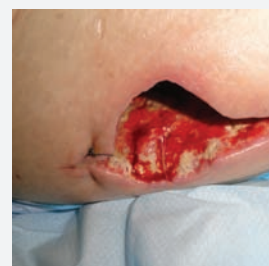

Figure 2. Right hip wound at two weeks. The wound had reduced to 6.2cm x 3.8cm x 4cm. There was 98% granulation, moderate to high levels of exudate and no irritation to the surrounding skin

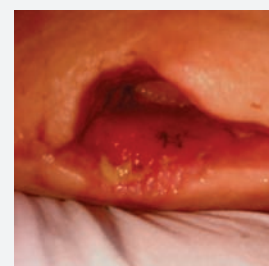

Figure 2. Right hip wound at six weeks. There was 99% granulation and moderate to high levels of haemoserous exudate

“Dressing changes are now reduced and the surrounding skin is no longer macerated”

CASE 7: POST-SURGICAL ABDOMINAL WOUND

Loty Lara, Annalie Canonigo, Diane Shaw, Agnes Collarte, Andrea Alberto, Tissue Viability Nurses, Central London Community Healthcare NHS Trust, St Charles' Centre for Health and Wellbeing, Exmoor Street, London

BACKGROUND

In May 2012, a 43-year-old man, presented to the complex wound clinic with a post-surgical abdominal wound, as a result of an emergency laparotomy, total colectomy and ileorectal anastomosis.

On referral to the clinic, the post-surgical wound measured 16cm x 10cm x 12cm. It was treated with negative pressure wound therapy for five weeks, followed by Fucidin® Cream, AQUACEL® (ConvaTec) and Kerramax® superabsorbent dressing (Crawford Healthcare). At review, the wound measured 13cm x 1cm and there were moderate amounts of exudate. The wound contained 30% sloughy tissue and 20% granulation tissue. The periwound skin was dry with some evidence of skin excoriation from previous dressing adhesives.

TREATMENT

AQUACEL® Foam heel adhesive dressing (19.8cm x 14cm) was applied to the abdominal wound, which fitted the contours of patient's abdomen well.

The wound was reassessed after three days. There was no discomfort or pain at dressing change, although the patient reported that he had to renew the dressing at home as it came loose in the shower. The wound contained predominantly granulation tissue and the excoriation to the periwound skin was resolved. AQUACEL® Foam heel adhesive dressing was reapplied and a small piece of film applied at the top of the dressing to secure the area and keep it waterproof. He was reviewed twice a week.

On reassessment the following week, 70% of the wound bed was healed, with 20% epithelialisation and 10% granulation tissue. The patient reported no pain or discomfort at dressing change. AQUACEL® Foam dressing had contained the wound exudate and the dressing change frequency reduced to once a week.

At week 3, the wound had continued to improve and more epithelialisation was noted. The wound was reassessed after seven days and the wound bed was 90% healed with 10% epithelialisation. The team together with the patient agreed to continue with AQUACEL® Foam heel adhesive dressing for a further week. At week 5 the abdominal wound had completely healed.

OUTCOMES

AQUACEL® Foam heel adhesive dressing was found to be easy to use and the patient had no pain or discomfort during dressing changes. The dressing was able to handle moderate levels of wound exudate and at the same time provided a moist environment for closure of this complex wound.

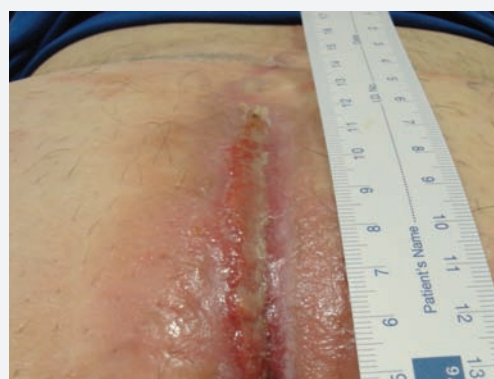


Figure 1. On presentation

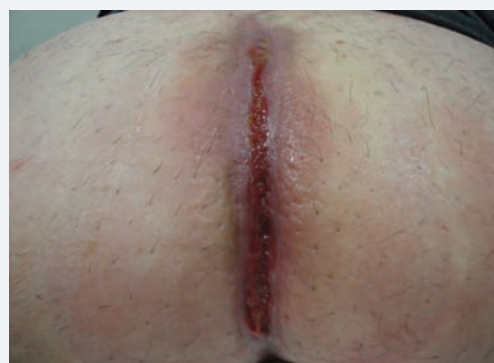


Figure 2. One week following commencement of treatment with AQUACEL® Foam

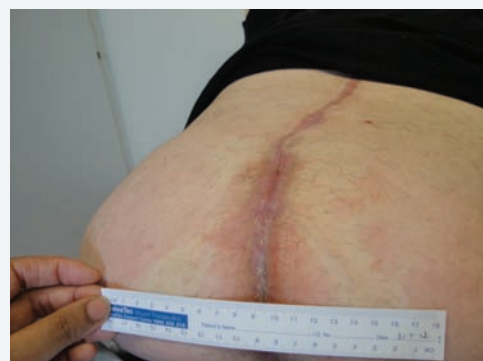

Figure 3. The wound was completely healed at week 5

Central London Community Healthcare 
NHS Trust
Barnet | Hammersmith and Fulham | Kensington and Chelsea | Westminster

Everything you love about foam dressings *and more*



Now only one dressing offers the comfort and simplicity of FOAM plus the healing benefits of an AQUACEL® contact layer

- Gentle silicone adhesive designed to adhere to surrounding skin, not the wound bed
- Available in a range of adhesive and non-adhesive sizes

new AQUACEL®
Foam



To learn more about AQUACEL® Foam dressing or to arrange a visit from your ConvaTec representative, please call **0800 289 738 (UK)** or **1800 946 938 (ROI)**

www.convatec.com/aquacelfoam

AQUACEL, the AQUACEL logo, ConvaTec, the ConvaTec logo, Hydrofiber and the Hydrofiber logo are trademarks of ConvaTec Inc., and are registered trademarks in the U.S.
© 2012 ConvaTec Inc.

AP-011757-MM



AQUACEL® Dressings

TRIED. TRUE. TRUSTED.™

