

# Holistic Approach for Noninvasive Facial Rejuvenation by Simultaneous Use of High Intensity Focused Electrical Stimulation and Synchronized Radiofrequency

## A Review of Treatment Effects Underlined by Understanding of Facial Anatomy

Suneel Chilukuri, MD

### KEYWORDS

- Face • Fillers • High intensity focused electrical stimulation • Radiofrequency • Neuromodulators • Noninvasive

### KEY POINTS

- Facial aging is a continuous process resulting from age-related changes in all structures present in the face. Such complex anatomy needs to be considered when it comes to noninvasive treatments for improving facial appearance. The facial muscles especially should be seen within their connective tissue environment and addressed accordingly.
- Novel HIFES and Synchronized RF technology was developed to target facial layers in synergy. Its effects show that it is a viable option for noninvasive face lifting and wrinkle reduction.
- It has been documented that HIFES and Synchronized RF does not interfere with the effects of neuromodulators or dermal fillers and can be safely and effectively used in patients injected with either of them, to deliver satisfactory improvement of overall facial appearance.

### INTRODUCTION

Facial aging is a continuous process resulting from age-related changes in all structures present in the face: skin, fat, muscle, fascia, and bone.<sup>1,2</sup> Age-related changes of all facial soft tissues start at different decades and progress at various paces, which vary between individuals of different gender and ethnicity. All changes together result in reduced support for the bone-overlying soft tissues, which then follow the effect of gravity. Thus, a loss of structural support owing to volume

depletion and changes to the facial muscles and their connective tissue framework results in increased soft tissue laxity.

#### *The Role of Facial Muscles and Fascia Framework in Aesthetic Appearance*

Facial muscles have been found to age through the process of sarcopenia, which manifests as a loss of muscle mass and volume, similar to skeletal muscles.<sup>3</sup> Because the facial muscles are interconnected via the fascial system and the

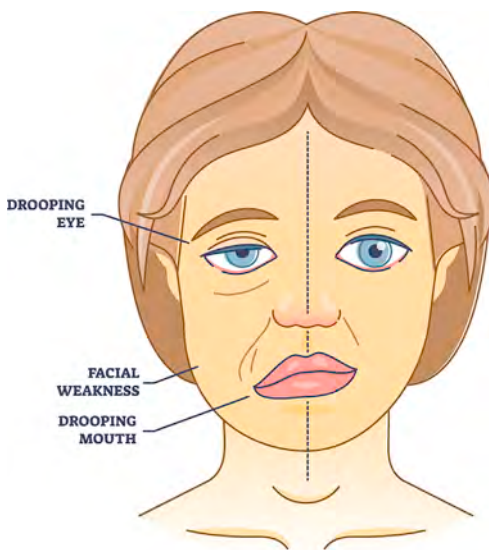
---

Refresh Dermatology, 5427 Bissonnet Street #500, Houston, TX 77081, USA  
E-mail address: chilukuri@refreshdermatology.com

Facial Plast Surg Clin N Am ■ (2023) ■-■  
<https://doi.org/10.1016/j.fsc.2023.06.006>  
1064-7406/23/© 2023 Elsevier Inc. All rights reserved.

overlying skin, weakening of these muscles may result in a visible descent of the tissue as we age (Fig. 1). The weaker the facial muscles are, and the lower the resting muscle tone is, the higher that muscle effort is needed to avoid sagging and to hold the overlying tissues in place. When too weak, they become unable to hold the tissue, resulting in eyebrow drop or cheek sagging. When the resting muscle tone is increased, the muscles are then able to hold the overlying tissue in place without dropping and without the need to stay contracted.

Specifically, the muscles in the cheek are interconnected by the midfacial superficial musculoaponeurotic system (SMAS).<sup>4</sup> Weakening of the cheek muscles, especially the zygomatic muscles, allows for the hypothesis that as we age, the resulting facial muscle weakness can promote midfacial soft tissue descent, resulting in the increased severity of the nasolabial fold, formation of jowls, and loss of jawline contour.<sup>5</sup> Targeting these muscles and their surrounding connective tissue architecture might allow for midfacial soft tissue repositioning. Also, the same muscle weakening could be expected for the frontalis muscle owing to aging or long-term use of neurotoxins. The frontalis muscle is mainly responsible for eyebrow movements. Its connection with the skin is ensured via the suprafrontalis fascia (located superficial to the frontalis muscle) and the subfrontalis fascia (located deep below the frontalis muscle). Aging of the forehead structures may result in eyebrow ptosis<sup>6</sup> and heaviness,



**Fig. 1.** Visualization of the effect caused by weakened facial muscles on the left in comparison to healthy muscles on the right.

which along with skin aging, may lead to laxity and wrinkle formation in the region.

In contrast to skeletal motion, the facial muscles are embedded in a connective tissue framework that interconnects all tissues from bone to skin. Interestingly, they are connected directly to the brain via the cranial nerves and are responsive to emotional input and the limbic system. Emotional states affect facial contours via resting tone of the muscles and the SMAS. Therefore, the facial muscles need to be seen within their connective tissue environment and addressed accordingly. Assuming that facial muscles affect skin movement alone without the support of a connective tissue environment creates an incomplete picture of facial muscle anatomy.

### **Treatment Alternatives**

Repositioning and restructuring the facial tissues and layers is the aim of aesthetic procedures via surgical and nonsurgical means.<sup>1,2</sup> Among noninvasive aesthetic procedures, radiofrequency (RF) is considered the gold standard for facial skin treatment. The effect of RF on the skin tissue is based on dermal heating, which leads to structural changes within the skin and the overall improvement in skin quality.<sup>7</sup> However, these skin heating procedures focus solely on improving skin quality and textural improvement, but not the overall facial appearance, which is also influenced by the facial volume and density of the underlying structures, including the fascial system, facial ligaments, and facial muscles. Therefore, the extent of facial laxity is a composite effect of all implicated structures of which the facial muscles and their interconnection with the skin play a fundamental role.<sup>8</sup>

The most frequently performed nonsurgical treatment to date is the administration of soft tissue fillers, which helps to restore facial volume. However, soft tissue fillers only cover the aging symptoms and do not affect facial muscles, which play a crucial role in natural skin mobility.<sup>9</sup> When it comes to muscles, the application of neurotoxins is yet another popular solution, although its primary effects are also limited to one tissue only. Currently, the only way to reliably alter facial muscles is through a surgical lift procedure, where the skin and fat tissues are separated from the muscle, and the muscles are then repositioned.<sup>10</sup>

Overall, the combination of age-related facial changes results in an alteration of the facial shape, which cannot be improved by targeting one type of tissue alone. Therefore, more profound treatment algorithms need to be applied to address age-related facial changes.<sup>11</sup> This may include addressing deeper fascial and muscle layers

together, as they have the ability to promote facial repositioning.

Recently, HIFES technology synchronized with RF heating has been introduced with the EMFACE (BTL Industries Ltd, Boston, MA, USA) device, to target the facial muscles and their connective tissue frameworks for lifting and tightening of the facial contours. HIFES technology induces electrical fields to contract facial muscles selectively. These delicate facial muscles are crucial for supporting the facial soft tissues and play a structural role in a more youthful appearance. While the HIFES targets the muscle and overlying fascia tissue, the Synchronized RF heating induces structural changes to the dermal and subdermal architecture. This approach can ultimately result in an improved appearance through changes in all facial tissue layers.

### TARGETING FACIAL TISSUES BY NONINVASIVE HIFES AND SYNCHRONIZED RADIOFREQUENCY TECHNOLOGIES

#### *Mechanics of HIFES for Facial Muscle Stimulation*

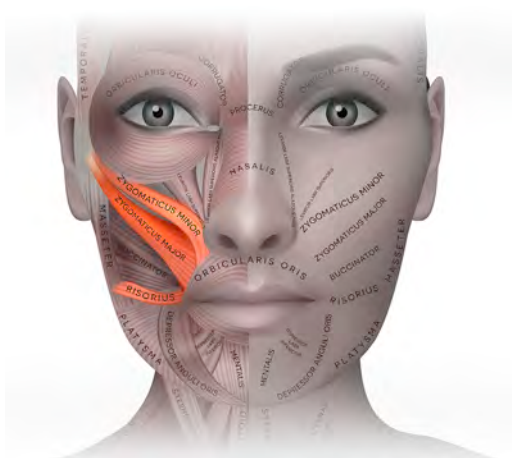HIFES technology was specifically designed to selectively induce supramaximal contractions of small delicate muscles in the face, namely the frontalis muscle on the forehead and zygomaticus major muscles, zygomaticus minor muscles and risorius muscles on the cheeks (**Fig. 2**). The technology generates strong electrical fields, delivered by its specifically designed applicators, that affect the underlying neuronal and muscle tissue. These electrical fields depolarize the membrane of the motor neurons that innervate the muscle. When the motor neurons are depolarized, a signal is

created that travels along the neuron, all the way to the neuromuscular junction—the place where the motor neuron is connected to the muscle. These signals overcome the barrier of the neuromuscular junction and progress to the muscle, which is thus forced to contract. This process bypasses the voluntary intention of the brain, inducing a forced contraction through electrical stimulation.

The HIFES stimuli repeat with such frequency that the facial muscles are not allowed to relax in between the individual signals. As the muscle cannot relax, with additional stimuli, it is forced to contract even further, which continuously builds up the contraction power with every additional signal. The appropriate selection of these 2 factors (electrical field strength and frequency) results in the so-called supramaximal contraction. Although it is poorly understood how and to what extent the facial muscles adapt to external stimuli, research studies conducted in skeletal muscles have revealed that heat shock proteins (HSP) and satellite cells (SCs) may be activated by intense muscle exercise as a response to the applied stimuli.<sup>12</sup> HSPs are the signaling molecules playing a crucial role in muscle remodeling through the promotion of muscle protein synthesis.<sup>13</sup> SCs are muscle-derived stem cells responsible for myofiber development and renewal.<sup>14</sup> In a resting state, the SCs remain quiescent, ready to be activated, and provide differentiation to create new myonuclei to existing muscle fibers or generate new muscle fibers. Together, HSP and SC activation can support muscle microprotein structure alterations. In a healthy muscle this may lead to densification of the muscle tissue and to overall improvement of the muscle quality. In atrophied muscle, the muscle structure alteration may lead to hypertrophic response reversing the atrophy. However, it is not only the muscle reacting to the signaling molecules. It has also been documented that the fascial layer remodels itself in response to heat and mechanical stimuli.<sup>15</sup> Nonetheless, the future studies will need to identify similarities between skeletal and facial muscles or provide conclusive evidence that facial muscles behave similarly or differently when targeted by external stimuli.

#### *The Role of Synchronized Radiofrequency Heating on Facial Muscles and Framework*

Simultaneously with the HIFES stimulation, the Synchronized RF that heats the facial tissue is delivered. Such stimuli affect the connective tissue framework and the facial muscle unit with consecutive adaptive changes to the overlying facial soft



**Fig. 2.** The cheek muscles stimulated by HIFES technology: zygomaticus major and minor muscles and risorius muscle.

tissues. According to previous studies on skeletal muscles,<sup>13,16</sup> HSPs can also be activated by heat within the range of 40°C. Together with the muscular contractions, the heat thus may further increase the levels of released HSP,<sup>17</sup> although this effect has been shown in abdominal muscle<sup>18</sup> or gluteal muscle.<sup>19</sup> A recent study by Kinney and colleagues<sup>20</sup> measured the facial muscle temperature during the treatment with HIFES and RF and showed that the temperatures in the targeted muscle tissues reached up to 40°C, indicating that a similar effect could also be seen in the facial muscles during the simultaneous treatment.

Furthermore, the primary effect of Synchronized RF heating on the subdermal tissues can be seen in the fascial framework. The fascial framework primarily consists of collagen and elastin, which are known to be heat responsive. Therefore, heating to adequate temperatures may induce remodeling of collagen and elastin within the fascial framework, leading to increased elasticity and tightness of the fascial web.<sup>15</sup>

### ***The Role of Synchronized Radiofrequency Heating on Skin Tissue Rejuvenation***

The same effect for the fascia can also be seen in the skin tissue. Regarding skin, fine lines and wrinkles accompanied by loss of skin volume are usually the first indicators of skin aging, a normal physiologic process influenced by genetic and hormonal changes with contribution of external factors.<sup>21</sup> During the skin aging process, the dermal blood vessel structure is disrupted, and in turn, the dermis is not supplied with nutrition and oxygen, thus slowing cellular regeneration.

The major building blocks of the skin are collagen and elastin fibers, which are responsible for skin elasticity and firmness. During the aging process, collagen and elastin synthesis decreases, and collagen bundles lose their extensible configuration and become fragmented. The elastin fiber network is degraded, leading to the loss of structural integrity of microfibrils. As the extracellular matrix is degraded, skin thickness is also reduced. It is estimated that adult skin loses 1% of overall collagen content annually.<sup>22</sup>

The EMFACE device uses a novel Synchronized RF electrode that allows the simultaneous application of an RF field together with HIFES. As the RF current flows through the tissue, a portion of the RF energy is absorbed, transforming the energy into heat and the desired thermal effect. During the 20-minute treatment, the skin tissue is heated to 40°C to 42°C. This therapeutic temperature range is reached within the first 2 minutes of the treatment, as documented by the thermal probe

measurements.<sup>23</sup> The level of RF energy absorption in the tissue depends on the RF frequency and tissue impedance, among other factors. Because the skin, muscle, and fat tissues have different impedances,<sup>24</sup> it is possible to selectively target the energy and achieve the thermal effect in the desired tissues.

When the therapeutic temperature is reached in the skin tissue for the desired time period, the hydrogen bonds tying the collagen fibers together begin to unwind, and collagen denaturation occurs. However, the above-mentioned temperatures do not lead to permanent damage. As the thermal effect dissipates, the bonds begin to renew, and the skin's architecture is changed to a more youthful level. After repeating this process during multiple treatments, the structure of older collagen and elastin fibers is changed, similar to newly formed collagen and elastin fibers.<sup>25</sup> This thermal effect is also accompanied by a heat-induced wound-healing response and increased fibroblast activity. Fibroblasts are the dermal cells responsible for producing new collagen and elastin fibers. As we age, their activity decreases to a level equivalent to an overall "net loss" of fibers. This means that the amount of newly formed fibers does not exceed the number of fibers being degraded, which accelerates the appearance of skin aging. Nevertheless, studies have shown that heat stress increases fibroblast activity, leading to an increased synthesis of collagen and elastin—neocollagenesis and neoeLASTinogenesis.<sup>25</sup> Overall, synchronized RF heating supports the skin to regain its volume, elasticity, and a more youthful appearance by restoring the collagen and elastin fiber structure and enhancing the synthesis of new collagen fibers.

### **CLINICAL EFFECTS OF HIFES AND SYNCHRONIZED RADIOFREQUENCY ON FACIAL TISSUES**

Because of the unique design and energy delivery, HIFES does not induce the stimulation of the depressors because it could potentially lead to a worsening of rhytides. The forehead application targets the frontalis muscle (brow elevator) and corresponding fascias while avoiding the depressors in the glabella. Restoring the tonus of the frontalis muscle and tightening the fascias in combination with the skin remodeling thus lead to reduced horizontal forehead lines, brow elevation, and skin texture improvement. The cheek application primarily targets the more superficial muscles of the cheeks (zygomaticus major/minor and risorius), which are all interconnected elevating units. In contrast, other deeper muscles,

such as the masseter muscle, are unaffected. Stimulation of these superficial muscles leads to an elevation of the entire cheek, increasing the midfacial volume and improving the nasolabial fold. Increasing the pull of these elevators further leads to a repositioning not only of the midface but also of the lower facial soft tissues. The resulting clinical effect is a reduction in jowls and an increase in jawline contouring. Furthermore, the combined effect of HIFES with Synchronized RF manifests as an overall textural improvement of the skin.

Clinical studies focusing on structural changes after HIFES and RF demonstrated a prominent skin remodeling effect. These studies found that collagen increase ranged between 26% and 27%, and elastin increase ranged between 110% and 129% 2 to 3 months following the procedure.<sup>23,26</sup> Research<sup>27</sup> investigating changes in skin texture and facial appearance reported a 37% wrinkle reduction and a 25% skin evenness improvement 3 months after the procedure. The processes induced in muscle tissue led to structural remodeling of the targeted muscles, which has been documented by Kinney and colleagues,<sup>20</sup> showing a 19% increase in muscle density and a 21% increase in the number of myonuclei. These results were coupled with reduced fibrotic and fat infiltration within the muscle tissue at 2 months after the procedure (Fig. 3).

The structural changes do manifest as increased resting muscular tone, which is necessary for maintaining the lifted facial appearance. The weaker the facial muscles are, the higher the muscle effort that is needed to avoid sagging and to hold the overlying tissues in place. When

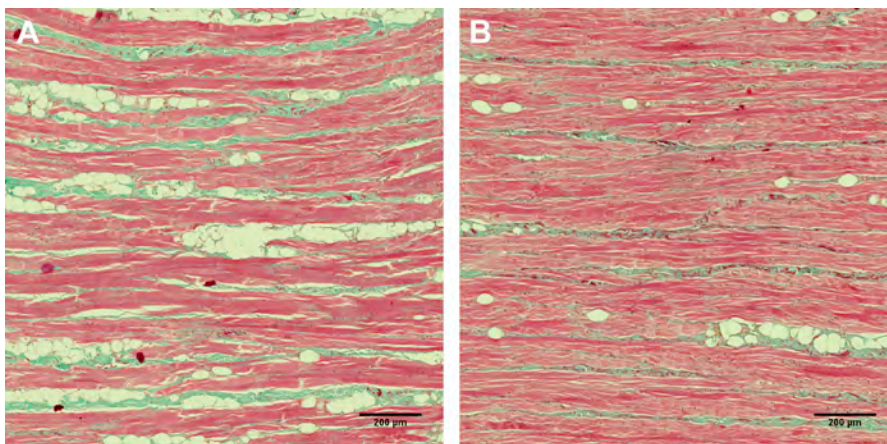
too weak, they become unable to hold the tissue, resulting in, for example, eyebrow drop or cheek sagging.<sup>2</sup> Recently, HIFES and RF was found to increase the muscle tone by 30%,<sup>28</sup> which was then shown to lead to an overall lifting effect by 23%.<sup>29</sup> Aside from multiple clinical studies using various evaluation methods, the results of the procedure are supported by a high patient satisfaction rate of 91%.<sup>29</sup>

#### APPLICATION OF HIFES AND SYNCHRONIZED RADIOFREQUENCY THERAPY WITH CURRENTLY USED PROCEDURES FOR IMPROVEMENT OF FACIAL APPEARANCE

##### *HIFES Effects on Neurotoxin-Blocked Muscles*

Neuromodulators in aesthetic medicine, such as Botox, Dysport, Xeomin, or Jeuveau, have become some of the most frequently sought nonsurgical aesthetic procedures with type A botulinum-based neurotoxins having a myriad of clinical indications. They are most frequently used to treat dynamic facial rhytides<sup>30</sup> involving the glabella, frontalis, and periorcular regions. Botulinum neurotoxins block neurotransmitter release (Acetylcholine; Ach) in the synaptic neuromuscular junction and block voluntary muscle contraction. With blocked contractions, wrinkle formation is prevented, as the overlying skin is not being repetitively folded during daily activities and thus aids in maintaining a more youthful skin appearance.

Botulinum-based neurotoxin affects the process of muscular contraction at the level of neuromuscular junction. When applied, it works as a protease and prevents the fusion of the vesicles with the presynaptic membrane.<sup>31</sup> Without this fusion, the Ach



**Fig. 3.** Histologic images of muscle tissues before (A) and 2 months after (B) the treatment with the HIFES and RF. Red represents muscle tissue; green represents intersected collagen fibers, and white rounded cells are adipocytes.

cannot be released into the neuromuscular junction and trigger the muscle contraction. It is a chemical denervation that causes partial paralysis of the innervated muscle. However, such paralysis is not causing any damage to the nerve or the neuromuscular junction and is not permanent.<sup>32</sup>

Studies have shown it is possible to stimulate even the botulinum-paralyzed muscles.<sup>33,34</sup> However, it is not entirely clear how such stimulation overcomes the barrier made by the botulinum neurotoxin. Upon the application of botulinum toxin, the membrane of the presynaptic neuron should be practically impermeable to Ach molecules owing to its size as the fusion of vesicles and presynaptic membrane ("quantal release") is blocked. Nevertheless, clinical trials are showing that externally it is possible to overcome this barrier, and although the mechanism of how this happens is not entirely clear, several hypotheses were proposed to explain such mechanism, particularly the nonquantal Ach release<sup>35</sup> and direct stimulation of postsynaptic membrane.<sup>36</sup>

Research has shown that a nonquantal release of small amounts of Ach into the synapse still occurs, even in botulinum toxin denervated muscle. However, during voluntary contractions, the amount of the Ach is not sufficient to cause depolarization, and the muscles thus remain relaxed. By applying an external high-frequency electrical field that surpasses the frequency of brain signals, the activity of the high-affinity choline transporter could be elevated, leading to exaggerated non-quantal release of Ach in amounts sufficient enough to cause muscle depolarization and contraction. In addition, an insufficient long-term concentration of Ach in the synapse, owing to the application of botulinum toxin, can lead to an increased expression of n-acetylcholine receptor on the postsynaptic membrane and, therefore, also to an increase in the sensitivity of the muscle to Ach.<sup>37</sup> A lower amount of Ach would thus be needed to induce such depolarization.

On the other hand, the conclusions regarding the direct muscle stimulation are based on studies performed on skeletal muscles only. Facial muscles are of significantly different proportions and are much more superficially located in low depths. All this may influence the response. As the facial muscles are more delicate, lower intensity of stimulus may suffice to irritate the muscle membrane. Because the thickness of some facial muscles may be as small as 0.5 mm,<sup>38</sup> it may be possible that such stimulation is able to recruit enough muscle fibers to induce contraction of the entire muscle.

Regardless of the mechanism, HIFES technology is seemingly able to stimulate botulinum neurotoxin-blocked muscles in order to prevent

risk of muscle atrophy. HIFES stimulates blocked facial muscle even though it is not possible voluntarily. Recent findings<sup>39</sup> showed that during the EMFACE treatment the botulinum-denervated muscles are being contracted, and what is most important, it does not interfere with the effect of botulinum toxin itself. No negative effects of the HIFES and RF procedure on the efficacy of the botulinum toxin were found.

### ***Synchronized Radiofrequency and Dermal Fillers Treatment***

Injection of dermatologic fillers is one of the most common procedures that is used in aesthetic medicine for rejuvenation of the face. These gellike substances are used for the treatment of wrinkles by injecting filler beneath the skin so it restores lost volume and more contour to the face. Fillers can be divided into 2 categories. First, the biodegradable fillers that are not permanent and can last up to 12 months, losing their effectiveness with time and eventually being metabolized. Fillers that are currently available stimulate neocollagenesis, so the effect persists longer to some extent.<sup>40</sup> Such dermal fillers that are currently used and approved by the Food and Drug Administration (FDA) are hyaluronic acid, calcium hydroxylapatite, and poly-L-lactic acid. The second group of nonbiodegradable fillers are long-term solutions for wrinkles, but there is a much bigger risk of complications. There are only 2 nonbiodegradable fillers approved by the FDA: polymethylmethacrylate microspheres and liquid injectable silicone (LIS), but LIS was approved only for intraocular use.<sup>41</sup>

Concerns have been voiced among patients and practitioners regarding RF treatments in that dermal filler would break down if they underwent RF treatment, or even worse, that the patient's skin would get damaged under RF applicators. Nevertheless, there exists plenty of evidence in the literature about safety of RF treatment over the area injected with dermal fillers.<sup>42-44</sup> In addition, there even exist devices that are using RF energy during dermal filler injection. In study by Kim and colleagues,<sup>45</sup> it was found that using RF during filler injection is a safe and effective method to treat especially mobile areas like the nasolabial fold. Overall, the findings prove that increasing the temperature of the tissue above normal levels is safe for the filler's stability. Depending on the system used, RF devices for noninvasive skin treatments elevate the tissue temperature no more than 65°C. On the other hand, the current dermal fillers are usually autoclaved, and therefore, bear considerable thermal stability. For instance, hyaluronic acid fillers are usually sterilized at a temperature of 120°C before one can observe

negative effects of heightened temperatures.<sup>46</sup> Furthermore, the literature shows that use of RF with dermal fillers is safe for treated tissue itself if using RF treatments at normal clinical temperatures up to 65°C, which is far beyond the temperature range achieved during EMFACE therapy. Nevertheless, more studies are needed to rule out any possible doubt, especially studies using human participants treated with different ranges of RF intensity and time exposure as well as using multiple different commercially available dermal fillers.

## SUMMARY

The novel EMFACE device was developed for noninvasive face lifting and wrinkle reduction by targeting all facial layers, framework, and facial muscles by simultaneously using Synchronized RF and HIFES technologies. Heating the facial tissue to effective temperatures and HIFES stimulation of only specific facial muscles result in a combined effect that causes textural changes to the skin, smoothing, wrinkle reduction, facial repositioning, and an overall lifting effect. The simultaneous and targeted manner of both technologies yields unique benefits by inducing a synergistic effect in the facial soft tissues that cannot be achieved by using these technologies consecutively or as a stand-alone procedure. It poses no risk to patients who underwent neuromodulator or dermal filler procedures and can be safely and effectively used in patients injected with either of them to deliver satisfactory improvement of overall facial appearance.

## CLINICS CARE POINTS

- In a long-time botox using patients, the visible contractions start at a higher intensity and after a longer period of time, however in all the patients, the visible contractions were always achieved
- It is normal to observe asymmetrical contractions, when in doubt please palpate the subject. You can adjust the HIFES intensity for each applicator separately
- This therapy uses the radiofrequency, therefore be aware of patients' hydration

## DISCLOSURE

Dr S. Chilukuri is a clinical advisor to BTL Industries Ltd. Nonetheless, no funding for authorship and publication of this article was provided, and the author declares no other conflict of interest related to this article.

## REFERENCES

1. Coleman S, Grover R. The anatomy of the aging face: Volume loss and changes in 3-dimensional topography. *Aesthetic Surg J* 2006;26(1):S4–9.
2. Kavanagh S, Newell J, Hennessy M, et al. Use of a neuromuscular electrical stimulation device for facial muscle toning: a randomized, controlled trial. *J Cosmet Dermatol* 2012;11(4):261–6.
3. Cotofana S, Lowry N, Devineni A, et al. Can smiling influence the blood flow in the facial vein?—An experimental study. *J of Cosmetic Dermatology* 2020;19(2):321–7.
4. Whitney ZB, Jain M, Jozsa F, Zito PM. Anatomy, Skin, Superficial Musculoaponeurotic System (SMAS) Fascia. In: StatPearls. StatPearls Publishing; 2022. Available at: <http://www.ncbi.nlm.nih.gov/books/NBK519014/>. Accessed January 29, 2023.
5. Joshi K, Hohman MH, Seiger E. SMAS Plication Facelift. In: StatPearls. StatPearls Publishing; 2022. Available at: <http://www.ncbi.nlm.nih.gov/books/NBK531458/>. Accessed January 29, 2023.
6. De Jong R, Hohman MH. Brow Ptosis. In: StatPearls. StatPearls Publishing; 2022. Available at: <http://www.ncbi.nlm.nih.gov/books/NBK560762/>. Accessed January 29, 2023.
7. Araújo AR de, Soares VPC, Silva FS da, et al. Radiofrequency for the treatment of skin laxity: myth or truth. *An Bras Dermatol* 2015;90(5):707–21.
8. Swift A, Liew S, Weinkle S, et al. The Facial Aging Process From the “Inside Out.”. *Aesthetic Surg J* 2021;41(10):1107–19.
9. Kim K, Jeon S, Kim JK, et al. Effects of Kyunghee Facial Resistance Program (KFRP) on mechanical and elastic properties of skin. *J Dermatol Treat* 2016;27(2):191–6.
10. Van Borsel J, De Vos MC, Bastiaansen K, et al. The Effectiveness of Facial Exercises for Facial Rejuvenation. *Aesthetic Surg J* 2014;34(1):22–7.
11. Sulamanidze MA, Paikidze TG, Sulamanidze GM, et al. Facial Lifting with “APTOS” Threads: Featherlift. *Otolaryngol Clin* 2005;38(5):1109–17.
12. Schultz E, McCormick KM. Skeletal muscle satellite cells. *Rev Physiol Biochem Pharmacol* 1994;123:213–57.
13. Kakigi R, Naito H, Ogura Y, et al. Heat stress enhances mTOR signaling after resistance exercise in human skeletal muscle. *J Physiol Sci* 2011;61(2):131–40.
14. Mauro A. Satellite cell of skeletal muscle fibers. *J Biophys Biochem Cytol* 1961;9:493–5.
15. Langevin HM, Bouffard NA, Fox JR, et al. Fibroblast cytoskeletal remodeling contributes to connective tissue tension. *J Cell Physiol* 2011;226(5):1166–75.
16. Goto K, Okuyama R, Sugiyama H, et al. Effects of heat stress and mechanical stretch on protein

- expression in cultured skeletal muscle cells. *Pflügers Archiv European Journal of Physiology* 2003;447(2):247–53.
17. Halaas Y, Duncan D, Bernardy J, et al. Activation of Skeletal Muscle Satellite Cells by a Device Simultaneously Applying High-Intensity Focused Electromagnetic Technology and Novel RF Technology: Fluorescent Microscopy Facilitated Detection of NCAM/CD56. *Aesthetic Surg J* 2021;41(7):NP939–47.
  18. Samuels JB, Katz B, Weiss RA. Radiofrequency Heating and High-Intensity Focused Electromagnetic Treatment Delivered Simultaneously: The First Sham-Controlled Randomized Trial. *Plast Reconstr Surg* 2022;149(5):893e–900e.
  19. DiBernardo B, Chilukuri S, McCoy JD, et al. High-Intensity Focused Electromagnetic Field With Synchronized Radiofrequency Achieves Superior Gluteal Muscle Contouring Than High-Intensity Focused Electromagnetic Field Procedure Alone. *Aesthet Surg J Open Forum* 2023;5:ojac087.
  20. Kinney BM, Bernardy J, Jarošová R. Novel Technology for Facial Muscle Stimulation Combined With Synchronized Radiofrequency Induces Structural Changes in Muscle Tissue: Porcine Histology Study. *Aesthet Surg J* 2023;43(8):920–7.
  21. Wong QYA, Chew FT. Defining skin aging and its risk factors: a systematic review and meta-analysis. *Sci Rep* 2021;11(1):22075.
  22. Tobin DJ. Introduction to skin aging. *J Tissue Viability* 2017;26(1):37–46.
  23. Kent D, Fritz K, Salavastru C, et al. Effect of Synchronized Radiofrequency and Novel Soft Tissue Stimulation: Histological Analysis of Connective Tissue Structural Proteins in Skin. Presented at: American Society for Dermatologic Surgery (ASDS) Annual Meeting 2022. October 6-10, 2022; Denver, CO.
  24. Bouazizi A, Zaibi G, Samet M, Kachouri A. Parametric study on the dielectric properties of biological tissues. In: 2015 16th International Conference on Sciences and Techniques of Automatic Control and Computer Engineering (STA). IEEE; 2015:54-57. Available at: [https://www.semanticscholar.org/paper/Parametric-study-on-the-dielectric-properties-of-Bouazizi-Zaibi/6514f20152d1d0e47b06ca0eb35b89ebada31e87?utm\\_source=email](https://www.semanticscholar.org/paper/Parametric-study-on-the-dielectric-properties-of-Bouazizi-Zaibi/6514f20152d1d0e47b06ca0eb35b89ebada31e87?utm_source=email).
  25. Elsaie ML, Choudhary S, Leiva A, et al. Nonablative Radiofrequency for Skin Rejuvenation. *Dermatol Surg* 2010;36(5):577–89.
  26. Goldberg DJ, Lal K. Histological Analysis of Human Skin after Radiofrequency Synchronized with Facial Muscle Stimulation for Wrinkle and Laxity Treatment. Presented at: American Society for Dermatologic Surgery (ASDS) Annual Meeting 2022. October 6-10, 2022; Denver, CO.
  27. Halaas Y, Gentile R. The Interim Results of Novel Approach for Facial Rejuvenation. Presented at: American Academy of Facial Plastic and Reconstructive Surgery (AAFPRS) 2022 Annual Meeting. October 20-23, 2022; Washington, DC.
  28. Halaas Y., MD. Muscle Quality Improvement Underlines the Non-invasive Facial Remodeling Induced by a Simultaneous Combination of a Novel Facial Muscle Stimulation Technology with Synchronized Radiofrequency. Presented at: American Academy of Facial Plastic and Reconstructive Surgery 2022. October 19-23, 2022; Washington, DC.
  29. Kinney B, Boyd C. Safety and Efficacy of Combined HIFES Tissue Stimulation and Monopolar RF for Facial Remodeling. Presented at: American Academy of Facial Plastic and Reconstructive Surgery 2022. October 19-23, 2022; Washington, DC.
  30. Nestor MS, Kleinfelder RE, Pickett A. The Use of Botulinum Neurotoxin Type A in Aesthetics: Key Clinical Postulates. *Dermatol Surg* 2017;43(Suppl 3):S344–62.
  31. Segelke B, Knapp M, Kadkhodayan S, et al. Crystal structure of Clostridium botulinum neurotoxin protease in a product-bound state: Evidence for noncanonical zinc protease activity. *Proc Natl Acad Sci U S A* 2004;101(18):6888–93.
  32. Satriyasa BK. Botulinum toxin (Botox) A for reducing the appearance of facial wrinkles: a literature review of clinical use and pharmacological aspect. *Clin Cosmet Investig Dermatol* 2019;12:223–8.
  33. Santus G, Faletti S, Bordanzi I, et al. Effect of short-term electrical stimulation before and after botulinum toxin injection. *J Rehabil Med* 2011;43(5):420–3.
  34. Adams V. Electromyostimulation to fight atrophy and to build muscle: facts and numbers. *J Cachexia Sarcopenia Muscle* 2018;9(4):631–4.
  35. Vyskočil F, Malomouzh A, Nikolsky E. Non-quantal acetylcholine release at the neuromuscular junction. *Physiol Res* 2009;763–84.
  36. Cameron MH. *Physical agents in rehabilitation: from research to practice*. 4th edition. UK: Elsevier/Saunders; 2013.
  37. Frick CG, Richtsfeld M, Sahani ND, et al. Long-term effects of botulinum toxin on neuromuscular function. *Anesthesiology* 2007;106(6):1139–46.
  38. Alfen NV, Gilhuis HJ, Keijzers JP, et al. Quantitative facial muscle ultrasound: feasibility and reproducibility. *Muscle Nerve* 2013;48(3):375–80.
  39. Chilukuri S. Evaluation of Safety and Efficacy of the BTL-785F Device for Non-Invasive Facial Rejuvenation in Patients Injected With Botulinum Toxin. *ClinicalTrials.gov* identifier: NCT05524766. Updated September 6, 2022. Available at: <https://clinicaltrials.gov/ct2/show/NCT05524766>. Accessed November 3, 2022.
  40. Carruthers J, Carruthers A, Humphrey S. Introduction to Fillers. *Plast Reconstr Surg* 2015;136(5 Suppl):120S–31S.
  41. Commissioner O of the. *Dermal Filler Do's and Don'ts for Wrinkles, Lips and More*. FDA. Published online April 2, 2022. Available at: <https://www.fda>.



- gov/consumers/consumer-updates/dermal-filler-dos-and-donts-wrinkles-lips-and-more. Accessed January 30, 2023.
42. England LJ, Tan MH, Shumaker PR, et al. Effects of monopolar radiofrequency treatment over soft-tissue fillers in an animal model. *Lasers Surg Med* 2005; 37(5):356–65.
  43. Shumaker PR, England LJ, Dover JS, et al. Effect of monopolar radiofrequency treatment over soft-tissue fillers in an animal model: part 2. *Lasers Surg Med* 2006;38(3):211–7.
  44. Alam M, Levy R, Pajvani U, et al. Safety of radiofrequency treatment over human skin previously injected with medium-term injectable soft-tissue augmentation materials: a controlled pilot trial. *Lasers Surg Med* 2006;38(3):205–10.
  45. Kim H, Park KY, Choi SY, et al. The efficacy, longevity, and safety of combined radiofrequency treatment and hyaluronic Acid filler for skin rejuvenation. *Ann Dermatol* 2014;26(4):447–56.
  46. Goldman MP, Alster TS, Weiss R. A randomized trial to determine the influence of laser therapy, monopolar radiofrequency treatment, and intense pulsed light therapy administered immediately after hyaluronic acid gel implantation. *Dermatol Surg* 2007; 33(5):535–42.