
RIVISTA ITALIANA DI

Organo Ufficiale della FIO
Federazione Italiana di Ossigeno-Ozonoterapia


OSSIGENO-OZONOTERAPIA

VOLUME 5 - N. 1 - APRILE 2006

CENTAURO s.r.l., BOLOGNA

Semestrale - Poste Italiane s.p.a. - Sped. in a.p. - D.L. 353/2003 (conv. in L. 27/02/2004 n° 46) art. 1, comma 1, DCB/BO Euro 30,00

ISSN 1720-6561



OZONLINE

INTERNATIONAL

®

by MEDICA srl

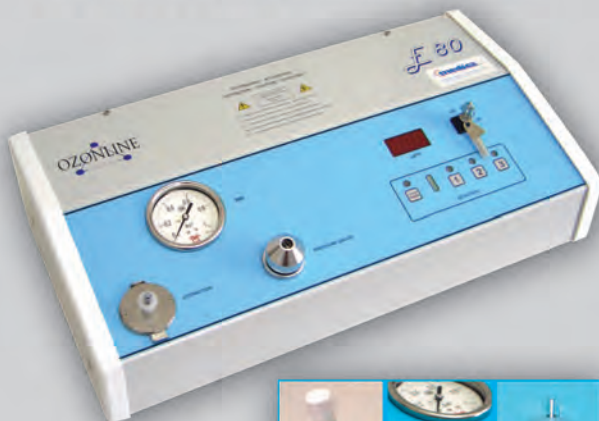Via del Barroccio, 6/2 - 40138 Bologna - Italy

Tel. 0039 051 534715 - Fax 0039 051 534441

info@medica-srl.com - www.medica-srl.com



Ozone Therapy: a new medical technology of generators



- *Our generators are built with the system of "corona discharge"*
- *Variable concentration range from 1 to 80 µg/ml*
- *Differential digital photometer for real - time display of concentrations*
- *Automatic zero setting and washing of all circuit before and after treatment*
- *Our generators are built with titanium, silicone, stainless steel, viton ecc...*
- *Available to connect oxygen tanks and also in the central oxygen system with our oxygen flow regulator*
- *Available with valve adapter disposable device for taking ozone by hypodermic syringe to avoid discitis*
- *Available to make topical application with our "trolley komby"*
- *Exclusive kit for the optimized procedure of O3- AHT*
- *Maximum portability for the model E/30 (only 7 kg.)*
- *Certificated and constructed in conformity with the MDD CE 93/42 class II A CE 0476*

**Our dealer
in the world:**

Spain and Latin America
Ozon Linea S.L. - Madrid
E-mail: joseangelserrano@telefonica.net

Middle East - Cairo, Egypt
E-mail: nashed.maged@gmail.com

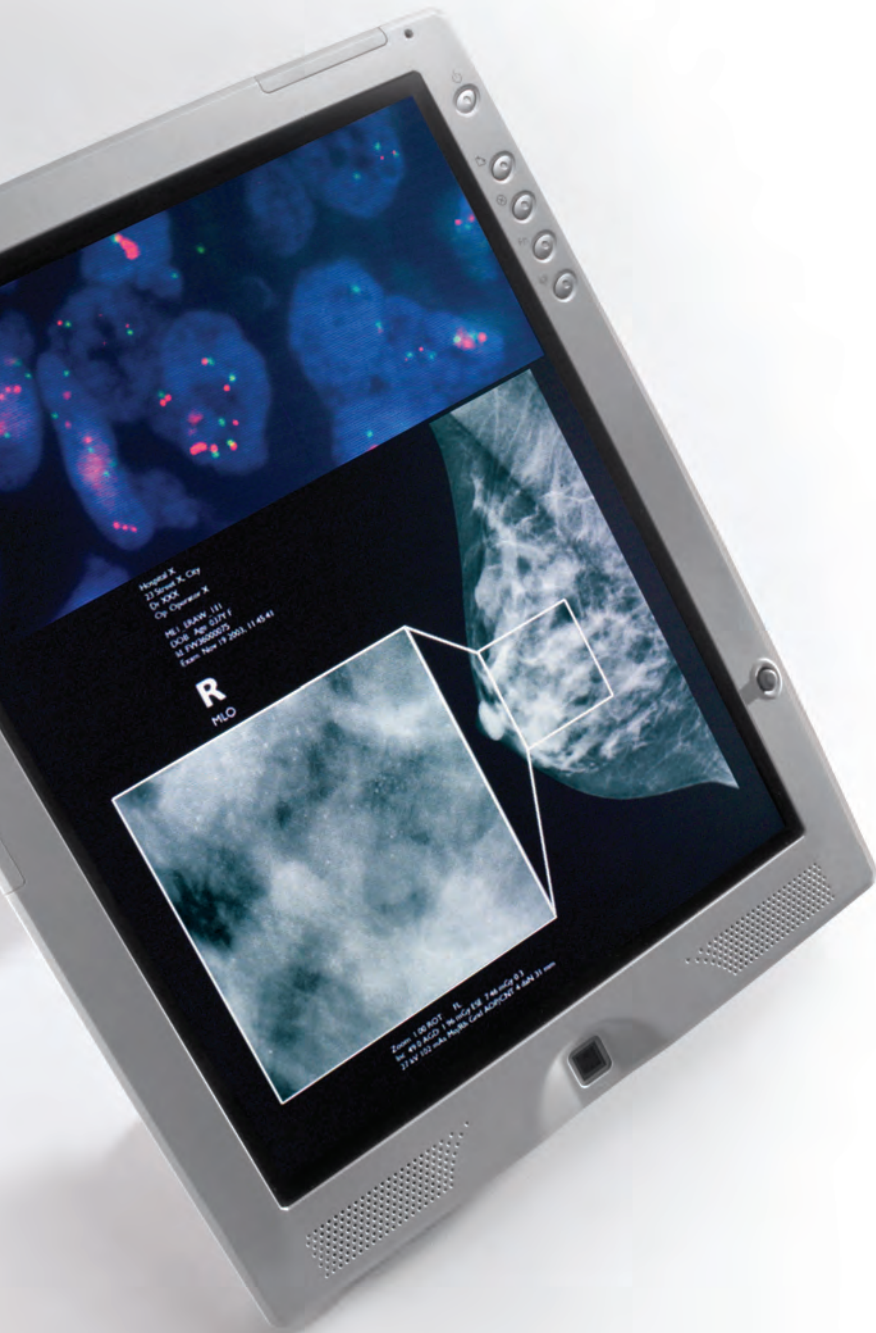East Europe - Sofia, BG
www.bulconsulting.com/
E-mail: rangelova_m@yahoo.com

People's Republic of China
Unico Technologies Ltd
E-mail: info@unicotech.com.hk

Index

■ Editorial	5	OXYGEN-OZONE THERAPY FOR LOCAL ADIPOSE DEPOSITS AND OEDEMATOUS FIBROSCLEROTIC PANNICULOPATHY	37
V.S. Kumar		M.A. Sirito	
OZONE THERAPY IN CRITICAL PATIENTS. RATIONALE OF THE THERAPY AND PROPOSED GUIDELINES	7	EL OZONO Y LOS FACTORES DE CRECIMIENTO EN LA CURACIÓN DE LAS ULCERAS	41
V. Bocci, G.S. Brito		<i>ULCERS TREATED WITH OZONE AND GROWTH FACTORS</i>	
EFFECT OF MAJOR AUTOHAEMOTHERAPY WITH OXYGEN-OZONE ON THE ANAEROBIC THRESHOLD IN ATHLETES	12	José Faus Vitoria	
A. Gjonovich, G. Sallusti, A. Brusomini		CHANGES IN HAEMOCHROMOCYTOMETRIC VALUES IN HORSES AFTER OZONE AUTO-HAEMOTRANSFUSION	47
INITIAL EXPERIENCE OF OXYGEN-OZONE TREATMENT FOR DISC HERNIATION IN BOLIVIA. A REPORT OF 120 CASES	17	E. Ballardini	
R. Alvarado, J. Jimenez		WFOT - WORLD FEDERATION OF OZONE THERAPISTS. Constitution	66
INTRAFORAMINAL O ₂ -O ₃ INFILTRATION: USE OF CT GUIDANCE IN CASE OF ACCIDENTAL PUNCTURE OF THE PERIGANGLIONIC VENOUS PLEXUS	21	WFOT – WORLD FEDERATION OF OZONE THERAPISTS Bylaws	71
F. Albertini, M. Bonetti		■ Letters to the Editor	57
OXYGEN-OZONE THERAPY FOR DEGENERATIVE SPINE DISEASE IN THE ELDERLY	25	■ Intermezzo	64
M. Bonetti, A. Fontana, D. Mardighian		FRANCESCO RICCARDO MONTI	
OXYGEN-OZONE CHEMONUCLEOLYSIS FOR HERNIATED DISC WITH SCIATICA. A COMPARISON OF TREATMENTS IN PATIENTS WITH SUBACUTE AND CHRONIC SYMPTOMS	33	■ Information & Congresses	40, 53, 54, 56, 59, 60, 62, 74, 75
M. Leonardi, L. Albini Riccioli, S. Battaglia, F. de Santis, P. Cenni, L. Raffi, L. Simonetti		■ Subscription Form	76
		■ FIO Application Form	77
		■ Instructions to Authors	80

GE Healthcare



GE imagination at work

Ciò che l'ossigeno non può fare, l'ozono lo fa

Hyper-Medozon comfort con analizzatore di ozono e touchscreen con istruzioni in italiano



novità

hypermedozon

- » Guida all'utilizzo passo dopo passo attraverso il touchscreen
- » Regolazione micrometrica della concentrazione e misurazione automatica attraverso l'analizzatore e l'apparecchiatura di controllo
- » Regolazione individuale della concentrazione di emissione
- » Possibilità di insufflazione intestinale
- » Tre impianti separati di erogazione dell'ozono
- » Range di concentrazione: 5-80 µg/ml
- » Effusore per riempimento e disinfezione della siringa
- » Connessione diretta per erogazione permanente
- » Pompa vacuum integrata

- **Alimentazione:** 230 V ~/50 Hz
- **Consumo:** 210 VA
- **Concentrazione di ozono:** 5-80 µg/ml (Spettrofotometro di controllo)
- **Sicurezza:** sensore ottico con valvola di compressione e valvola di sfogo per la pressione
- **Intensità di flusso:** appr. 1 litro al minuto
- **Connessione permanente:** cono Luer, temporizzatore automatico 15 minuti
- **Connessione per siringa:** Luer-Lock
- **Connessione per infusione:** Luer-Lock
- **Dimensioni L/A/P:** 525 x 180 x 460 mm
Peso: 21.3 kg (con Airtrap)
- **Categoria di prodotto:** Direttiva 93/42 CE, categoria II b
- **Colori:** verde e argento
- Notificato al Ministero della Salute



NAMED srl
Via Lega Lombarda 33 - 20050 Lesmo (MI)
Tel. 039.698501 - Fax 039 6985030
e-mail: info@named.it - www.named.it

*E*ditorial

Since the discovery of Ozone by German physicist Christian Friedrich Schonbein in 1840, it has taken a long time for scientists to understand its usefulness in clinical medicine. Ozone was used as an agent to purify water in 1901 and found its clinical application as an antimicrobial agent during the First World War for treatment of infected wounds and burns.

Italians and Germans were at the forefront of research into this application of ozone. Velio Bocci has done pivotal work on the molecule and written two landmark monographs in English on the physiology and clinical applications of ozone in myriad clinical disorders (*Oxygen-Ozone Therapy: A critical evaluation and Ozone: A new medical drug*).

Verga's proposal in 1988 that ozone can be used for disc prolapse was further refined by M. Muto ten years later and paved the way for an exponential increase in the application of this molecule for disc prolapse.

In this era of surgical minimalism, nearly 150,000 spinal interventional procedures are performed annually (nearly a third of all spinal surgical procedures are for degenerated discs), many of which comprise ozone injection therapy for disc prolapse. An unparalleled record of safety, cost effectiveness and relative technical simplicity are the reasons for the enormous growth of ozone therapy.

In April 2002, interest in ozone therapy led to the creation of the Italian Federation of Oxygen therapy (FIO) by Marco Leonardi and its official journal *Rivista Italiana di Ossigeno-Ozonoterapia*, edited by Matteo Bonetti.

Americans, despite their initial skepticism have started to look at this technology with much interest. An FDA application for Investigational Device Exemption has been submitted by E. Soriano from Temple University, Philadelphia, USA.

The second annual international meeting on Spine Intervention, focused on ozone therapy for disc prolapse, was held in New Delhi, India. The meeting was attended by faculty and delegates from Italy, USA, Taiwan, Russia, Germany, Canada, Spain, Pakistan and India.

During the proceedings, it was suggested that we set up an international society specifically dealing with ozone therapy. The aim of the society was to widen the participation and enhance the knowledge on a global level and incorporate ozone therapy into mainstream medicine. With this view in mind the World Federation of Ozone Therapists (WFOT) was created.

We propose to make *Rivista Italiana di Ossigeno-Ozonoterapia* into an international journal on ozone therapy to be published bilingually or with an abridged translation from either English to Italian or Italian to English.

I am honored to be nominated as the first president of this nascent organization and encourage all to join the WFOT and contribute to the journal.

The first International meeting of the Federation will be incorporated with the Third Indo-Italian Congress “*Least Invasive Spine Intervention and Ozonucleolysis*” to be held in New Delhi, India on November 3-6, 2006.

I look forward to hosting many of you during the congress.

Vijay Sheel Kumar
MBBS, MD, FACS, DABNS, FIPP
New Delhi, India

Ozone Therapy in Critical Patients. Rationale of the Therapy and Proposed Guidelines

V. BOCCI*, G.S. BRITO**

* Department of Physiology, University of Siena; Siena, Italy

** Clinical Immunology and Allergy Division, São Paulo, State University Medical School Hospital and Hospital Santa Catarina, Brazil.

Key words: major ozonated autohemotherapy (O-HAT), Minor O-HAT, albumin, n-acetyl cysteine, ascorbic acid chronic oxidative stress, lung shunt

SUMMARY – In combination with the most suitable orthodox therapy, there are rational bases for justifying the use of ozone therapy in critical patients. This approach is difficult to implement in intensive care units, not for technical reasons, but because ozone therapy is regarded with suspicion and scepticism. However, assuming that appropriate permission and informed consent are obtained, which is the best way to proceed? We should aim to improve oxygen delivery to vital organs and ischemic areas and to support respiratory, cardiac and renal functions. If the patient's metabolic conditions are not excessively deteriorated, within 3-4 days of daily ozonated autohemotherapy treatments the increased synthesis of antioxidant enzymes and the induction of heme-oxygenase-1 may reduce the chronic oxidative stress simultaneously caused by infection-inflammation-tissue necrosis and dysmetabolism. We suggest some guidelines with the proviso of being flexible for each clinical case. The aim is not to achieve a scientific result but to save human lives.

Introduction

Visiting an ordinary intensive care unit, one can observe a heterogeneous group of patients, all at risk of losing their lives owing to traumatic events, severe burns, stroke, gangrene of the limbs, abdominal or pulmonary infections with various degrees of septic shock. We have often wondered if an intensive application of ozone therapy combined with the best conventional therapies may improve the prognosis¹. However, at Siena hospital the chief doctor has been always concerned about the legal aspects because if the patient dies he will be accused of having used a non-validated therapy. The Ethical Committee also refuses to give permission for a trial because there is not yet any prospect that ozone therapy could represent a valid support.

Recently, Dr. Brito urgently requested a scheme and schedule for treating a critically ill patient with ozone therapy. The patient was a Brazilian colleague who presented a multiple critical dissection of the aorta. Luckily an experienced surgeon was able to correct it by placing an aortic prosthesis, an aortic valve prosthesis and suitable stents in the aortic descendend and thoracic aorta. The patient was under extracorporeal circulation for about six

hours and although he was aided by multiple blood transfusions (40 units) he developed a critical situation with lung shunt, pneumonia, fever and serious respiratory difficulties documented by very poor respiratory parameters and a gram negative bacterium on bronchoscopy aspiration. Fortunately, Dr. Brito was a dear friend of the patient, and a disciple of ozone therapy. Having read section 15 in my latest book¹ concerned with ozone therapy in emergency conditions, he decided that it was worthwhile to combining the orthodox therapy with ozone therapy. After obtaining prompt permission from the director of the intensive care unit, on the basis of the family's request, an informed consent form signed by the family members and a special authorization from Ministry of Health regulatory agency on medical practice, he performed four major ozonated autohemotherapy (O-HAT) treatments daily for three consecutive days (October 4-6, 2005), using a blood volume of 200 ml each time and an ozone concentration of 40 mcg/ml on the first day and 25 mcg/ml on the 2nd and 3rd days. As the patient conditions started to improve, he reduced the number of treatments to two on the fourth day and to one daily for the following week. The patient had a remarkable improvement, characterized by normalization of body temperature

This paper is dedicated to the memory of Dr. Edison de Cesar Filippi, the most experienced ozone therapist in Brazil.

and improvement of respiratory parameters. He was then moved from the intensive care unit to a regular room, in fairly good health, walking, eating, and starting working on his laptop. Once all intravenous catheters were removed because they were no longer necessary, autohemotherapy was stopped. Moreover, because of the recent extensive surgery, it was decided to stop heparinization to avoid bleeding at surgery sites. This may have been an untimely decision because he had a sudden stroke with high intracranial pressure probably caused by an embolus from the heart or aorta. Any further attempt to save him was unsuccessful due to extensive brain swelling and cerebral death. Unfortunately this outcome is fairly frequent in patients with severe vascular disease.

What could be the role of ozone therapy and was it reasonable to undertake it? Dr G.S. Brito, who closely followed the patient and performed the ozone therapy during the first phase, is convinced that ozone therapy corrected a dangerous post-operative course. Needless to say, the initial surgery and conventional treatments were absolutely indispensable.

If clinical conditions tend to further deteriorate, before multiorgan failure develops, a prompt and appropriate use of ozone therapy may improve the situation even though its intrinsic validity remains a matter of opinion. Nonetheless, in such cases, the scientific rigor is less important than the patient's life. According to Paragraph 32 of Helsinki Declaration the assumption is: In the treatment of a patient, where proven prophylactic, diagnostic and therapeutic methods do not exist or have been ineffective, the physician, with informed consent from the patient, must be free to use unproven or new prophylactic, diagnostic and therapeutic measures, if in the physician's judgment it offers hope of saving life, re-establishing health or alleviating suffering. Where possible, these measures should be made the object of research, designed to evaluate their safety and efficacy. In all cases, new information should be recorded and, where appropriate, published. The other relevant guidelines of this Declaration should be followed.

Dr G.S. Brito felt that we should propose a guideline taking into account the dysmetabolic and most frequent septic conditions of critically ill patients.

A brief analysis of the problem

Owing to the extreme variability of the aetiology and pathogenesis of the above indicated pathologies, it is reasonable to ask if they share a common denominator which may justify the use of ozone

therapy. Is it inflammation, or tissue degeneration, or infection? We feel that the most important and common problem is the presence of chronic oxidative stress (COS) which is a persistent and progressive imbalance between decreasing antioxidants and prevailing oxidants, able to induce a generalized cellular apoptosis and death of the patient. During an infection and/or a chronic inflammation, leukocytes and macrophages generate excessive amounts of reactive oxygen species (ROS, such as anion superoxide, hydrogen peroxide, hypochloric acid) that unselectively destroy pathogens as well as normal cells. Ozone therapy is currently the only procedure able to block and reverse this negative process because it can:

1) Enhance the transport and release of oxygen in ischemic areas. One may think that reperfusion may further damage hypoxic tissues, but if the degeneration has not gone too far, the messengers generated by ozone, namely the lipid oxidation products (LOPs), can, after binding to cell receptors, stimulate the synthesis of antioxidant enzymes such as superoxide dismutase (SOD), catalase (Cat), glutathione peroxidase, reductase and transferase (GSH-Px, Red. and Tr.)²⁻⁶. Moreover and most importantly, small calculated and transitory acute oxidative stress is one of the best stimuli for inducing the synthesis of some acute oxidative stress proteins, of which the most protective is the inducible heme-oxygenase-1 (HO-1)¹. This enzyme (OSP-32) allows the degradation of heme from over-abundant hemoproteins and hemoglobin and results in the formation of biliverdin (hence bilirubin that is a valuable lipophilic antioxidant) and carbon monoxide (CO). The concomitant co-induction of ferritin, due to the release of iron, allows the beneficial sequestration of redox-active iron, thus avoiding formation of hydroxyl radical (OH[•]) by the Fenton reaction. Since 1978, the properties and protective effects of HO-1 overexpression have been described in over 3600 publications! It is impossible to enumerate all of the functions of this Herculean enzyme able to prevent or improve different pathological conditions.

2) During infusion of the ozonated blood into the donor, LOPs enter into contact with the vast expanse of the endothelium and stimulate an increased synthesis of nitric oxide (NO) via NO-synthase and arginine⁷. NO (and NO-thiols) and CO are the crucial physiological gases able to activate guanylate cyclase, so that the release of cyclic GMP enhances the vasodilation. The combination of these processes can, in not too advanced diseases, reduce infection, inflammation and cell degeneration.

3) Ozonation of blood *ex vivo*, by the controlled release of small amounts of the generated

hydrogen peroxide, allows a mild activation of neutrophils and the induction of the production of some cytokines⁸⁻¹². After re-infusion of the ozonated blood, the activated or primed leukocytes migrate all over the body and can slowly improve the response of the adaptive immune system. Obviously, with the crucial help of appropriate antibiotics, even chronic infections can be controlled.

4) Some of our experimental data suggest that stimulation of platelets^{13,14} and endothelial cells⁷ by LOPs may favour the release of growth factors and autacoids, one of which may be prostacyclin. Surprisingly, LOPs may also inhibit cyclooxygenase II with the beneficial consequences of reducing hyperpermeability, edema and pain¹⁵.

5) Once LOPs and nitroso-thiols reach the bone marrow microenvironment, they may activate metalloproteinase 9, a critical enzyme favouring the release of staminal cells. After their mobilization, these cells may enter the general circulation and home in infarcted areas. Although this idea has not yet been experimentally proved, it is a likely possibility that must be pursued because it may acquire practical importance.

6) Ozonation of blood performed using sodium citrate (1 ml of citrate 3.8% solution/ 9 ml of blood) does not cause any dyscoagulation during slow blood infusion. Citrate is rapidly metabolized while heparin is less safe.

7) It is a general observation that the majority of patients undergoing ozone therapy report a feeling of well-being and euphoria. Although we have no experimental data, it has been speculated that by influencing cerebral, hypothalamic neurons and endocrine cells, LOPs may induce the release of some hormones (ACTH, cortisol, dehydroepiandrosterone, serotonin, endorphins) able to induce a reduction of pain and a feeling of wellness.

8) Provided that ozone therapy is performed correctly, after millions of treatments performed all over the world during the last three decades, there is no record of acute or chronic toxicity. Against scepticism and the dogma that "ozone is always toxic", we know that the ozone dose (calculated as the product of the ozone concentration per gas volume), representing the acute stressor, must be perfectly calibrated against the potent antioxidant capacity of blood in such a way as to never overwhelm it. Within the established therapeutic window (10-80 mcg/ml ozone per ml of blood), no more than 30% of the antioxidant capacity of blood is oxidized during the ozonation reactions and is rapidly (in about 20 min) reconstituted by a very efficient biochemical recycling of antioxidants^{1,16}.

9) According to a Cuban study, ozone may inhibit

it platelet aggregation, and at least theoretically, had ozone therapy been continued, it may have avoided thromboembolism in our case.

In conclusion, each autohemotherapeutic treatment, equivalent to a precisely calculated chemical shock, appears able to trigger a multitude of biological processes relevant for correcting the complex pathology present in critically-ill patients. The consequent possible correction of the chronic oxidative stress is particularly important.

How and when to perform ozone therapy. Tentative guidelines

We propose to perform the following procedures:

Major O-HAT. Depending on the hemodynamic status of the patient, Major O-HAT can be carried out by collecting from 50 up to 225 ml of venous blood in a sterile glass bottle (250-500 ml) under vacuum. Sodium citrate solution (3.8%) must be added to the bottle before the blood in the proportion of 1:9 ml blood. To avoid any risk of haemorrhage, heparin must be used cautiously by first ascertaining the coagulation parameters. The gas volume must be added in a 1:1 volume ratio using an initial ozone concentration of 10 mcg/ml per ml of blood. Five minutes of slow mixing to avoid foaming is sufficient to complete the ozone reaction before re-infusion of the ozonated blood into the donor. The ozone concentration can be slowly increased to 15- 20-25 mcg/ml during the next few days, but, because the patient is under COS, a higher concentration of ozone should be avoided because more deleterious than advantageous. Frequency of O-AHT can be up to three (about every 8 hours) on the first few days and then, if the patient improves, it can be reduced to two and one.

Minor O-AHT. Very simply, the residual 3-4 ml of blood remaining at the end of the infusion tubing during each O-AHT can be withdrawn in a 10 ml syringe just filled with 5 ml of gas (ozone concentrations at 80-100 mcg/ml for a total dose of 400- 500 mcg). After inserting a G21 needle, the blood is rapidly mixed with the gas by rotating the syringe for 1-2 min and then promptly injected intramuscularly (glutei), with the foam. The very high ozone concentration is purposely used to provoke some hemolysis in order to activate the induction of OSP, particularly heme-oxygenase-I. We suggest the same frequency of administration indicated for major AHT. This i.m. injection is intended to act as a minor acute oxidative shock that, in the hands of one of us (VB), greatly enhances the overall treatment.

An important and frequently overlooked aspect is the possibility that the critically ill patient, under pronounced COS, has a low blood antioxidant capacity. Although we are unable to correct the COS by administering megadoses of antioxidants, we must recommend intravenous administration of selected antioxidants immediately after the auto-hemotherapy treatment for 2-3 hours, hence 5-6 hours before the next O-AHT. For several reasons we suggest the infusion of human albumin (20% concentration), possibly diluted with 100 ml 5% glucose solution with additional 0.5 g of ascorbic acid. Unfortunately, N-acetyl-cysteine (NAC), the best precursor of reduced glutathione (GSH) is not yet available for infusion and therefore can only be administered per os, but this is rarely possible. A compromise is the i.v. infusion of GSH, which will transiently increase the plasma levels but will not increase the critical cellular level because, there is no membrane transport for GSH - at variance with what is commonly believed. Needless to say, depending on the hemoglobin content, we must be ready to perform allotransfusions because it will be useless to administer ozone therapy if the hemoglobin level falls below 11 g/dL.

If major O-AHT cannot be performed, as a last option we can resort to rectal insufflation of gas every 8 hours. A volume of 300-400 ml can be insufflated very slowly using an initial concentration of 5 mcg/ml that can be progressively increased to a maximum of 25 mcg/ml. In the case of abdominal or pulmonary lesions, particularly after trauma and infections, it is advisable to use intraperitoneal and intrapleural insufflation of gas via, as usual, a polypropylene catheter. Ozone can exert both a direct disinfectant activity on these cavities as well as immunomodulatory effects without any discomfort or toxicity.

In the case of severe sepsis and/or septic shock the mortality can be as high as 50% and during the last two decades antibodies against endotoxin and TNF alpha as well as other approaches have yielded negligible results. However, several clinical trials have shown that infusion of recombinant

human activated Protein C (Drotrecogin alpha activated) can markedly decrease morbidity and mortality and therefore should be kept in mind because this protein reduces inflammation and overt dyscoagulation. Similarly, whenever surgery appears necessary, antibiotics and all the other supportive orthodox drugs must be applied because in our mind ozone therapy can only benefit the patient if used in combination.

Ozone may be able to reverse disseminated intravascular coagulation.

Conclusions

We have outlined a possible scheme and schedule for treating severely ill patients in intensive care units with ozone therapy. In spite of a minimal practical experience, there are good rational bases for suggesting the use of ozone therapy in combination with the best orthodox therapy to reduce the morbidity and high mortality of these patients. It would be extremely gratifying if other ozone therapists would like to share their experience with us, so that we may be able to further improve the treatment. Once the patient, if mentally alert, and/or the family desiring to receive a specific treatment according to the Helsinki Declaration have signed an informed consent, the doctor should be allowed to proceed with the treatment. Dr. Brito is currently developing the design of a Phase I study for treatment of sepsis cases in the Intensive Care Unit of Trauma at the Emergency Surgery Department of his Medical School Hospital in Sao Paulo, Brazil.

Acknowledgements

We are grateful to Dr. Silvia Menendez, Dr Luiz Haertel, Dr Djalma Faraco (heart surgeon), Dr Marcelo Linhares and Dr Eduardo Philippi for help and advice during the unfortunate attempt to save the patient.

References

- 1 Bocci V: Ozone. A new medical drug. Springer, Dordrecht, The Netherlands 2005: 1-295.
- 2 Bocci V: Does ozone therapy normalize the cellular redox balance? *Med Hypotheses* 46: 150-154, 1996.
- 3 Leon OS, Menendez S, Merino N et Al: Ozone oxidative preconditioning: a protection against cellular damage by free radicals. *Med. Inflamm* 7: 289-294, 1998.
- 4 Barber E, Menendez S, Leon OS et Al: Prevention of renal injury after induction of ozone tolerance in rats submitted to warm ischaemia. *Mediat. Inflamm* 8: 37-41, 1999.
- 5 Larini A, Bianchi L, Bocci V: The ozone tolerance: I) Enhancement of antioxidant enzymes is ozone dose-dependent in Jurkat cells. *Free Radical Research* 37: 1163-1168, 2003.
- 6 Bocci V, Larini A, Micheli V: Restoration of normoxia by ozone therapy controls neoplastic growth: a review and a working hypothesis. *J. Alt. Compl. Medicine* 11: 257-265, 2005.
- 7 Valacchi G, Bocci V: Studies on the biological effects of ozone: 11. Release of factors from human endothelial cells. *Mediat. Inflamm* 9: 271-276, 2000.
- 8 Bocci V, Paulesu L: Studies on the biological effects of ozone 1. Induction of interferon gamma on human leucocytes. *Haematologica* 75: 510-515, 1990.
- 9 Bocci V, Luzzi E, Corradeschi F et Al: Studies on the biological effects of ozone: 3. An attempt to define conditions for optimal induction of cytokines. *Lymphokine Cytokine Res* 12: 121-126, 1993.
- 10 Bocci V, Valacchi G, Corradeschi F et Al: Studies on the biological effects of ozone: 7. Generation of reactive oxygen species (ROS) after exposure of human blood to ozone. *J Biol Regulat Homeost Agent* 12: 67-75, 1998.
- 11 Bocci V, Valacchi G, Corradeschi F et Al: Studies on the biological effects of ozone: 8. Effects on the total antioxidant status and on interleukin-8 production. *Mediat Inflamm* 7: 313-317, 1998.
- 12 Bocci V: Roles of interferon produced in physiological conditions. A speculative review. *Immunology* 64: 1-9, 1988.
- 13 Bocci V, Valacchi G, Rossi R et Al: Studies on the biological effects of ozone: 9. Effects of ozone on human platelets. *Platelets* 10: 110-116, 1999.
- 14 Valacchi G, Bocci, V: Studies on the biological effects of ozone: 10: Release of factors from ozonated human platelets. *Mediat. Inflamm* 8: 205-209, 1999.
- 15 Bochkov VN, Leitinger N: Anti-inflammatory properties of lipid oxidation products. *J Mol Med* 81: 613-626, 2003.
- 16 Mendiratta S, Qu Z-C, May JM: Erythrocyte ascorbate recycling: antioxidant effects in blood. *Free Rad. Biol. Med.* 24: 789-797, 1998..

Prof. Velio Bocci
Dipartimento di Fisiologia
Via A. Moro 2
53100 Siena - Italy
Tel: +39 (0) 577 234226
Fax: +39 (0) 577 234219
E-mail: bocci@unisi.it

Effect of Major Autohaemotherapy with Oxygen-Ozone on the Anaerobic Threshold in Athletes

A. GJONOVICH*, G. SALLUSTI*, A. BRUSOMINI**

* Pain Therapy and Palliative Care Units, Local Health Trust 17; Este-Monselice Veneto Region, Italy

** Specialist in Sports Medicine

Key words: oxygen-ozone, anaerobic threshold, autohaemotherapy

SUMMARY – We investigated the clinical capacity to increase the delivery of oxygen to tissues by major autohaemotherapy (MAHT) with oxygen-ozone. Eight top level amateur athletes were enrolled in the study. Their anaerobic threshold was periodically tested by the Conconi test during a cycle of MAHT. A clear-cut shift of the curve to the right was observed in six athletes indicating enhanced peripheral oxygenation. Although the number of subjects is limited, this study offers further confirmation that peripheral oxygen delivery can be enhanced by MAHT. The clinical use of MAHT is a valid treatment for diseases characterized by a reduced tissue uptake of oxygen.

Introduction

We undertook a clinical investigation of some of the most important actions of oxygen-ozone therapy, namely its effects on:

1. Peripheral oxygen delivery
2. Intra-erythrocyte 2,3-diphosphoglycerate concentration
3. Glucide metabolism.

The anaerobic threshold (AT) was measured by the Conconi test in amateur athlete volunteers undergoing oxygen-ozone therapy.

According to the literature, oxygen-ozone therapy can trigger major biochemical reactions. In particular, it can induce the peroxidation of membrane phospholipids in red blood cells⁵ with shortening of lipid chains and subsequent membrane relaxation associated with an increase in negative charges on the erythrocyte surface. This has a major anti-sludge effect resulting in reduced viscosity. The increased permeability of the erythrocyte membrane allows greater diffusion of oxygen through its membrane. In addition, ozone affects different metabolisms, especially the glucidic metabolism where mediated by coenzymes it speeds up anaerobic glycolysis resulting in increased ATP. Thanks also to the pentosophosphates cycle, there is an increased erythrocyte concentration of 2,3-diphosphoglycerate with a clear-cut effect on the haemoglobin dissociation curve. The enhanced peripheral delivery of oxygen is confirmed by a peripheral reduction in the partial pressure of venous oxygen (< 20 mm/Hg)

rather than an increase in PaO₂. These biochemical and metabolic findings account for the fact that one of the main clinical applications of oxygen-ozone therapy is in peripheral arteriopathy. We aimed to confirm the known improvement in cell homeostasis and oxygenation assessing if and to what extent oxygen-ozone therapy influences the anaerobic threshold in athletes. Anaerobic threshold is a basic concept in sports medicine. To define a person's "aerobic strength" the maximum oxygen consumption (VO₂ MAX) is usually measured by cumbersome expensive equipment. However, there is no close correlation between VO₂ MAX and the athlete's performance even in endurance competitions. The anaerobic threshold (AT) offers more valid indications on an athlete's performance². This value expresses exercise intensity corresponding to the highest percentage of VO₂ MAX used without affecting lactic acid type energy recharge mechanisms. It is well documented that during physical exercise the body uses mixtures of glucose and fatty acids which become increasingly rich in glucose as exercise intensity increases. When the aerobic potential is almost completely used up, further increases in exercise intensity will be maintained by the anaerobic-lactic acid metabolism. Hence AT is defined as the exercise intensity triggering the anaerobic mechanism. Its value varies from one individual to another, and also depends on the individual's genetic characteristics. AT also varies in the same individual depending on his/her degree of training³. From a practical standpoint, AT is the

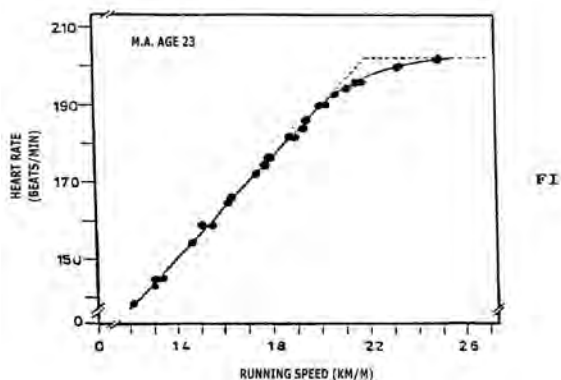


Figure 1 Conconi Test.

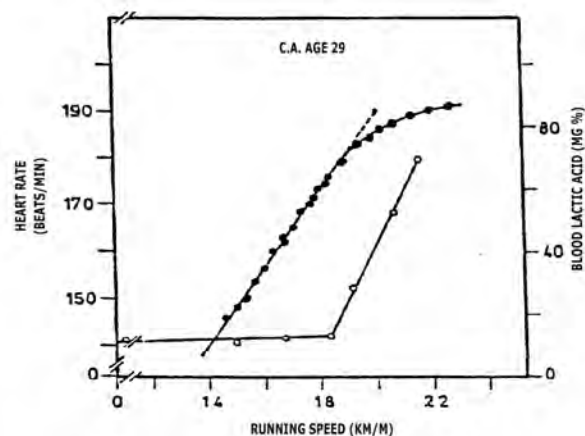


Figure 2 Anaerobic Threshold: Heart Rate And Blood Lactic Acid Ratio.

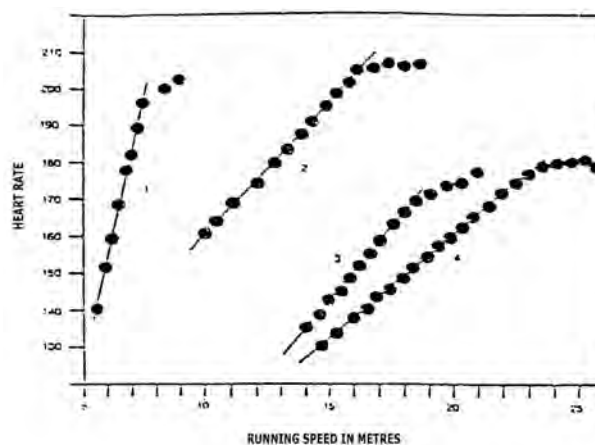


Figure 3 At: Interindividual Changes 1 Sedentary, 2 Athlete, 3-4 High Level Athlete.

level at which anaerobic glycolysis is triggered with a consequent accumulation of lactates in order to increase muscle exercise and hence athletic performance. This may be one of the factors limiting complete use of VO_2 MAX or reducing its percentage use. Different methods have been advocated to measure AT such as the relation between increasing exercise intensity and corresponding blood lactate concentrations. In the early Eighties an invasive method was developed for AT determination based on a simple principle: as there is a linear relation between oxygen consumption and heart rate, and an identical relation between oxygen consumption and running speed, there may be a linear relation between heart rate and running speed. This is the principle underlying the Conconi test which consists in a graphic study of the relation between heart rate and running speed. The line had a linear trend (figure 1) up to the point at which exercise intensity becomes high enough to trigger anaerobic glycolysis which is irrespective of both oxygen transport and heart rate⁴. Anaerobic glycolysis is

thought to cause the loss of straight line linearity, i.e. there is an increase in speed without an increase in heart rate. The coincidence between linearity deflection speed and anaerobic threshold has been proved with a correlation index of 0.99³. It has also been demonstrated⁶ that linear deflection coincides with a major increase in plasma lactate concentration (figure 2). Figure 3 shows an example of four different anaerobic thresholds ranging from a sedentary subject to an Olympic athlete. The Conconi test is routinely used to measure an athlete's initial AT. Subsequent control tests are very useful to direct and monitor training and to yield useful indications on competition speed.

Material and Methods

To date we have studied eight volunteer high level amateur athletes, six men and two women, selected by a sports medicine specialist. All athletes practice endurance sports (cycling, skating,

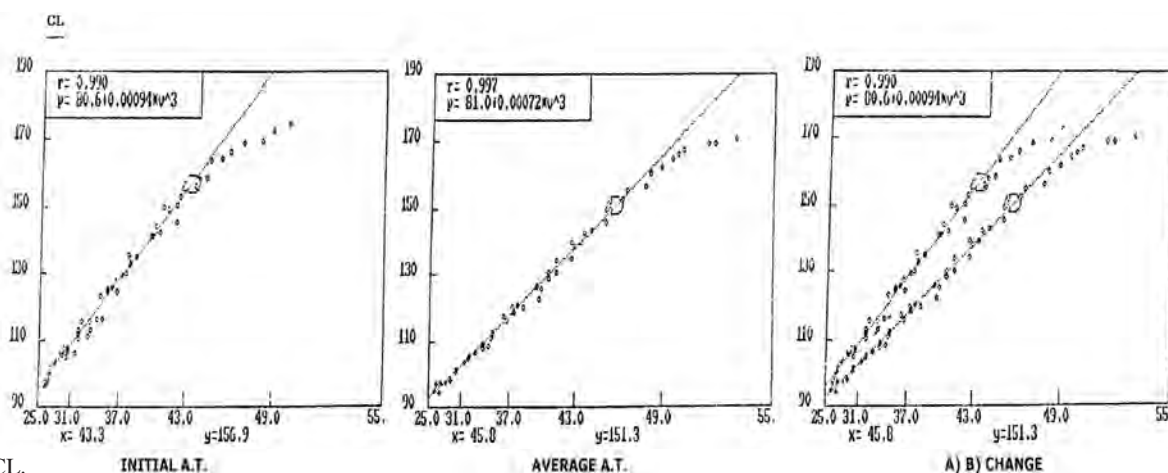


Figure 4 CL.

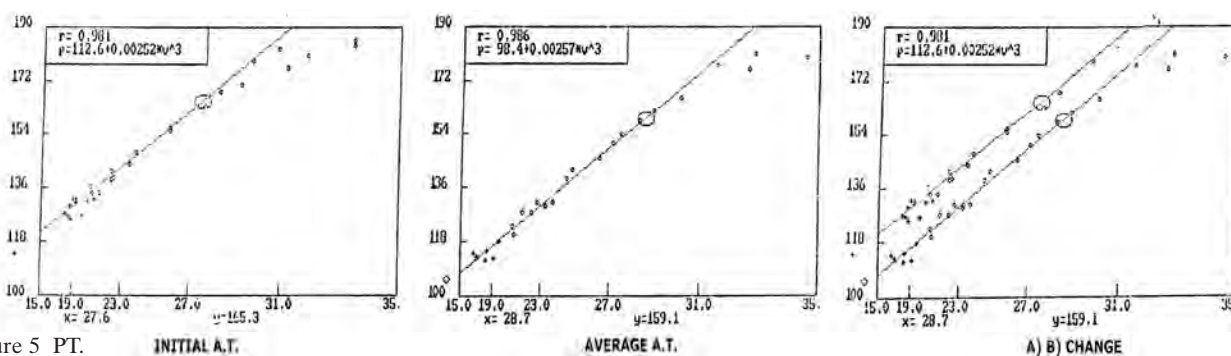


Figure 5 PT.

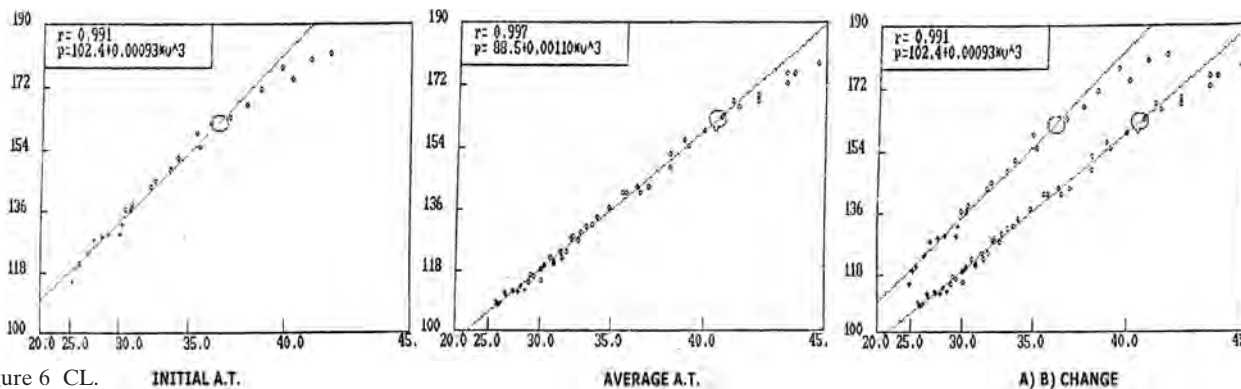


Figure 6 CL.

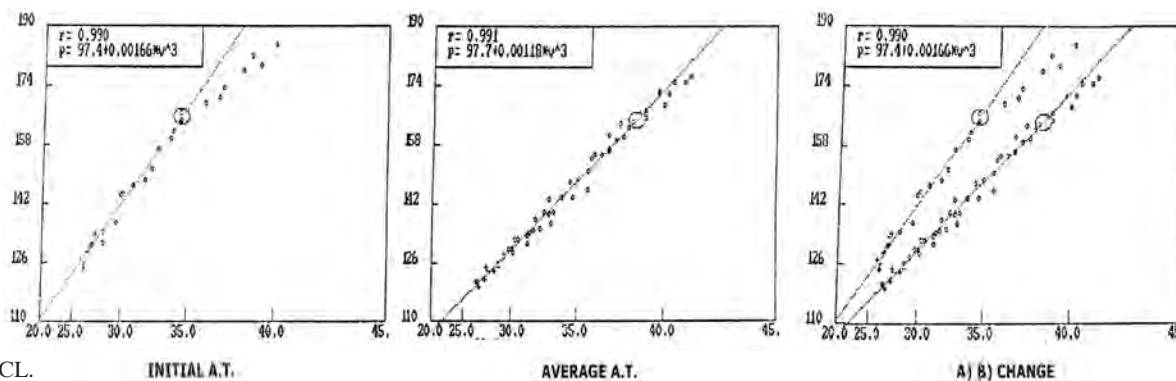


Figure 7 CL.

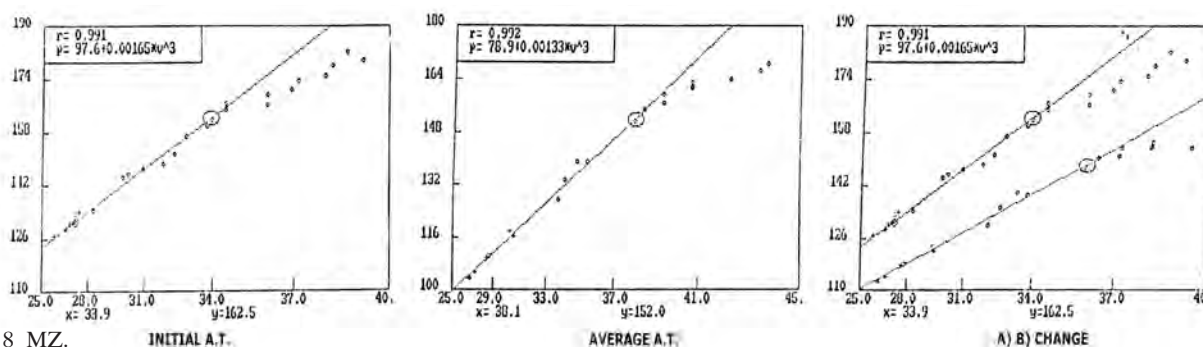


Figure 8 MZ.

canoeing) and on enrolment they were in excellent training condition. The athletes were monitored for a period of four months and underwent an initial Conconi test and at least three subsequent controls during the observation period. In previous years all athletes had undergone the Conconi test to establish their AT. Each athlete was administered MAHT by the standard method using an E 30 Ozon-Line device: 150-200 ml are taken and mixed with 150 ml of oxygen-ozone mixture at an O_3 concentration of 30 gamma/ml; the gas mixture was then reinfused over a period of 15 minutes. MAHT was performed at three day intervals up to a total of four consecutive applications. After a 20/30 day interval another two cycles of three MAHT were administered up to a total of ten sessions throughout the period of observation. As no specific oxygen-ozone concentration is given in the literature, we kept to our long-standing clinical experience in the field of peripheral arteriopathy^{1,7,8}. As we were using the method on healthy subjects, we chose a concentration of 30 gamma/ml deemed low-average for peripheral arteriopathy. In addition to the initial Conconi test, the first follow-up was carried out after the fourth MAHT. Subsequent controls were regularly spread over the following three months. All volunteers gave their informed consent on enrolment in the study. Seven tests were carried out on a bicycle mounted on rollers, one directly on the field. All athletes wore a heart rate monitor with a memory subsequently decoded. The results were processed and assessed by the sports medicine specialist. The AT and the slope of the curve were taken as parameters for assessment of the Conconi test. The effect on the threshold was deemed positive when it coincided with a rightward shift of the line.

Results

Only two of the eight athletes studied had a negative response to MAHT with an unchanged curve

both during and after the protocol. The rise in AT in the remaining six athletes was demonstrated by a clear rightwards shift of the curve. Figures 4-9 show a detailed analysis of initial AT and final AT for each athlete. Final AT is construed as the average threshold obtained in the three follow-up Conconi tests. Figure 9 shows an example of an intermediate threshold.

None of the athletes presented any side effects or unforeseen reactions and the method was well tolerated.

At the first follow-up after the fourth MAHT session, the rightward shift was already clearly evident and subsequent changes were less radical showing a good stabilization. It is noteworthy that heart rate was reduced in four athletes with respect to initial values.

Discussion

The fact that a cycle of MAHT had an effect on AT is further evidence of how oxygen-ozone therapy interacts at several levels. On the one hand the treatment allows the aerobic reserve to be fully exploited by boosting metabolism; on the other it ensures enhanced peripheral delivery of oxygen also by virtue of its effect on erythrocyte 2,3-diphosphoglycerate.

The experience of our athletes and the assessment of trainers and the sports medicine specialist disclosed a slight reduction in performance on the day after MAHT in three athletes. This effect was attenuated after the first treatment sessions and suggests that healthy subjects require an initial phase of adaptation to therapy.

In the future it would be interesting to determine the effects of oxygen-ozone concentrations higher than 30 gamma/ml in the same athletes using the same test.

This would establish whether oxygen concentration is correlated to changes in AT.

Another problem is the duration of the effect.

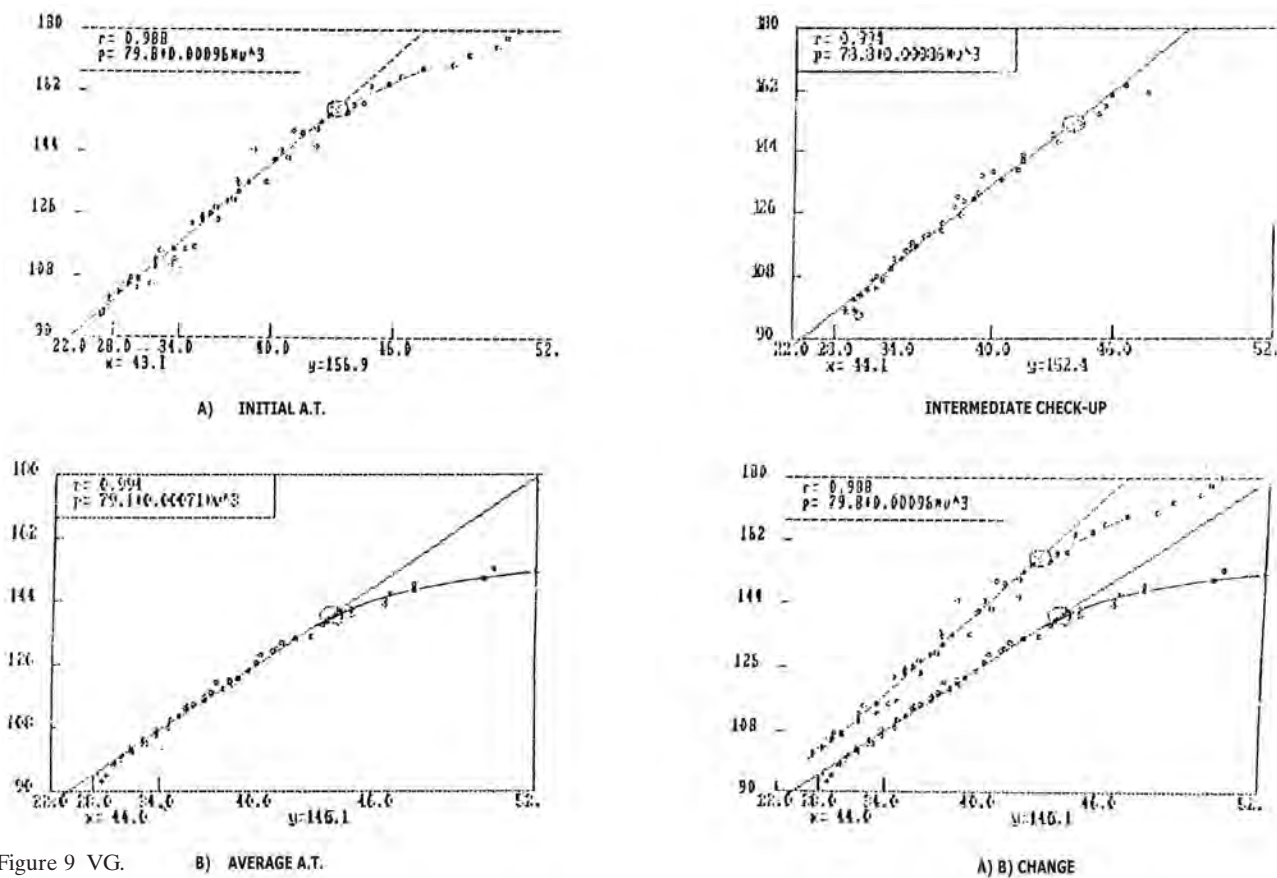


Figure 9 VG.

B) AVERAGE A.T.

A) B) CHANGE

Currently available evidence indicates that the benefits of MAHT last for at least two months after the end of the protocol.

Apart from the objective findings of the Conconi test, the volunteers also had a subjective sensation which is very important in treating highly sensitive athletes.

In addition to a subjective feeling of well-being

and "lightness in the legs", our athletes had much shorter recovery times. This could be due to both the raised AT and the frequent drop in heart rate during exercise.

Although confined to a small cohort, our findings further confirm the usefulness of oxygen-ozone therapy by MAHT in all diseases characterized by reduced peripheral oxygen delivery.

References

- 1 Bocci V: Ossigeno-ozono terapia. Casa editrice Ambrosiana 2000.
- 2 Conconi F et Al: Noninvasive determination of the anaerobic threshold in swimming. *Int. J. Sports Med.* 7: 347-351, 1986.
- 3 Conconi F et Al: Noninvasive determination of the anaerobic threshold in canoeing, cross-country skiing, cycling, roller, and iceskating, rowing and walking. *Eur. J. Appl. Physiol* 53: 299-303 1985.
- 4 Conconi F et Al: Un test da campo per la determinazione della soglia anaerobica nell'uomo. *Boll. Soc. It. Biol. Sper.* Vol. LVI, 1980.
- 5 Coppola L. et Al: Oxygen-Ozone therapy and haemorheological parameters in peripheral chronic arterial occlusive disease. *Trombosi e Arteriosclerosi* Vol. 3 n. 2 mar-apr 1992.
- 6 Green et Al: Anaerobic threshold, blood lactate and muscle metabolites in progressive exercises. *J. Appl. Physiol.: Respirat. Environm Exercise Physiol* 54: 1032-1038, 1993.
- 7 R. Matassi: Ozonoterapia. Organizzazione Editoriale

Dr A. Gjonovich
UOC Terapia del Dolore e Cure Palliative
USL 17 Regione Veneto
C.so Vittorio Emanuele, 15
35123 Padova
Tel. 049 8754347 - 8801910

Initial Experience of Oxygen-Ozone Treatment for Disc Herniation in Bolivia

A Report of 120 Cases

R. ALVARADO* J. JIMENEZ**

*Neurosurgeon Arco Iris Hospital and Police Hospital; La Paz, Bolivia

** Medical student of Nuestra Señora de La Paz University; La Paz, Bolivia

Key words: lumbar disc herniation, ozone therapy, paravertebral percutaneous treatment, cervical discolysis

SUMMARY – We describe our initial experience using an oxygen-ozone mixture to treat herniated cervical and lumbar discs in Bolivia from August 2003 to June 2005. In all the 120 patients were treated. Despite the limited number of cases our experience provided statistically significant conclusions.

Introduction

The application of ozone (O₂-O₃) in the treatment of cervical and lumbar disc herniation is a widely used treatment in Europe. Our is the first experience of this therapy in Bolivia.

A herniated disc is accompanied by mechanical factors¹ and in the last years evidence of biochemical or immunological² alterations has also emerged.

Lumbar disc herniation is commonly responsible for low back pain and the condition for which spinal surgery is carried out most frequently³.

There is evidence that many patients with symptoms of nerve root compression from disc herniation will get better using conservative methods such as physiotherapy, and the herniation will eventually disappear in a few months. In addition, patients with known disc herniation live with their lesion in between pain attacks, even though the morphology of the disc lesion remains unchanged on CT and/or MRI controls.

For over fifty years neurosurgeons have been searching for a method which would allow shrinkage of herniated or protruded discs to solve the problem of pain. Although disc compression is corrected by surgery many patients continue to feel pain either attenuated or even exacerbated, irrespective of the structural changes of the disc herniation disclosed by CT and/or MRI scans after the operation⁴.

A number of non invasive percutaneous techniques have been conceived which aim to remove and/or cause shrinkage of the discal tissue. The common principle of these techniques is that of acting directly on the disc structure without access

to the spinal canal to eliminate the possibility of scar tissue forming in the epidural space, which would cause compression of the nervous tissue and adhere to the moving bones.

Much research has been done on the various aspects of disc pathology, and on the possible solution to the problem. Studies on pain originating from disc disease show that it may be a consequence of biochemical mechanisms of acid intoxication of the nerve. These may somehow be independent from the mechanical problem, but depend on an autoimmune reaction producing a chronic inflammatory response which engenders an acid environment, or a situation of ischemia⁵.

A mixture of O₂-O₃ has been used in medicine since 1985 to treat herniated disc. The effect ozone is thought to have in the herniated disc as such is based on the biochemical composition of the intervertebral disc mainly composed of proteoglycans and collagen⁶.

Hence the nucleus pulposus and the herniated disc are complex macromolecular structures containing water linked to various hydrophilic matrices. Because of its solubility and pressure, once injected into the disc, ozone dissolves in the intradiscal water and immediately decomposes generating a ROS cascade⁷.

Patients and Methods

Our study reports the first experience in Bolivia August 2003 and June 2005. We treated 120 patients by intradiscal injection of ozone in cervical herniated discs, and paravertebral injection in lumbar herniated discs.

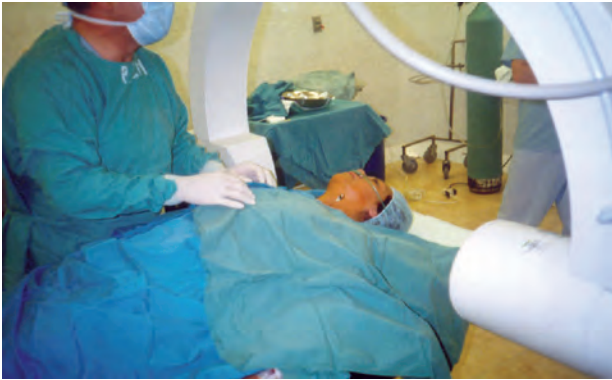

Figure 1 Preparing the patient.

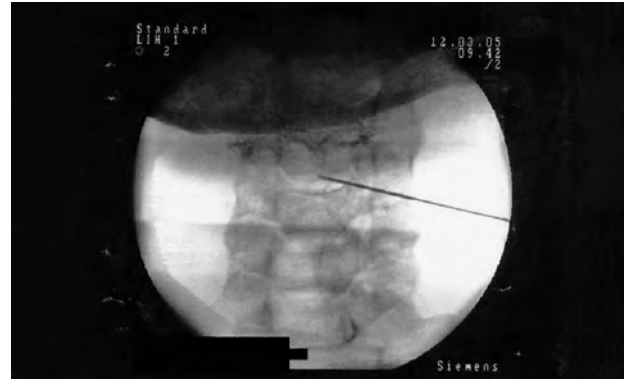


Figure 2 Anteroposterior fluoroscopic imaging to check correct placement of the needle in the disc.

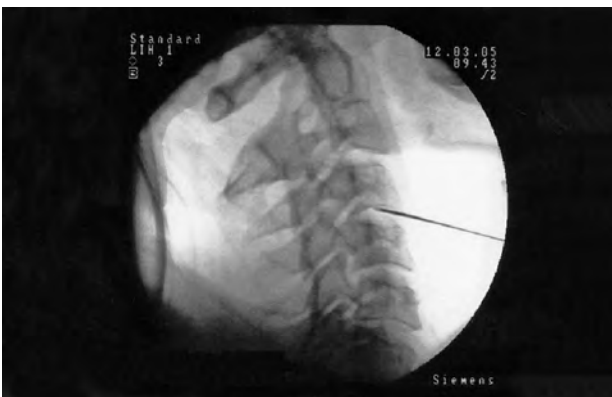

Figure 3 Laterolateral fluoroscopic imaging to check correct placement of the needle in the disc.

All patients with diagnostically confirmed cervical and lumbar discs herniation, diagnostic verification by CT and/or MR scans exhibiting the disc herniation or protrusion with nerve root compression.

Steroidal drugs were not administered as the prospect of solving the problem without drugs or conventional surgical treatment was offered to the patients who accepted after detailed explanation.

We used the intradiscal approach for the cervical region and the classical technique of paravertebral percutaneous infiltration for lumbar disc herniation.

For the treatment of cervical herniated disc, the patient is positioned on the surgical bed face up with a cushion under the cervical region in a sterile surgical operating room.

After deep sedation by Propofol under C type arm X ray surveillance, the disc is punctured with a 22G 3 1/2 spinal needle. The tip of the needle has to reach the middle of the disc.

The entire procedure was done under continuous fluoroscopic control (figure 1).

Once in place the position was confirmed by lateral and anteroposterior imaging (figure 2-3) 7 to 10 ml of O₂-O₃ at 30-40 micrograms/ml was injected

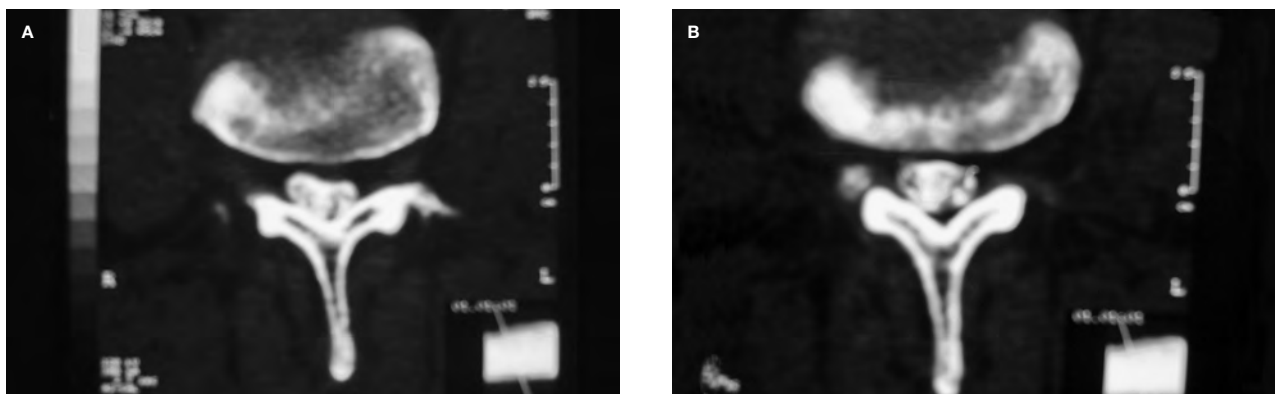


Figure 4 (A) Right herniated disc L3-L4. (B) The herniation has completely disappeared at CT follow up four months after oxygen-ozone treatment.

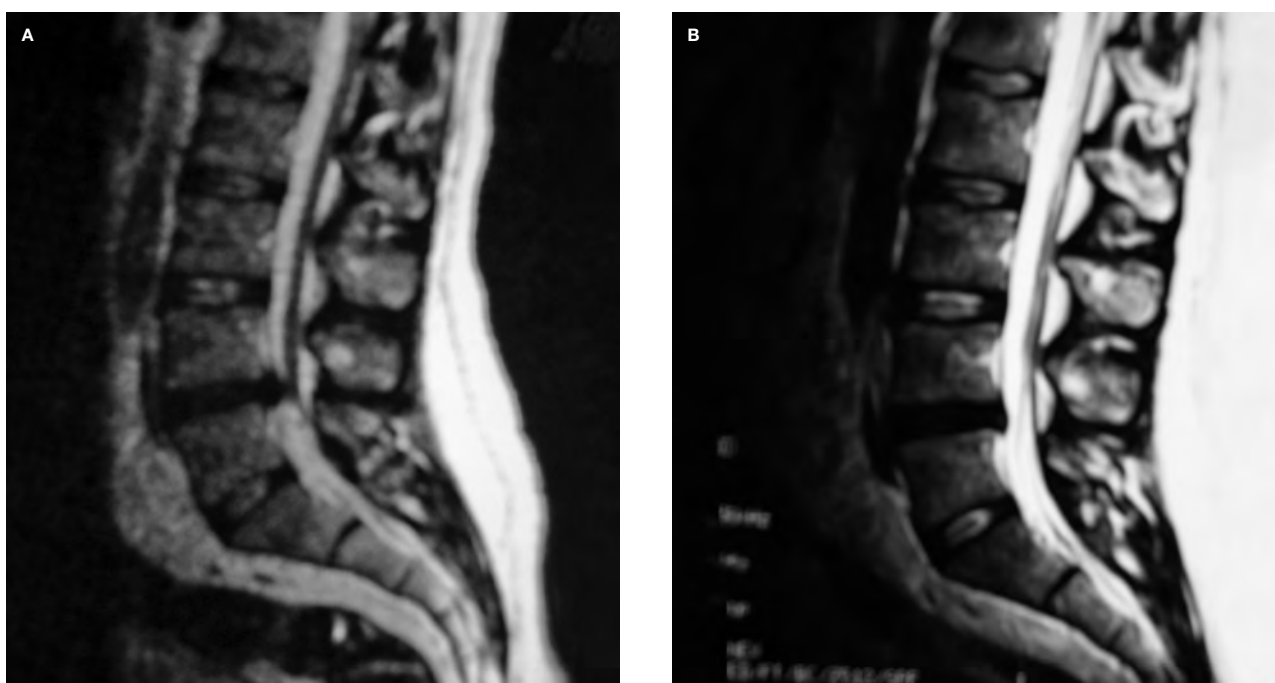


Figure 5 (A) Large herniated disc L4-L5. (B) Follow-up MRI four months after oxygen-ozone treatment showing complete disappearance of the disc herniation.

into the inside of the lesioned disc. The patient was discharged on the day after the procedure.

For lumbar herniated disc we used the classical technique of percutaneous infiltration that is possible only with CT and /or MR imaging and simple X ray investigation of the lumbosacral spine to ascertain and confirm the anatomic levels affected by disease and the reference points on the skin surface. After confirming the lesion levels the skin is marked and the treatment starts.

The lumbar reference points refer to the bisiliac line and the relative spinous process, moving about 3-3.5 cm.

From the apophysis the needle is inserted with precision.

The treatment is bilateral divided into four sites of injection of O_2-O_3 in the paravertebral area, two above and two below the metametric level of the pathology.

The concentration used is 30-40 micrograms/ml with the administration in each point of 20 ml of O_2-O_3 . A 20 ml syringe is used with a TSK STERIJECT or TERUMO 21 G \times 2". We performed 20 sessions twice a week. The results were evaluated four or five months after the treatment was completed (figures 4, 5).

Results

Among the 120 patients (68 males and 52 females), 17 were treated for cervical discs and 103 for lumbar discs. The clinical effectiveness was evaluated and patients were followed up from four to eight months. Among the "cervical group" pain symptomatology and sensory dysfunction was completely abolished in 16 cases (94%) and improved in one case (5.8%). In the "lumbar group" excellent results were obtained in 71 patients (68%) good and satisfactory results in 15 patients (15%) and the result was poor with the dysfunction remained unchanged in 17 patients (16.5%). Eight patients from the latter group underwent surgical treatment and nine refused surgery. As a whole 86 patients obtained excellent and good results (82.4%).

Discussion and Conclusion

The surgical techniques used to treat cervical and lumbar discs herniation by relieving root compression often fail to provide a definitive or lasting

cure even in selected patients. In our experience administering oxygen-ozone therapy we obtained excellent and good results in 82.4% of patients.

Ozone therapy for the treatment of the cervical and lumbar herniated discs is a wonderful new alternative to surgery.

Accurate patient selection for this therapeutic alternative is very important to obtain good results, to avoid complications and avoid a negative outcome.

The effectiveness in using ozone therapy shows that with this method we can obtain very good results with minimum trauma and no complication. In addition ozone therapy is a very cheap treatment especially for third world countries such as Bolivia.

Acknowledgement

We thank Dr Hector Giocoli former president of the Latin-American Federation of Neurosurgical Societies who introduced us to ozone therapy and gave useful advice.

References

- 1 Resnick D, Niwayama G: Diagnosis of bone and joint disorders W.B. Saunders, Philadelphia PA 1988.
- 2 Takahashi H et Al: Inflammatory cytokines in the herniated disc of the lumbar spine. *Spine* 21: 218-224, 1996.
- 3 Postacchini F: Lumbar disc herniation. A new equilibrium is needed between nonoperative and operative treatment. *Spine* 26: 601-2001.
- 4 Simonetti L, Agati R: Why does disc root conflict generate pain? *Rivista di Neuroradiologia* 11: 403-404, 1998.
- 5 Saal J, Saal JS, Hersog R: The natural history of the lumbar intervertebral disc extrusion treated nonoperatively. *Spine* 15: 683-688, 1990.
- 6 Leonardi M, Simonetti L, Agati R: Neuroradiology of spine degenerative disease. *Best Practice & Research Clinical Rheumatology* 16: 59-88, 2002.
- 7 Bocci V: Ossigeno Ozonoterapia. Casa Editrice Ambrosiana, Milano 2000.

Dr Ramiro Alvarado
Casilla 1701
La Paz Bolivia
E-mail: ralvarado@accelerate.com

Intraforaminal O₂-O₃ Infiltration: Use of CT Guidance in Case of Accidental Puncture of the Periganglionic Venous Plexus

F. ALBERTINI, M. BONETTI*

Neuroradiology Service, Istituto Clinico S. Anna; Brescia, Italy

* Neuroradiology Service, Istituto Clinico Città di Brescia; Brescia, Italy

Key words: oxygen-ozone therapy, intraforaminal injection, local embolism

SUMMARY - We describe a patient with a left preforaminal L2-L3 herniated disc treated with oxygen-ozone therapy under CT guidance. The gas mixture was infiltrated using appropriate precautions following specific guidelines. Despite this, a local embolism developed with gas emboli in some stretches of the external and internal venous plexus involving the basivertebral vein and its branches. CT guidance proved particularly useful in depicting the presence of gas in anatomical locations other than the foraminal and periganglionic areas. This study confirms the need to use small volumes of O₂-O₃ which are still effective and avoid needless risks in case of inappropriate distribution of the gas mixture.

Introduction

The growing recent use of radiologically guided infiltration procedures has increased the safety and efficacy of ozone therapy to treat herniated discs. One of the important features of CT use in controlling O₂-O₃ infiltration is visualizing the distribution of the gas mixture in the foraminal region under treatment and to check for any anomalous gas leaks at epidural and/or vascular level.

We describe the case of a local embolism after right L2-L3 foraminal O₂-O₃ infiltration with the demonstration of gas emboli in some stretches of the external and internal venous plexus, involving the basivertebral vein and its branches. The gas leak was probably caused by accidental puncture of the intervertebral vein and/or radicular veins which are non collapsible resulting in local embolization. The leak occurred despite the extreme care taken in positioning the needle and performing the aspiration manoeuvre. This incident offers further proof of the importance of using small volumes of gas for effective treatment of herniated disc avoiding the major problems linked to embolism in case of O₂-O₃ leakage.

Case Report

A 58-year-old man presented with left low back pain due to a preforaminal L2-L3 herniated disc demonstrated by recent magnetic resonance scan

(figure 1 A,B). Given the clinical and radiological coincidence between the level of the herniation and the patient's symptoms, treatment with CT guided foraminal O₂-O₃ infiltration was decided according to the standard procedure³. The patient was placed in a prone position on the CT table and a lateral view topogram was obtained with subsequent accurate localisation of the established level. After the necessary measurements and careful disinfection and local anaesthesia, a 22 G 9 cm needle was inserted at an entry angle of 45° down to the foraminal region to be treated. According to the usual procedure, an aspiration manoeuvre was performed with the syringe before O₂-O₃ infiltration. Then a *total volume of 8-10 ml* gas mixture at a concentration of 27 micrograms/ml was injected *slowly*¹².

Distribution of the gas mixture was subsequently checked with CT scans which demonstrated the expected filling of the foraminal and ganglionic regions (figure 2 A,B), but also an associated embolism in some stretches of the external and internal venous plexus mainly involving the basivertebral vein and its branches (figure 3 A,B). The patient referred local pain lasting several minutes and was monitored clinically for two hours in a supine position and was contacted by telephone on several occasions some hours and days after the procedure. At outpatient follow-up 12 days later the patient described a rapid and complete disappearance of pain without other symptoms correlated to gas embolism.

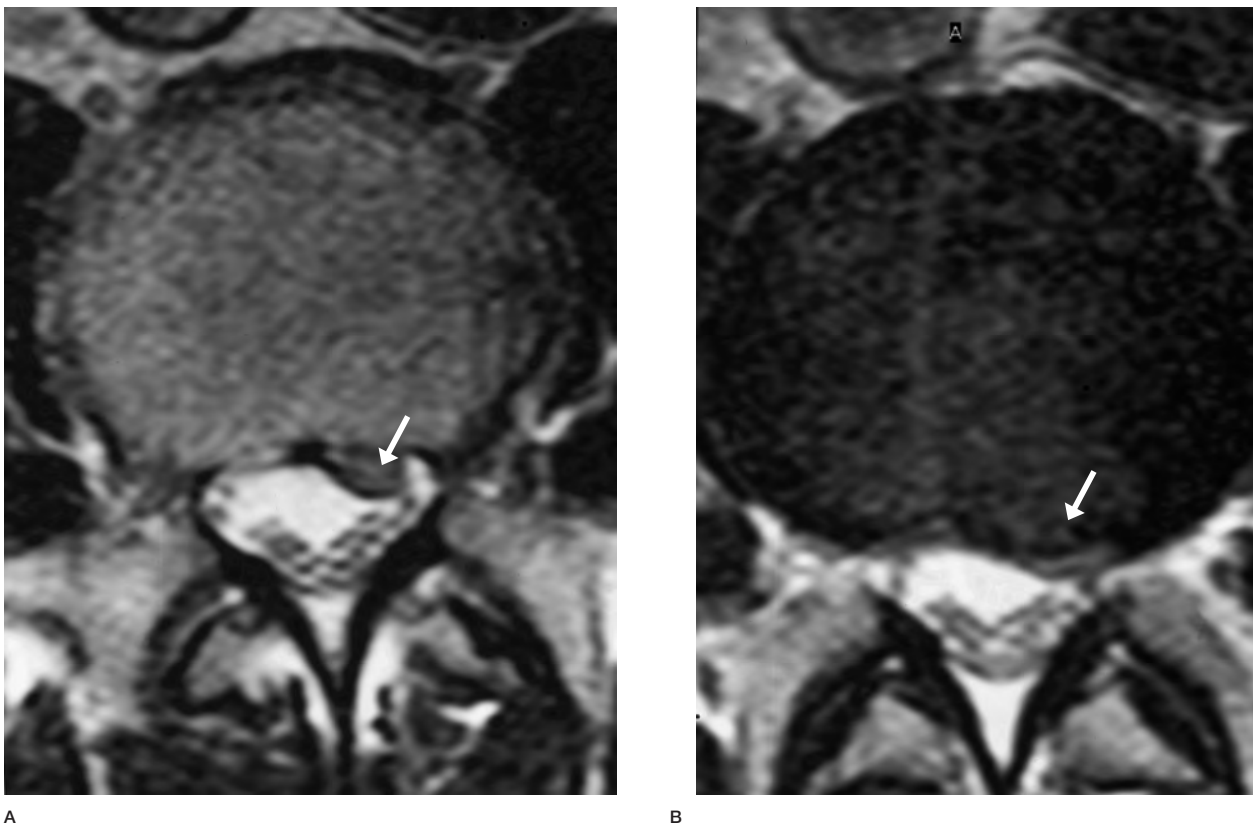


Figure 1 A-B) MR: left preforaminal L2-L3 herniated disc (arrows).

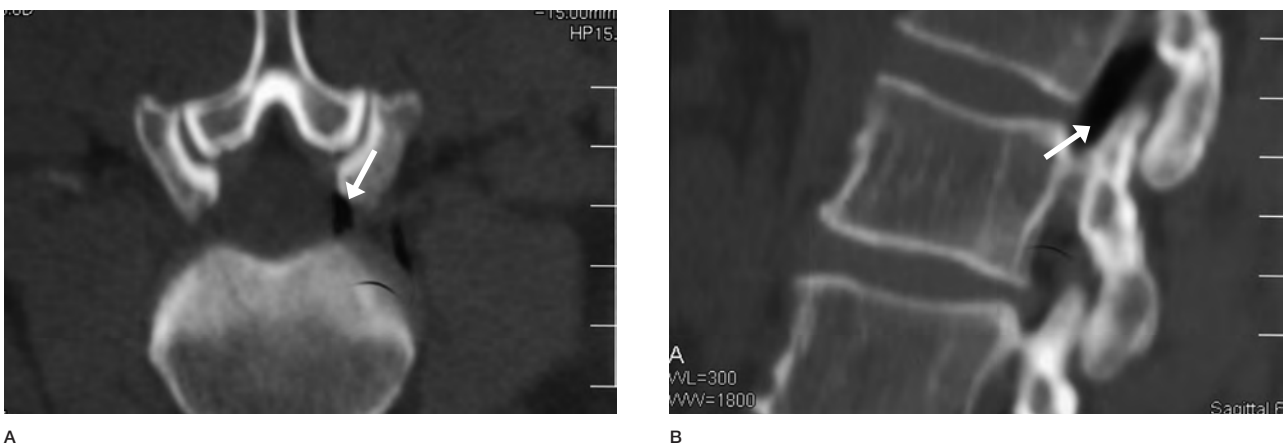

Figure 2 A) CT axial scan showing the presence of gas in the foramina region after O₂-O₃ treatment (arrows). B) CT sagittal reconstruction confirming the gas mixture in the left L2-L3 root canal (arrows)

Discussion

CT guided intraforaminal O₂-O₃ infiltration resolves pain from the first treatment session and has rapid effects on nerve root compression^{1,3,4,6,9,11}. This is largely due to the possibility of delivering the gas mixture very close to the diseased area, improving the local circulation and normalizing

cytokine and prostaglandin levels (anti-inflammatory and analgesic effect). Ozone also has a direct effect on the disc accelerating dehydration and hence disc shrinkage (attenuated mechanical effect)^{2,5,7,10,11}.

According to the technique adopted the needle tip is positioned as close as possible to the root canal. This small oval structure is made up anteriorly

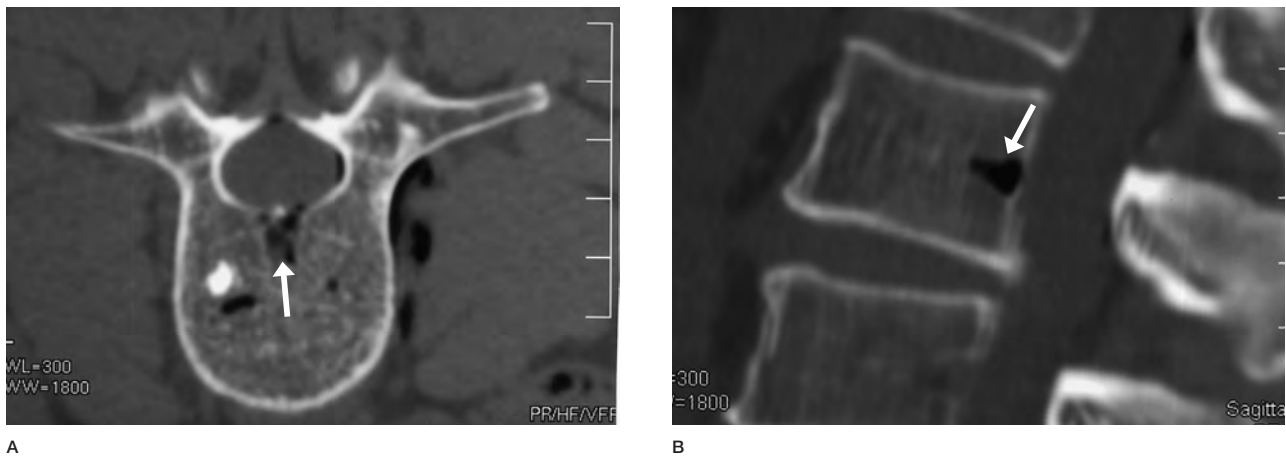


Figure 3 CT image of gas embolism in the basivertebral vein (arrows).

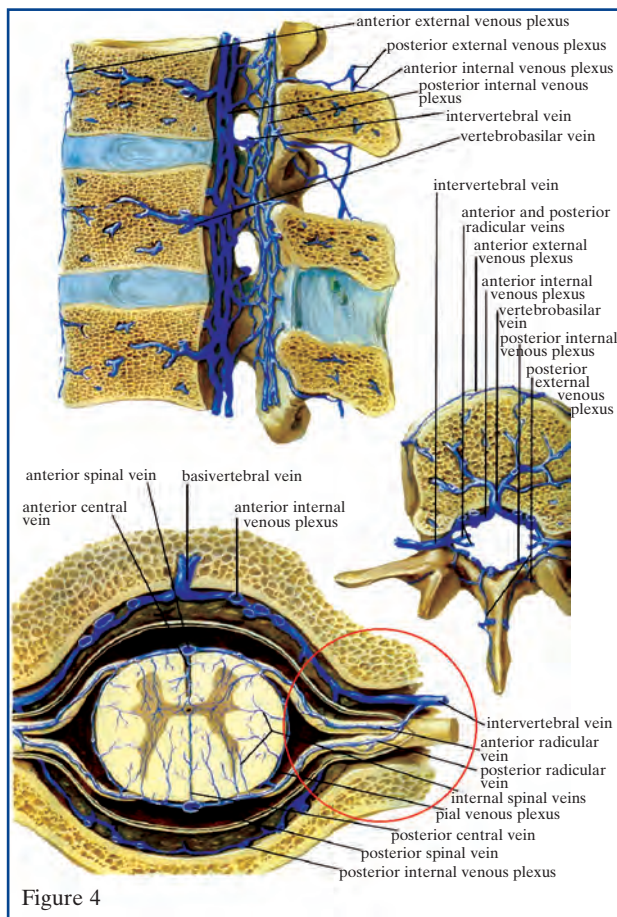
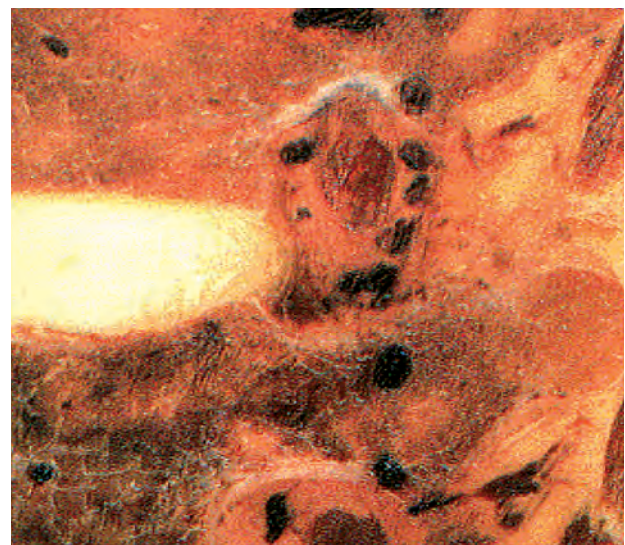
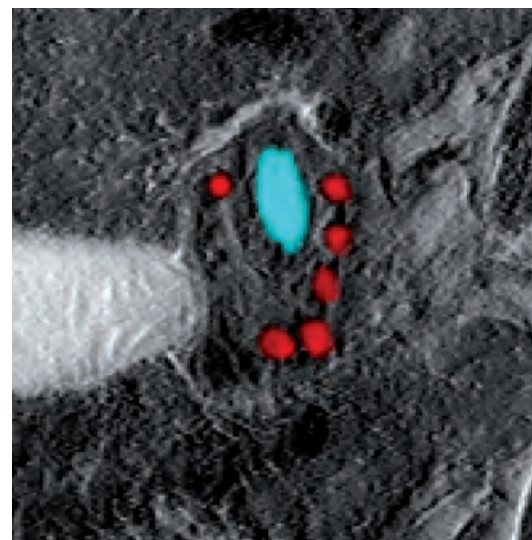


Figure 4

only of the posterolateral margin of the vertebral body and the intervertebral disc, posteriorly the intervertebral joint, superiorly the peduncle of the overlying vertebra and inferiorly the peduncle of the underlying vertebra. The delicate content of the root canal comprises the anterior and posterior nerve roots (with the spinal ganglion) and lower down the radicular artery and veins and the



A



B

Figure 5 Anatomic drawing (from a cadaver) of the root canal: nerve root (blue), venous plexus (red).

intervertebral vein (figure 4). It is understandable how a small part of the O₂-O₃ mixture can pass into the venous vascular district when it is injected close to these structures, despite all the necessary precautions.

No complications of O₂-O₃ therapy have ever been reported in the many case studies published to date^{1,3,4,6,9}.

In the case of possible venous gas embolism the physiological filter of the pulmonary circulation acts as an effective protection against gas volumes below 50 ml and in these cases the venous embolism may go unrecognised. Nonetheless it is important to use low amounts of O₂-O₃ to avoid the risk

of paradoxical emboli which may occur even in the absence of evident intracardiac defects or other detectable shunts^{8,12}.

For this reason we recommend administering the O₂-O₃ mixture at a flow rate below 10 ml/min and at single doses not exceeding 10 ml¹². This is even more important in the case of foraminal infiltrations which allow the mixture to be inserted "only where needed" and hence requiring even smaller gas volumes, but at the same time introducing the gas close to non collapsible veins like the dural venous sinuses and emissary veins of the sinuses.

These precautions will avoid severe complications even if O₂-O₃ leakage does occur.

References

- 1) Andreula CF, Simonetti L et Al: Minimal invasive oxygen-Ozone therapy for lumbar disk herniation. *Am J Neuroradiol* 24: 996-1000, 2003.
- 2) Bocci V: Ozone as a bioregulator. *Pharmacology and toxicology of ozone therapy today. J Biol Regul Homeos Agents* 10: 31-53, 1998.
- 3) Bonetti M : Tecnica intraforaminale TC guidata. *Rivista Italiana di Ossigeno-Ozonoterapia* 1: 69-71, 2002.
- 4) D'Aprile P, Tarantino A et Al: Infiltrazione intraforaminale di O₂-O₃ TC guidata. La nostra esperienza nei conflitti disco-radicolari. *Rivista Italiana di Ossigeno-Ozonoterapia* 3: 37-44, 2004.
- 5) Dall'Aglio R, Gomez M et Al: Biochemical and pharmaceutical aspects of entrapment: the possible role of free radicals and ozone in nerve root compression. *Rivista Italiana di Ossigeno-Ozonoterapia* 3: 105-111, 2004.
- 6) Iliakis E, Bonetti M: Infiltrazione intraforaminale di O₂-O₃ TC guidata 3D. *Rivista di Neuroradiologia* 14: 419-423, 2001.
- 7) Leonardi M, Simonetti L et Al: Effetti dell'ozono sul nucleo polposo: reperti anatomopatologici su un caso operato. *Rivista di Neuroradiologia* 14: 57-59, 2001.
- 8) Muth C, Shank E: Gas embolism. *N Engl J Med* 342: 476-482, 2000.
- 9) Muto M, Andreula CF, Leonardi M: Treatment of herniated lumbar disc by intradiscal and intraforaminal oxygen-ozone injection. *J Neuroradiol* 31: 183-189, 2004.
- 10) Richelmi P, Valdenassi L et Al: Basi farmacologiche dell'azione dell'ossigeno-ozonoterapia. *Rivista di Neuroradiologia* 14: 17-22, 2001.
- 11) Simonetti L, Raffi L et Al: Pharmacological mechanisms underlying oxygen-ozone therapy for herniated disc. *Rivista Italiana di Ossigeno-Ozonoterapia* 2: 7-11, 2003.
- 12) Zambello A, Bianchi M et Al: Sicurezza in Ozonoterapia. *Rivista Italiana di Ossigeno-Ozonoterapia* 3: 25-34, 2004.

Dr F. Albertini
Neuroradiology Service
Istituto Clinico S. Anna
Via del Franzone, 31
25100 Brescia, Italy
E-mail: albertini.fil@tiscali.it

Oxygen-Ozone Therapy for Degenerative Spine Disease in the Elderly

M. BONETTI, A. FONTANA, D. MARDIGHIAN*

*Servizio di Neuroradiologia Istituto Clinico Città di Brescia; * Servizio di Neuroradiologia Spedali Civili di Brescia; Italy*

Key words: oxygen-ozone therapy, medical ozone, spondyloarthrosis, intraforaminal infiltration, elderly

SUMMARY - We describe our experience of oxygen-ozone therapy to treat degenerative spine disease in the elderly. From April 2002 to January 2005 we selected 129 patients with CT and/or MR evidence of spondyloarthrosis and disc degeneration of the lumbar spine. All patients enrolled in the study had contraindications to the administration of commonly used analgaesic and anti-inflammatory drugs. Oxygen-ozone therapy was given by CT-guided intraforaminal injection as the first treatment followed by four weekly paralumbar infiltrations on an outpatient basis. The full treatment lasted a month. Clinical outcome was assessed three months and one year after treatment. The good results obtained indicate that oxygen-ozone therapy is an ideal treatment with no side-effects in elderly patients with degenerative spine disease.

Introduction

Gains in the average life span have been flanked by an exponential increase in degenerative spine disease in the elderly. In particular, spine disease other than disc degeneration (osteophytosis, pseudo-spondylolisthesis, canal stenosis, facet joint syndrome) is increasingly responsible for disability in people who already have other age-related conditions (e.g. endarteritis obliterans of the lower limbs, diabetes, cerebrovascular failure, etc.)^{1,2}.

Concomitant disease is often a factor limiting the administration of analgaesic and anti-inflammatory drugs to relieve the pain caused by degenerative spine disease and hence improve patients' quality of life.

We studied 129 patients aged between 65 and 92 years to assess the therapeutic efficacy of intraforaminal infiltration of an oxygen-ozone gas mixture (O₂-O₃) completed by outpatient paravertebral infiltrations in patients with contraindications to commonly used analgaesic and anti-inflammatory drugs. Clinical outcome was evaluated three months and one year after the end of treatment.

Materials and Methods

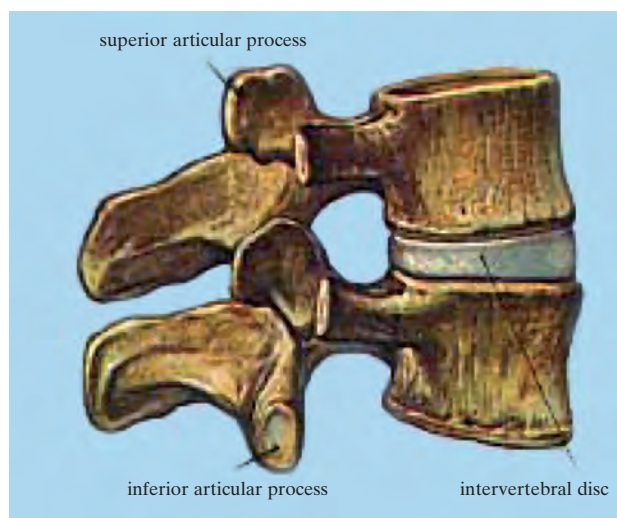
After reading and signing an informed consent form, 129 patients (57 men and 72 women aged between 65 and 93 years, average age 76 years) with chronic low back pain underwent CT-guided

infiltration of an O₂-O₃ gas mixture. Patients were treated between April 2002 and January 2005.

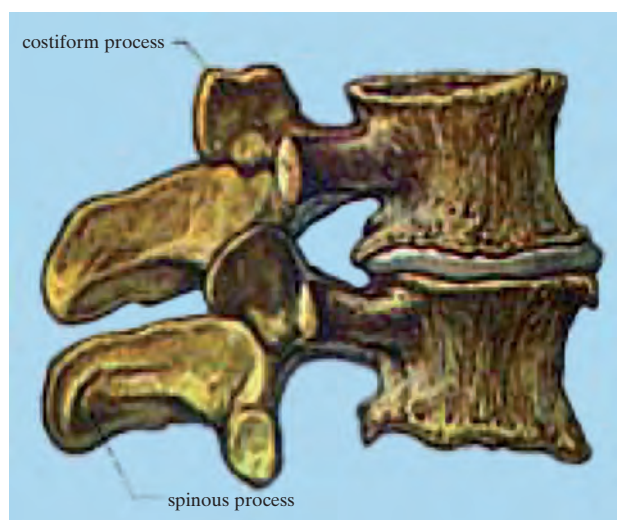
A clinical record was prepared for each patient on enrolment noting age, date of birth, date of enrolment, date of treatment and clinical information on the type of pain, pain irradiation, presence of paraesthesias, Lasègue's sign, degree of sensitivity, lower limb reflexes, plantar and dorsal extension of the foot and dorsal extension of the great toe. All patients had CT or MR evidence of advanced zygo-apophyseal degenerative arthrosis, multiple levels of lumbar disc disease, segmental canal stenosis, pseudo-spondylolisthesis and severe scoliosis. The patients enrolled in the study had chronic unilateral or bilateral low back pain irradiating along the regions innervating the lumbosacral plexus.

Patients with electromyographic evidence of neurogenic injury (diabetic neuropathy) and those with concomitant endarteritis obliterans of the lower limbs with grade II and IV intermittent claudication were excluded from the study.

Before treatment the skin area was disinfected and local anaesthesia administered by ethyl chloride spray in all patients. Infiltrations were performed by specialist neuroradiologists at the Neuroradiology Service at Istituto Clinico Città di Brescia. A CT scan was done to identify the point of infiltration and marked on the skin then the distance from this point to the spinal root canal was measured. A 22 G Terumo needle was positioned 2-3 mm from the foraminal region close to



A



B

Figure 1 Schematic drawing of degenerative disc disease. A) Normal. B) Degenerative arthrosis. In lumbar degenerative arthrosis the vertebrae are deformed: the intervertebral discs are flattened and jut out from the bone surface leading to inflammation which triggers marginal bony proliferation resulting in the patient's pain.

the ganglion of the nerve root to be treated. We usually used a 9 cm needle but a longer needle was used in some cases depending on the patient's size. Another CT scan was then performed to check accurate needle placement.

The O_2-O_3 mixture was injected into the joints in patients with facet joint syndrome or immediately around the joint capsule when it was not possible to reach the intervertebral space (osteophytosis, asymmetric facet joints and particular shape of the joint aperture). Up to three periganglionic infiltra-

tions were made in patients with multiple levels of disease. Infiltration involved injection of 3 cc of the O_2-O_3 gas mixture at 25 $\mu\text{g}/\text{ml}$ then the needle was retracted a few millimetres injecting another 5 cc of the mixture to involve the region surrounding the facet joint.

CT scans were done in all patients to check the correct distribution of the gas mixture in the root canal and facet joint. All treatments were performed using equipment fitted with a photometric detector monitoring the concentration of ozone in the gas mixture.

The treatment cycle was completed with four paravertebral infiltrations given weekly on an outpatient basis.

These infiltrations were done by injecting 10 cc of the O_2-O_3 gas mixture at 25 $\mu\text{g}/\text{ml}$ into each infiltration point using 23 G Terumo needles and a medical ozone device (Alnitec Futura 2) fitted with a photometric detector monitoring the concentration of ozone in the gas mixture. The infiltration point was kept constant at 2 cm from the spinous apophysis of the diseased space. Multiple level treatments were usually performed.

All patients had follow-up checks at three months and one year after treatment. We used a modified version of McNab's method to define clinical outcome as follows:

- excellent: resolution of pain and a return to normal daily activities performed before the onset of pain.
- good or satisfactory: more than 50% reduction of pain.
- mediocre or poor: partial reduction of pain less than 70%.

Results

At three months follow-up 74 (57.3%) patients referred a marked improvement in clinical symptoms with almost complete disappearance of low back pain, whereas 32 (24.8%) were satisfied with the treatment but had only a partial reduction of pain. The treatment produced little or no benefit in 23 (17.9%) of patients.

One year follow-up was done in 127 patients as two had died from natural causes in the meantime. Of these, 43 (33.9%) had maintained an excellent quality of life with an almost complete disappearance of low back pain.

The number of patients with good or satisfactory benefit after treatment had increased to 34 (26.7%); pain had returned but was decidedly less severe than before treatment.

Treatment was deemed mediocre or poor in 50 (39.4%) patients.

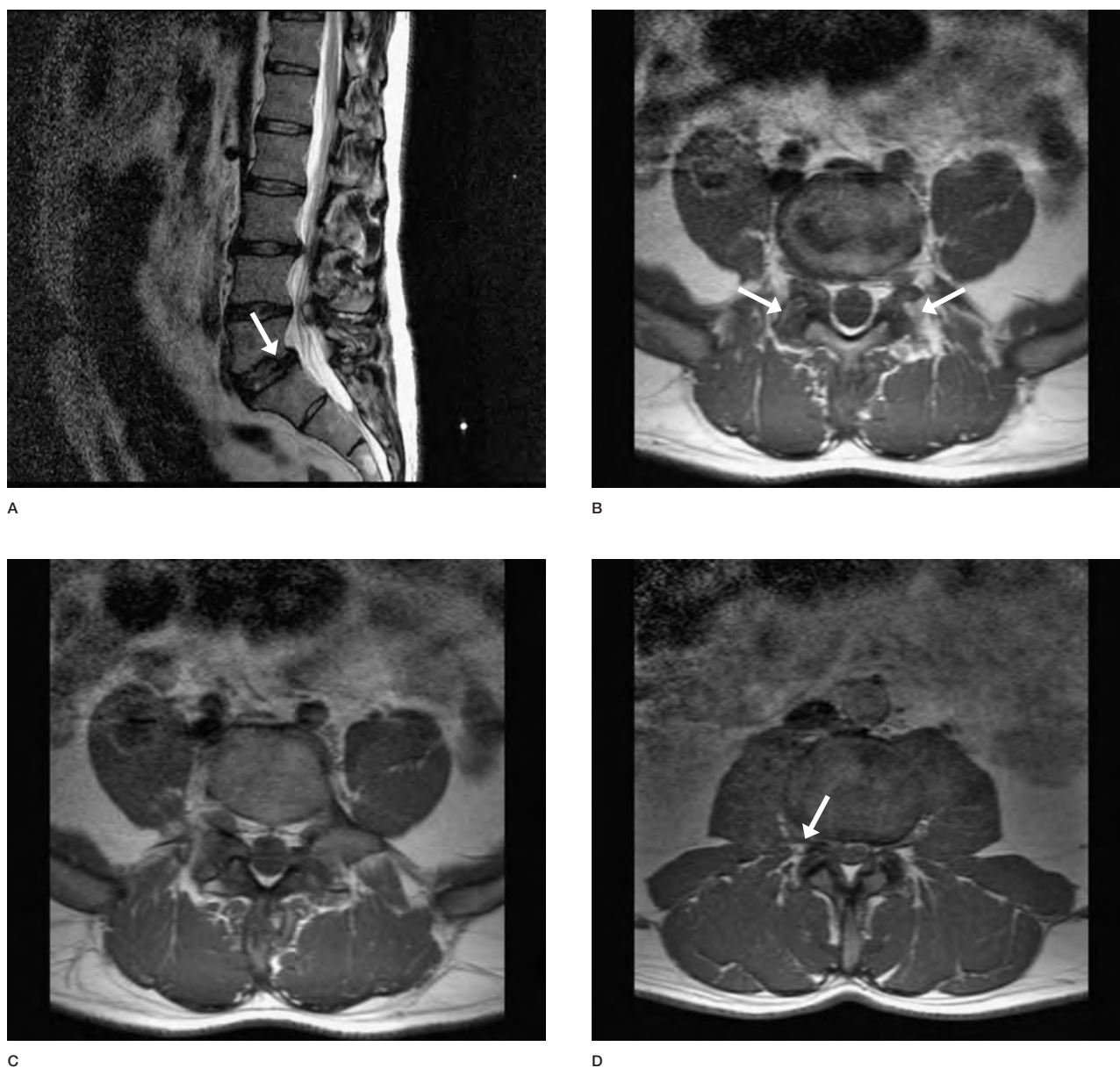


Figure 2 A 66-year-old man with chronic low back pain complicated by right sciatic nerve pain. MR scan (A-C) depicts spondylolisthesis of L5 over S1 (arrows) associated with degenerative arthrosis of the facet joints. Circumferential protrusion of the L3-L4 disc is also present mainly in the right intra-extraforaminal region (arrow) (D). The patient underwent O_2-O_3 treatment with CT-guided intraforaminal infiltration into both L3-L4 (right monolateral) and L5-S1 (bilateral) followed by 4 outpatient treatments with paravertebral intramuscular injections into the two levels. At 1 year follow-up the patient referred an excellent resolution of clinical symptoms (assessed by our modified McNab method).

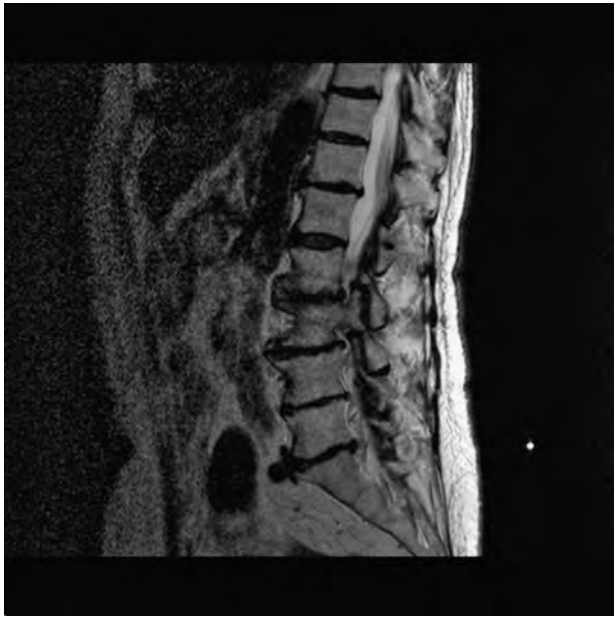
Discussion

At one year follow-up after O_2-O_3 treatment 33.9% (43/127) of our patients reported a clear-cut improvement in quality of life following a resolution of pain and a return to normal daily activities previously abandoned.

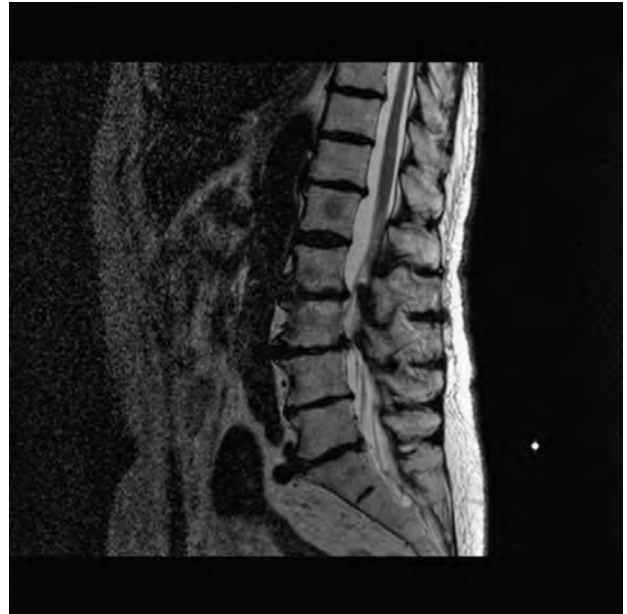Ten patients no longer required walking aids (crutches and corsets). After a partial resolution

of pain, 34 out of the 127 patients treated (26.7%) experienced a recurrence of symptoms but pain was judged to be much milder than before O_2-O_3 treatment and almost all patients requested another cycle of treatment. Of the 50 patients with a poor outcome at one year follow-up (39.4%) only one patient with multiple levels of segmental canal stenosis opted for surgical decompression.

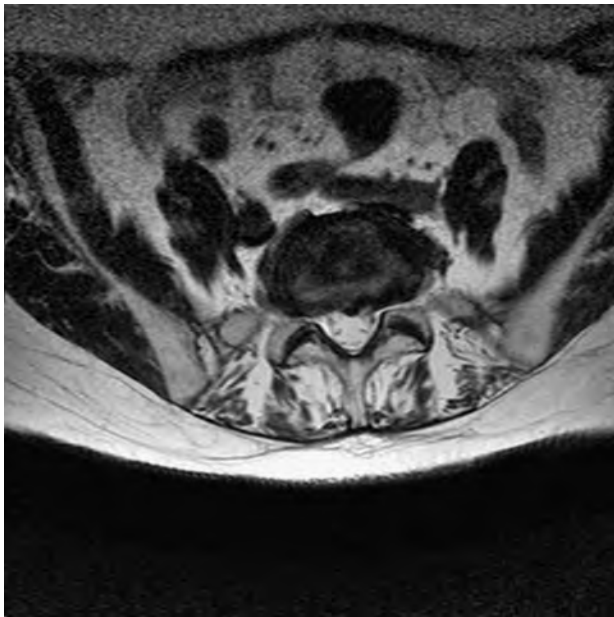
The good treatment outcome obtained at three



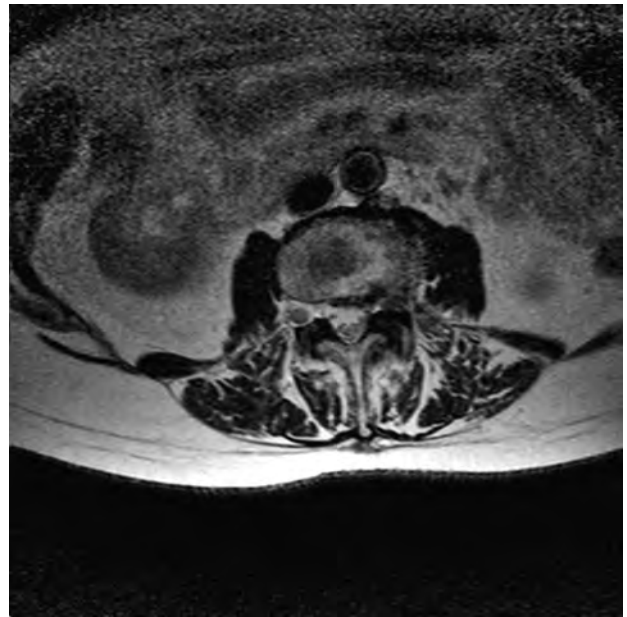A



B



C

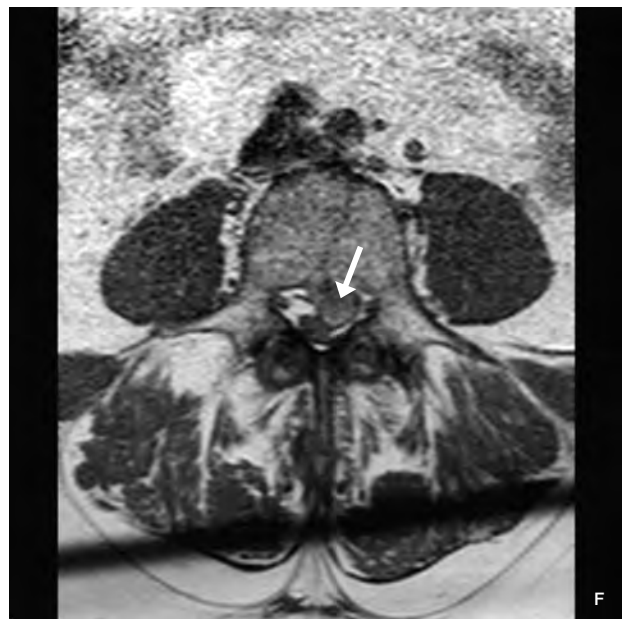
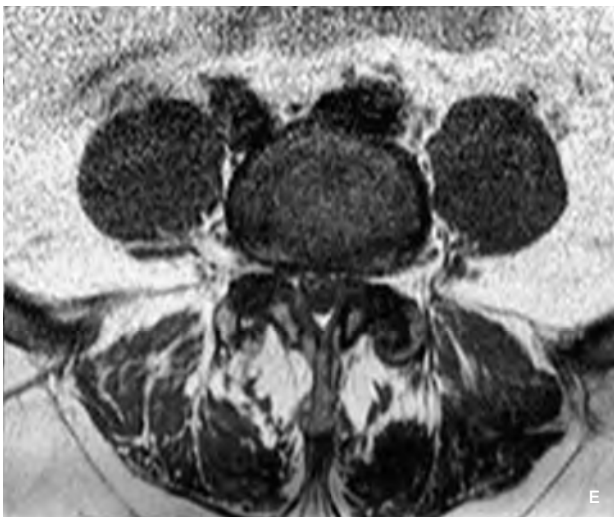
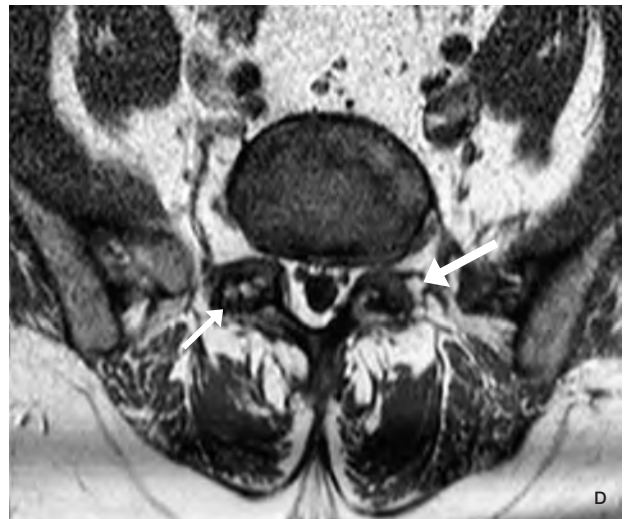
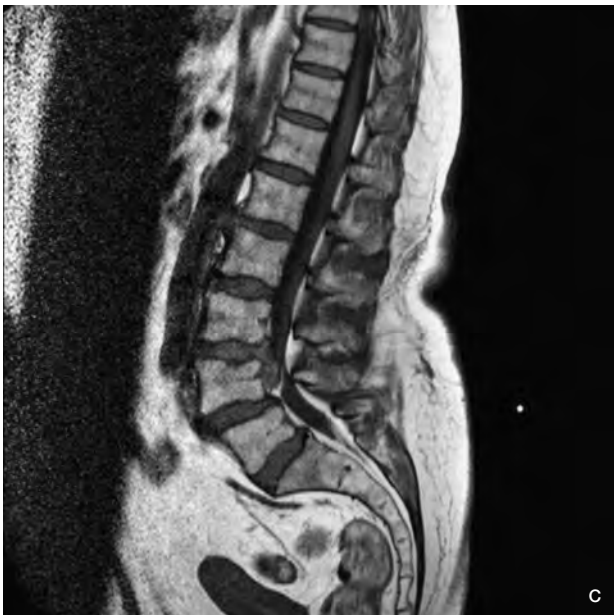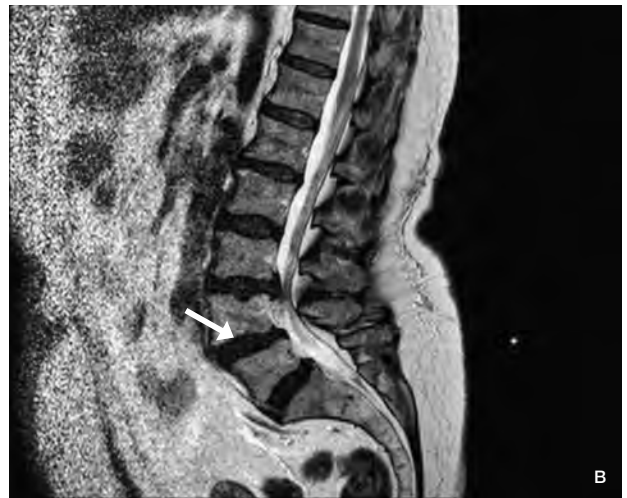

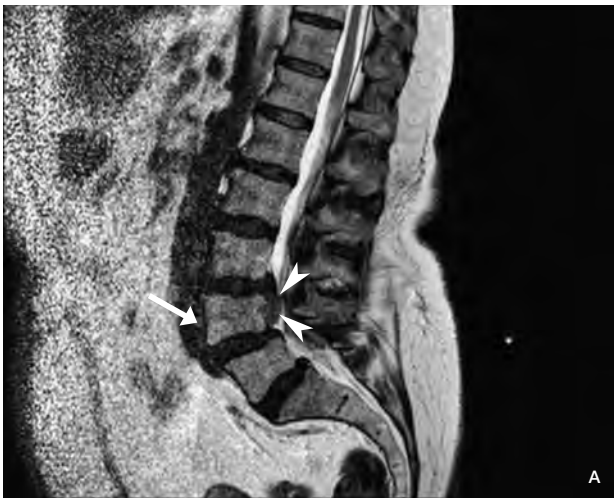
D

Figure 3 A-D A 74-year-old woman with chronic low back pain. MR scan (A-B) depicts advanced lumbar spondyloarthrosis with multiple levels of disc degeneration: the discs are thinned and present a hypointense signal in T2, mainly in L5-S1 (C) and L3-L4 with associated disc protrusion showing a left intraforaminal focus (D). She was treated by a three-level approach first with intraforaminal O₂-O₃ infiltration (L2-L3, L3-L4 and L5-S1) followed by 4 paravertebral intramuscular injections. Clinical outcome was deemed excellent at 1 year follow-up.



Figure 4 A 74-year-old woman with low back pain complicated by a 1 month history of severe left sciatic nerve pain irradiating along the region innervating the left L4, treated with O₂-O₃ administration with a poor clinical outcome. A-C) Sagittal MR scans show 1st degree listhesis of L4 over L5 according to Meyerding (arrows) and a large extruded L3-L4 disc (arrowheads). D) The L5-S1 disc also shows severe zygo-apophyseal degeneration (arrows). E) The axial scan at the L4-L5 passage documents the reduced canal diameter caused by the listhesis. F) Large extruded left L3-L4 herniation (arrow).



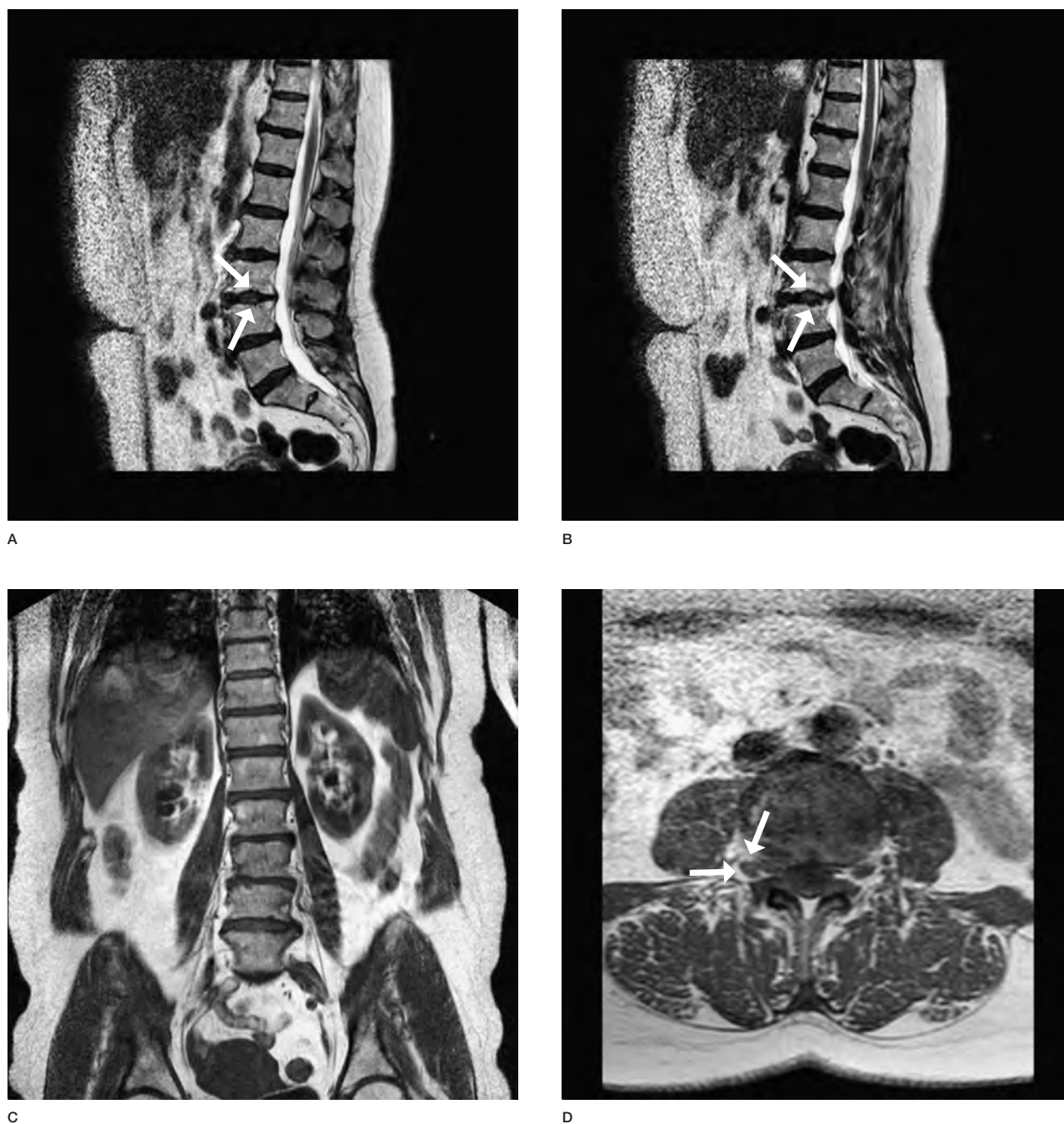


Figure 5 A 67-year-old man with low back pain lasting several months sometimes complicated by right sciatic nerve pain, treated by O_2-O_3 administration with an excellent clinical outcome. A,B) Sagittal MR scan shows L3-L4 disc degeneration with associated osteochondrosis of the opposite end plates (arrows). C) Coronal MR scan shows an initial scoliosis secondary to the degenerative spondyloarthrosis. D) The L3-L4 disc protrusion is focused in the right preforaminal region (arrows).

months follow-up is due to the capacity of O_2-O_3 injection into the ganglionic region to normalize the level of cytokines and prostaglandins, increase superoxide dismutase (SOD) and minimize reactive oxygen species (ROS) thereby

enhancing local periganglionic circulation with a eutrophic effect on the nerve root^{3,8}. This effect, however, appears to subside in the long-term especially when the morphostructural changes to the spine result in continuous pain stimulation. The

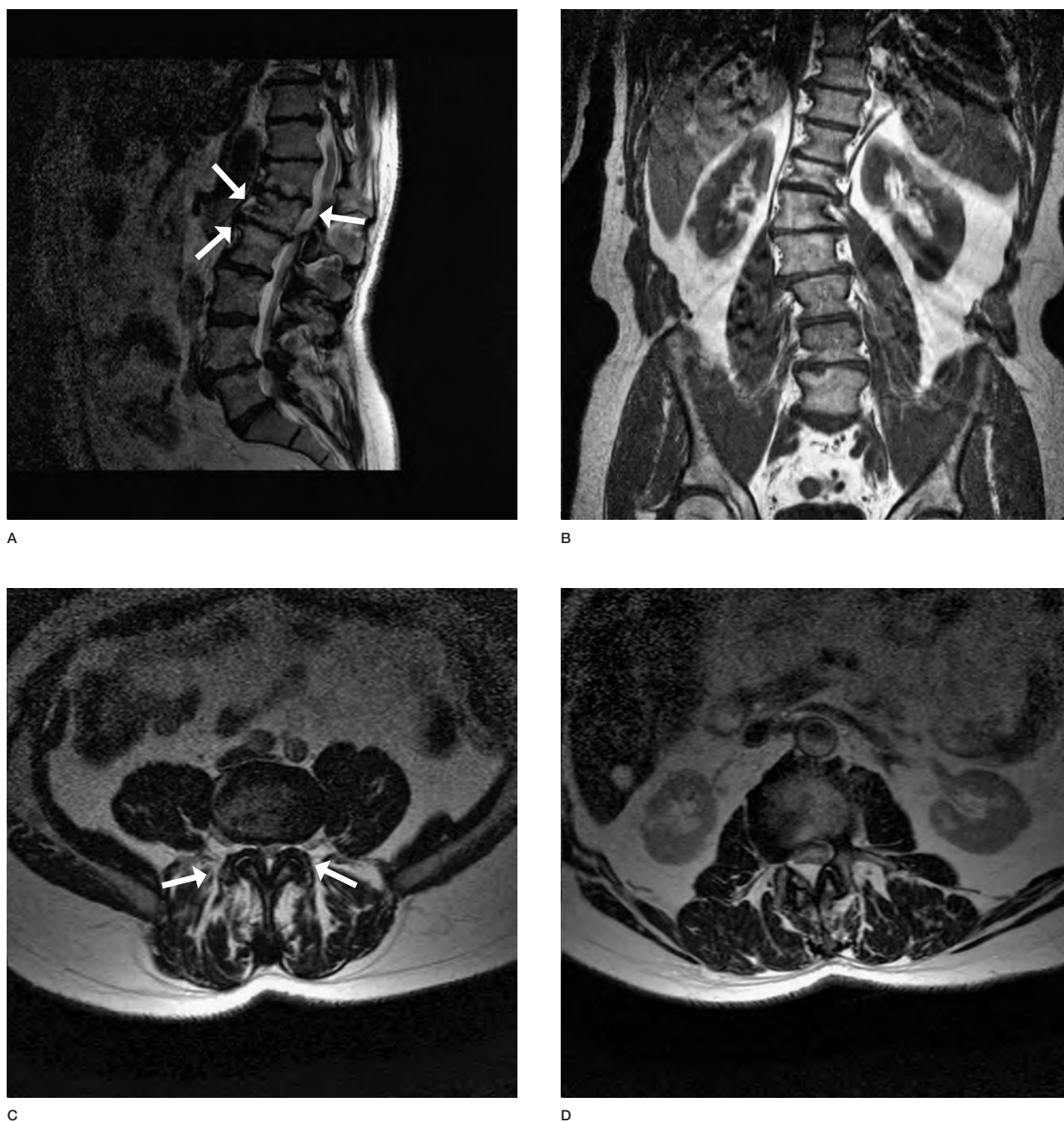


Figure 6 A 71-year-old man with chronic low back pain treated by O_2-O_3 administration with a good clinical outcome. A) Sagittal MR scan shows severe degenerative arthrosis at the dorsolumbar and lumbosacral passage (arrows). B) Coronal MR scan shows dorsolumbar scoliosis secondary to the degenerative spondyloarthrosis. C) The L4-L5 disc shows severe degeneration as do the facet joints (arrows). D) Scoliotic L1 vertebral body tending to rotate anti-clockwise.

patients most refractory to treatment proved to be those with canal stenosis resulting in mechanical nerve root compression by bony structures which prevented long-lasting pain relief due to the continuous recurrence of the nociceptive stimulus

caused by mechanical stress. Of the 34 patients with satisfactory outcome 29 requested a second cycle of treatment and of the 50 patients who failed to benefit from treatment 22 opted for a new cycle of O_2-O_3 infiltrations.

O₂-O₃ administration proved an effective treatment for root pain caused by spondylolysis thanks to its well-known pain relieving properties^{8,14}.

The treatment is a valid alternative to many drugs like corticosteroids which have non negligible adverse effects (e.g. sensory impairment, bowel/bladder dysfunction) especially problematic in the elderly^{15,17}.

By contrast, biochemical studies have demonstrated the lack of side-effects linked to short and long-term O₂-O₃ administration.

Conclusions

Conservative O₂-O₃ treatment is effective in relieving chronic low back pain and can offer significantly long improvements in quality of life in patients like the elderly with contraindications to drug management or concomitant age-related diseases. The lack of side-effects means that O₂-O₃ treatment can be repeated at six month to one year intervals to guarantee pain-free cover and avoid recourse to surgery.

References

- Weiner DK, Sakamoto S, Perera S, Breuer P: Chronic low back pain in older adults: prevalence, reliability, and validity of physical examination findings. *J Am Geriatr Soc.* 54: 11-20, 2006.
- Modic MT, Steinberg PM et Al: Degenerative disk disease: assessment of change in vertebral body marrow with MRI. *Radiology* 166: 193-199, 1988.
- Siddall PJ, Cousins MJ: Spine update. Spinal pain mechanism. *Spine* 22: 98-104, 1997.
- O'Donnell J: Prostaglandin E2 content in herniated lumbar disc disease. *Spine* 21: 1653-1656, 1997.
- Kawakami M, Tamaki T: The role of phospholipase A2 and nitric oxide in pain related behavior produced by an allograft of intervertebral disc material to the sciatic nerve of the rat. *Spine* 22: 1074-1079, 1997.
- Saal JS, Franson RC, Dobrow R et Al: High levels of inflammatory phospholipase A2 activity in lumbar disc herniations. *Spine* 15: 674-678, 1990.
- Weinstein J: Mechanisms of spinal pain: the dorsal root ganglion and its role as a mediator of low back pain. *Spine* 11: 999-1001, 1986.
- Vanderlinden R: Subarticular entrapment of the dorsal root ganglia as a cause of sciatic pain. *Spine* 9: 19-22, 1984.
- McCarron RF, Wimpee MW, Hudgkins PG et Al: The inflammatory effect of the nucleus pulposus. *Spine* 12: 759-764, 197.
- Andreula CF, Simonetti L, De Santis F et Al: Minimally Invasive Oxygen-Ozone Therapy for Lumbar Disk Herniation. *Am J Neuroradiol* 24: 996-1000, 2003.
- Iliakis E: Ozone treatment in low back pain. *Orthopaedics* 1: 29-33, 1995.
- Andreula CF: Ernie discali lombosacrali e patologia degenerativa correlata. Trattamento interventistico spinale con chemiodiscalisi con nucleoptesi con O₃ e infiltrazione periradicolare e periganglionare. *Rivista di Neuroradiologia* 14: 81-88, 2001.
- Bonetti M, Fontana A, et Al: Intraforaminal O₂-O₃ versus Periradicular Steroidal Infiltrations in Lower Back. *Am J Neuroradiol* 26: 996-1000, 2005.
- Fabris G, Tommasini GL: Percutaneous treatment of lumbar herniated disk. 10 years of experience in Udine. *Rivista di Neuroradiologia* 10: 523-532, 1997.
- Dougherty JH, Fraser RAR: Complications involving intraspinal injections of steroids. *Neurosurg* 48: 1023-1025, 1978.
- Bonetti M, Cotticelli B, Raimondi D et Al: Ossigeno-ozono terapia vs infiltrazioni epidurali cortisoniche. *Rivista di Neuroradiologia* 13: 203-206, 2000.
- Rovira E, Garcia EM, Catala J, Garcia J: Chronic adhesive arachnoiditis following epidural paramethasone. *Rev Neurol* 25: 2067-2068, 1997.

Dr Matteo Bonetti
 Servizio di Neuroradiologia
 Istituto Clinico Città di Brescia
 Via Gualla 15
 I – 25123 Brescia
 Tel.: 030.3197173
 Fax: 030.3197171
 Home: via Verdi 1 - 25060 Collebeato (BS)
 E-mail: matobon@numerica.it
 www.matteobonetti.com

Oxygen-Ozone Chemonucleolysis for Herniated Disc with Sciatica. A Comparison of Treatments in Patients with Subacute and Chronic Symptoms

M. LEONARDI, L. ALBINI RICCIOLI, S. BATTAGLIA, F. DE SANTIS, P. CENNI, L. RAFFI, L. SIMONETTI

Neuroradiology Service, Bellaria Hospital, Bologna

Key words: chemonucleolysis, lumbar herniated disc, sciatica

SUMMARY - This study compares the results obtained after O₂-O₃ chemonucleolysis in patients treated early and patients with long-standing symptoms. Because very few patients are referred in the acute stage, we considered patients treated early all those with symptoms of less than six months duration. Patients were divided into two groups: *Group A*: 37 patients with symptoms lasting less than six months; *Group B*: 52 patients with long-standing symptoms lasting from more than six months up to 20 years. Intradiscal and periganglionic injection was administered by extraspinal lateral approach using a 22 G × 17.78 cm spinal needle. Results were assessed by a modified version of the Oswestry questionnaire to make the evaluation as objective as possible. The questionnaire was administered to patients before chemonucleolysis and one, six and 18th months after treatment.

Background

Our team has gained 18 years' experience in the percutaneous treatment of herniated lumbar disc in more than 4000 patients. The techniques adopted have changed over the years for a number of reasons.

From 1987 to 1993 we treated lumbar herniated disc by papain injection obtaining satisfactory results^{3,4}. However, the lack of a CE mark led us to suspend the use of this product. We subsequently treated roughly 200 patients by nucleotomy according to Onik⁶ but the results were somewhat disappointing. A number of other techniques have also been used.

Since 1997 we have performed intradiscal injection of an oxygen-ozone (O₂-O₃) mixture^{2,7,8}. The positive outcome obtained in 70% of our patients using a low cost technique virtually free of contraindications and side effects lent support to the continued use of the treatment.

We have often been criticised for not having undertaken a randomized trial comparing oxygen-ozone administration with commonly prescribed medical treatments and the supposedly gold standard of surgery. There are no randomized studies on the efficacy of any of the percutaneous techniques

proposed and our own attempts to perform such studies have encountered major difficulties.

Firstly, patients are not referred to us in the acute stage, but only after failure of other physical or medical treatments. Secondly, our patients do not agree to be enrolled in a randomized study comparing oxygen-ozone chemonucleolysis with commonly administered drug treatments because they have already experienced medical management failure.

In practical terms, our chemonucleolysis procedures are comparable with drug treatments but a comparative study of patients treated with oxygen-ozone only in the acute stage has hitherto been impossible.

In addition, the pathophysiology of low back pain and sciatica is complex since disc herniation is only part of the cause and not necessarily the most important factor. It is also difficult to pinpoint the exact time of disease onset.

This hinders the possibility of randomized studies but also accounts for the many therapeutic techniques available and their ongoing development.

Despite the lack of randomized studies, the large number of patients treated to date is in itself evidence of the efficacy of O₂-O₃ chemonucleolysis.

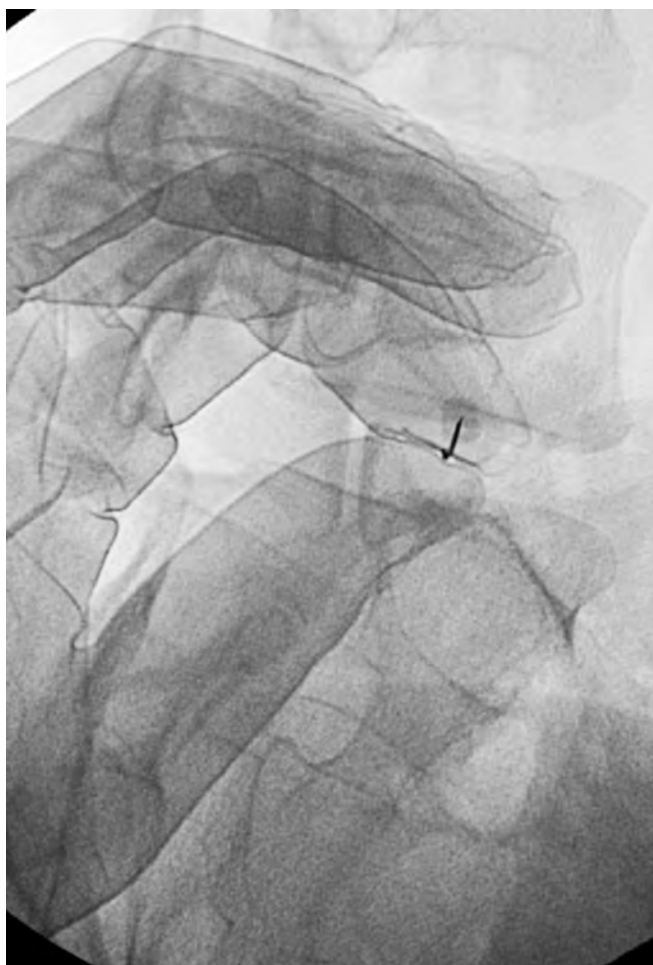

Figure 1

Introduction

This study compares the results obtained after O_2 - O_3 chemonucleolysis in patients treated early and patients with long-standing symptoms. Because very few patients are referred in the acute stage, we considered patients treated early all those with symptoms of less than six months duration.

Materials and Methods

From 1st January to 30th June 2004 we treated 89 patients with single herniated disc by O_2 - O_3 chemonucleolysis in a single session. Results were assessed 18 months after treatment.

Patients were divided into two groups: *Group A*: 37 patients with symptoms lasting less than six months; *Group B*: 52 patients with long-standing symptoms lasting from more than six months up to 20 years. *Group A* comprised nine men and 11 women with an average age of 57 years. *Group B*

comprised 19 men and 16 women with an average age of 49 years. Before referral to us all patients had received drug treatments of varying duration generally proportional to the duration of low back pain. The technique used has been described in previous articles^{2,8}: patients received intradiscal (4 ml) and periganglionic (10 ml) injection of an oxygen-ozone mixture with an ozone concentration of 27 $\mu\text{g}/\text{ml}$, followed by periganglionic injection of corticosteroid (1 ml Depo-Medrone 40 mg) and anaesthetic (2 ml Bupivacain 0.5%) at the same session.

Intradiscal and periganglionic injection was administered by extraspinal lateral approach using a 22 G \times 17.78 cm spinal needle. No premedication or anaesthesia was given. The procedure was carried out in the day hospital. Needles were positioned over the site of injection using fluoroscopic guidance⁵ (figures 1, 2).

Results were assessed by a modified version of the Oswestry questionnaire to make the evaluation as objective as possible. The questionnaire was

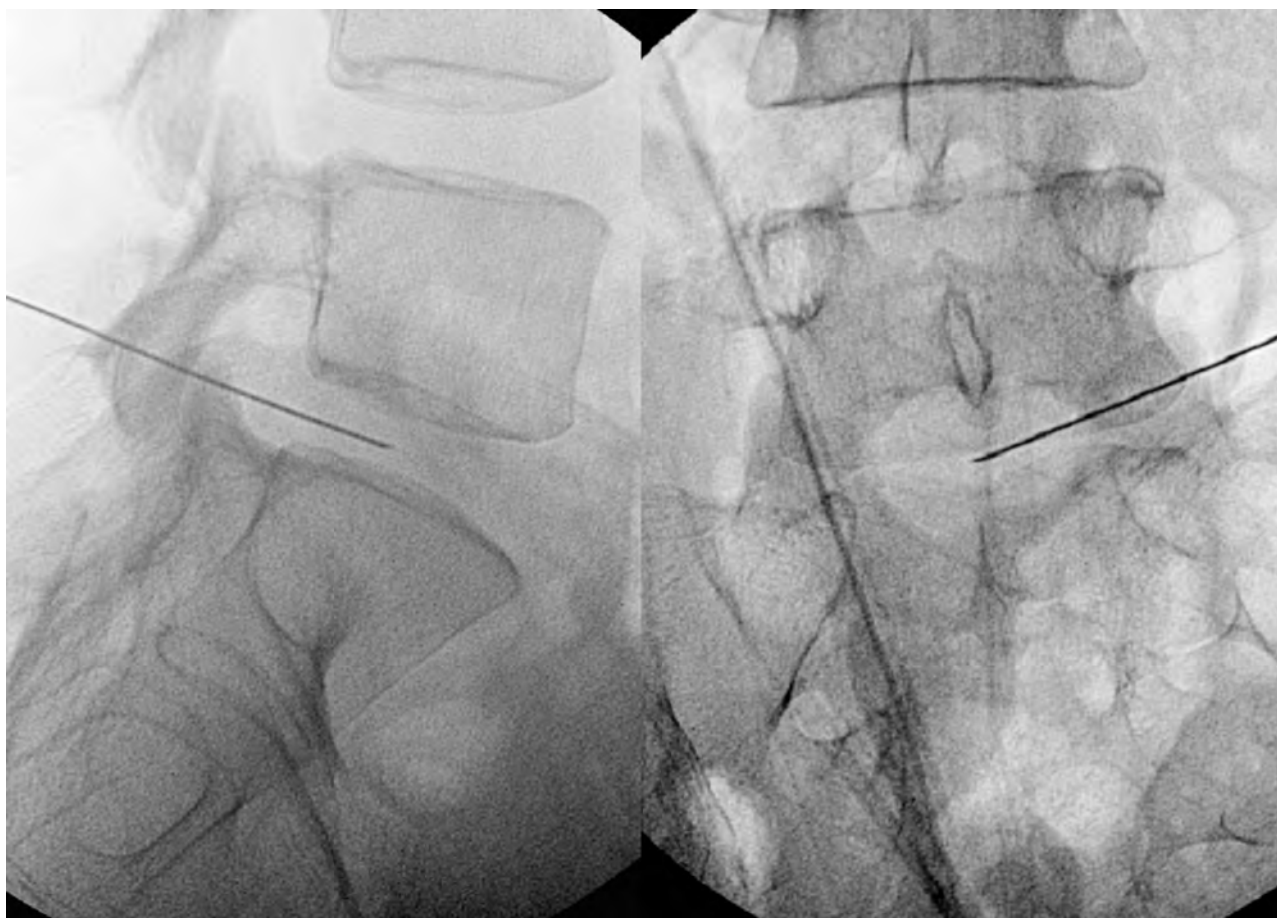

Figure 2

administered to patients before chemonucleolysis and one, six and 18th months after treatment.

Results

For simplicity treatment outcome was classified as positive, negative or null. A positive outcome was considered a complete or almost complete resolution of symptoms without the need for further treatment. Any mild recurrence on pain was controlled by traditional medical management with NSAIDs. Negative or null outcome was failure to relieve pain after treatment.

Treatment outcome was positive in 56 patients (62.9%) and negative or null in the remaining 33 (37.1%).

Group A patients obtained a positive outcome in 20 cases (54%). The initial symptoms in this group yielded an average Oswestry score of 19.5, whereas the final average score after treatment was 9.75.

Group B patients obtained a positive outcome

in 35 cases (67.3%). The initial symptoms in this group yielded an average Oswestry score of 18, whereas the final average score after treatment was 7.17. 25 of the 33 patients with a negative or null outcome after treatment underwent surgery for microdiscectomy. In all cases O₂-O₃ chemonucleolysis had no effect on the surgical procedure.

No complications related to O₂-O₃ chemonucleolysis treatment were encountered in any patient. Some patients not included in this cohort were unsatisfied with the treatment outcome and underwent repeat O₂-O₃ chemonucleolysis. The results obtained in these cases will be the object of a further study.

Discussion

A positive treatment outcome was obtained at 18 months after O₂-O₃ chemonucleolysis in 62.9% of patients in both groups. This is a satisfactory result for a mildly invasive procedure virtually free

from risks and complications. In addition O₂-O₃ chemonucleolysis is a low cost technique and can be repeated if necessary. It is difficult to account for the different outcome obtained in the two groups of patients treated in this study. As a whole, the patients with more recent onset of symptoms presented a more severe clinical status and were older on average. This could explain the lower percentage of positive results in *Group A* with respect to *Group B*.

In our experience, it is useful to administer O₂-

O₃ chemonucleolysis to treat low back pain and herniated disc before resorting to surgery. Our study demonstrated that the likelihood of a positive treatment outcome is irrespective of elderly patient age and chronic symptoms.

A comparison of O₂-O₃ chemonucleolysis and commonly administered drug treatments (steroids, NSAIDs) in acute lumbar disc disease is currently precluded by the difficulty in recruiting patients in the acute stage who have not already tried medical management.

References

- 1 Andreula CF, Muto M, Leonardi M: Interventional spinal procedures. *European Journal of Radiology* 50: 112-119, 2004.
- 2 Andreula CF, Simonetti L, de Santis F et Al: Minimally invasive oxygen-ozone therapy for lumbar disk herniation. *Am J Neuroradiol* 24: 996-1000, 2003.
- 3 De Nardi E, Ceccotto C, Pomelli L et Al: La chemonucleolisi nell'ernia discale lombare, 1° parte: analisi clinica dei risultati. *Rivista di Neuroradiologia* 1: 53-61, 1988.
- 4 Fabris G, Lavaroni A, Zappoli F et Al: La chemonucleolisi nell'ernia discale lombare. *Rivista di Neuroradiologia* 2: 93-102, 1989.
- 5 Leonardi M: Disc Punture under Fluoroscopic Guidance. *Rivista Italiana di Ossigeno-Ozonoterapia* 1: 73-78, 2002.
- 6 Leonardi M, Fabris G, Lavaroni A: Percutaneous discectomy and chemonucleolysis. In: Valavanis A (ed): *Medical Radiology: Interventional Neuroradiology*. Editor. Springer Verlag, Heidelberg 1993: 173-190.
- 7 Muto M, Andreula CF, Leonardi M: Intradiscal oxygen-ozone in the treatment of herniated lumbar disc. In: *Image-guided spine interventions*. John M.Mathis (editor). Springer-Verlag 2004.
- 8 Muto M, Andreula CF, Leonardi M: Treatment of herniated lumbar disc by intradiscal and intraforaminal oxygen-ozone (O₂-O₃) injection. *Journal of Neuroradiology* 31: 183-189, 2004.

Prof. Marco Leonardi
Neuroradiology Department
Bellaria Hospital
Via Altura, 3
40139 Bologna - Italy
Tel.. +39 051 6225520 - Mobile: +39 348 8714153
Fax: +39 051 6225785
E mail: marco.leonardi@ausl.bologna.it

Oxygen-Ozone Therapy for Local Adipose Deposits and Oedematous Fibrosclerotic Panniculopathy

M.A. SIRITO

Fisiomedical; Genova

Key words: lipodystrophy, ozone, lipolysis

SUMMARY - Localised adipose tissue deposits and oedematous fibrosclerotic panniculopathy are different conditions but they often coexist in the same areas. They both respond to treatment with an appropriate concentration of oxygen-ozone as the gas mixture has a lipolytic effect and regulates tissue irrigation. This accounts for the use of O₂-O₃ in the initially oedematous stages of panniculopathy whereas there is currently no scientific evidence for its use for fibrinolysis. This study proposes a treatment protocol based on five years' experience of specific O₂-O₃ treatment for these conditions.

Introduction

Among the many fields of application of oxygen-ozone therapy in aesthetic medicine, two conditions are convincing from the standpoint of scientific rationale and efficacy: localised adipose tissue deposits and oedematous fibrosclerotic panniculopathy (OFSP), commonly known as cellulite. Local adipose deposits do not constitute a disease and may occur anywhere and vary in quantity. Instead, cellulite is a qualitative dystrophic change in the adipose panniculus localised exclusively in the limbs and due to changes in the microcirculation.

The two conditions often coexist in the same area, accounting for difficulties in diagnosis and treatment. Ozone has lipolytic properties¹, binding to the double carbon bonds in fatty acids, promoting scission and elimination. The lipolytic effects have already been demonstrated by magnetic resonance imaging (Rivista Italiana di Ossigeno-Ozonoterapia 1: 87-92, 2002).

It has been demonstrated^{2,3,4,5} that all the morphopathogenetic events in OFSP result from impaired capillary-venular permeability with slowing of the local microcirculatory haemodynamics. As ozone enhances both the deformability of red blood cells and^{2,3} DPG levels and hence tissue irrigation⁶, its use appears to be appropriate in the initial, mainly oedematous, stages of OFSP.

Since ozone has no proven fibrinolytic effect, there is currently no indication for its use in the advanced fibrotic stages of OFSP. On the other

hand, since localised and lipodystrophic adipose deposits may coexist in the same area⁷, it is not illogical to expect therapeutic results (reduction in volume due to lipolysis) also in the mainly fibrotic areas.

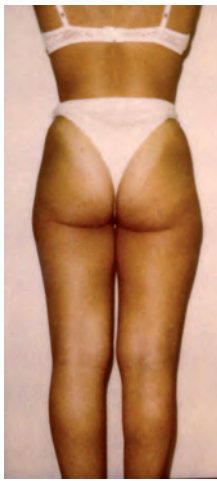This paper describes five years' personal experience of O₂-O₃ infiltration to treat localised adipose tissue deposits and OFSP from March 2001 to February 2006.

Materials and Methods

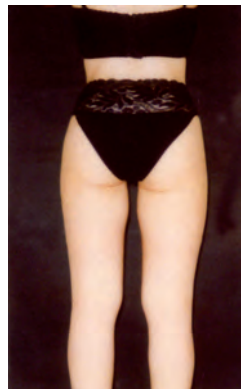A medical ozone device equipped with photometric control of ozone concentration was used (Mod. Ozofutura - Alnitic). Ozone concentration was set at 5 µg/ml, and 10 ml of gas mixture were injected for every 5 cm area to be treated at a variable depth of between 10 and 20 mm. Treatment was administered weekly or twice weekly for ten sessions for each therapeutic cycle and two or more cycles a year. The gas mixture was injected using 50 cc eccentric cone syringes and 27 G needles from 13 to 19 mm long inserted at an angle of 90° for local adipose deposits and almost tangential down to the subcutaneous region in the mainly lipodystrophic areas.

The following treatment exclusion criteria were adopted:

- Pathological processes in the areas to be treated.
- Coagulation disorders likely to cause prolonged bleeding.
- Frequent faintness or hypotension.



A



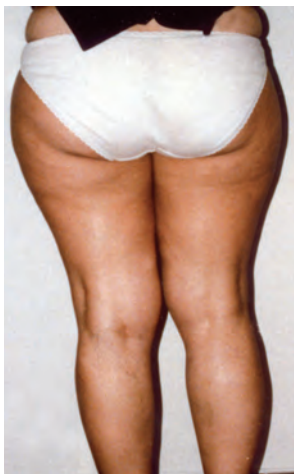B



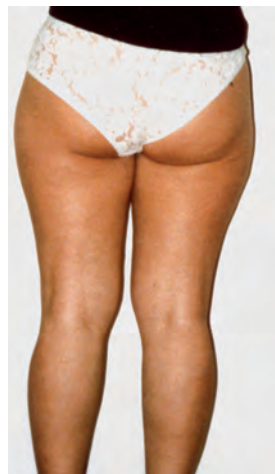C



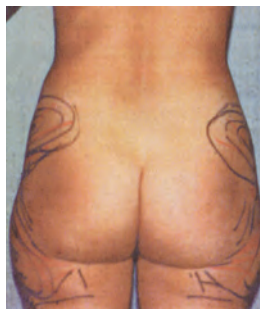D



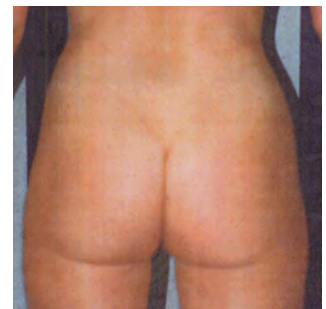E



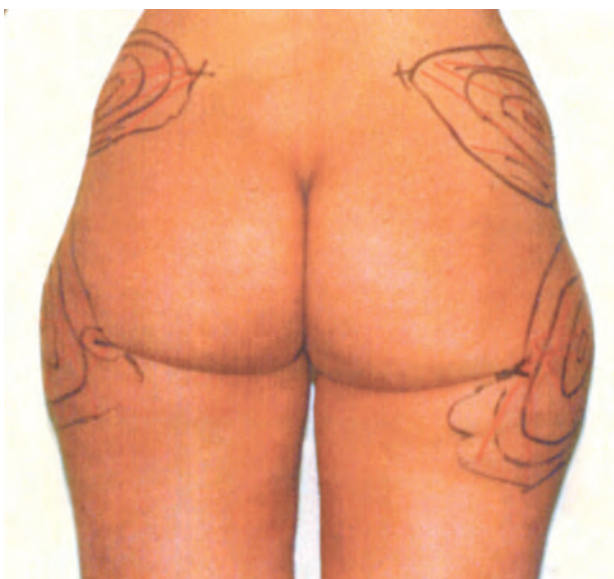F



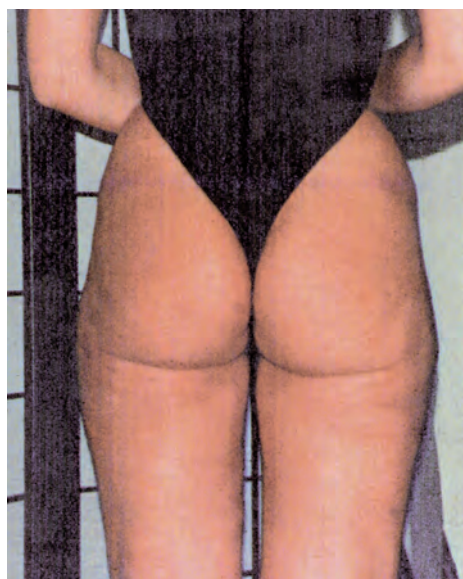G



H



I



J

Figure 1 Five subjects before and after oxygen-ozone therapy at concentrations of 5 mcg/ml. The results were obtained after a number of weekly or twice weekly treatment sessions varying from 10 to 30.

- Tendency to put on weight.
- Neurosis and psychosis.
- Underage without written parental consent.
- Pregnancy and breastfeeding.

Treatment was applied to the hips, the periumbilical area, the thighs in lateral view of the femur trochanters and the proximal medial thigh region, the knee above the kneecap and the projection of the medial condyles of femur and tibia, and the extensor region of the arms. Anthropometric measurements (weight, fat mass, plicometry and circumference of the area to treat) were taken before, during and after the treatment cycles.

Overweight or frankly obese patients were put on a slimming diet and told to exercise regularly. Subjects who failed to lose weight were invited to suspend the treatment. The following side effects were observed:

- Pain and burning sensation lasting seconds.
- Reddening lasting minutes.
- Haematomas.
- Perception of gas beneath the skin lasting minutes.

- Attenuated sense of heaviness in the legs lasting days.

Results

The reduction in thickness of the dystrophic and normal adipose layer documented by the anthropometric measurements was most pronounced in the arms, hips, periumbilical area, proximal medial thigh region, the area above the kneecap and the medial knee region, and less evident in the trochanters. Non responders were fewer than 15%.

Conclusions

Oxygen-ozone therapy is an effective means of treating local adipose tissue deposits and cellulite. The results observed indicate that the greater the reactive fibrotic component of cellulite, the less effective the treatment is at the concentrations used. Our findings await further confirmation with future applications of oxygen-ozone therapy in this field.

References

- 1 Bocci V: 'Ossigeno-ozonoterapia', Casa Ed. Ambrosiana 2000: 73-82.
- 2 Curri SB: Lymphoedeme et cellulite, *J. Med. Esth* 10: 11-19, 1982.
- 3 Curri SB: Stasi venosa e liposclerosi: aspetti morfofunzionali, *Proc. VII Riun. Fiorentina Angiologia*, Firenze 1990: 74-75.
- 4 Curri SB: L'interessamento del microcircolo cutaneo, adiposo e muscolare nella stasi venosa cronica degli arti inferiori, in *Flebolinfologia*, vol. I, Salus Ed. Int., Roma 1988: 31-41.
- 5 Curri SB: Correlazioni microvascolo-tessutali e stasi venosa: alterazioni dei microvasi e dei tessuti cutaneo, adiposo e muscolare, in: *Flebologia* 87, Monduzzi Ed., Bologna 1987: 265-284.
- 6 Bocci V: Ossigeno-ozonoterapia, Casa Ed. Ambrosiana 2000: 83-97.
- 7 Bartoletti CA: Mesoterapia, in: A. Rituffo e C.A. Bartoletti: *La cellulite*, Salus Ed. Int., Roma 1983: 79-83.

Dr M.A. Sirito
Fisiomedical
Via XX Settembre, 23
16121 Genova
Italy
E-mail: mario.sirito@libero.it

Presidente del Congresso
Fabio Triulzi

Segreteria Scientifica
Elena Bianchini
Cecilia Parazzini
Andrea Righini

Consiglio Direttivo AINR

Presidente Onorario
Giovanni Ruggiero

Presidente
Ugo Salvolini

Past President
Raffaele Elefante

Segretario
Cosma Andreula

Tesoriere
Sossio Cirillo

Consiglieri
Paola D'Aprile
Andrea Falini
Massimo Gallucci
Marco Leonardi
Luigi Manfrè
Mario Muto
Giannantonio Pellicanò
Mario Savoiaro
Giovanni Sirabella

22

Congresso Nazionale Associazione Italiana di Neuroradiologia

PALAZZO MEZZANOTTE
Milano, 4-6 Ottobre 2006

PRIMO ANNUNCIO



Termine per l'invio
degli Abstract:
15 Giugno 2006

RELATORI

Raffaele Agati
Cosma Andreula
Giacchino Angarano
Darell Bigner
Edoardo Boccardi
Giuseppe Bonaldi
Vincenzo Branca
Giovanni Broggi
Maria Grazia Bruzzone
Fabio Calbucci
Ferdinando Caranci
Cesare Colosimo
Ugo De Paula
Francesco Di Salle
Jean Pierre Elsig
Gaetano Finocchiaro
Roberto Gasparotti
Jeroen Hendriksen
Denis Kaech
Timo Krings
Luigi Manfrè
Mario Muto
Cecilia Parazzini
Giannantonio Pellicanò
Piero Picozzi
Juergen Reul
Andrea Rossi
Mary Rutherford
Giuseppe Scotti
Riccardo Soffietti
A. Gregory Sorensen
Alessandra Splendiani
Majda Thurnher
Anton Valavanis



Associazione Italiana di Neuroradiologia

GIOVEDÌ 5 OTTOBRE, 2006

Il trattamento delle MAV cerebrali

- Trattamento endovascolare
- Trattamento radiocirurgico
- Trattamento neurochirurgico
- Il punto di vista del paziente (e della MAV)

Lesioni della sostanza bianca nel prematuro

Le encefaliti virali

- Eziopatogenesi e clinica
- Quadri neuroradiologici nel bambino
- Quadri neuroradiologici nell'adulto

Vantaggi e limiti delle procedure di stenting intracranico

- Stenosi ateromasiche
- Stent non ricoperti
- Stent ricoperti

ore 17,30 Assemblea Generale AINR

VENERDÌ 6 OTTOBRE, 2006

Diagnosi e terapia dei gliomi

- Dalla classificazione alla tipizzazione neuroradiologica
- Cellule staminali neurali e GBL
- Chemioterapia
- Radioterapia
- Terapia chirurgica
- Terapia molecolare

Nuove tecniche di indagine del rachide e del midollo spinale

- AngioTC e angioRM spinale
- Diffusione del rachide e del midollo spinale
- Spettroscopia a 3T del midollo spinale
- Studi BOLD del midollo cervicale
- RM dinamica e sotto carico della colonna
- Valutazione del rachide cervicale con FMRI

Imaging delle lesioni iatrogene del SNC

- Nel bambino
- Nell'adulto

La vertebroplastica

- Biomateriali e sistemi di iniezione
- Vertebroplastica e cifoplastica a confronto
- Tecniche di intervento, metodologia operatoria
- Tecniche di remodelling vertebrale

INFORMAZIONI GENERALI

Sede del Congresso

Palazzo Mezzanotte
Piazza degli Affari, 6 - 20123 Milano - Tel +39 02 802871

Registrazione e Prenotazione Alberghiera

Le iscrizioni al Congresso e le prenotazioni alberghiere potranno effettuarsi online tramite il sito www.aimgroup.it/2006/ainr. Le informazioni sulle modalità di iscrizione saranno contenute nel prossimo annuncio.

Cerimonia Inaugurale

La cerimonia inaugurale del Congresso si svolgerà presso la Sala Plenaria di Palazzo Mezzanotte.

Programma Sociale

Giovedì 5 ottobre 2006 è prevista una cena sociale per i partecipanti al Congresso. Maggiori informazioni sull'evento e sul programma sociale saranno fornite nel prossimo annuncio.

Esposizione Tecnico-scientifica

Nell'ambito del Congresso è prevista un'area espositiva per aziende farmaceutiche, apparecchiature elettromedicali ed edizioni scientifiche.

Informazioni più dettagliate potranno essere richieste alla Segreteria Organizzativa.

CME

Il Congresso verrà accreditato presso il Ministero della Salute.

PROGRAMMA SCIENTIFICO PRELIMINARE

MERCOLEDÌ 4 OTTOBRE, 2006

Cerimonia Inaugurale

Perfusione Cerebrale TC e RM

- La perfusione RM con gadolinio
- Arterial Spin Labeling
- La perfusione RM nelle neoplasie cerebrali
- La perfusione TC

Multichannel MR imaging

Segreteria Organizzativa

AIM AISC & MGR - AIM GROUP
Sede di Milano
Via Ripamonti, 129 - 20141 Milano
Tel.: + 39 02 56601.1 - Fax : +39 02 56609045
E-mail: ainr2006@aimgroup.it - www.aimgroup.it/2006/ainr

Segreteria Scientifica

Elena Bianchini, Cecilia Parazzini, Andrea Righini
Ospedale dei Bambini V. Buzzi
Via Castelvetro, 32
20154 Milano

El Ozono y los factores de crecimiento en la curación de las úlceras

Ulcers Treated with Ozone and Growth Factors

JOSÉ FAUS VITORIA

Clínica de Medicina Biológica; Gandía, Valencia, España

Key words: ozonotherapy, ulcer, autoemotherapy

SUMMARY – The use of ozone to heal wounds and ulcers dates back to the First World War when it was applied to septic wounds and abscesses which healed better under the disinfectant action of ozone. Between 40 and 50% of patients with diabetes have foot ulcers, leading to amputation in 20% irrespective of the type of ulcer. Ozone therapy is an alternative to amputation given its local and systemic antibacterial and antiviral properties due to the formation of peroxide. Ozone improves cell metabolism due to increased consumption of glucose, fatty acids and aminoacids and activation of free antiradical enzymes.

El uso del Ozono en la curación de las heridas y úlceras se remonta a la Primera Guerra Mundial, cuando se aplicó en las heridas sépticas de guerra y en abscesos, presentaban una mejor cicatrización bajo la acción desinfectante del ozono.

Hoy en día, la patología infecciosa en las úlceras de los miembros inferiores ha aumentado su frecuencia debido a las siguientes circunstancias:

1. La dificultad en vencer la infección larvada por gérmenes habituales. (diabetes, inmunidad deprimida, traumatismos con heridas anfractuadas...)
2. La disminución de la luz arterial (ya sea por espasmo o esclerosis de la intima arterial). Esta situación impide el necesario flujo sanguíneo para aportar oxígeno y nutrientes a la célula.
3. La insuficiencia venosa que impide el retorno de la sangre, facilitando la hinchazón y la estasis sanguínea.
4. La carencia de vitaminas y minerales, así como los componentes necesarios para la “cementación” del tejido conectivo.

Se calcula que entre el 40-50% de los diabéticos desarrollan úlceras en los pies, llegando a la amputación en un 20 por ciento, independientemente del tipo de úlcera que presenten.

La terapia con el Ozono es la alternativa a la “definitiva” amputación, por sus efectos beneficiosos que enumero:

1. Efecto antibacteriano y antiviral tanto sistémico como local debido a la formación discreta de peróxidos.
2. Aumento de la elasticidad del glóbulo rojo, permitiéndole mayor penetración en la microcirculación (anti-sludge)

The use of ozone to heal wounds and ulcers dates back to the First World War when it was applied to septic wounds and abscesses which healed better under the disinfectant action of ozone. Ulcers are currently increasing in frequency for the following reasons:

1. The difficulty in overcoming infection due to germs habitually present in the skin (diabetes, depressed immunity, injuries with complicated wounds).
2. Decreased arterial lumen due to spasm or sclerosis of the arterial intima preventing the blood flow needed to carry oxygen to feed cells.
3. Venous insufficiency preventing venous blood return and facilitating blood stasis.
4. Vitamin and mineral deficiency and a lack of the components required to “cement” the connective tissue.

Between 40 and 50% of patients with diabetes have foot ulcers, leading to amputation in 20% irrespective of the type of ulcer.

Treatment is divided into four stages:

1. The fight against infection,
2. Cleansing dead tissues
3. Stimulating granulation tissue
4. Final epidermization.

Ozone therapy is an alternative to amputation given its local and systemic antibacterial and antiviral properties due to the formation of peroxide. It increases the elasticity of erythrocytes allowing greater penetration through the microcirculation. Ozone enhances the production of 2,3 diphosphoglycerate responsible for releasing oxygen to tissues. It also improves cell metabolism due

3. Aumento de la producción, siempre a nivel del glóbulo rojo, del 2,3DPG (difosfoglicerato), responsable de la cesión de Oxígeno a los tejidos.
4. Mejoramiento del metabolismo del Oxígeno por aumento de la utilización de la glucosa, de los ácidos grasos y por la activación de enzimas anti-radicales libres.

Los Factores de crecimiento (FC)

Son pequeños fragmentos proteicos biológicamente activos que pertenecen al grupo de las *citoquinas*.

Aunque los FC son producidos y segregados por todas las células del organismo como respuesta a un estímulo específico donde se encuentran en mayor proporción es en las *plaquetas*. Cuando estas sustancias (citoquinas) se unen a los receptores de la membrana celular, la célula se activa o inhibe en sus funciones.

El primer factor de crecimiento, descubierto en 1960, fue denominado Epidérmico Growth Factor (EGF) o factor de crecimiento epidérmico (FCE) nombre que indica su capacidad de inducir la proliferación celular en cultivos de células de la epidermis.

Todos los factores aislados hasta el momento, promueven en los tejidos celulares vecinos una serie de actividades que las podemos resumir en: actividad, proliferación, diferenciación y quimiotaxis en diferentes células blanco, como lo pueden ser macrófagos y osteoblastos.

Además los factores de crecimiento estimulan la angiogénesis, con lo que favorecemos el aporte de sangre arterial a dichos tejidos afectados

Método de extracción de los FC

Se realiza una extracción sanguínea al paciente y se centrifuga la sangre. Del suero se separa la fracción correspondiente al concentrado de plaquetas o Plasma Rico en Plaquetas (PRP).

Dicha fracción de suero rico en plaquetas, será la utilizada.

Caso N° 1: R. A: 11-12-2003. 59 años. Ama de casa y trabaja en bar (mucho tiempo de pie). Presenta úlcera maleolar de dos años de duración. Aspecto necrótico con gran pigmentación periférica. Desde hace 2 meses con antibióticos+analgésicos. Dolor clavante, ardiente, ondulante, <noche y>movimiento y caminar. Antecedente de flebitis complicadas y varias sesiones de tratamiento esclerosante de venas. El dolor es tan intenso que provoca temblor y ansiedad.

to increased consumption of glucose, fatty acids and aminoacids and activation of free antiradical enzymes.

Growth Factors

Growth factors are small biologically active protein fragments belonging to the group of cytokines. Growth factors are also produced for all cells in the body in response to a specific stimulus where they are found in large numbers in the platelets, macrophages in plasma proteins. When these substances (cytokines) bind to cell membrane receptors cell function is activated or inhibited. Discovered in 1960, the first growth factor was called Epidermal Growth Factor (EGF) reflecting its capacity to stimulate cell proliferation in cultures of epidermal cells. Generally speaking, all growth factors trigger a series of activities in cell tissues consisting in proliferation, differentiation and chemotaxis in different white blood cells (macrophages and fibroblasts). In addition growth factors stimulate angiogenesis for a better blood supply to damaged tissues.

Growth Factor Extraction

Blood is sampled and centrifuged. The serum is separated from the fraction corresponding to the platelet concentrate or platelet rich plasma (PRP) to be used in the treatment.

Case No. 1: A 59-year-old housewife who also worked in a bar spending a lot of time on her feet. She had an ulcer on her ankle for two months treated with antibiotics and analgaesics. The ulcer caused a sharp stabbing pain worsening at night and on walking. The patient had a history of complicated phlebitis and had received several sessions of sclerosing treatment for her veins. Pain was so intense it caused trembling and anxiety.

Local Treatment

1. Cleansing the ulcer with ozonized water (20 mcrg/ml)
2. Peripheral infiltration with saline serum + lidocaine
3. Posterior infiltration of an oxygen/ozone mixture (16 mcrg/ml)
4. Aspiration with a bell connected to an emptying machine.
5. Application of a plastic bag with an oxygen/ozone mixture at 100 mcrg/ml (sterilization)
6. The bag was removed and a garze soaked in serum applied to the ulcer and closed.

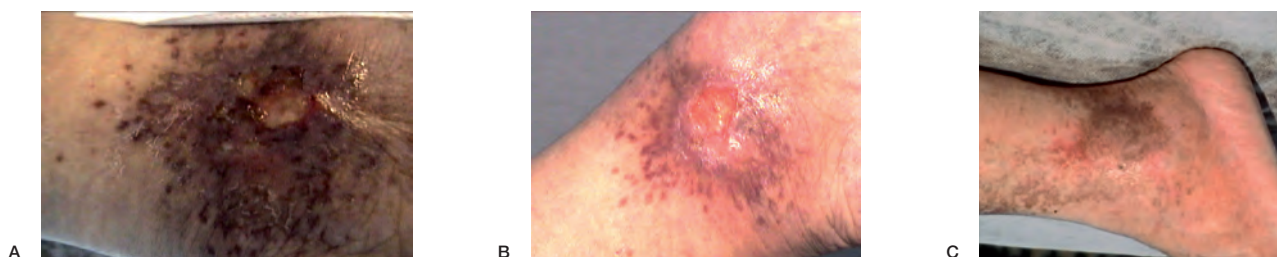

Figura 1
Figure 1

Tratamiento local

1. Limpieza de la úlcera agua ozonizada a 20 microgramos/ml., retirando bien los esfacelos.
2. Infiltración periférica (3-5 cm del borde de la ulcera) con suero (20 cc)+Lidocaina (1 ampolla).
3. Infiltración posterior de Ozono/oxígeno a 16 microgramos /mililitro.
4. Aspiración con la campana conectado a una bomba de vacío
5. Aplicación de Ozono/Oxígeno a 100 microgramos /mililitro, en bolsa de plástico durante 15 minutos.
6. Retirar bolsa y cerrar la ulcera con gasa empapada de suero propio del paciente rico en plasma rico en plaquetas (PRP)

Tratamiento general

1. Autohemoterapia de 110 cc de sangre con mezcla de 100 cc. de Ozono/oxígeno a concentración de 55 microgramos/mililitro, en total 5.500 microgramos de Ozono
2. Autosanguis IM con 5 cc de sangre ozonizada propia (del frasco anterior), con una ampolla de Placenta compositum.-Circulo-injeel-Lynfomiosot-Funiculus umbilicales-Discus compositum- (se utilizó un compuesto cada vez)

Evolución de la enfermedad

Tras 5 sesiones de tratamiento espaciado entre 10 y 25 días, la paciente experimentó:

1. Mejoría en el dolor de la ulcera casi desde la primera sesión
2. Mejoría en la hinchazón de la pierna a la 2-3 sesión
3. Cierre total de la ulcera entre la 4-5 sesión

Caso N° 2: S.V. 21 años. Estudiante

Úlcera residual que no cura tras un accidente en moto que provocó herida inciso-contusa en maleolo interno, interesando a éste, pero solo con erosión. El pie presento gran hinchazón y hematoma. El cirujano le refresca la herida (técnica de Friederich).

Systemic Treatment

1. Autohaemotherapy di 110 cc of blood mixed with an oxygen/ozone mixture at a concentration of 55 mcgr/ml
2. Intramuscular autohaemotherapy with 5 cc of the patient's ozonized blood mixed with a phial of Placenta compositum.-Circulo-injeel-Lynfomiosot-Funiculus umbilicales-Discus compositum- (used at every session).

Disease Evolution

After five treatment sessions over a period of ten to 25 days, the patient had:

1. An improvement in ulcer pain from the first session.
2. An improvement in leg swelling from the second session.
3. Total closure of the ulcer between the fourth and fifth session

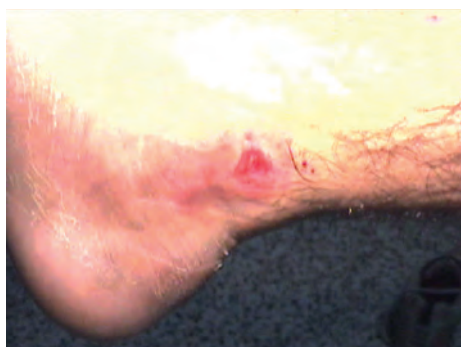Case No. 2: A 21-year-old student with a residual ulcer after a motor-cycle accident which had caused an open wound and contusion in the ankle. His foot was highly swollen with haematoma. The surgeon applied Friederich's technique. The patient was treated with antibiotics and analgaesics for three weeks without benefit.

Local Treatment

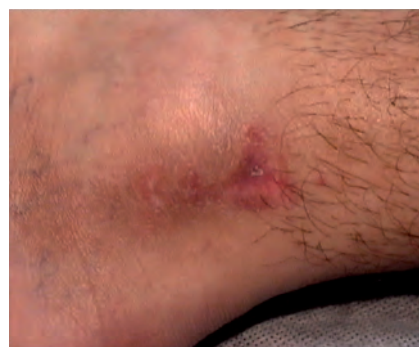1. Cleansing the ulcer with ozonized water (20 mcrg/ml)
2. Peripheral infiltration with saline serum + lidocaine and posterior infiltration of an oxygen/ozone mixture (12 mcrg/ml)
3. Aspiration with a bell connected to an emptying machine.
4. Application of a plastic bag with an oxygen/ozone mixture at 100 mcrg/ml (sterilization).
5. The bag was removed and a garze soaked in serum applied to the ulcer and closed.

Disease Evolution

The wound close in only two weeks leaving a thick scar which was treated by perilesional infiltration of ozone.



A



B

Figura 2
Figure 2

Toma durante 20 días antibióticos y analgésicos, llegando a mí como lo presenta en la foto 1.

Tratamiento local

1. Limpieza de la úlcera con agua ozonizada a 20 microgramos/ml. Retirando bien los esfacelos.
2. Infiltración periférica (3-5 cm del borde de la úlcera) con suero salino (10 cc)+Lidocaina (1 ampolla).
3. Infiltración posterior de Ozono/oxígeno a 12 microgramos /mililitro.
4. Aspiración con la campana conectado a una bomba de vacío
5. Aplicación de Ozono/Oxígeno a 100 microgramos /mililitro, en bolsa de plástico durante 15 minutos
6. Retirar bolsa y cerrar la úlcera con gasa empapada de suero propio del paciente rico en plasma rico en plaquetas (PRP)

Resultado: en tan solo 15 días la herida cerró dejando cierta cicatriz reaccional que se solucionó infiltrando ozono perilesional, previa aplicación de de Ozono

Caso N° 3

Herida provoca da por la rozadura de un paraguas que no curaba después de tres meses de evolución. La úlcera de ubicaba en zona anterior de pierna izquierda, de aspecto circular, no muy profundo, de aspecto limpio. La paciente no era diabética, ni hipertensa, ni tampoco presentaba ninguna molestia, tan solo desesperación de que la úlcera que no cerraba.

Tratamiento local

1. Limpieza de la úlcera con agua ozonizada a 20 microgramos/ml. Retirando bien los esfacelos.
2. Autosanguis IM con 5 cc de sangre ozonizada propia con una ampolla de Placenta compositum.
3. Cerrar la úlcera con gasa empapada de suero

Case No.3: A 63-year-old housewife had a wound caused by an umbrella which had not healed after three months of traditional treatment. The ulcer was roundish, shallow and appeared clean, located on the anterior part of the left leg. The patient was not diabetic or hypertensive, nor did she present any other disorder but was worried that the ulcer had not healed.

Local Treatment

1. Cleansing the ulcer with ozonized water (20 mcrg/ml)
2. Intramuscular autohaemotherapy with 5 cc of the patient's ozonized blood mixed with a phial of Placenta compositum.
3. The bag was removed and a garze soaked in serum applied to the ulcer and closed

Evolution: One week later there was perilesional skin growth and after two weeks the ulcer was totally closed as seen in the photograph.

Conclusions

Generally speaking, scarring of an ulcer treated with ozone depends on:

1. The time passed since onset (chronicity)
2. The patient's age (doubtful?)
3. The patient's biochemical parameters (glycaemia, cholesterol, triglyceride levels, etc.)
4. Complete sterilization of the ulcer (fundus and surrounding tissues) which in turn depends on the concentration of ozone (80-100 mcr/ml).
5. The activity of granulation tissue like re-epithelization which depends on the growth factors contains in the platelets released.
6. In the last two cases ozone was not applied in bags and in the last case painful peripheral infiltration was avoided.

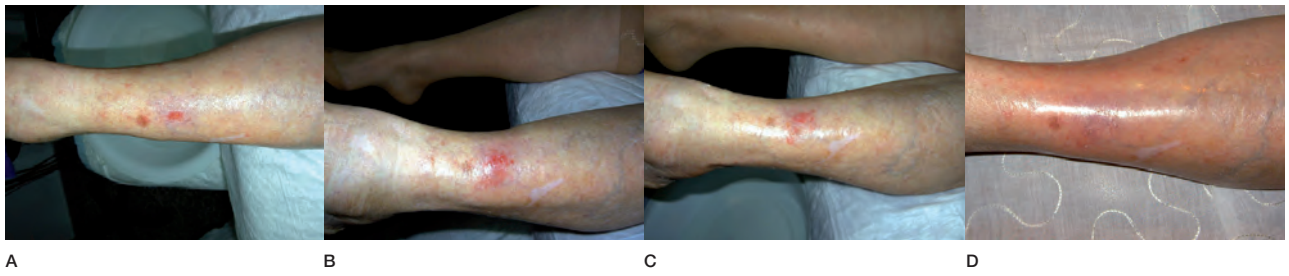
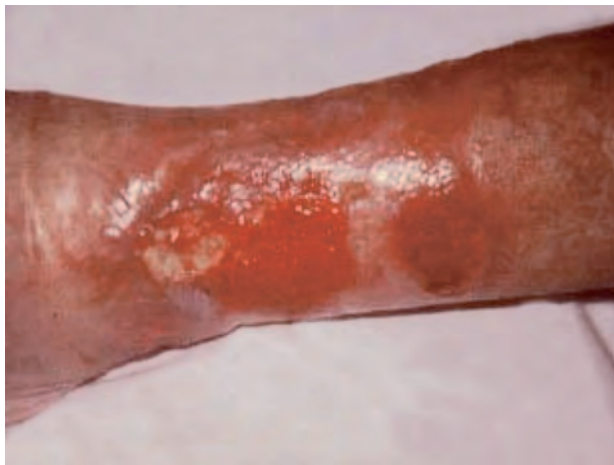
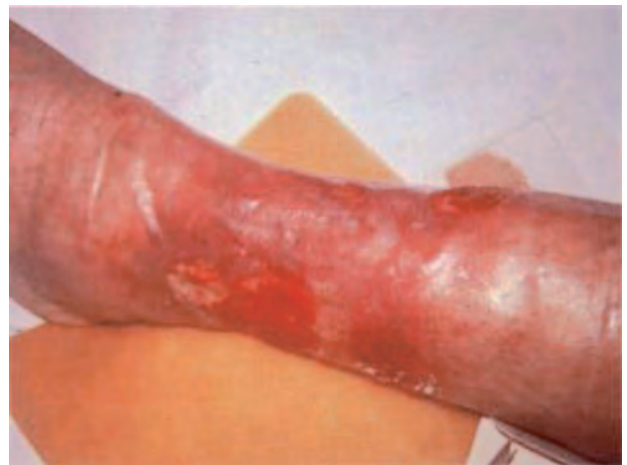
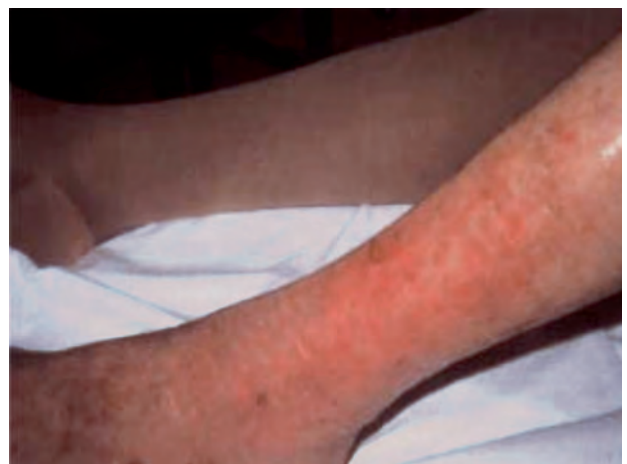Figura 3
Figure 3



A



B



C

Figura 4 Ulceras cutáneas tratadas con oxígeno-ozono-terapia (por gentileza de Dr Tabaracci).
Figure 4 Skin ulcers treated by ozone therapy (courtesy of Dr Tabaracci).

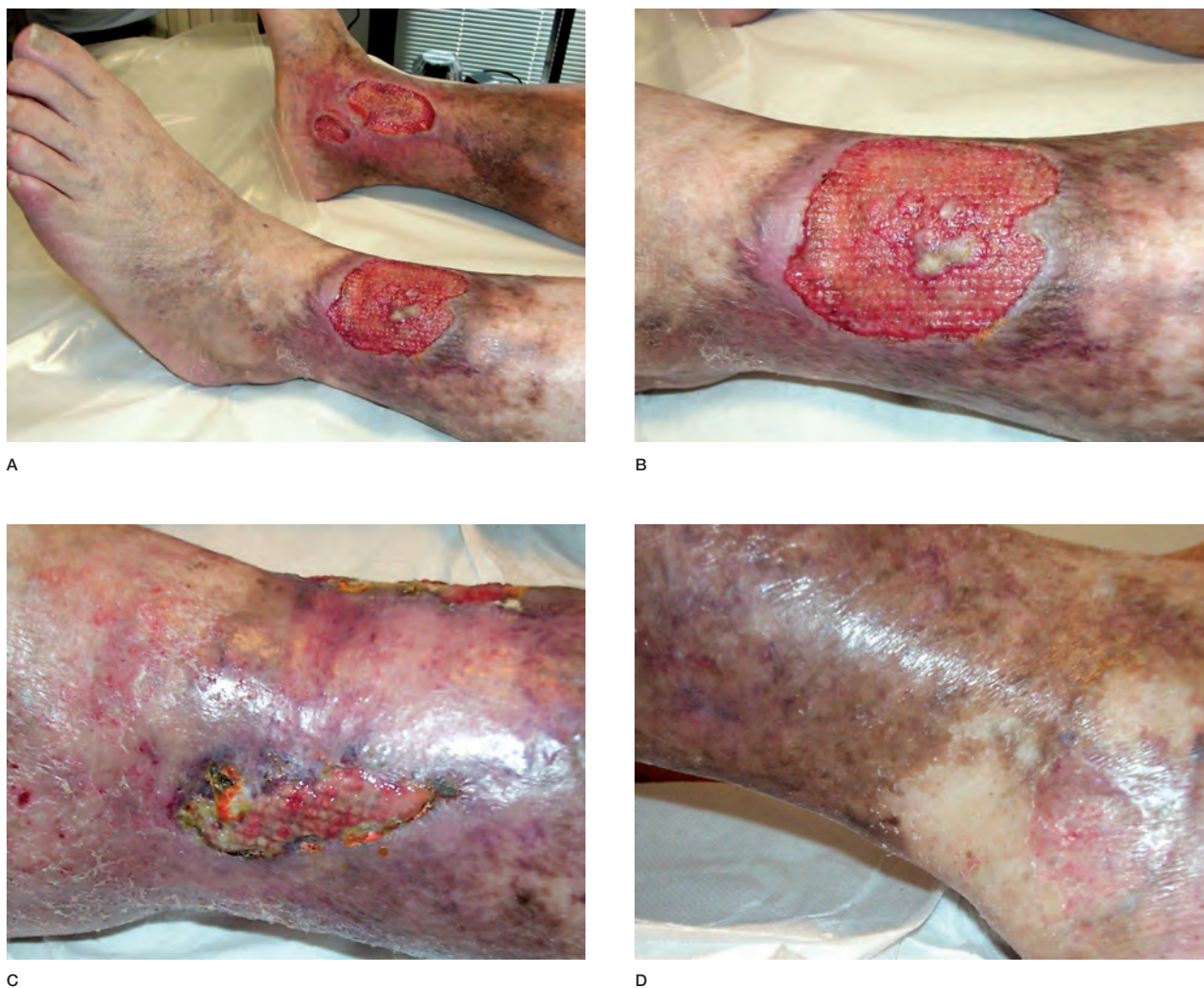

Figura 5 Úlceras cutáneas tratadas con oxígeno-ozono-terapia (por gentileza de Dr Tabaracci).
 Figure 5 Skin ulcers treated by ozone therapy (courtesy of Dr Tabaracci).

propio del paciente rico en plasma rico en plaquetas (PRP)

Evolución: A la semana aparecía crecimiento epidérmico perilesional y a los 15 días, la úlcera esta totalmente cerrada y su epidermis regenerada.

Conclusiones

La cicatrización de una úlcera tratada con Ozono depende en términos generales

1. Del tiempo desde su aparición (cronicidad)
2. De la edad del paciente.(dudoso)
3. De la bioquímica que presente (niveles de glucemia, colesterol, triglicéridos....etc)
4. Importancia de la esterilización completa de la úlcera (fondo y tejido circundante). Esto compete

al Ozono en dosis de 80-100 microgramos/ml.

5. La activación del tejido de granulación como la re-epidermización depende de los factores de crecimiento contenidos en las plaquetas que al degranularse se liberan. Son las citoquinas que movilizaran a los fibroblastos necesarios.

6. En las dos últimos casos. Podemos observar que se prescinde de la aplicación de Ozono en bolsas; y en la última de las infiltraciones de Ozono periféricas (son muy dolorosas).

Dr José Faus Vitoria
 N° Col. 9582 (Valencia)-España
 Republica Argentina, 52, 2º, 3ª
 46701-Gandia (Valencia)
 E-mail: drfaus@ono.com
 Web: www.doctorfaus.com

Changes in Haemochromocytometric Values in Horses after Ozone Auto-haemotransfusion

E. BALLARDINI

Veterinary Surgeon

Key words: Mayor Ozone autohaemotransfusion (MAHT), ozonized blood transfusions, trotting horses

SUMMARY - This study investigated the short-term immune response following major ozone autohaemotransfusion (MAHT) in nine competition horses with normal blood tests (haemoglobin, haematocrit, white blood cells - granulocytes, lymphocytes/monocytes -platelets) and one horse with a form of anaemia. All horses showed an enhanced athletic performance after MAHT. Clinical studies in man have demonstrated the therapeutic efficacy of one or more ozonized blood transfusions, this short study demonstrates the potential of this alternative treatment in horses.

Introduction

This study investigated the short-term immune response in a sample of nine competition horses with normal blood tests before treatment (haemoglobin, haematocrit, white blood cells - granulocytes, lymphocytes/monocytes -platelets) and one horse with a form of anaemia following major ozone autohaemotransfusion (MAHT). The study was conducted during 2004 up to the first quarter of 2005.

Anemia is a reduction in erythrocytes or haemoglobin in a unit volume of blood leading to a decrease in haematocrit (the percentage of red blood cells in a blood sample after centrifugation). Equine anaemias are classified as haemorrhagic anemia, haemolytic anemia and anemia due to decreased erythrocyte production¹. Haemorrhagic equine anaemias include: rhinorrhagia, often secondary to guttural pouch lesions in the resting horse, but usually of pulmonary origin when the animal is under stress; massive strongyloid infestations, traumatic injury during a race, and haemophilia. Equine disease characterized by haemolytic anemia includes: babesiosis or pyroplasmiasis, infectious equine anaemia, phenothiazine poisoning - even though this antihelminthic drug is currently little used for horses; isoerythrolysis of newborn foals, autoimmune haemolytic anaemias and snake's bite anaemia. Anaemia due to a decreased production of erythrocytes and haemoglobin include: nutritional deficiencies like copper, cobalt, iron and folic acid; chronic diseases like

radiating injuries, fern or arsenic poisoning, intestinal parasites, etc.

Anaemia is usually mild in racing horses (galloping and trotting horses) and competition horses (jumping and dressage horses) but it inevitably determines a decrease in athletic performance during intense exercise.

Materials and Methods

The following materials were used:

- An IDEXX QBC Autoread for haemochromocytometric tests: haemoglobin, haematocrit, MCHC, white blood cells (granulocytes, lymphocytes/monocytes) and platelets (The IDEXX Autoread QBC does not calculate the number of red blood cells);
- A portable Ozonline Isis 2000 device with a 5 litre oxygen cylinder, 1000 ml Grifols blood bags and sodium citrate solution in 1000 ml Grifols bags as anticoagulant at a dose on 1ml of ACD solution for every 10 ml of ozonized blood.

Blood samples from nine Italian trotting horses were tested. All horses were apparently healthy and in full competition activity. On the same day all horses underwent major autohaemotransfusion (MAHT) with 500 ml ozonized blood (500 ml venous blood + 500cc ozone in 1000 ml bags) at an ozone concentration of 40 mg/ml of blood. A second blood sample was taken from the horses 72 h after MAHT for comparison.

The tenth horse had a form of anaemia but unfortunately no further tests were done to establish the etiology of the disease. This animal (*Case 10*) had

¹ Blood-Henderson



Figure 1

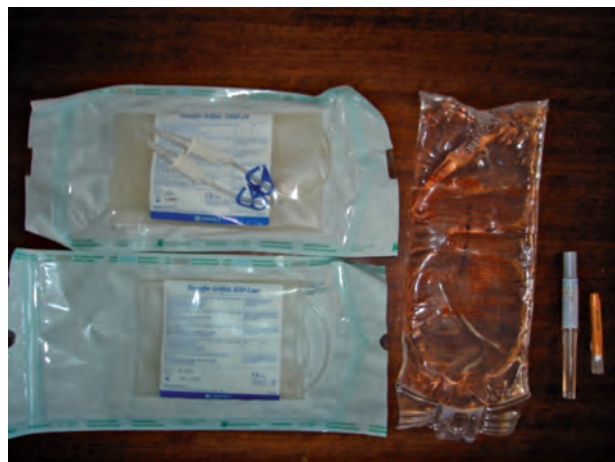

Figure 2



Figure 3

very low haematocrit and haemoglobin values accompanied by pale mucous membranes, sensory depression, loss of appetite and reduced athletic performance. The horse underwent MAHT on the same day infusing 500 ml of ozonized blood at an ozone concentration of 40 mg/ml blood. A second blood sample was taken three days later followed by a second session of MAHT identical to the first. A third and last blood sample was taken after

another three days and compared with the results of the previous samples.

Standard equine values according to the IDEXX parameters are: haematocrit from 32% to 52%, haemoglobin from 11.0 to 18.0 g/dl, MCHC from 31 to 36 g/dl, white blood cells from 6.0 to $12.5 \times 10^9/L$, of which granulocytes from 2.8 to $8.0 \times 10^9/L$ and lymphocytes/monocytes from 2.1 to $7.0 \times 10^9/L$, platelets from 90 to $350 \times 10^9/L$.




Figure 4



Figure 5

Case 1: four-year-old male trotting horse

<i>Profile</i>	<i>Reference values</i>		<i>Initial values</i>	<i>Values at 72 h</i>
Haematocrit	32.0-52.0	%	34.4	36.6
Haemoglobin	11.0-19.0	g/dl	12.6	13.4
MCHC	30.0-36.9	g/dl	36.6	36.6
White blood cells	6.0-12.5	$\times 10^9/L$	10.1	10.0
Granulocytes	2.8-8.0	$\times 10^9/L$	6.1	6.4
Lymphocytes/monocytes	2.1-7.0	$\times 10^9/L$	4.0	3.6
Platelets	90-350	$\times 10^9/L$	40 low	104

Case 2: four-year-old female trotting horse

<i>Profile</i>	<i>Reference values</i>		<i>Initial values</i>	<i>Values at 72 h</i>
Haematocrit	32.0-52.0	%	37.7	42.1
Haemoglobin	11.0-19.0	g/dl	13.7	15.1
MCHC	30.0-36.9	g/dl	36.3	35.9
White blood cells	6.0-12.5	$\times 10^9/L$	9.6	9.4
Granulocytes	2.8-8.0	$\times 10^9/L$	5.6	5.2
Lymphocytes/monocytes	2.1-7.0	$\times 10^9/L$	4.0	4.2
Platelets	90-350	$\times 10^9/L$	167	122

Results and Discussion

Case 1 had thrombocytopenia of unknown etiology: three days after MAHT the platelet values had normalized. Horses ^{5,7,8}, and in part also case 6 whose white blood cells were close to the upper limit, had an ongoing infection (increased white blood cells or some of them above normal limits) without visible mental or physical changes (no

fever, normal sensory response, appetite and athletic performance). As shown in the tables, values in all four horses had normalized three days after MAHT.

Cases 2, 3, 4 and 9 had normal blood tests. Three days after MAHT there was a 5% increase in haematocrit in two horses, whereas values remained unchanged in the other two animals.

Case 10, the horse with a form of anaemia

Case 3: three-year-old female trotting horse

<i>Profile</i>	<i>Reference values</i>		<i>Initial values</i>	<i>Values at 72 h</i>
Haematocrit	32.0-52.0	%	39.1	40.3
Haemoglobin	11.0-19.0	g/dl	14.1	14.3
MCHC	30.0-36.9	g/dl	36.1	35.5
White blood cells	6.0-12.5	$\times 10^9/L$	9.3	9.2
Granulocytes	2.8-8.0	$\times 10^9/L$	5.9	5.0
Lymphocytes/monocytes	2.1-7.0	$\times 10^9/L$	3.4	4.2
Platelets	90-350	$\times 10^9/L$	146	159

Case 4: six-year-old gelding trotting horse

<i>Profile</i>	<i>Reference values</i>		<i>Initial values</i>	<i>Values at 72 h</i>
Haematocrit	32.0-52.0	%	39.5	45.9
Haemoglobin	11.0-19.0	g/dl	14.3	16.6
MCHC	30.0-36.9	g/dl	36.2	36.2
White blood cells	6.0-12.5	$\times 10^9/L$	8.9	10.5
Granulocytes	2.8-8.0	$\times 10^9/L$	5.5	6.21
Lymphocytes/monocytes	2.1-7.0	$\times 10^9/L$	3.4	4.4
Platelets	90-350	$\times 10^9/L$	143	170

Case 5: two-year-old male trotting horse

<i>Profile</i>	<i>Reference values</i>		<i>Initial values</i>	<i>Values at 72 h</i>
Haematocrit	32.0-52.0	%	38.5	36.6
Haemoglobin	11.0-19.0	g/dl	13.5	13.4
MCHC	30.0-36.9	g/dl	35.1	36.6
White blood cells	6.0-12.5	$\times 10^9/L$	12.3	10.0
Granulocytes	2.8-8.0	$\times 10^9/L$	4.9	6.4
Lymphocytes/monocytes	2.1-7.0	$\times 10^9/L$	7.4 high	3.6
Platelets	90-350	$\times 10^9/L$	72 low	166

which had two MAHT sessions, presented a 10% increase in haematocrit from 28.8% before treatment to 34.5% after the first MAHT rising to 38% after the second and last MAHT session. These values were accompanied by an improvement in the horse's physical and mental wellbeing with a normalization of mucous membranes, a return of appetite, improved sensory response and athletic performance.

Lastly, all treated horses showed an enhanced athletic performance after MAHT.

In conclusion, in-depth clinical studies in man¹⁻³ have demonstrated the therapeutic efficacy of one or more ozonized blood transfusions. This short study demonstrates the potential of this alternative treatment in horses. Further results will emerge from investigations by clinical and university facilities using novel diagnostic techniques on larger cohorts. The scepticism surrounding alternative treatments in the world of horses is currently a drawback. The lack of tests on the application of ozone in horses means that the therapeutic proto-

Case 6: three-year-old female trotting horse

<i>Profile</i>	<i>Reference values</i>		<i>Initial values</i>	<i>Values at 72 h</i>
Haematocrit	32.0-52.0	%	44.8	45.1
Haemoglobin	11.0-19.0	g/dl	15.4	15.6
MCHC	30.0-36.9	g/dl	34.4	34.6
White blood cells	6.0-12.5	$\times 10^9/L$	12.3	10.1
Granulocytes	2.8-8.0	$\times 10^9/L$	7.5	5.1
Lymphocytes/monocytes	2.1-7.0	$\times 10^9/L$	4.8	5.0
Platelets	90-350	$\times 10^9/L$	176	214

Case 7: seven-year-old female trotting horse

<i>Profile</i>	<i>Reference values</i>		<i>Initial values</i>	<i>Values at 72 h</i>
Haematocrit	32.0-52.0	%	45.3	42.5
Haemoglobin	11.0-19.0	g/dl	15.8	15.1
MCHC	30.0-36.9	g/dl	34.9	35.5
White blood cells	6.0-12.5	$\times 10^9/L$	12.7 high	10.7
Granulocytes	2.8-8.0	$\times 10^9/L$	8.3 high	6.7
Lymphocytes/monocytes	2.1-7.0	$\times 10^9/L$	4.4	4.0
Platelets	90-350	$\times 10^9/L$	214	201

Case 8: two-year-old male trotting horse

<i>Profile</i>	<i>Reference values</i>		<i>Initial values</i>	<i>Values at 72 h</i>
Haematocrit	32.0-52.0	%	38.2	40.0
Haemoglobin	11.0-19.0	g/dl	13.5	14.2
MCHC	30.0-36.9	g/dl	35.3	35.5
White blood cells	6.0-12.5	$\times 10^9/L$	14.0 high	9.6
Granulocytes	2.8-8.0	$\times 10^9/L$	5.5	4.8
Lymphocytes/monocytes	2.1-7.0	$\times 10^9/L$	8.5 high	4.8
Platelets	90-350	$\times 10^9/L$	98	131

Case 9: seven-year-old male trotting horse

<i>Profile</i>	<i>Reference values</i>		<i>Initial values</i>	<i>Values at 72 h</i>
Haematocrit	32.0-52.0	%	42.2	41.0
Haemoglobin	11.0-19.0	g/dl	15.4	14.8
MCHC	30.0-36.9	g/dl	36.5	36.1
White blood cells	6.0-12.5	$\times 10^9/L$	10.6	11.6
Granulocytes	2.8-8.0	$\times 10^9/L$	7.4	7.6
Lymphocytes/monocytes	2.1-7.0	$\times 10^9/L$	3.2	4.0
Platelets	90-350	$\times 10^9/L$	155	143

Case 10: three-year-old female trotting horse

<i>Profile</i>	<i>Reference values</i>		<i>Initial values</i>	<i>Values at 72 h</i>	<i>Values at 144 h</i>
Haematocrit	32.0-52.0	%	28.8 low	34.5	38.0
Haemoglobin	11.0-19.0	g/dl	10.6 low	12.7	13.8
MCHC	30.0-36.9	g/dl	36.8	36.8	36.3
White blood cells	6.0-12.5	×10 ⁹ /L	8.4	7.9	8.7
Granulocytes	2.8-8.0	×10 ⁹ /L	5.4	3.3	5.2
Lymphocytes/monocytes	2.1-7.0	×10 ⁹ /L	3.0	4.6	3.5
Platelets	90-350	×10 ⁹ /L	116	201	200

cols adopted are improvised and applied by adjusting those implemented in human applications. The same applies to the veterinary literature largely available on the Internet⁴⁻⁹.

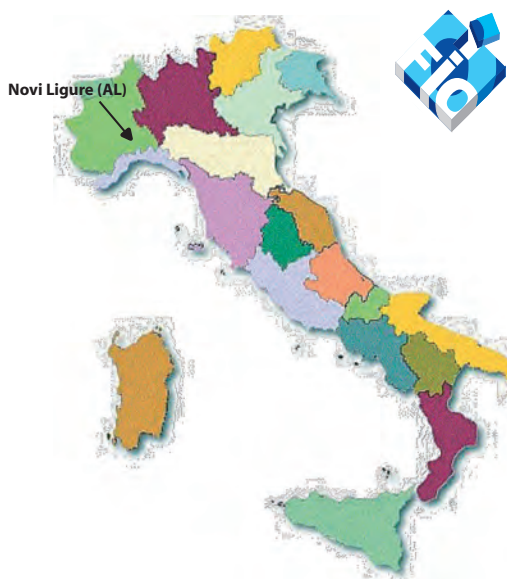Although still in the early stages of research, the

application of MAHT in my practice to trotting horses with respiratory, hepatic and locomotor and other physical problems using intra and peri-articular, ligamental and muscular infiltration is yielding good results¹⁰.

References

- 1 Bocci V: Ozone. A New Medical Drug. Springer Verlag, Heidelberg 2005.
- 2 Bocci V, Valacchi G, Rossi R et Al: Studies on the biological effects of ozone: 9. Effects of ozone on human platelets. Platelets 10: 110-116, 1999.
- 3 Coppola L. et Al: Oxygen-Ozone therapy and haemorheological parameters in peripheral chronic arterial occlusive disease. Trombosi e Arteriosclerosi 3: 1992.
- 4 Castrini A, Prignacca E: Protocollo di trattamento dell'ernia discale con ossigeno-ozono terapia nel cane. Rivista Italiana di Ossigeno-Ozono Terapia 1: 113-115, 2002.
- 5 Erichsen C, Eksell P et Al: Relationship between scintigraphic and radiographic evaluations of spinous processes in the thoracolumbar spine in riding horses without clinical signs of back problems. Equine Vet J 36: 458-465, 2004.
- 6 Haussler KK, Stover SM, Willits NH: Pathologic changes in the lumbosacral vertebrae and pelvis in thoroughbred racehorses. Am. J. vet. Res. 60: 143-153, 1999.
- 7 Hendrickson D: The thoracolumbar spine, In: Adams' Lameness in Horses, 5th edn., Ed: T. Stashak, Lippincott Williams & Wilkins, Baltimore 2002: 1053-1057, 2002.
- 8 Jeffcott LB: Pelvic lameness in the horse. Eq. Pract. 4: 21, 1982.
- 9 Jeffcott LB: Disorders of the thoracolumbar spine of the horse - a survey of 443 cases. Equine vet. J. 12: 197-210, 1980.
- 10 Ballardini E: Oxygen-Ozone Therapy for spinal muscle disorders in the horse. Rivista Italiana di Ossigeno-ozono terapia 4: 70-73, 2005.

Dr E. Ballardini
Via Achillini, 7
I - 40137 Bologna
Tel. +39 347 5301464
E-mail: ettoreballardini@tiscali.it



I SABATI DI OZONOTERAPIA

4 Marzo 2006

Novi Ligure (AL)

Reportage



Dr F. Parodi, Dr M. Bonetti



Dr G. Tabaracci, Dr M. Sirito



Dr Cardelli



Dr M. Cutellè, Dr Cardelli, Dr Dall'Aglio



Segreteria Organizzativa:

X-RAY SERVICE:

Tel +39.030.3197173 - Fax +39.030.3197171 - E-mail: info@xrayservice.it



Sabato 11 marzo 2006 - Jolly Hotel, Assago, Milano

Rachide & Riabilitazione multidisciplinare - Secondo Evidence-Based Meeting

www.isico.it/rer2006

Presidente: Stefano Negrini – Presidente Onorario: Silvano Boccardi

In collaborazione con il Gruppo di Studio della Scoliosi e delle Patologie Vertebrali (GSS)

Patrocini richiesti

Società Italiana Medicina Fisica Riabilitativa (SIMFER) - Società Italiana di Ortopedia e Traumatologia (SIOT)

Società Italiana di Medicina Generale (SIMG) - Società Italiana di Reumatologia (SIR)

Associazione Italiana Fisioterapisti (AIFI) - Società Italiana Ginnastica Medica (SIGM) - Unione Nazionale Chinesitologi (UNC)

Società Italiana di Medicina del Lavoro e Igiene Industriali (SIMLII) - Federazione Medico Sportiva Italiana (FMSI)

VINCITORI PER L'ANNO 2006 (il primo premio verrà assegnato in sede congressuale anche con il voto dei partecipanti al congresso)

Aina A, May S, Clare H - The centralization phenomenon of spinal symptoms-a systematic review. Man Ther. 2004; 9(3):134-43. • Bonetti M, Fontana A, Cotticelli B, Volta GD, Guindani M, Leonardi M - Intraforaminal O(2)-O(3) versus periradicular steroidal infiltrations in lower back pain: randomized controlled study. AJNR Am J Neuroradiol. 2005; 26(5): 996-1000. • Padua L, Caliendo P, Aprile I, Pazzaglia C, Padua R, Calistri A, Tonali P - Back pain in pregnancy: 1-year follow-up of untreated cases. Eur Spine J. 2005; 14(2):151-4. • Padua L, Padua R, Mastantuoni G, Pitta L, Caliendo P, Aulisa L - Health-related quality of life after surgical treatment for lumbar stenosis. Spine. 2004; 1-29(15): 1670-5. • Smania N, Corato E, Fiaschi A, Pietropoli P, Agliotti SM, Tinazzi M - Repetitive magnetic stimulation A novel therapeutic approach for myofascial pain syndrome. J Neurol. 2005; 252(3): 307-14. • Splendiani A, Puglielli E, De Amicis R, Barile A, Masciocchi C, Gallucci M - Spontaneous resolution of lumbar disk herniation: predictive signs for prognostic evaluation. Neuroradiology. 2004; 46(11): 916-22.



Dr. Bonetti receiving the ISICO prize



Dr Stefano Negrini, ISICO Chairman



Dr. Bonetti proudly shows the ISICO prize



Title page of the article for which our Scientific Editor was awarded the ISICO prize

AJNR Am J Neuroradiol 26:996–1000, May 2005

Intraforaminal O₂-O₃ versus Periradicular Steroidal Infiltrations in Lower Back Pain: Randomized Controlled Study

Matteo Bonetti, Alessandro Fontana, Biagio Cotticelli, Giorgio Dalla Volta, Massimiliano Guindani, and Marco Leonardi

BACKGROUND AND PURPOSE: Reports about steroids and oxygen-ozone therapy to treat lower back pain have been increasing. The purpose of our study was to compare the clinical outcomes in patients treated with infiltrations of O₂-O₃ gas or steroids at short-, medium-, and long-term follow-up.

METHODS: A total of 306 patients (166 with primarily disk disease, 140 with nondisk vertebral disease) with acute or chronic low back and sciatic nerve pain received a CT-guided intraforaminal infiltration of an O₂-O₃ gas mixture or an periradicular infiltration of steroids. Neurologists unaware of the type of treatment assessed the patients.

RESULTS: At 1-week follow-up, most patients had a complete remission of pain, regardless of the treatment. At 6-month follow-up, differences in favor of O₂-O₃ treatment were significant in patients with disk disease ($P = .0021$) but not in those without disk disease ($P = .0992$). Clinical outcomes were poor in 13 (15.1%) of 86 patients receiving O₂-O₃ infiltration and in 18 (22.5%) of 80 patients receiving steroid injection ($P = .2226$). Among patients without disk disease, six (8.6%) of 70 patients receiving O₂-O₃ infiltration but 21.4% of the patients receiving steroid injections had poor outcomes ($P = .0332$).

CONCLUSION: Oxygen-ozone treatment was highly effective in relieving acute and chronic lower back pain and sciatica. The gas mixture can be administered as a first treatment to replace epidural steroids.

Lower back pain with or without sciatic nerve involvement affects roughly 80% of the population at least once in their lifetime. In addition, lower back pain is the leading cause of lost working days, which has a major effect on national healthcare spending (1). Until 15 years ago, surgery was the treatment of choice, but conservative measures are now preferred in the wake of unsatisfactory surgical outcomes (2). Among the techniques adopted in the past decade to treat sciatic nerve pain caused by a herniated disk or non-diskal spinal disease (osteophytosis, spondylolysis, facet joint syndrome, etc.) are the periradicular infiltration of a steroid and the intraforaminal injection of

an O₂-O₃ gas mixture. Both methods have yielded encouraging results (3–7).

We compared the therapeutic effectiveness of these methods, undertaking a randomized controlled study in 306 patients with acute or chronic low back pain and sciatica. Patients were treated with either an intraforaminal infiltration of an O₂-O₃ gas mixture or the periradicular infiltration of steroid.

Methods

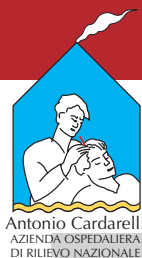Between March 2001 and December 2003, 306 patients (178 men, 128 women; age range, 26–72 years; mean age, 48 years) with acute or chronic low back and sciatic nerve pain were treated. All patients provided informed consent. Patients received CT-guided infiltration of an O₂-O₃ gas mixture or a steroid, and they were told that both were effective treatments according to recent findings reported in medical literature.

On their enrollment, the name, date of birth, date of enrollment, date of treatment and clinical details were recorded for each patient. We recorded the type of pain, irradiation, paresthesias, presence of the Lasègue sign, degree of sensitivity, lower limb reflexes, plantar extension of the foot, and dorsal extension of the big toe. Their records also included details about the type of treatment given (steroid or O₂-O₃ mixture), but this information was withheld from the neurologists performing the follow-up assessment. Patients had acute or

Received June 28, 2004; accepted after revision August 19.

From the Department of Neuroradiology and Division of Neurology, Istituto Clinico Città di Brescia (M.B., A.F., G.D.V.), the Division of Neurology, Casa di Cura S. Anna (B.C., M.G.), and the Department of Neuroradiology Ospedale Bellaria, Bologna (M.L.), Italy.


Address reprint requests to Dr Matteo Bonetti, Servizio di Neuroradiologia, Istituto Clinico Città di Brescia, Via Gualla 15, I-25123 Brescia, Italy.



Antonio Cardarelli
AZIENDA OSPEDALIERA
DI RILIEVO NAZIONALE



Stroke and Spine Meeting in Naples



Presidenti

Dott. M. Muto - Napoli

Prof. S. Cirillo - Napoli

Napoli, 26 - 27 aprile 2006

Hotel S. Francesco al Monte
Corso Vittorio Emanuele, 328 - Napoli

Organizzazione Scientifica

U.O. di Neuroradiologia
A.O.R.N. Cardarelli
Via A. Cardarelli, 9 - Napoli
Tel.: 081 7473838 Fax: 081 7473825
E-mail: mario.muto@ospedalecardarelli.it

Segreteria Organizzativa

G.P. Pubbliche Relazioni s.r.l.
Via San Pasquale a Chiaia, 55
80121 Napoli
Tel.: 081 401201 - 412835 Fax: 081 404036
E-mail: info@gpcongress.com

Letter to the Editor

Dr Matteo Bonetti
Scientific Director
Rivista Italiana di Ossigeno-Ozonoterapia

Gent.mo Dott. Bonetti

sono il marito della Sig.ra PINA SCAFIDI di Roma e Le scrivo la presente solo ed UNICAMENTE per ringraziarla di quanto ha fatto.

Il Dott. Di Donato si è dimostrato un medico assolutamente preparato, disponibile, umano.

Mia moglie, grazie a voi, ha finalmente risolto il suo problema dell'ernia "mostruosa". Ora non so se sia dovuto alla Sua infiltrazione di Brescia o a quelle (3 in tutto!) di Di Donato... fatto sta che STA BENISSIMO!

Non ha più alcun disturbo né fastidio.

Dietro suggerimento del Dott. Di Donato sta facendo piscina e, grazie alle sofferenze atroci patite con l'ernia, ha anche trovato il coraggio di superare una sua atavica FOBIA:

l'acqua! Sta imparando a nuotare e sta facendo una sorta di riabilitazione in acqua. Seguiranno ginnastica posturale ecc.

Insomma Dottor Bonetti, non ho realmente parole per dimostrarle la nostra gratitudine ma sappia che, la sua umanità e la sua disponibilità, saranno sempre nel nostro cuore e, per quanto nelle nostre possibilità, qualche persona in più, a Roma, sentirà parlare del Dott. Bonetti.

Ancora grazie per averci indirizzato da un medico splendido, umano, determinato ed eticamente onestissimo. La Sua FIO dovrebbe annoverare medici come VOI...

Con tutta la nostra gratitudine...

Pina e Renato

Cancer and Terrorism

Already before September 1st, desperate people have understood that, by killing themselves with explosives, they would call world attention to their problems. The spiral of violence increases every day and, while a bus or a building can be rebuilt, the life of innocent people is lost forever. Every tragic episode is followed by "serious political decisions to be united against terrorism"?

There are analogies between cancer and terrorism. Both are terrible diseases, the first affecting the human body and the second the human society. So far it is proved that symptomatic therapy is practically useless and only understanding the cause of the disease can lead to a cure. The human body hosts more than 10¹⁴ cells and, either for a genetic defect or to exogenous and exogenous carcinogens, it appears unavoidable that during our life time, a few cells become tumoral: unless killed by the immune surveillance they can proliferate, metastasize and kill the host. Unlike bacteria or viruses which, rather than killing the host, take advantage to proliferate and pass into other hosts, the strategy of the neoplastic cell is to become immortal even if eventually they all die with the host. While bacteria contribute to maintain the bulk of the earth biomass, the only meaning of the neoplastic cells is to terrorize and systematically kill each year between 0.2-0.3% of the world population, thus limiting growth. Mankind totals about 6x10⁹ individuals and, during the last year, the number of active or aspiring terrorists has grown to a few hundreds, yet more than enough because, with the destructive power of explosives, they have already killed more than one thousand innocent people. Both cancer and terrorists do not spare children, women or men of any age and their intent is to terrorize in the hope to call an action on their cause. Thus anyone of us has the duty to control and possibly eliminate cancer and terrorism.

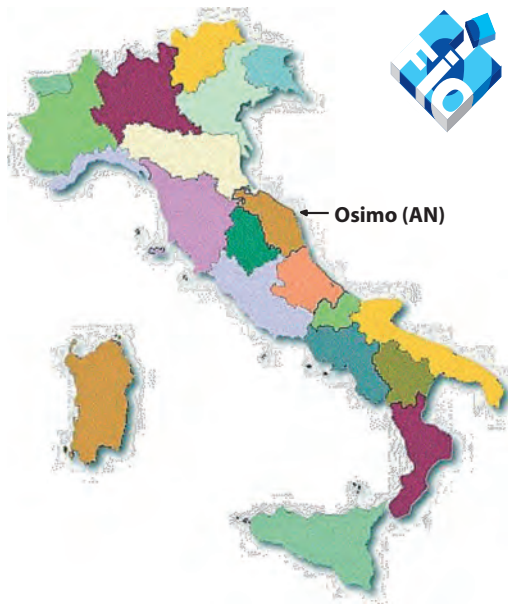During the last four decades an enormous amount of money has been spent to win the battle against cancer but, even with continuous small progresses, results are meagre and often the praised prolongation of survival has dire consequences in terms of quality of life. I am not complaining about the huge cancer expenses, actually we must do more but how

much have we done to avoid terrorism and has money to strengthen safety been well spent? What have world leaders done to allow a decent life to forlorn people or independence to other ethnic groups? History reminds us that revolutions have always been made by desperate and hungry people. Politicians' sorrow resembles the crocodile tears because in spite of "serious" intentions, so far nothing serious has been done. Since the Chinese Great Wall until the Berlin wall, we should have learnt that walls are eventually useless and we cannot hope now that an ugly cement wall will correct the weekly atrocities. By no means can I justify terrorism but particularly when performed by a young woman I consider it as an act of supreme desperation that deserves attention.

The therapeutic tactic between cancer and terrorism diverges because in the former we kill both neoplastic and normal cells but we cannot do this in the latter. Both cancer and terrorism will be tamed only if we can fully understand the causes and precisely correct them. It is time that all the worlds' leaders create opportunities for everyone because neither terrorism nor continuous wars solve the problem. I challenge every economist to prove that I am wrong when I say that with all the billion dollars wasted during four decades of arab-israelian conflicts (not to speak about death and suffering), by now we would have built a villa with swimming pool to each Palestinian and Israelian family. Obviously selfishness, greed and dishonesty have tarnished human's intelligence.

Velio Bocci

Velio Bocci MD
Emeritus Professor of Physiology
University of Siena
via Moro 2,
53100 Siena - Italy
E-mail: bocci@unisi.it
Tel.: +39 (0)577 234226
Fax: +39 (0) 577 234219



CORSO ITINERANTE IN OSSIGENO-OZONOTERAPIA 5 Novembre 2006

Osimo - Ancona

Reportage



Congress centre



Dr Bonetti, Dr Piana



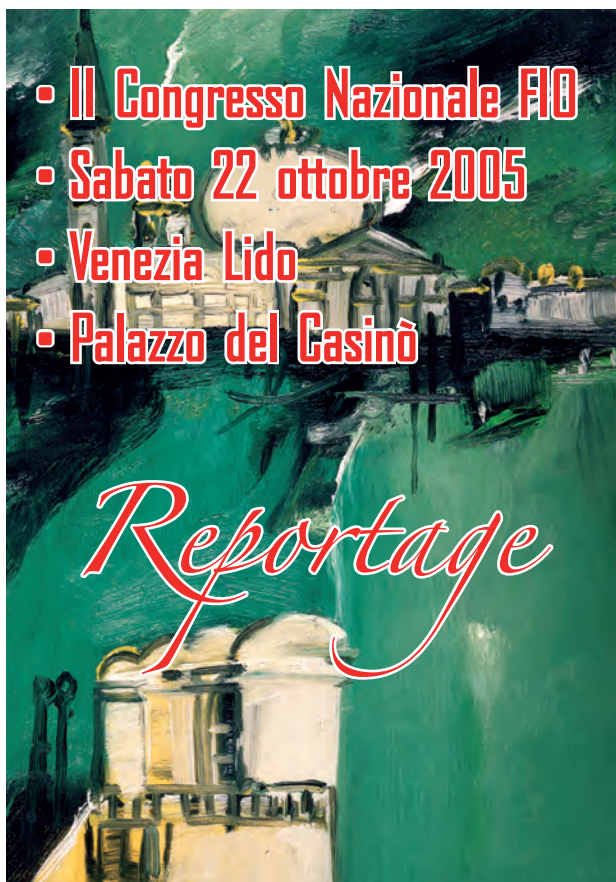Dr Piana, Dr Stramentinoli



Dr Piana and Organizational Staff
Osimo Congress



Segreteria Organizzativa:
X-RAY SERVICE:
Tel +39.030.3197173 - Fax +39.030.3197171 - E-mail: info@xrayservice.it



Prof. Bocci, Prof. Leonardi



Dr. Bonetti, Prof. Kumar



Prof. Kumar, Dr. Bragaglio



Dr. Bonetti, Dr. He



Conference Hall



Dr Vilasuso and daughter



Dr Bonetti, Dr Vylitelka



Chinese delegation



Dr Fontana

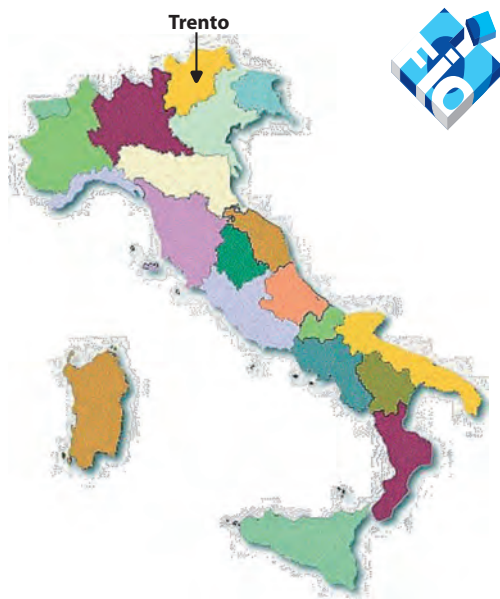

Dr Parodi



Dr Andreula, Dr Pellicanò





CORSO ITINERANTE IN
OSSIGENO-OZONOTERAPIA
24-25 Marzo 2006
Roncegno - Trento

Reportage



Dr L. Simonetti



Prof. E. Genovese



Prof. Ceron



Dr L. Brina



Segreteria Organizzativa:
X-RAY SERVICE:
Tel +39.030.3197173 - Fax +39.030.3197171 - E-mail: info@xrayservice.it



Dr Gjonovich



Dr Gjonovich, Dr Tabaracci, Dr Brina



Dr Tabaracci, Dr Bertozzi



Dr Tabaracci in Kabinett Ozono



Dr V. Bertozzi



Dr Fabris

Intermezzo



Eve. Lobby of the Metropolitan theater, Manila



Siamese dancer on a pillar of the theater's external cornice

Monti's first project in the Philippines was with Juan Arellano for the Metropolitan Theater of Manila.

Here Monti sculpted Adam and Eve for the lobby and concrete figures inside the theatre and outside the building.

This is one of three identical ballerinas and a Siamese dancer on top a pillar of the building's external cornice.



All the Photos by Anna Filippici Bonetti

The monument and sanctuary in Quezon is located in the national park in Quezon City, capital of the Philippines from 1948 to 1976. The monument, designed by the architect Federico Illustre, consists of three vertical pillars representing the three major divisions of the country: Luzon, Visayas and Mindanao. The monument is 66 metres high, surmounted by three angels in mourning supporting a crown of sampaguita, the national flower, carved by the sculptor Francesco Riccardo Monti.



WFOT – World Federation of Ozone Therapists

Constitution

Article 1 • Name - Duration - Site and Status

The World Federation of Ozone Therapists (hereafter “the WFOT”) is constituted for an unlimited period. It is an international non-profit making association founded in 2005.

The WFOT’s site shall in future be at the address of the President, or as otherwise directed by the Executive Committee. English will be its official language. The activities of the WFOT shall be in accordance with this Constitution. No salary shall be paid to any Member for any reason as remuneration for their activities on behalf of the WFOT.

Article 2 • Purposes of the WFOT

These are as follows:

- a) To promote the use of ozone – polyatomic oxygen in all the possible medical aspects.
- b) To co-ordinate work in and scientific documents and ensure adequate circulation throughout the world, as required.
- c) To co-ordinate relations between WFOT and the other clinical specialities devoted to the treatment of the same pathologies.
- d) To promote development of appropriate methods of teaching the use of ozone and to ensure that standards of training and (if appropriate) certification are obtained and maintained.

Article 3 • Methods of achieving the purposes laid out in Article 2

The WFOT shall:

- a) Hold a scientific meeting every two years at a time and place designated by the Executive Committee.
- b) Organise educational courses.
- c) Organise any other such meetings as well also promote its purposes.
- d) Award prizes or make scientific awards for work aimed at these purposes.
- e) Promote publication of an official journal and other appropriate documents..

Article 4 • Membership

The WFOT shall be composed of:

- *Society Members*
- *Full Members, individuals*
- *Associate Members*
- *Honorary Members*
- *Emeritus Members*
- *Corporate Members.*

Society Members

Duly constituted Medical Ozone National or Continental Societies.

This category is open to constituted scientific societies dedicated to the medical use of Ozone.

They shall pay an annual subscription, the amount of which will be determined by the WFOT.

The Society Members will be represented by their President, or delegate, as Member at Large in the WFOT Executive Committee.

The Society Members will be entitled to one vote every 50 members or their society.

Full Members, individuals

This category shall be limited to medical practitioners active in the medical use of ozone. Full Members shall enjoy all rights and privileges of membership of the WFOT, including the rights to vote, to serve on committees and to hold any office in the WFOT. They shall pay an annual subscription, the amount of which will be determined by the WFOT. The rights and privileges shall be forfeit if, over a period to be determined by the WFOT, currently two calendar years, the Member does not pay the annual subscription. Full Members whose membership lapses in this way will be eligible to apply for reinstatement on payment of the appropriate subscription.

Associate Members, individuals

The category is open to any individual not eligible for Full Membership. Associate Members have all the rights and privileges of membership of the WFOT, but are not entitled to vote, neither to serve on Committees except as consultants or to hold any office in the WFOT. They will pay an annual subscription fee, the amount of which will be determined by the Society. The rights and privileges shall be forfeit if, over a period to be determined by the Society, currently two calendar years, the Member does not pay the annual subscription. Associate Members whose membership lapses in this way will be eligible to apply for reinstatement on payment of the appropriate subscription.

Honorary Members and Honorary Presidents, individuals

Honorary Membership is conferred by the WFOT upon individuals who are judged to have made outstanding contributions. Conferment of Membership will be proposed by the Executive Committee and must be confirmed by a simple majority of voting Members. Honorary Members will have all the rights and privileges of Full Membership of the WFOT.

Individuals who are considered suitably distinguished may be nominated as Honorary Presidents of the WFOT. Nominations should be made to the Secretary General. They will then be considered by the Membership Committee, who will make a recommendation to the Executive Committee. Conferment of this honour, which is for life, will require ratification by the General Assembly.

A Full Member who is no longer in active practice may apply to the Membership Committee to modify his or her status. Emeritus Members have all the rights and privileges of membership of the WFOT, but are not entitled to vote, neither to serve on Committees except as consultants or to hold any office in the WFOT. They are not required to pay subscription fees.

Corporate Members

The category is open to companies active in fields related to the medical use of ozone and interested in closer collaboration with the WFOT. Corporate Members may send two delegates to the General Assembly, but they will not have the right to vote. Corporate Members shall pay an annual subscription, the amount of which will be determined by the WFOT. The rights and privileges shall be forfeit if, over a period to be determined by the WFOT, currently one calendar year, the Corporate Member does not pay the annual subscription. Corporate Members whose membership lapses in this way will be eligible to apply for reinstatement on payment of the appropriate subscription.

Termination of Membership

Membership may be terminated by:

- a) the Member resigning;
- b) the Member being removed from the list of Members by direction of the Executive Committee for serious causes, or for actions of such nature as to hinder the purposes of the WFOT; or
- c) for failure to pay annual subscriptions for a period to be determined by the WFOT, currently two years (or one year in the case of Corporate Members).

Article 5 • The administrative bodies of the WFOT

The administrative bodies shall be:

- a) The Executive Committee

- b) The General Assembly
- c) The Committees

Article 6 • The Executive Committee

The Executive Committee is formed by the following officers:

- i. The President
- ii. The Vice-President
- iii. The Past President
- iv. The General Secretary
- v. The Treasurer
- vi. Five Members-at-Large, elected by the General Assembly.
- vii. The Presidents, or delegates, of the Member Societies

The Executive Committee is responsible for managing and directing the scientific, financial and other activities of the WFOT. It shall meet when directed by the President, or at the request of a majority of its members.

Article 7 • Election of Officers

Any Full Member of the WFOT can seek election as Vice-President, Secretary General, Treasurer or Member-at-Large of the Executive Committee. These Officers shall be elected at the General Assembly to serve according to the provisions of this Article. The procedure for their election shall be as follows.

- a) Notice of candidature, with the names of the candidate and two Sponsors, who shall also be Full Members shall be sent, at least three months before the General Assembly, to the Secretary General, who will ascertain that the candidate is in good standing as a Full Member. The lists of candidates shall be inserted in the convocation to the General Assembly
- b) Voting for each office shall be by secret ballot, unless there is only one unopposed candidate, in which case a show of hands clearly indicating majority agreement will suffice.
- c) The results of the elections shall be announced at the General Assembly; the candidate for each post who has received the largest number of votes will be declared to have been elected. Should voting be tied, the election will be repeated, by secret ballot, at the same General Assembly.
- d) Newly-elected Officers will take office immediately after the General Assembly.
- e) The Officers constituting the Presidency will serve for one term, the length of which has been decided by the WFOT (currently two years), and will not be eligible for re-election at the immediate following term.
- f) The Officers of the Secretariat will serve for the term determined by the WFOT (currently two years), and be eligible for re-election.
- g) The Members-at-Large will serve for two years and will be eligible for re-election.

Duties of the Officers

President

The President shall be the presiding Officer of the WFOT and will perform all duties which custom and practice associate with his or her office. The President shall preside over meetings of the Executive Committee, including its meeting with the Council of National Delegates. The President, with the approval of the Executive Committee, and taking into account offers from individual members, and their competence, shall appoint Full Members to standing and ad hoc Committees. The President may personally convene an Advisory Board to be consulted upon specific items concerning the WFOT. The President shall serve for two years. If for some reason the President becomes unable or unwilling to continue in office before the end of his or her normal term, the Vice-President shall assume the post of President until the next General Assembly or a Special Business Meeting convened for this purpose.

Vice-President

The Vice-President will co-operate with the President as appropriate and assume the duties of the President if the latter is unable to serve, temporarily or, as indicated in the preceding clause, permanently.

He or she will also carry out such other duties as may reasonably be assigned by the President. If for some reason the Vice-President becomes unable or unwilling to continue in office before the end of his or her normal term, the post will remain vacant until the next General Assembly or a Special Business Meeting convened for this purpose.

The Executive Committee will seek nominations for this post, in the usual way. The newly-elected Vice-President will then serve until the end of the term of office of the current President.

Past President

After one term in office the President will automatically become Past President for a period of two years. He or she will co-operate with the President as appropriate, and will also carry out such other duties as may reasonably be assigned by the President.

If for some reason the Past President becomes unable or unwilling to continue in office before the end of his or her normal term, the post will remain vacant until the end of the term of office of the current President.

Secretary General

The Secretary General will maintain the requisite records of the WFOT, including those concerning membership and the transactions at the General Assembly. He or she will also carry out such other duties as may reasonably be assigned by the President.

The Secretary General will serve for two years and will be eligible for re-election. If for some reason the Secretary General becomes unable or unwilling to continue in office before the end of his or her normal term, his or her duties will be assumed by the Treasurer until the next General Assembly or a Special Business Meeting convened for the purpose of electing a new Secretary General. The Executive Committee will seek nominations for this post, in the usual way. The new Secretary General will then serve for two years from the time of that General Assembly or from the following one if a Special Business Meeting is held in the sixth months preceding it.

Treasurer

The Treasurer will be responsible for administering the funds of the WFOT, keeping a record of financial transactions, and providing a financial report to the General Assembly. He or she will also carry out such other duties as may reasonably be assigned by the President. The Treasurer will serve for two years, but will be eligible for re-election.

If for some reason the Treasurer becomes unable or unwilling to continue in office before the end of his or her normal term, his or her duties will be assumed by the Secretary General until the next General Assembly or a Special Business Meeting convened for the purpose of electing a new Treasurer. The Executive Committee will seek nominations for this post, in the usual way. The new Treasurer will then serve for three years from the time of that General Assembly or from the following one if a Special Business Meeting is held in the sixth months preceding it.

Duration of officers terms

The Executive Committee may, in collaboration with the Rules Committee, propose to the General Assembly a variation in the length of service of the Officers, including the Members-at-Large should early retirement or other events disturb the normal sequence of changes of Officer.

Article 8 • Financial Management - Responsibility

All financial contributions to the WFOT, including subscriptions and other fees and donations, together with income from the educational and other activities of the WFOT, are to be paid to the Treasurer. The amount and conditions of the annual subscriptions shall be proposed by the Executive Committee and submitted to the General Assembly for approval. The funds of the WFOT shall be used to finance the WFOT's activities, to organise the meetings of the WFOT. The Executive Committee shall assume collective responsibility for its actions, including those relating to disbursement of funds. It shall not, however, be held responsible for actions by individual Members of the WFOT or by its Committees which it has not previously approved, unless it is deemed to have exercised insufficient control over them.

Article 9 • Constitution and Bylaws

The Constitution may be amended at any General Assembly or at a Special Business Meeting (convened for that purpose on written request of one third of the combined numbers of Full and Honorary Members), by a two thirds majority of the voting members present. Proposed amendments must be presented to the Members in the convocation to the General Assembly or Special Business Meeting.

The general management of the WFOT will be based on the Bylaws. The Bylaws are responsibility of the officers of the WFOT and will be settled, and may be amended, by the WFOT Executive Committee.

Article 10 • Dissolution - Disposal of Property

The WFOT may be dissolved only at a General Assembly or a Special Business Meeting convened for this purpose, by a three-quarters majority of Full and Honorary Members present. If the final balance sheet shows a profit, this shall be transferred to an non-profit organisation with aims similar to those of the WFOT.

Article 11 • Provisional organisation

The constitution will be duly registered with the provisional nomination of the following officers:

<i>President</i>	V.J. Kumar, New Dheli
<i>Vice President</i>	C.F. Andreula, Bari
<i>Secretary General</i>	M. Bonetti, Brescia
<i>Treasurer</i>	A. Fontana, Brescia
<i>Members at Large</i>	E. Iliakis, Athens, Greece
	J. Baeza Noci, Valencia, Spain
	Byung Chan Jeon, South Korea
	X. He, Guangzhou China
	O. Pepa, Buenos Aires, Argentina
	X.F. Vilasuso, Miami, USA

and:

G. Barco, President Eumedica
 J.C. De Lucas-García, President Spanish Ozone Society (ACEOOT)
 M. Leonardi, President FIO
 J. Vilitelka, President Slovak Group

At the occasion of the next WFOT Congress in 2007, probably in Beijing, China, formal elections will be held. The provisional officer will be able to re-candidate.

WFOT has been registered by Marco Leonardi and Nicola Leonardi Dall'Occa dell'Orso in Bologna, on Thursday 22 December 2005, by Dr Giorgio Forni Notaio.

Fiscal Number of the WFOT is 91265570373

The provisional location is indicate at the residence of:

Prof. Marco Leonardi
 Via del Pratello, 8
 40122 Bologna

WFOT – World Federation of Ozone Therapists

Bylaws

Election of Members

Applications for Society Membership will be passed, via the Secretary General for proposal at the next General Assembly. Candidates will be elected by a simple majority of voting Members. The Member Society will declare the number of its members, the membership fee and vote numbers will be proportional to the number of full members of the Member Society.

Full Members may propose individual candidates for membership of the WFOT. Anyone wishing to become a Full Member must seek an existing Full Member to act as his or her sponsor. The latter must certify that the applicant has had the requisites. The application will then be passed to the Secretary General for proposal at the next General Assembly. Candidates will be elected by a simple majority of voting Members. Successful applicants will become Full Members as from the General Assembly at which their application is approved.

Applications for Corporate Membership will be passed, via the Secretary General, for proposal at the next General Assembly. Candidates will be elected by a simple majority of voting Members.

Proposals for Honorary Membership or Honorary Presidency should be made to the President.

The General Assembly

The General Assembly will normally be held in conjunction with the Scientific Meeting. The Secretary General shall send the convocation to the Assembly to all Members at least six weeks before the date set for the Assembly. All Members may attend the Assembly, but only Full and Honorary Members may vote. The General Assembly may take place and decisions may be taken only when the number of members with voting rights present is at least one fifth of the combined numbers of Full and Honorary members; it will be the responsibility of the Secretariat to ensure that this requirement is fulfilled. If it is not, a further Meeting shall be convened, at which a quorum shall be deemed to be present regardless of the number of Full and Honorary Members present. The convocation to this latter meeting shall be sent to all Members not less than 30 days before the date set for the Meeting.

The following will be elected at the time of the General Assembly: the President, the Vice-President, the Secretary general, the Treasurer, the Members-at-Large of the Executive Committee, and the President of the next Annual Scientific Meeting whose President has not as yet been appointed. New Members in any category will be elected and registered.

Changes to the Constitution will be discussed and ratified, if approved, at the General Assembly. All such matters as are indicated in the agenda shall be discussed. Any Members present may raise Any Other Business of interest to the WFOT, but shall first notify the Secretary General in writing of his or her intention to do so. Decisions made at General Assemblies will be made by a simple majority (or by the largest number of votes cast, if more than two choices are available) of voting Members, except as otherwise indicated in this Constitution.

Special Business Meetings may be convened by the President on written request of one third of the combined numbers of Full and Honorary Members. The agenda for such Meetings shall be included in the convocation to them, and no business other than that indicated by the agenda shall be conducted. The convocation to a Special Business Meeting [and any relevant ballot papers] shall be sent to all Members at least 30 days before the date set for the Meeting.

Committees

Standing Committees

The members and Chairmen of these Committees shall be appointed by the Executive Committee, and the Chairmen's appointments shall be ratified at the General Assembly or a Special Business Meeting.

Any Full member may offer him- or herself for consideration as a Committee member and should do so by informing the Secretary General of his or her willingness to serve. Membership will normally be for one term of two years, with the possibility of appointment for one further term. The Committees shall be authorised to co-opt such further ad-hoc members as circumstances demand by agreement among the existing appointed members, without reference to the Executive Committee; the latter will, however, be advised of such arrangements. The activities of the Committees shall be reported to the Executive Committee and to the General Assembly.

The list of Standing Committees will be kept under review, taking into account the needs of the WFOT. They currently include the following.

- a) Technical Committees:
 - i. Rules Committee
 - ii. Membership Committee
 - iii. Audit Committee
- b) Scientific Committees:
 - iv. Publication Committee
 - v. Scientific Programme Committee
 - vi. Scientific Award Committee
 - vii. Education Committee

i. Rules Committee

This Committee shall consist of three members, including the Chairman. It shall be responsible for interpreting the Constitution. It will also keep it under review, taking into account the views of the Members of the WFOT, and its changing needs. It will advise the Executive Committee of proposals for modifications to the Constitution. With the agreement of the Executive Committee, it will prepare proposed changes for presentation to the Members.

ii. Membership Committee

This Committee shall be responsible for receiving new applications for membership from the Secretary General, and for allotting the appropriate category to candidates. It will also review the suitability of existing Members for the category of membership in which they are currently placed, having at its disposition the information required to do this. It will provide the Executive Committee with proposals for membership, to be approved at the General Assembly.

iii. Audit Committee

This shall consist of three members, including a Chairman. The Committee will review the accounts prepared by the Treasurer each year and shall retain a certified accountant for these purposes, and for certifying the annual report of the Treasurer.

iv. Publication Committee

This Committee will consist of three appointed members, including the Chairman, plus the most senior editor of the official journal of the WFOT who is a Full Member of the WFOT, and the editor appointed to that journal by the WFOT. It shall promote publication of appropriate documents by the WFOT and shall be consulted about any projected publication by or on behalf of the WFOT.

v. Scientific Programme Committee

This Committee shall consist of three appointed members, including the Chairman. The President of the forthcoming Annual Scientific Meeting is a member ex-officio from the time of the end of the previous Meeting until the end of the Meeting he or she organises. This Committee shall co-operate with local scientific committees and be responsible, in collaboration with the Secretariat, for the scientific organisation of the meeting(s) of the WFOT.

vi. Scientific Award Committee

This will consist of three appointed members, including a Chairman. It shall supervise any prizes or awards the WFOT may sponsor.

vii. Education Committee

This will consist of three appointed members, including a Chairman. The Committee will co-operate with local scientific committees and shall be responsible, in collaboration with the Secretariat, for the scientific organisation of didactic courses organised by or on behalf of the WFOT. It will propose places, topics and Presidents for courses to the Executive Committee and General Assembly for approval.

Other Committees

Ad hoc Committees may be established by the Executive Committee and an Advisory Board may be set up by the President, as indicated above. The period for which these bodies are appointed will normally be determined at the time they are convened.

Meetings

The Officers of the WFOT will hold such meetings as are deemed appropriate, which shall be organised locally by a Full Member appointed by the WFOT, following such guidelines as may currently be laid down. These will normally include a Congress (and General Assembly), and one or more didactic courses.

I Congresso Internacional de
OZONIO TERAPIA
Belo Horizonte . 28 a 30 de abril de 2006




Information

Address: Centro de Convenções do Hospital de Olhos de Minas Gerais
Rua da Paisagem, 220 - Vila da Serra - Belo Horizonte - Brazil

Organizers: Associação de Ozonioterapia Médica do Brasil (Brazil Medical Ozonotherapy Association), Fundação Hospital de Olhos de Minas Gerais (Hospital foundation of Olhos de Minas Gerais)

Location: Central de Ozonioterapia, Hospital de Olhos de Minas Gerais

Organization Committee: Dra. Wendy Falzoni (São Paulo, SP); Dr. Ricardo Guimarães (Belo Horizonte, MG); Dr. Sérgio Bruzadelli Macedo (Brasília, DF); Dra. Claudia C. Cardoso (São Paulo, SP); Bruno Vieira Marques Rodrigues (Belo Horizonte, MG)

Organizing Secretariat:  comunicação e eventos Telefax (31) 3291-9899 www.consulteventos.com.br

Message: From the 28th to the 30th of April, the city of Belo Horizonte is going to host a new appointment. Promoted by the Brazil Medical Ozonotherapy Association, the 1st International Ozonotherapy Congress is going to debate this new therapeutic technique that is utilized in different medical specialities: dermatology, plastic surgery, dentistry, endocrinology, ophthalmology and others.

The Congress will take place at the Convention Centre of the Hospital of Minas Gerais, which is located in Rua Paisagem 220 in Bairro Villa da Serra and from which is possible to enjoy a wonderful view of Belo Horizonte.

The event will use the videoconference connection, that will make possible the involvement of medical practitioners from all over the world.

All the doctors who work with ozonotherapy are invited to submit their papers (free essays and posters) regarding the subject. The rules for the submission are on the link "Trabalhos".

A broad commercial exposition will offer to the practitioners a direct contact with the last news regarding the services and equipments dealing with ozonotherapy.


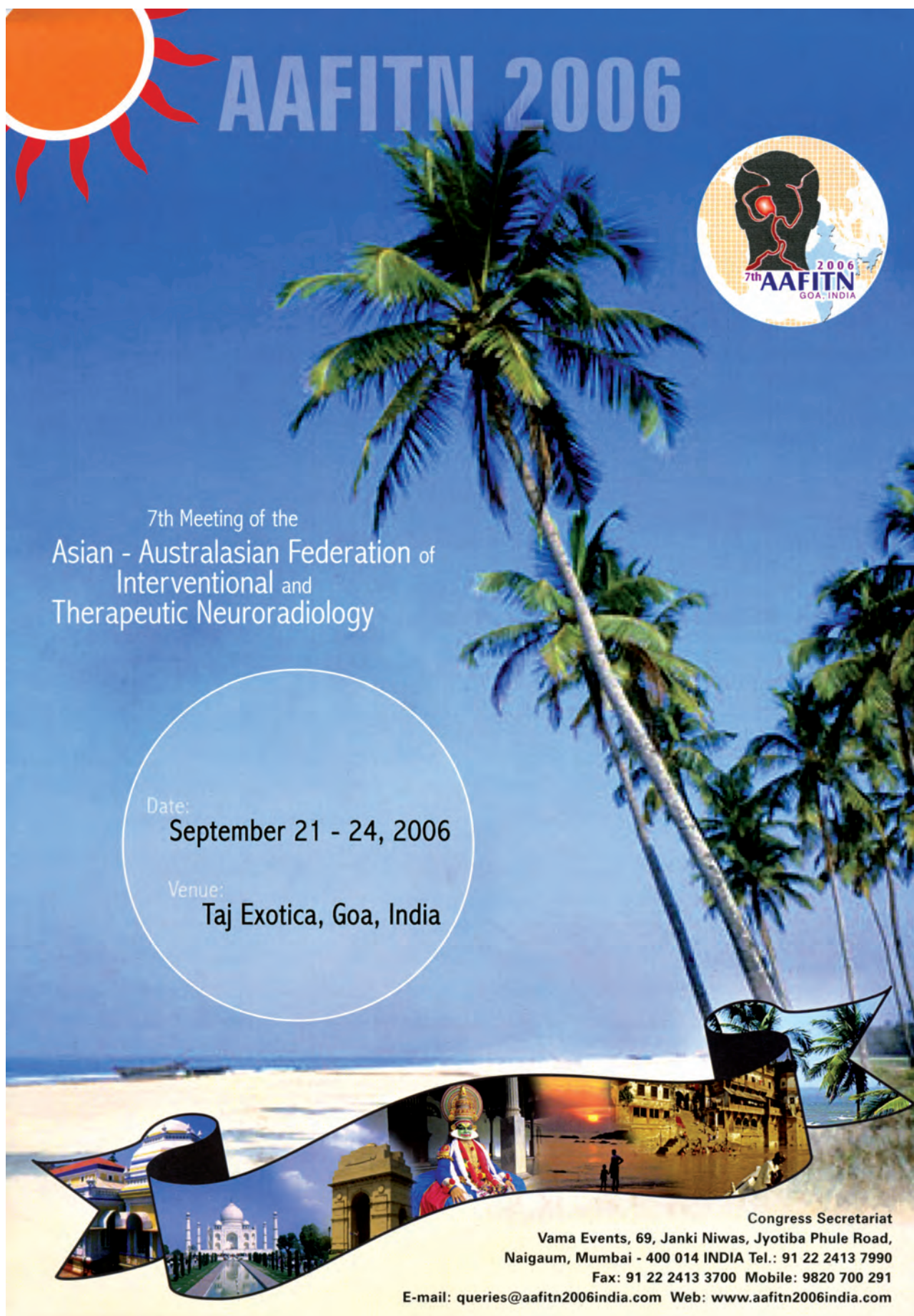
In case of subscription, the form is available on the website. If more information on the commercial participation is needed (stands etc...) send an e-mail to Consult, clicking "fale conosco".

We are looking forward to include you as our participant.


Organization Committee.

Relators: International Confirmed Relators

Alberto Alexandre, Italy • Cláudia Catelani Cardoso, SP • Deborah Phair, Canada • Edmur Hawthorn, SP • Francisco Humberto Azevedo, MG • Freddi Dimantas, SP • Glacus Souza Brito, SP • Heinz Konrad, SP • João Magalhães, RJ • José Oswaldo Molla, SP • Marco Marcondes, PR • Mariano Franzini (videoconference), Italy • Osmwaldo Molla, SP • Paulo Rockett, SP • Philip Mollica, USA • Roberto César Leite, PR • Roberto Dall'Aglio, Italia • Sérgio Bruzadelli Macedo, DF • Sílvia Menéndez Cepero, Cuba • Velio Bocci (videoconference), Italy • Wendy Falzoni, SP




AAFITN 2006



7th Meeting of the
Asian - Australasian Federation of
Interventional and
Therapeutic Neuroradiology

Date:
September 21 - 24, 2006

Venue:
Taj Exotica, Goa, India



Congress Secretariat
Vama Events, 69, Janki Niwas, Jyotiba Phule Road,
Naigaum, Mumbai - 400 014 INDIA Tel.: 91 22 2413 7990
Fax: 91 22 2413 3700 Mobile: 9820 700 291
E-mail: queries@aafitn2006india.com Web: www.aafitn2006india.com



Federazione Italiana di Ossigeno-Ozonoterapia

www.webfio.it

Al Presidente della FIO

Il sottoscritto/a

Residente in via

CAP Città

e-mail Telefono Fax

Chiede di essere iscritto alla FIO - Federazione Italiana di Ossigeno-Ozonoterapia.

Allega un breve curriculum vitae (una pagina)

Data Firma

Mi impegno al versamento della quota sociale annua di 125,00 €.

Di cui 85,00 € come iscrizione alla FIO e 40,00 € come abbonamento alla Rivista Italiana di Ossigeno-Ozonoterapia, organo ufficiale della FIO, Banca Carige agenzia 2 di Brescia, CIN: k abi 06172 cab 11202 C/C 000000624780, oppure inviare con bollettino postale C/C nr. 43650316, intestato a F.I.O. (Federazione Italiana di Ossigeno-Ozonoterapia).

Dr Matteo Bonetti
Segretario FIO

Presso: **X-Ray Service Srl**

Sede amministrativa: Via Leonardo da Vinci, 20 - 25100 Brescia

Sede operativa: c/o **Casa di Cura Sant'Anna**, Via del Franzone 31 - 25100 Brescia

Tel.: **030.3197173** - Fax: **030.3197171**

e-mail: segreteria.fio@cdcsantanna.it

Comunicazione all'Abbonato - In relazione a quanto disposto dall'art. 10 della L. n. 675/1996, Le assicuriamo che i Suoi dati (nome, cognome, titolo di studio, attività svolta e indirizzo), presenti nel nostro archivio informatico, verranno utilizzati esclusivamente per l'invio di lettere commerciali e avvisi promozionali inerenti al rapporto editore-abbonato. Ai sensi dell'art. 13 della L. n. 675/1996, Lei potrà opporsi all'utilizzo dei dati in nostro possesso se trattati in maniera difforme a quanto disposto dalla legge

FEDERAZIONE ITALIANA DI OSSIGENO-OZONOTERAPIA

Date.....

Re: association membership fee

Dear Colleague,

This is a reminder that the Association *membership* fee for 2006 is € 125,00, inclusive of a subscription to the Rivista Italiana di Ossigeno-Ozonoterapia, *payment by bank draft to Banca Carige - agenzia 2 - Brescia, Italia*

IBAN: IT 35 K 06175 11202 000000624780 SWIFT Code: CRGEITGG542, or by credit card

Thank you in advance for your prompt payment.

Yours sincerely,

Dr Matteo Bonetti
FIO Secretary

Objeto: cuota de asociación

Estimado Colega,

quería recordarte que *la cuota* de asociación por *el año 2006 es de € 125,00*, la que incluye la subscripción a la Rivista Italiana di Ossigeno-Ozonoterapia, *con un pago en la Banca Carige - agencia 2 - Brescia, Italia*

IBAN: IT 35 K 06175 11202 000000624780 Codigo SWIFT: CRGEITGG542, o con la tarjeta de crédito.

Te agradezco desde ahora por el pago de la cuota.

Cordialmente

Dr Matteo Bonetti
Segreteria FIO

Oggetto: quota associativa

Caro Collega,

desidero ricordarti che *la quota sociale* della FIO è per il 2006 di € 125,00, comprensiva dell'abbonamento alla Rivista Italiana di Ossigeno-Ozonoterapia, *con un bonifico alla Banca Carige - agenzia 2 - Brescia, Italia*

IBAN: IT 35 K 06175 11202 000000624780 o con carta di credito.

oppure inviare con bollettino postale: c/c nr. 43650316, intestato a F.I.O.

(Federazione Italiana di Ossigeno-Ozonoterapia)

Ti ringrazio fin da ora per il pagamento.

Cordialmente

Dr Matteo Bonetti
Segreteria FIO

FIO FEDERAZIONE ITALIANA DI OSSIGENO-OZONOTERAPIA

Marco Leonardi
President

Cosma F. Andreula, Roberto Dall'Aglio, *Vice-Presidents*
Matteo Bonetti, *Secretary*
Filippo Albertini, *Treasurer*

Advisors: Roberto Cardelli, Francesco Ceccherelli,
Massimo Damini, Gabriele Tabaracci, Alessio Zambello
Giovanni Barco, *Eumedita President*

RIVISTA ITALIANA DI OSSIGENO-OZONOTERAPIA

OFFICIAL JOURNAL OF THE
ITALIAN SOCIETY OF OXYGEN-OZONE THERAPY

EDITORIAL COMMITTEE

Cosma Andreula (*neuroradiology*), FrancAntonio Bertè (*pharmacology*),
Vello Bocci (*general physiology*), Marco Brayda-Bruno (*orthopaedics*),
Francesco Ceccherelli (*anaesthesia and intensive care*)
Giuliano Fabris (*neuroradiology*), Carlo Luongo (*vascular medicine*),
Giovanni Pierucci (*forensic medicine*), Giovanni Ricevuti (*immunology*),
Plinio Richelmi (*toxicology*), PierLuigi Sapelli (*dentistry*),
Luigi Valdenassi (*pharmacology*), Giuliano Agolini (*hygiene and antiseptics*)

REVIEWERS COMMITTEE

Giovanni Agostini, Alberto Alexandre, Carlotta Barbara,
Liberato Berrino, Josip Buric, Franco Cirillo, Franco Combi,
Ludovico Coppola, Roberto Dall'Aglio, Cesare D'Ambrosio,
Paola D'Aprile, Giovanni Battista Di Mauro, Amelia Filippelli,
Alessandro Fontana, Eugenio Genovese, Riccardo Giunta,
Antonio Gijonovich, Giorgio Gombos, Stergios Ikonomidis,
Emmanuel Iliakis, Nivio Jucopilla, Enrico Lampa, Raffaele Landi,
Biagio Lettieri, Antonino Levita, Carlo Maria Longo, Renato Manzi,
Filippo Roberto Marcolongo, Enzo Marinoni, Giuseppe A. Marra,
Raoul Matassi, Claudio Morosi, Mario Muto, Vincenzo Pantusa,
Marco Pasquali Lasagni, Hector Salgado, Adriano Sammartino,
Francesco Silvano Sasso, Alberto Scarchilli, Luigi Simonetti,
Umberto Spagnoli, Marco Spreafico, Anteo Tomasso, Giulia Tommasini

SCIENTIFIC EDITOR

Matteo Bonetti
Servizio di Neuroradiologia - Istituto Clinico Città di Brescia
via Gualla, 15 - 25100 Brescia
Tel. ..39/030/3710311 - Fax ..39/030/3710370
e mail: matbon@numerica.it

EDITOR-IN-CHIEF

MARCO LEONARDI
Cattedra e Servizio di Neuroradiologia - Ospedale Bellaria
via Altura, 3 - 40139 Bologna
Tel. ..39/051/6225520 - Fax ..39/051/6225785
e mail: marco.leonardi@centauro.it

LANGUAGE EDITOR

Anne Collins
e mail: collins@iol.it

MANAGING EDITOR

Elisabetta Madrigali
e mail: elisabetta@centauro.it

ADVERTISING

Gerardo Dall'Occa
e mail: gerardo.dallocca@centauro.it

PRINTED BY:

Grafiche dell'Artiere - Bologna

INSTRUCTIONS TO AUTHORS

Rivista Italiana di Ossigeno-Ozonoterapia is a clinical and practice journal documenting the current state of neuroradiology practice. The journal publishes original clinical observations, descriptions of new techniques or procedures, case reports and articles on the ethical and social aspects of health care. Papers are accepted on the understanding that they are subject to peer review, editorial revision and, in some cases, comment by the editors. Manuscripts are examined by independent anonymous reviewers. All authors remain anonymous to the reviewers, in line with international standards. Manuscripts submitted in English will be edited and corrected if necessary. Articles and other material published in the journal represent the opinions of the authors and should not be construed to reflect the opinions of the publisher.

Submissions should be accompanied by a covering letter signed by all authors stating that a) the paper is not currently being considered for publication elsewhere; b) all authors have been personally and actively involved in work leading to the report and will thus hold themselves jointly and individually responsible for its content; c) all relevant ethical safeguards have been met in relation to patient protection; d) an acknowledgement of any financial support from commercial sources or pecuniary interest in such enterprises that could pose a conflict of interest including consultations for any product or process mentioned in the submission. Failure to make such disclosure in the covering letter will result in the manuscript being rejected. All manuscripts and correspondence should be sent to the Editor-in-Chief, Matteo Bonetti. Manuscript selection is based on peer review. The guidelines to authors are based on the Uniform Requirements for Manuscripts Submitted to Biomedical Journals (*Ann Intern Med* 108: 258-265, 1988).

The publishers will inform the author(s) in case they want to make use of their limited copyright. In case of sales of reprints or other reproductions of the article in printed or electronic media, the publisher will compensate the authors financially or by other means. The authors retain the right to reject publication for purposes they deem to be conflicting with their personal or scientific integrity.

GENERAL GUIDELINES - Original articles should be organized in the customary format of: Summary, Introduction, Methods, Results, Discussion and Conclusion. Case reports should be concise, clear and well documented. Technical notes will offer brief descriptions of techniques with possible applications. Summaries and captions will be published in English and Italian.

REFERENCES - References should be prepared carefully. Journal names should be abbreviated according to Index Medicus using the following format:

- 1) Names of authors, Capitals of given names (in the case of more than three authors use "et Al"): Title of article. abbreviated Journal name volume: page-page, year.
i.e.: Laredo JD, Bard M: Thoracic Spine: Percutaneous Trephine Biopsy. *Radiology* 160: 485-489, 1986.
- 2) Names of authors, Capitals of given names (in the case of more than three authors use "et Al"): Title of book. Printer, City year.
i.e.: Valavanis A: *Medical Radiology: Interventional Neuroradiology*. Springer Verlag, Heidelberg 1993.
- 3) Names of authors Capitals of given names (in the case of more than three authors use "et Al"): Title of chapter. In: Editor's name: Title of book. Printer, City year: page-page.



For information: Centauro s.r.l.
Via del Pratello, 8 - I-40122 Bologna
Tel: ..39/051/227634 - Fax: ..39/051/220099
e mail: adriana.dallocca@centauro.it
www.centauro.it
SINGLE ISSUE: Euro 30,00
Back Issue: 50% surcharge
Reg. Trib. di Bologna n. 7159 del 20-09-2001

i.e.: Bonneville JF, Clarisse J et Al: Radiologie Interventionnelle. In: C Manelfe (Ed): Imagerie du rachis et de la moelle. Vigot Editeur, Paris 1989: 761-776.

ILLUSTRATIONS – Figures should be submitted as original x-ray or laser films, glossy prints or slides (all originals will be returned to the authors with offprints). Clearly indicate on one side the top of the figure and number. Do not label the image with arrows, numbers or letters, but indicate on a duplicate copy or on a sketch where these indications are desired. Do not cut or attach figures with scotch tape or use paper clips.

Instructions for Submission of Electronic Illustrations

Colour figures: Images must be acquired using the QUADRICROMIA-CMYK method. The RGB method is only recommended for video reproductions as the quality of printed figures is poor:

Black and white figures: Images must be acquired using the GREY SCALE with a minimum scanner resolution of 300 pixels per inch or 150 pixels per cm. Images should be saved in .TIFF format, minimum base 8.1 cm.

It is important that images retain their original acquisition features. Subsequent changes do not improve the initial resolution. If these minimum requirements are not satisfied, the print quality will be poor. Definition also depends on the enlargement factor: a large image can be reduced for publication thereby improving the resolution, but enlargement of a small image highlights all its flaws and severely reduces the resolution. Images submitted for publication must be the original acquisition.

Images already paged in Word, PowerPoint or other documents or inserted in web pages contain a low-resolution image unsuitable for printing.

Graphic paging will be done using the Macintosh system.

Illustrations can be submitted on a CD-ROM copied in ISO 9006 format legible on PC or MAC. Other media can be used, compressing files with Stuffit, Aladdin or Zip, as long as the original is in high-resolution TIFF format. Submissions can be sent via the Internet, but maintaining the same initial characteristics. The time required to send files will vary depending on the number of figures, but image resolution must not be reduced to speed up transmission times. When naming the figures, please check that the name corresponds to the figure number.

Typewritten manuscripts – double spaces – should be submitted in triplicate (illustrations in one original copy and two photocopies). They should be typed on one side of the paper, double spaced, with margins of at least 25 mm, accompanied by a diskette (3 1/2") indicating the programme used (IBM, MS/DOS or Macintosh are acceptable). Send everything to the Editor in Chief.

Offprints: Rivista di Ossigeno-Ozonoterapia offers authors a complimentary copy of the issue in which their article is published and a .pdf file of the article will be made available on the publisher's website www.centauro.it. Authors will be sent instructions by e-mail on how to download their papers to print the copies they need. To purchase reprints of articles published by the journal please contact Centauro Srl for a quotation at serena.preti@centauro.it.

NORME EDITORIALI

1) Si accettano solo lavori originali.

2) Lingua: la Rivista di Ossigeno-Ozonoterapia accetta articoli in inglese ed in italiano con didascalie e riassunto nelle due lingue o almeno in italiano.

3) *Traduzioni:* le traduzioni e le revisioni dell'inglese verranno effettuate da un traduttore specializzato (omaggio dell'editore agli autori). Ciò consente la migliore uniformità dei testi inglesi.

4) *Il testo* dei lavori va presentato in tre copie (complete di iconografia) stampato a doppia spaziatura. Nella prima pagina vanno indicati solo il titolo, gli autori, il reparto di appartenenza. Indicare oltre al nome, indirizzo e numero telefonico della persona riferimento per ogni comunicazione. Nella seconda pagina vanno inseriti il titolo (senza i nomi degli autori, per permettere la lettura anonima) e le parole chiave, seguiranno poi i riassunti ed il testo.

I riassunti dovranno essere due: uno breve e descrittivo, che sarà pubblicato in italiano, ed uno *molto ampio ed esaustivo* che sarà tradotto in inglese e dovrà consentire la piena comprensione del lavoro.

Da ultimo vanno inserite le didascalie dell'iconografia e delle tabelle e la *bibliografia* (completa, ma *essenziale*), numerata ed in ordine alfabetico.

5) *Bibliografia:* si prega di seguire le norme editoriali in modo molto accurato, limitando le citazioni alle essenziali:

– Cognome dell'autore Iniziale del nome: Titolo del lavoro. Nome abbreviato della rivista Volume: pagina iniziale-pagina finale, anno.

– Cognome dell'autore Iniziale del nome: Titolo del libro Editore, Città, Paese; Anno: pagina iniziale-pagina finale.

Qualora gli autori siano più di tre si consiglia di indicare i primi due più: «et Al».

6) Inviare il testo anche su dischetti da 3 1/2" per Macintosh, IBM, MS-DOS o comunque in formati tipo Word, Write, Xpress. Esso dovrà essere battuto senza formattazione od impaginazione. In caso di tabelle, grafici o disegni specificare il programma con il quale sono stati creati.

7) *Iconografia:* si raccomanda la presentazione di iconografia della migliore qualità, sotto forma sia di lastre originali (preferibilmente) o diapositive, sia di stampe bianco/nero. Le tabelle devono essere numerate. Ogni immagine o tabella va corredata da una didascalia sintetica in italiano (traduzione in inglese a cura della redazione). *Indicare sempre i parametri RM.*

Istruzioni per l'invio del materiale iconografico

L'impaginazione grafica dei lavori avviene in ambiente Macintosh.

Immagini a colori: L'acquisizione delle immagini deve essere eseguita in modalità (metodo) QUADRICROMIA - CMYK. La modalità RGB

è indicata solo per immagini da riprodurre in video, ma perde la qualità con la riproduzione su carta.

Immagini in bianco e nero: L'acquisizione delle immagini deve essere eseguita in SCALA DI GRIGIO.

Tutte le immagini devono essere acquisite in scanner ad una risoluzione di 300 pixel per pollice minimo o di 150 pixel per cm minimo. Le immagini devono essere poi salvate in formato .TIFF, con base minima 8,1 cm.

È importante che le immagini abbiano queste caratteristiche all'origine dell'acquisizione. Le modifiche successive non migliorano la risoluzione iniziale. Se non è possibile ottenere queste caratteristiche minime, il risultato in stampa sarà a bassa definizione. La definizione dipende inoltre dal fattore di ingrandimento: un'immagine di grandi dimensioni può essere ridotta per la stampa e migliorare le caratteristiche di risoluzione; ma un'ingrandimento di un'immagine piccola mette in luce tutti i più piccoli difetti, oltre a ridurre in modo evidente la risoluzione. Le immagini inviate per la stampa devono essere assolutamente gli originali di acquisizione. Le immagini già impaginate in documenti Word o PPT (o altre applicazioni) o contenute in pagine web, contengono un'immagine virtuale in bassa risoluzione, non adatta alla stampa tipografica.

Per l'invio dell'iconografia si può utilizzare un cd-rom, masterizzato in formato ISO 9006 perché sia leggibile da PC a MAC.

Si può utilizzare altri supporti, comprimendo i files con Stufflet o Aladdin o Zip, raccomandando che l'originale sia in formato TIF e in alta risoluzione.

Il lavoro può essere inviato tramite la rete Internet, ma sempre con le stesse caratteristiche iniziali. Naturalmente il tempo d'invio sarà lungo in relazione al peso delle immagini, ma queste non devono assolutamente essere ridotte di risoluzione per facilitarne l'invio.

Se le caratteristiche iniziali delle immagini non fossero quelle richieste, perché acquisite con macchinari ospedalieri, sarebbe utile fare una verifica del risultato finale: dopo averle salvate in un supporto con le caratteristiche sopradette, utilizzando un altro computer non collegato alla rete di archivio delle immagini che si vogliono stampare, provate a fare un'uscita in carta. Da qui si potrà verificare la nitidezza delle immagini da stampare. Per questo tipo di immagini si può utilizzare il formato JPG.

Quando viene dato un nome all'immagine, verificare che il nome dato corrisponda alla numerazione delle didascalie.

8) *Estratti:* la Rivista di Ossigeno-Ozono terapia offre agli autori una copia omaggio del numero su cui il Loro articolo è pubblicato ed un CD gratuito con il file .pdf dello stesso articolo. Questo permetterà agli autori di stampare le copie di cui necessitano, ma un uso commerciale di questo CD configura un reato. Per acquistare estratti degli articoli pubblicati sulla rivista, si prega contattare Centauro S.r.l. per un preventivo di spesa all'indirizzo serena.preti@centauro.it.

9) Tutto il materiale va inviato al Direttore Scientifico.

ALNITEC

OZONE IN THE WORLD



EXCELLENT FEATURES: 120 µg/ml, 9,5 Kg (Portable Module), extractable from the trolley. No knobs. Totally automatic.

ACTIVE PHOTOMETER: Reads the ozone concentration and keeps it constant always. Checks to work inside strict tolerances with total safety.

10 MEMORIZABLE CONCENTRATIONS: To select 10 selections inside 120 concentrations.

10 SEQUENCES: In a Sequence it is possible to jump from a memorized concentration to another with a touch, to avoid dead times.

BUBBLER H₂O+O₃: With Five Programs to ozonize the water, with a timer. It calculates the concentration of ozone in the water after the bubbling.

BUBBLER OIL+O₃: With a Software Program to ozonize the oil, with a timer.

VACUUM PUMP: Portable. For topical applications. 7 Kg.

OZONE-PROOF MATERIALS: To avoid contamination of the output gas.

CERTIFICATIONS: MEDICAL DEVICES 93/42/EEC Directive. EC Quality Assurance System Certificate, according to Annex II of 93/42 EEC Directive. CE 0476



La vita è un mistero. La tecnologia no

Rivolgetevi a Kodak per avere delle risposte chiare, efficaci - per migliorare la produttività e la qualità del servizio che offrite.

Partiamo da soluzioni di workflow, realizzate su misura per i vostri bisogni operativi più specifici; e lavoriamo con voi per semplificare i processi, così da portare al successo la vostra implementazione.

Ad ogni passo del cammino, noi ci saremo. Con esperienza e competenza. Senza misteri.

RIS | PACS | Storage Solutions | CR | DR | Consulting & Network Services

Kodak | Health

www.kodak.com/go/health

