

See discussions, stats, and author profiles for this publication at: <https://www.researchgate.net/publication/303808225>

# Use of ozone in healing failed pectoralis major myocutaneous advancement flap

Article in *International Journal of Research in Medical Sciences* · January 2016

DOI: 10.18203/2320-6012.ijrms20161838

CITATIONS

0

READS

73

5 authors, including:



**Titiksha Pol**

The SIA College of Physiotherapy Dombivli

10 PUBLICATIONS 10 CITATIONS

[SEE PROFILE](#)



**Mariya P Jiandani**

King Edward Memorial Hospital

47 PUBLICATIONS 85 CITATIONS

[SEE PROFILE](#)



**Nivedita Shahane**

King Edward Memorial Hospital

4 PUBLICATIONS 2 CITATIONS

[SEE PROFILE](#)



**Vibhavari Koli**

1 PUBLICATION 0 CITATIONS

[SEE PROFILE](#)

Some of the authors of this publication are also working on these related projects:



pulmonary rehabilitation [View project](#)



Clinical Practice [View project](#)

## Case Report

# Use of ozone in healing failed pectoralis major myocutaneous advancement flap

Titiksha T. Pol\*, Mariya P. Jiandani, Sushama Gajakos, Nivedita Shahane, Vibhavari R. Koli

Department of Physiotherapy, PT School & Centre, Seth GS Medical College and KEM Hospital, Parel, Mumbai, India

**Received:** 05 April 2016

**Revised:** 07 April 2016

**Accepted:** 09 May 2016

**\*Correspondence:**

Dr. Titiksha T. Pol,

E-mail: [titikshapolphysio@gmail.com](mailto:titikshapolphysio@gmail.com)

**Copyright:** © the author(s), publisher and licensee Medip Academy. This is an open-access article distributed under the terms of the Creative Commons Attribution Non-Commercial License, which permits unrestricted non-commercial use, distribution, and reproduction in any medium, provided the original work is properly cited.

### ABSTRACT

Infection of the sternotomy wound following cardiac surgery is quiet common. The PMMF (pectoralis major myocutaneous advancement flap) procedure is commonly used to treat non healing sternotomy wounds following CABG (coronary artery bypass graft) procedure. Ozone is used in the treatment of chronic, infected non healing wounds. A 65 year old female with a similar type of situation was treated with ozone in our study and the effects of ozone to significantly control infection and promote healing of the failed PMMF (pectoralis major myocutaneous advancement flap) graft can be well appreciated.

**Keywords:** Ozone, Sternotomy wound, Infected wound, PMMF

### INTRODUCTION

Ozone therapy is a term that describes various practices in which oxygen, ozone or hydrogen peroxide is administered via gas or water in order to kill micro-organisms, improve cellular function and promote healing of damaged tissues.<sup>1</sup> Ozone has been used to treat medical conditions since the late 19<sup>th</sup> century.<sup>2</sup>

It was during the First World War that it was used in order to disinfect wounds.<sup>3</sup> Ozone is a molecule formed by the combination of three oxygen atoms in a dynamically unstable structure due to the presence of mesometric states.<sup>4</sup> It is naturally occurring in nature being present in the stratosphere.

Mechanically produced Ozone has been widely recognised as one of the best bactericidal, antiviral and antifungal agent and is being used empirically as a clinical therapeutic agent for chronic wounds, such as

trophic ulcers, ischemic ulcers and diabetic wounds.<sup>4</sup> Chronic wounds are wounds that fail to heal in an orderly and timely manner.

Presence of non-viable wound tissue, lack of healthy granulation tissue, lack of reduction in the size of the wound etc. are the signs of a non-healing chronic wound. The use of ozone in the treatment of such chronically, infected, non-healing wounds is well known. In this case, Ozone in the gaseous form is used to treat a chronically infected post CABG (coronary artery bypass grafting) median sternotomy wound.

The procedure of debridement, drainage followed by closure with PMMF (Pectoralis major myocutaneous advancement flap) in the treatment of infected median sternotomy wound post CABG is well known.<sup>5</sup> The use of ozone to treat infected sternotomy wound following failure of the PMMF procedure was successfully attempted in this case.

## CASE REPORT

A 65 year old female, a known case of hypertension, was operated for CABG (Coronary Artery Bypass Grafting). She developed wound dehiscence of the sternotomy wound 16 days following surgery for which wound debridement was done. This was followed by a Pectoralis major myocutaneous advancement flap (PMMF) cover after 15 days due to the persistent infection and non-healing nature of the wound along with optimized pharmacological therapy which included the cardiac

medications (Digoxin, Lasix, Atorva, Nebicard and Hemfer Forte) and antibiotics.

This procedure too failed as the infection was quite wide spread with the presence of purulent discharge from the surgical site which tested positive for presence of *acinetobacter baumannii* in the wound swab. There was significant rise in the WBC (white blood cell) counts, 14300 per Cmm. Repeated drainage with wash were given along with antibiotic therapy with colistin was started in order to control the infection.

**Table 1: Status of infection and wound evaluation (sessions 1 to 36).**

Outcome measures	Sessions 1-5	Sessions 6-15	Sessions 16-25	Sessions 26-36
Wound Size	Length- 18 cm	Length- 17cm	Length-13 cm	Length-9.5 cm
	Breadth	Breadth	Breadth	Breadth
	At 5cm- 10cm	At 5cm- 4cm	At 5cm- 4cm	At5cm- 1.5cm
	At10cm-10cm	At 10cm-8cm	At 10cm-5cm	At 10cm- --
	At 15cm- 6cm	At 15cm- 5cm	At 15cm- --	At 15cm- --
WBC count	14300per Cmm	10800per Cmm	9300per Cmm	9200per Cmm
Wound swab	<i>Acinetobacter baumannii</i>	<i>MRSA</i>	-	No growth
Blood culture	Gram+ve cocci	Gram+ve cocci	-	No growth
Medications: Cardiac	++	++	++	++
Antibiotics	Colistin, Levoflox	Levoflox, Linezolid	Linezolid	—
Ozone therapy week	1 <sup>st</sup>	2 <sup>nd</sup> and 3 <sup>rd</sup>	4 <sup>th</sup> and 5 <sup>th</sup>	6 <sup>th</sup> and 7 <sup>th</sup>

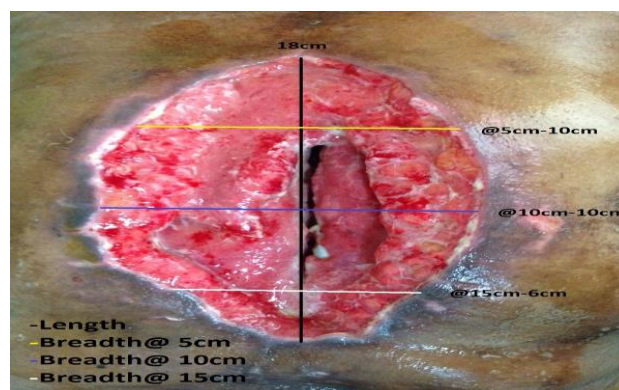
Ozone therapy was started at this point of time i.e. about one and half month post-surgery. A verbal consent was taken from the patient and the relatives and ozone therapy was initiated along with optimized pharmacological management. Under proper aseptic precautions, the wound was cleaned with betadine solution, followed by normal saline wash; the wound was then covered with a thin layer of gauze soaked in 5% normal saline.



**Figure 1: Method of covering the wound.**

Ozone in the gaseous form generated by the ozone machine was given once daily, 5-6 days a week for 7 weeks at the flow rate of 1l/min of O<sub>2</sub>. Ozone was delivered through the machine with the help of rubber

tubing attached to the machine which was sterilised before and after every use. The wound area was covered fully using polythene drape creating an air pocket covering the entire wound (Figure 1). The wound was dressed using gauze and micropore tape.

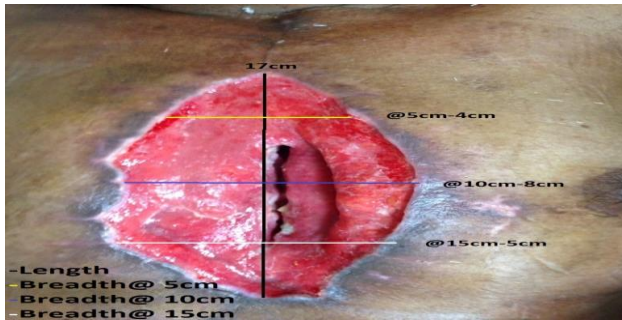


**Figure 2: Condition of wound before starting ozone therapy.**

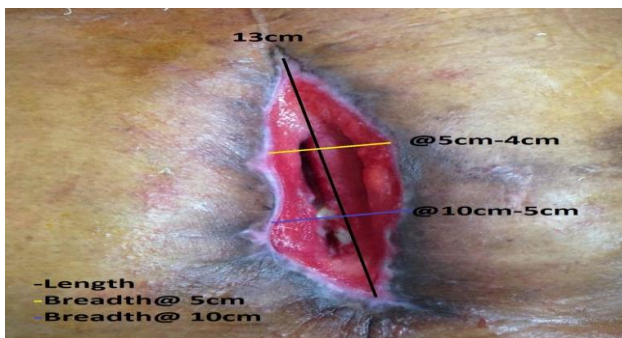
Weekly assessment of the wound noting the wound examination, wound size, WBC count, wound swab culture reports, medications was done. The assessment of the wound done weekly revealed a significant reduction in the wound infection over a period of 7 weeks (Table

1). There was significant reduction in the size of the wound from 18cm length in the first week to 9.5cm after 7 weeks (36 sessions) of ozone.

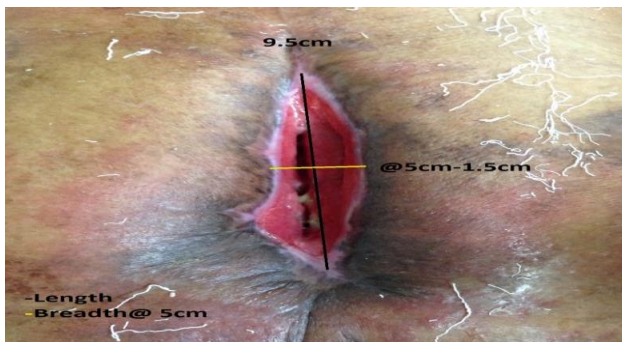
The WBC (white blood cell) count also reduced significantly from 14300per Cmm to 9200per Cmm after treatment with ozone. The swab culture and the blood cultures showed presence of no growth of bacteria in their cultures at the end of the treatment. The requirement of antibiotics also reduced from 2-3 per day to none after treatment with ozone.



**Figure 3: Condition of wound after 15 sessions.**



**Figure 4: Condition of wound after 25 sessions.**



**Figure 5: Condition of wound after 36 sessions.**

The effect of ozone can be well appreciated from the figures of the wound, condition of the wound before starting ozone (Figure 2), after 15 sessions (Figure 3), after 25 sessions (Figure 4), after 36 sessions (Figure 5).

The patient requested a DAMA (discharge against medical advice) and so was discharged with the wound left open and advised daily dressing for the same. According to the recent telephonic conversation with the

relatives 3 months post discharge, the wound measures 1.5-2cm in length without signs of infection.

## DISCUSSION

There was significant amount of healing with 47-50% reduction in the wound size seen after 7 weeks (36 sessions) of ozone therapy. The infection subsided considerably as seen from the WBC and swab cultures. There was also significant amount of wound healing seen as formation of healthy granulation tissue, healing evident at the wound edges with decrease in the amount of purulent discharge.

This can be attributed to the fact that, ozone acts by activating the immunocompetent cells and induction of biological antioxidants and radical scavengers.<sup>6</sup> Ozone exposure is associated with activation of transcription factor NF-KB, which is important to regulate inflammatory responses and entire process of wound healing.<sup>7</sup>

Ozone acts by activating and inducing stimulation of biological antioxidants and radical scavengers.<sup>7</sup> Ozone also improves circulation, oxygenates haemoglobin and kills parasites, acts as a bactericidal as well as a viricidal.

It increases the production of interferons and TNF (tumour necrosing factor) thus helping the body to fight infections.<sup>8</sup> Thus ozone helps in debridement of the dead tissue as well as provides O<sub>2</sub> and antioxidants stimulation to help facilitate healing. At the same time the bactericidal and viricidal property leads to destruction of the fat cell membrane of the organisms leading to their death and resolution of infection.<sup>8</sup>

*Funding: No funding sources*

*Conflict of interest: None declared*

*Ethical approval: Not required*

## REFERENCES

1. Giunta R, Coppola A, Luongo C, Sammartino A, Guastafierro S, Grassia A, et al. Ozonised autohaemotransfusion improves haemorheological parameters and O<sub>2</sub> delivery to tissues in patients with peripheral arterial diseases. *Ann Haematol.* 2001;80(12):7458.
2. Greer N, Foman N, Dorrian J, Fitzgerald P, MacDonald R, Rutks I, et al. Advanced wound care therapy for non-healing diabetic, venous and arterial ulcers: A systematic review. Washington DC: Department of veterans affairs. 2012. available at: <http://www.ncbi.nlm.nih.gov/books/NBK132238/>
3. Stroker G. Ozone in chronic middle ear deafness. *Lancet* 1902:1187-8.
4. Jani P, Patel G, YadavP, Sant L, Jain H. Ozone therapy: the alternate medicine of future. *Int Journal of Pharmacy and Biological sciences.* 2012;4(2):196-203.

5. Clinical guidelines (nursing): Wound care. The Royal Children's Hospital Melbourne. 2013.
6. Brito JD, Assumpção CR, Murad H, Jazbik AP, Sá MPL, Bastos ES et al. One –stage management of infected sternotomy wounds using bilateral pectoralis major myocutaneous advancement flap. *Rev Bras Cir Cardiovas.* 2009;24(1):58-63.
7. Hanster RV. Use of ozone in medicine. Mechanism of actions. Munich. 2003.
8. Stanley B. Medical ozone 1996. Available at <http://www.googlepapers.com>.

**Cite this article as:** Pol TT, Jiandani MP, Gajakos S, Shahane N, Koli VR. Use of ozone in healing failed pectoralis major myocutaneous advancement flap *Int J Res Med Sci* 2016;4:xxx-xx.