

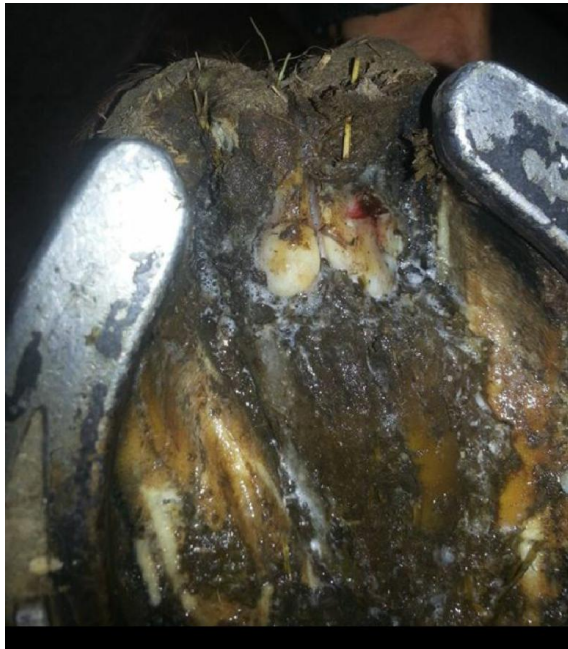
## Severe Canker Healed In Less Than Two Week Using RevitaVet™

GoldFinder “Fin” is an 8 yo Thoroughbred Gelding who came to Texas from Georgia. Shortly after he arrived he started showing signs of being lame in the front end. We presumed it was an abscess and treated accordingly for an abscess. Within a few days he was sound again and went back into work. Shortly after he went lame again so the vet came out and pulled X-rays and diagnosed him with an abscess. So I began soaking and packing again. He became sound but I turned him out for a few days to recover mentally. I brought him back and cleaned out his feet, revealing a horrible looking frog. I sent a photo to my vet who said that it was a Canker. I have never seen, much less dealt with a canker. So we followed “protocol” and having the vet and farrier cut away at his foot “removing” the canker. He had a plate put on his foot and was given 9 weeks of rest only for the Canker to come back.

So I started my research all over and then talked to Tom Neuman of RevitaVet. He had a hoof pad he wanted me to try while simultaneously applying one of the RevitaVet pad on the coronary band. I have used the RevitaVet for years for anything and everything. So I started Fin with it as soon as I got home from AEC’s. I used it twice a day and by the 4<sup>th</sup> day there was already and dramatic improvement. He was walking better, his sole and frog were not a sensitive to touch and less discharge. Exactly 7 days later he was sound, and the Canker was no longer visible. I used it one more week twice a day before having the farrier come out. We put a bar shoe on him to support his heel (and protect it). Our farrier was baffled by the fact that his hoof was growing so fast and healthy his frog was already really completely grown back after 2 WEEKS! I kept using the System for the rest of October now on both front feet to support healthy foot growth. At only 4 weeks, he needed to be re-shoed. This time we just put a basic keg shoe on and he has been sound and happy ever since. I have also used the RevitaVet on horses with Thrush, and a little quarter horse gelding who has poor circulation in his feet. It has been a miracle worker in our barn.

The photo below is Fin after the surgery at 12 weeks when he was given clear for turnout in mid September.

Nicky Jones-Taylor  
X to C Training  
Aledo, TX



**October 6, 2014**



**October 20, 2014**