

Case Study: Use of NewGel+ Sheeting on Facial Trauma Scar

Philip Narini, MD, FACS, Chief of Plastic Surgery at Lakeridge Health

PATIENT: A 24-year-old college student sustained a facial laceration during an assault with a knife.

PROCEDURE: The patient's wound was through-and-through the upper lip and cheek. It was sutured and repaired primarily in the emergency room.

SCAR TREATMENT PROTOCOL: The patient used NewGel+ silicone gel sheeting on the scar for twelve hours per day, seven days per week, for a 12 week treatment period.

RESULTS: This case demonstrates the positive aesthetic effects achieved by treating an acute facial laceration with NewGel+ silicone sheeting.

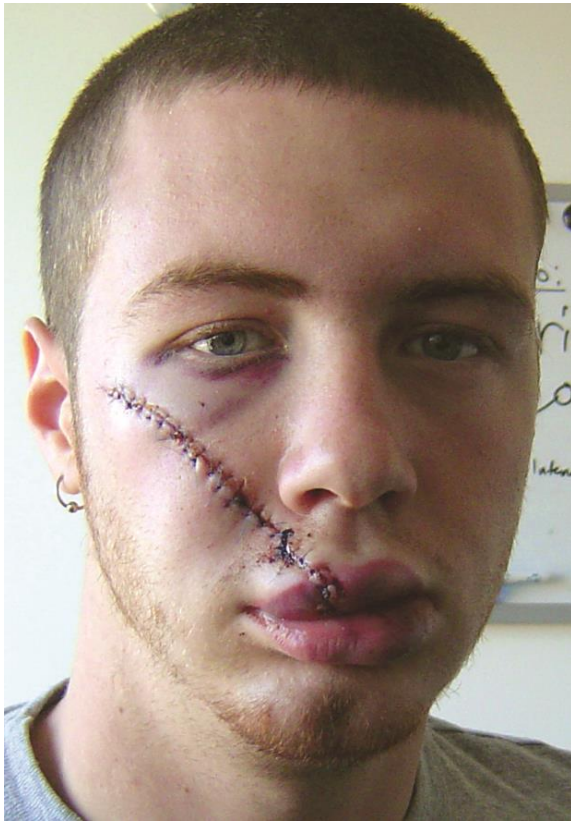

Fig1 - October 27, 2007 (Before using NewGel+)
Approximately 2 weeks after the lip repair, patient started treatment with 1"x6" silicone gel strips (Newmedical Technology), which he used 12 hours per day, seven days per week.




Fig 2 - February 15, 2008 (After 12 weeks treatment)

Post-treatment photo shows dramatic results with no perceptible scar across the lip or vermillion border. Only a small portion of the scar in the upper third of his face is minimally visible.