


## LEFT BREAST WITH IRREGULAR MASSES

There are three masses within this model. Try to locate them.

More information regarding these masses can be found on the back of this card.



*Left Breast  
(anterior view)*

**To clean and maintain:**

Wash with mild soap and water, then apply baby powder to surface.

## LEFT BREAST WITH IRREGULAR MASSES



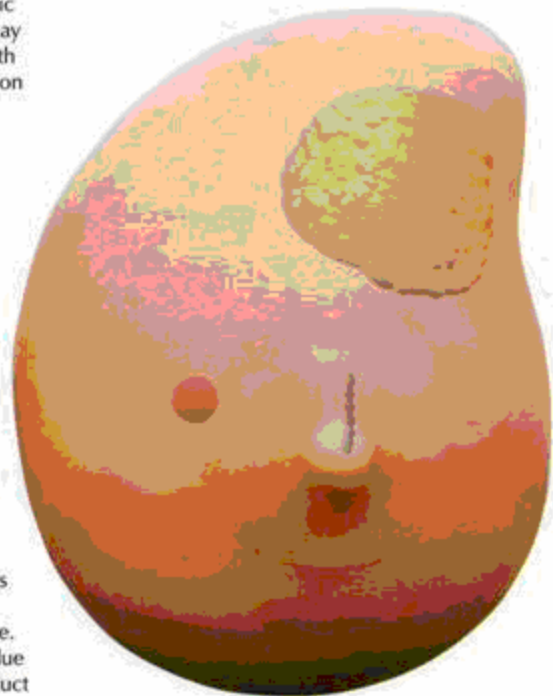
**Fibrocystic Mass** - An asymptomatic mass that is smooth, mobile and may be compressible. Often women with this noncancerous (benign) condition experience lumpy, painful or tender breasts, and sometimes nipple discharge.



**Tumor** - Tumors (abnormal tissue masses) can be malignant (cancerous) or benign (noncancerous). Breast cancer is a malignant tumor that begins in the cells of the breast. A malignant tumor may invade surrounding breast tissue or spread throughout the body (metastasize). Benign breast tumors are abnormal growths that do not spread outside the breast tissue, but are important because women with these conditions are at a greater risk of developing breast cancer.



**Plugged Lactiferous Duct** - One of many ducts (thin tubes) of the mammary gland that carry milk from the lobes of each breast to the nipple. When nursing the duct can become plugged due to residual milk. If left untreated the plugged duct can lead to infection.



*Color of irregular masses for illustrative purposes only*