

Microfat Grafting in Nasal Surgery

O. Onur Erol, MD

Aesthetic Surgery Journal
2014, Vol. 34(5) 671–686
© 2014 The American Society for
Aesthetic Plastic Surgery, Inc.
Reprints and permission:
[http://www.sagepub.com/
journalsPermissions.nav](http://www.sagepub.com/journalsPermissions.nav)
DOI:10.1177/1090820X14529444
www.aestheticsurgeryjournal.com



Abstract

Background: Injectable fillers are sometimes necessary to correct slight skin irregularities. However, there have been reports of necrosis after injection of alloplastic materials and heterogeneous transplants. On the other hand, the advantages of autogenous tissue grafts over those fillers are well established. Volumetric reshaping of the face with autologous tissue injection is a popular and reliable method with good long-term results. However, procedures performed on the fragile skin of the nose are prone to complications.

Objectives: The author conducted a study of injectable autologous microfat grafting to the nose in patients with secondary nasal deformities.

Methods: During a 5-year period, 313 patients who had secondary nasal deformities with slight skin irregularities or severe nasal skin damage were treated with microfat grafting. At each patient's first injection session, excess harvested fat was cryopreserved for subsequent injection. To correct minor irregularities, 0.3 to 0.8 mL of microfat was injected during each session; for major irregularities or defects, 1 to 6 mL was required for each session.

Results: One to 3 injections of microfat provided satisfactory results in all patients who had minor irregularities. For patients with multiple and severe irregularities, 3 to 6 injections were necessary and resulted in high patient satisfaction. In another group of patients, with severe traumatic skin damage, 6 to 16 injections were necessary for reconstruction. After repeated injections, each patient's skin damage was repaired.

Conclusions: Autologous microfat injection appears to be safe and effective for correcting slight irregularities of the nose.

Level of Evidence: 4

Keywords

autologous tissue transfer, cryopreservation, fat grafting, intradermal injection, microfat graft, rhinoplasty, immediate expansion



Accepted for publication October 22, 2013.

Various injectable materials have been utilized for facial soft-tissue contouring, including autologous material (free fat, dermis), heterogeneous material (bovine collagen), and alloplastic material (silicone, methyl-methacrylate spheres, polytetrafluoroethylene, and hyaluronic acid).¹⁻⁹ The advantages of autologous tissue grafts over alloplastic materials and heterogeneous transplants have been well established. Volumetric reshaping of the face with autologous tissue injection is a popular and reliable procedure that provides good long-term results.¹⁰⁻³⁵

METHODS

During a 5-year period, from 2009 to 2013, a total of 313 patients (286 women, 27 men; Table 1) who had secondary nasal deformities with minor skin irregularities or severe nasal skin damage underwent microfat grafting performed by the author. Patients were treated consecutively, and the follow-up period ranged from 1 to 5 years. This is

a retrospective study of patients with nasal deformities and skin irregularities of the nose treated with microfat grafting with no inclusion or exclusion criteria. The study was conducted in accordance with guidelines of the Declaration of Helsinki. Prior to the study, informed consent was obtained for each patient.

Dr Erol is Professor Emeritus, Department of Plastic Surgery at Hacettepe University, Ankara; Past Head of the Department of Plastic Surgery at Istanbul Science University; and a staff surgeon at American-Koc Hospital, Istanbul, Turkey.

This study was presented at the Rhinoplasty Society Meeting in Vancouver, British Columbia, on May 3, 2012, and at the European Association of Plastic Surgeons meeting in Antalya, Turkey, on May 31, 2013.

Corresponding Author:

Dr O. Onur Erol, ONEP Plastic Surgery Science Institute, Manolyali Sokak No. 15 Levent, Istanbul, Turkey.
E-mail: onurerolmd@onep.com.tr

Table 1. Patient Demographics

| Age Range, y | Patients, No. (%) (N = 313) | Women | Men |
|--------------|-----------------------------|-------|-----|
| 18-25 | 29 (9.26) | 24 | 5 |
| 25-30 | 34 (10.86) | 30 | 4 |
| 30-40 | 120 (38.33) | 109 | 11 |
| 40-50 | 88 (28.11) | 81 | 7 |
| 50-60 | 32 (10.22) | 32 | 0 |
| 60-70 | 6 (1.91) | 6 | 0 |
| 70-80 | 4 (1.27) | 4 | 0 |

Harvesting and Preparing Fat Grafts

The abdomen and flanks were the most common sites for fat harvesting. If those regions were not adequate, fat was obtained from the trochanteric region, buttocks, or medial thigh. With the patient under general anesthesia, a small incision was made and the fat was obtained through a 10-mL syringe and 3-mm cannula. (A local anesthetic was not applied to donor sites.) Once the syringe was filled with fat, the cannula was removed from the syringe and the grafts were transferred into 10-mL Luer-Lok syringes (Becton Dickinson, Franklin Lakes, New Jersey) after removing the plunger and sealing the aperture. The sealed Luer-Lok syringes were then centrifuged at 3000 rpm for 3 minutes. The upper liquid lipid layer and the lower aqueous layer were discarded, and 1 g of first-generation cephalosporin was added for each 100 g of centrifuged fat tissue.

Protocol for Freezing and Thawing

After the required amount of fat or tissue cocktail was injected, the remainder was cryopreserved. Specimens were placed into 10-, 20-, or 50-mL sterile tubes, labeled, frozen at -196°C in a liquid nitrogen tank, and transferred

to a UF 601 medical refrigerator (Electrolux, Stockholm, Sweden) for storage at -80°C . Cryopreserved graft specimens were taken from the medical refrigerator 12 hours before subsequent procedures, transferred to a standard refrigerator (-15°C), and thawed slowly at room temperature for 1 hour before injection.

Injection of Fat

The area of the nose to be injected was marked while the patient was standing. A local anesthetic mixture, comprising 20 mL of 0.5% bupivacaine, 0.50 mg of adrenaline, 30 mL of physiologic serum, and 20 mg of triamcinolone acetonide, was injected into recipient sites to decrease posttreatment edema and ecchymosis and to create vasoconstriction of vessels to diminish the risk of microembolism.

Depending on the thickness of the skin, injections were performed with either a 22- or 24-gauge intravenous cannula (Figure 1). To correct minor irregularities, 0.3 to 0.8 mL of cryopreserved microfat graft material was injected 1 to 3 times; for major irregularities or defects, 1 to 6 mL was injected 3 to 6 times. For cases of severe nasal deformities with damaged skin, injections of cryopreserved microfat graft material were performed every 2 months (6-16 times).

Repeat injections were performed of the cryopreserved fat. Small amounts of fat were injected intradermally or subcutaneously, depending on the injection site. For repeated injections, patients received a local anesthetic.

Evaluation

Patients were evaluated by comparing pre- and posttreatment photographs taken in the same studio using a Nikon camera (Nikon Corp, Tokyo, Japan) with a 105-mm micro lens, 2 studio flash heads, and the same film exposure, magnification, lighting, and angle.

During the first posttreatment year, patients were seen every 3 months, and photographs were obtained at every

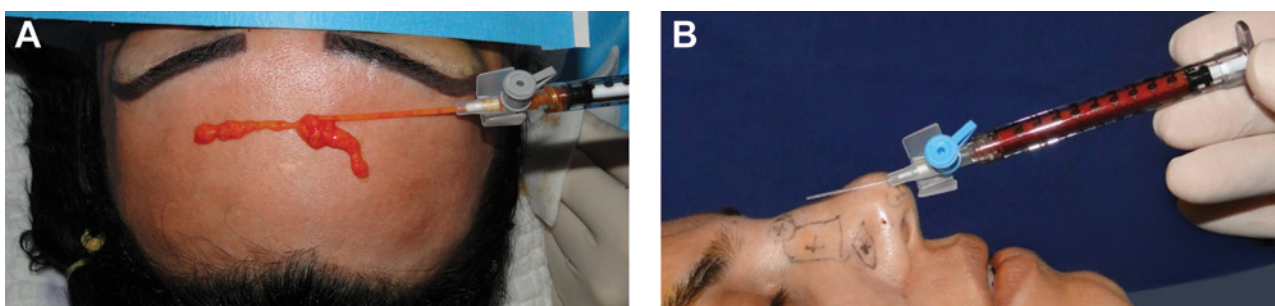


Figure 1. (A) Patient is a 35-year-old woman. Macroscopic view of cryopreserved fat graft 2 years after harvesting. (B) Injection sites were marked for treatment of skin irregularities that had occurred postoperatively after a primary rhinoplasty in another institute. A 22- to 24-gauge intravenous cannula was used, depending on skin thickness. For each session for a total of 3 sessions, 0.3 to 6 mL of microfat graft material was injected.

Table 2. Clinical Improvement in Patients Treated With Microfat Injection, as Rated by Both the Author and Patient

| Score | Nasal Skin Irregularities, No. (%) | | |
|--------------------------|------------------------------------|----------------|--------------------------------------|
| | Minor (n = 264) | Major (n = 38) | Damaged Nasal Skin, No. (%) (n = 11) |
| 0 (no improvement) | 0 (0) | 0 (0) | 0 (0) |
| 1 (minimal improvement) | 0 (0) | 0 (0) | 0 (0) |
| 2 (moderate improvement) | 5 (1.89) | 7 (18.42) | 0 (0) |
| 3 (good improvement) | 259 (98.10) | 31 (81.57) | 11 ^a (100) |

^aDamaged skin ready to undergo reconstructive rhinoplasty was rated as "good improvement."

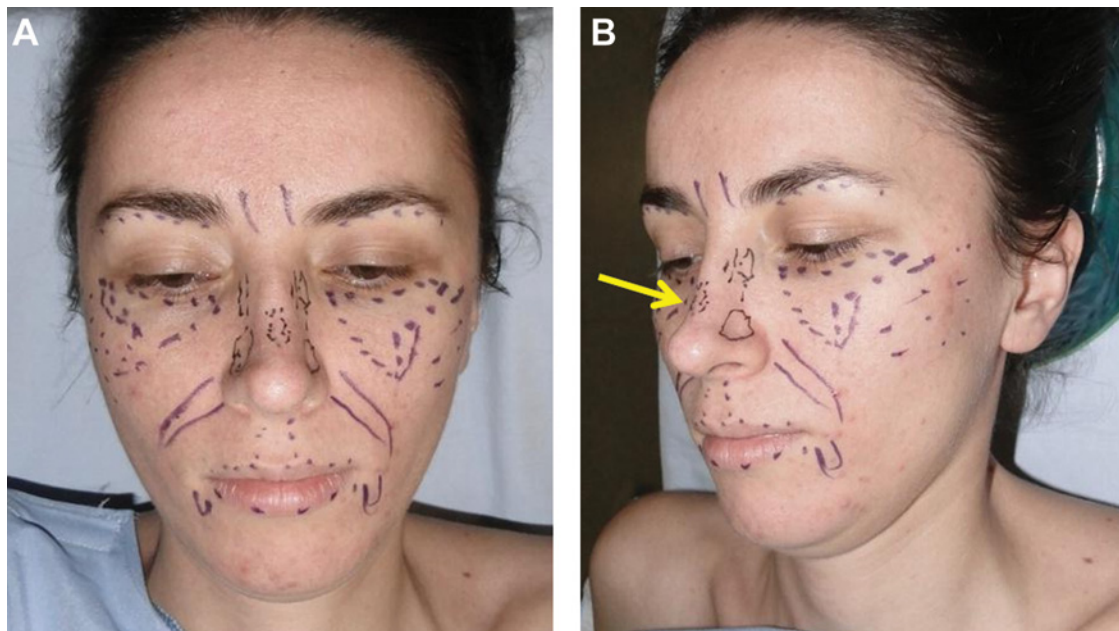


Figure 2. This 31-year-old woman presented with small irregularities on her nose after rhinoplasty surgery. Microfat grafting for correction of these irregularities and for facial rejuvenation is planned. Markings on the nose and face show the injection sites. (A) Frontal view. (B) Oblique view. Arrow indicates the supratip depression.

clinic visit. Thereafter, follow-up and photography were performed annually. At each visit, patient and author assessments of the results were noted in the medical record. Clinical assessments were made using medical records of the treatment and graded digital photographs. In addition, subjective patient satisfaction ratings were documented in the medical records.

Patients were categorized into 3 groups according to the severity of their deformities. Patients in group 1 had slight irregularities of the skin on the nose, which were considered completely resolved when the clinical appearance was scored as 3. Patients in group 2 had marked irregularities and depressions on the skin and cartilage, which were considered not completely corrected with a rating of 2 and completely corrected with a rating of 3. Patients in group 3 had severe nasal deformities with damaged skin and were considered ready to undergo reconstructive rhinoplasty

with a rating of 3 (Table 2). To determine patient satisfaction, ratings were made by the author and patient together, face-to-face, and results were evaluated by examining pre- and posttreatment clinical photographs. The overall clinical appearance of improvement was scored on a scale of 0 to 3 (0 = no improvement, 1 = minimal improvement, 2 = moderate improvement, 3 = good improvement).

RESULTS

For all patients in group 1 (n = 264), 1 to 3 injections of microfat graft material provided satisfactory results (Figures 2-4). One patient in this group experienced complications after overcorrection with microfat injection, which caused severe bruising (with the threat of necrosis) that lasted 3 weeks. Complications resolved without sequelae. (See online-only Appendix at www.aestheticsurgeryjournal.com.)

Table 3. Number of Injections Administered

| Group | Patients (n) | Injections (n) |
|-------|--------------|----------------|
| 1 | 264 | 1-3 |
| 2 | 38 | 3-6 |
| 3 | 11 | 6-16 |

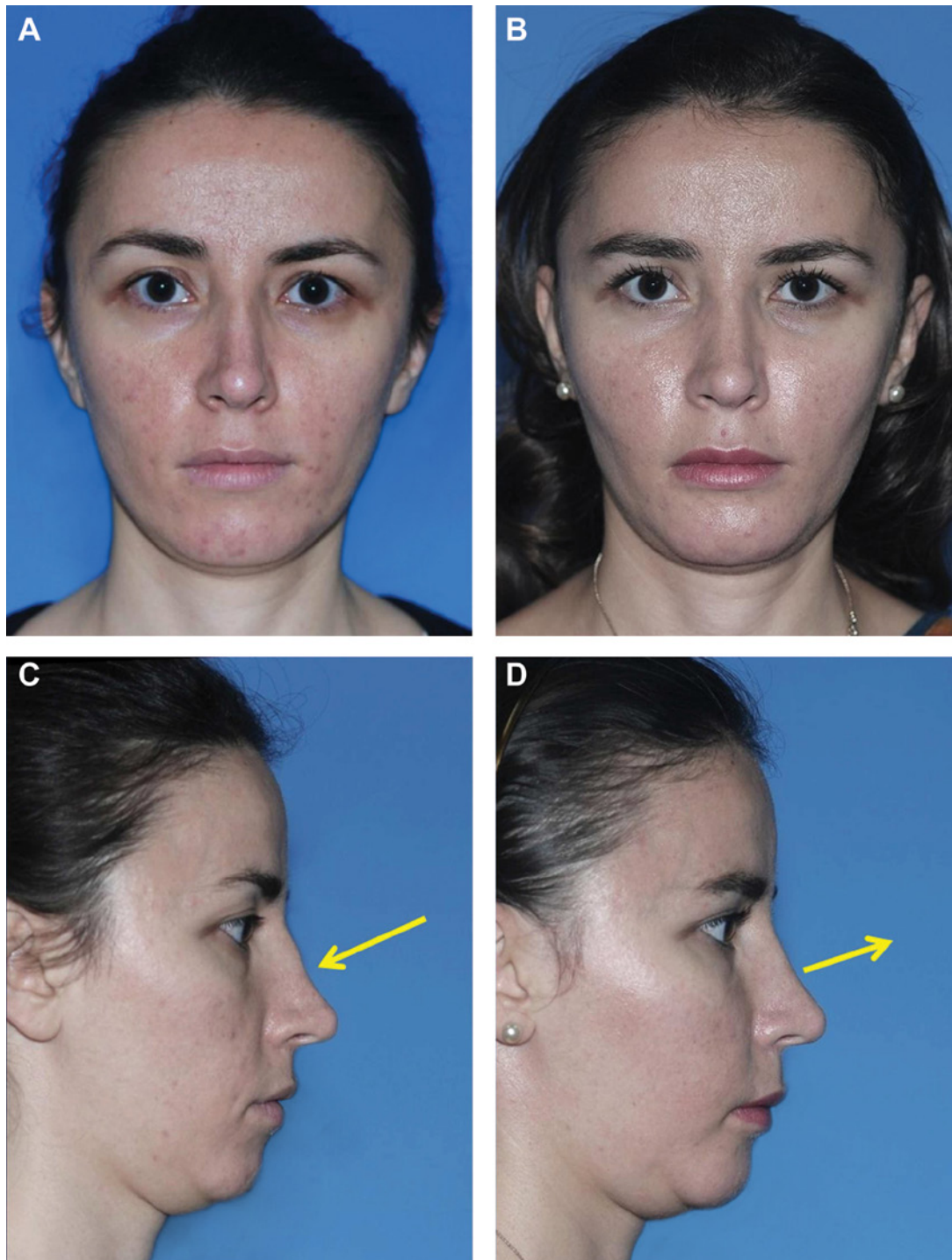

Figure 3. Additional images of the 31-year-old woman depicted in Figure 2, obtained (A, C) before and (B, D) 1 year after the second and final session of microfat grafting to the nose. (A, B) Frontal views; arrow denotes the area of depression. (C, D) Lateral views; arrow indicates the depression (C) and its correction (D). During each session, a 3-mL microfat graft was injected.

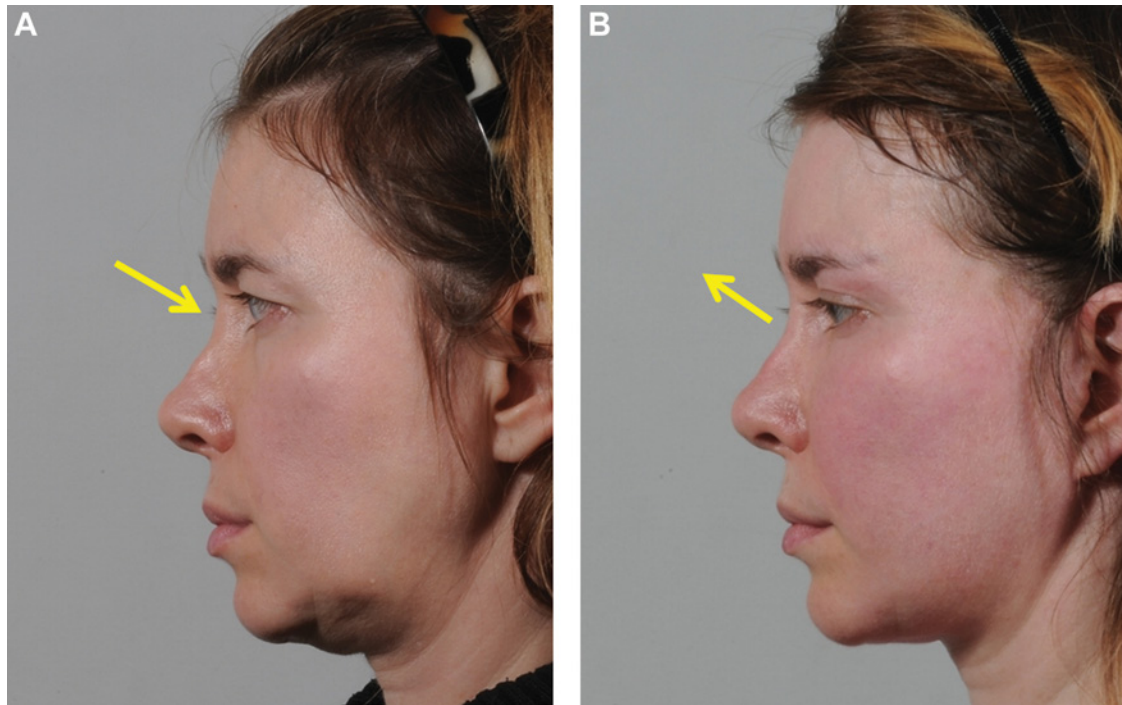

Figure 4. (A) This 45-year-old woman presented for correction of a radix depression (indicated by arrow). (B) One year after treatment with microfat grafting; 3 mL of microfat was injected in a single session to correct the radix depression (arrow).

In group 2 (38 patients), 3 to 6 injections were necessary and resulted in patient satisfaction (Figure 5). In group 3 (11 patients), 6 to 16 injections were necessary to allow further reconstruction of the nose (Table 3).

Three patients in group 3 had previously refused the forehead flap reconstruction option recommended by other physicians. For these patients, the damaged skin recovered after several sessions of microfat injection, allowing subsequent surgical intervention (Figure 6). Reconstruction was possible with immediate expansion of skin flaps³⁶⁻³⁹ and insertion of a cartilage graft. Successful fat grafting after elevation of the skin flaps was considered proof of the viability of the cryopreserved graft (Figure 7). The nose was reconstructed with the patient's own nasal skin, and these patients were satisfied with their results (Figure 8). After treating the damaged skin with cryopreserved microfat grafting, no complications occurred (ie, no vascular impairment, skin necrosis, or infection). (Images of another patient are available in the online-only Appendix.)

DISCUSSION

Although microfat grafting for the nose is beneficial, it has not been the specific focus of many published articles, and it has been mentioned only sporadically in medical literature pertaining to general facial microfat grafting.³³⁻³⁵ Because they are readily available and preferred by many

physicians, various fillers have been injected to correct skin irregularities or depressions on the nose. However, if these materials are injected into the nose by inexperienced individuals, many complications can occur.^{9,39-49} In general, hyaluronic acid injections are currently the preferred option; they are readily available and result in relatively fewer complications than other fillers.^{5,50-57} However, hyaluronic acid is not free of complications.^{40,43,46-48} Therefore, the author and other investigators^{29,31,33-35} recommend microfat grafting, which can correct small or severe irregularities of nasal skin. The procedure does not require grafting cartilage and should be preferred to injections of alloplastic material.

The need for additional injections may be lessened by cryopreservation of the harvested fat grafts. In a murine model, Shoshani et al⁵⁸ achieved varying results with preservation of harvested fat at -16°C and -18°C for 1 to 2 weeks. The injected fat survived in their experimental and control groups.⁵⁸ In another study, performed in isogenic Sprague-Dawley rats, there was a decrease in viable adipocytes and an increase in fat cell necrosis in the animals that received stored fat relative to those that underwent immediate graft injection.⁵⁹ In that study, viability and histology of preserved fat grafts were maintained by dry freezing in liquid nitrogen at -35°C and -195°C .^{60,61} According to many studies of cryopreservation with different protocols of freezing and thawing, adding cryoprotective agents (dimethyl sulfoxide, trehalose,

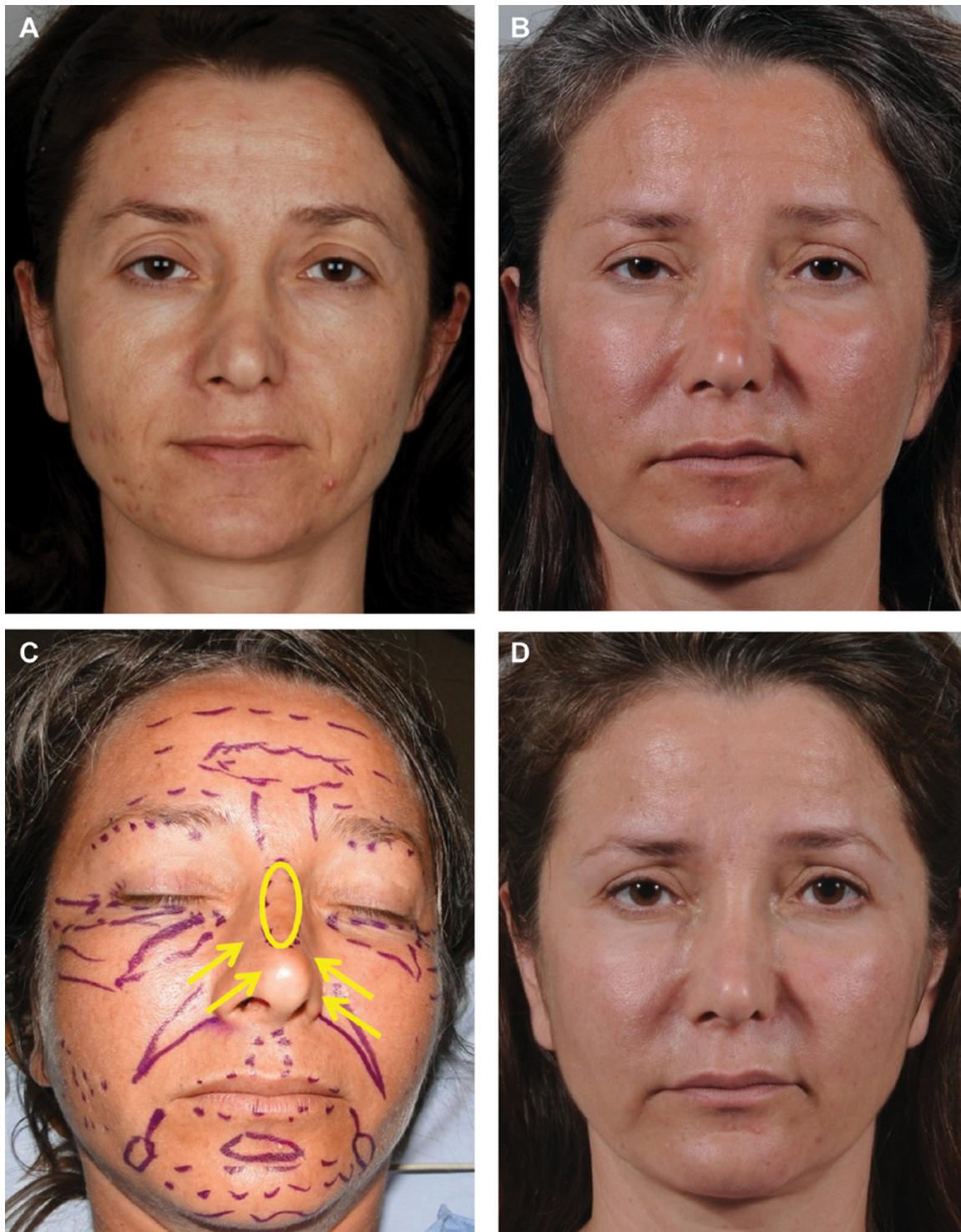

Figure 5. This 40-year-old woman presented for facial rejuvenation. She displayed severe postoperative deformities from a rhinoplasty performed several years earlier. (A) Pretreatment frontal view showing inverted V deformity, marked skin irregularities, and depression of the nose. (B) One year after the first session of microfat grafting (6-mL injection). (C) Pretreatment injection-site markings. Arrows and circle indicate depressions and inverted V deformity of the nose. (D) One year after the second session (3-mL injection). (E) Two years after the third and final session (4 years after the initial session; 3-mL injection). (F) Pretreatment oblique view and (G) posttreatment oblique view after 4 years (2 years after the last grafting session).

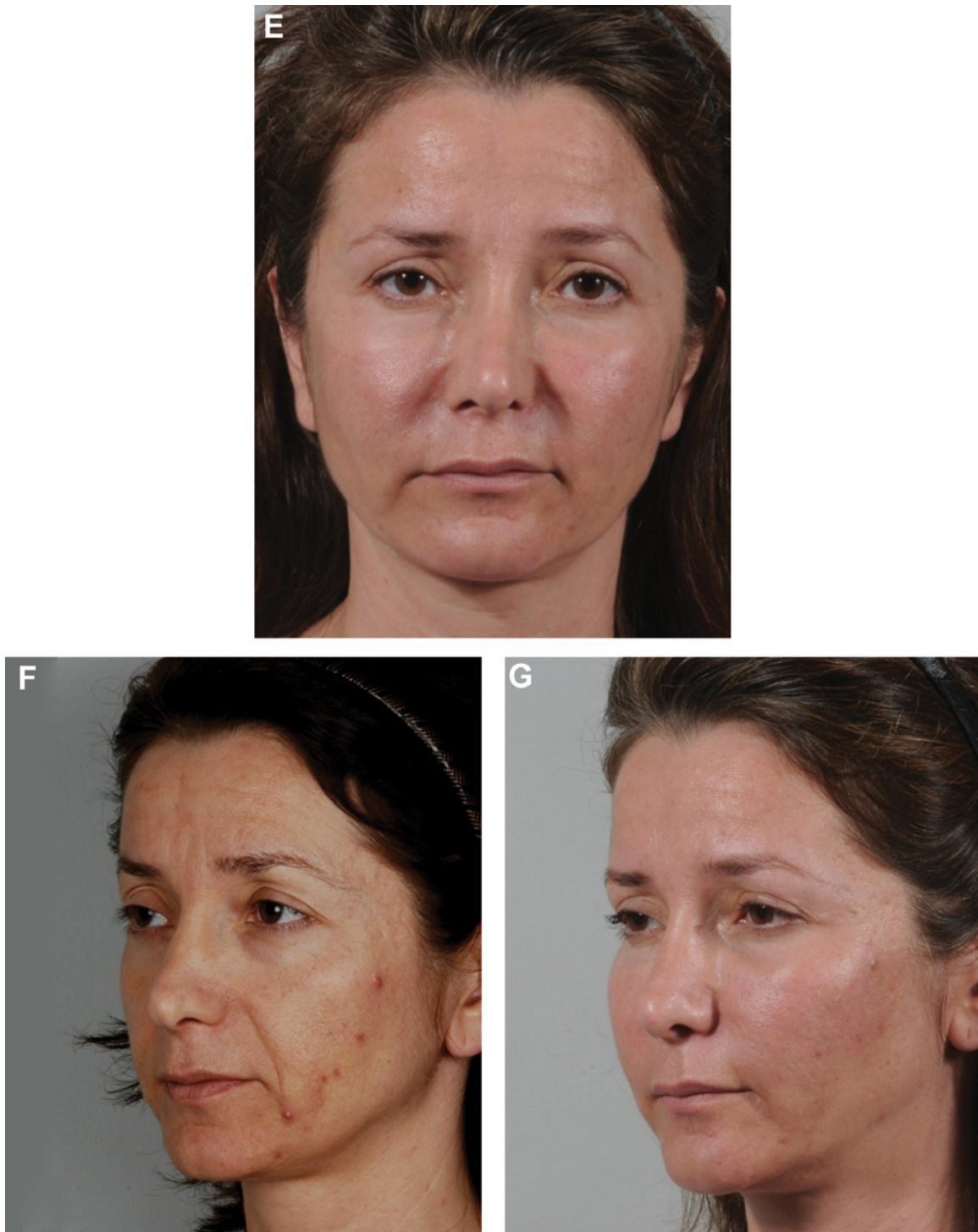

Figure 5. (continued) This 40-year-old woman presented for facial rejuvenation. She displayed severe postoperative deformities from a rhinoplasty performed several years earlier. (A) Pretreatment frontal view showing inverted V deformity, marked skin irregularities, and depression of the nose. (B) One year after the first session of microfat grafting (6-mL injection). (C) Pretreatment injection-site markings. Arrows and circle indicate depressions and inverted V deformity of the nose. (D) One year after the second session (3-mL injection). (E) Two years after the third and final session (4 years after the initial session; 3-mL injection). (F) Pretreatment oblique view and (G) posttreatment oblique view after 4 years (2 years after the last grafting session).

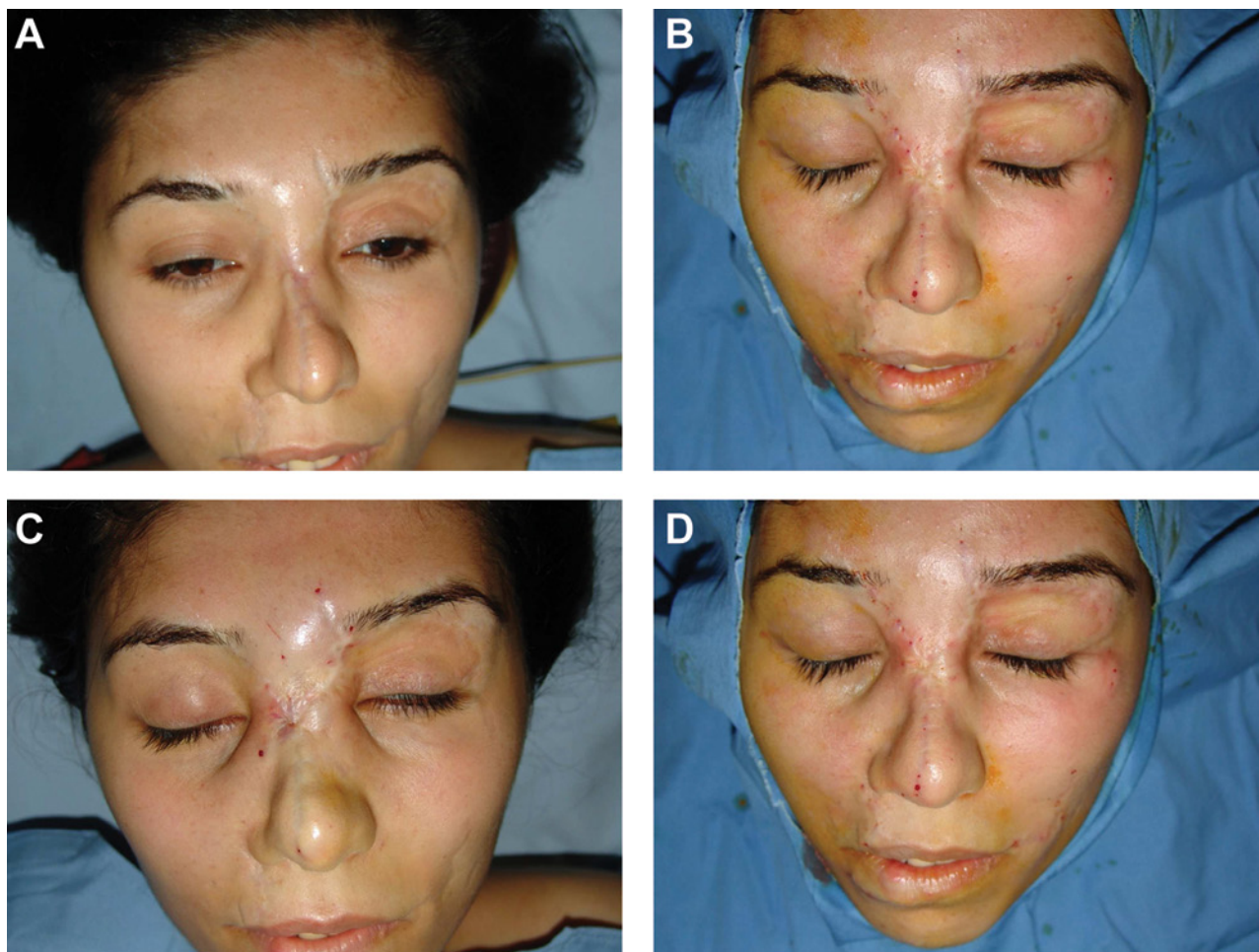


Figure 6. In 2008, this 24-year-old woman presented with severe nose deformities that resulted from a traumatic car accident in 2006. She decided against forehead flap reconstruction. Her skin was damaged and scarred. Therefore, a salvage procedure with microfat grafting was necessary to correct severe skin damage and enable skin flap creation for reconstruction. (A) Pretreatment view of the patient. (B) Appearance of the nose after 4 sessions of microfat grafting; improvement of skin quality was evident. (C) Appearance of the nose after 7 sessions of microfat grafting; improvement of the skin had continued. (D) At 6 months, after the last of 16 sessions of microfat injection, the damaged skin had recovered and the patient was deemed ready for reconstructive surgery. (Cryopreserved fat was used for the final 15 sessions.)

or glycerol) adequately protects fat grafts.⁶²⁻⁶⁹ Moreover, patient acceptance of results was uniformly positive with this method of cryopreservation.³⁰⁻³²

Microfat grafting is indicated to correct slight skin irregularities for which cartilage grafting would not be suitable, as well as moderate skin irregularities for which fat grafting would be less invasive than cartilage grafting. Microfat grafting also may be indicated for patients who prefer the technique, do not wish to undergo revision rhinoplasty, or desire a procedure that is less expensive than revision rhinoplasty. Contraindications include nasal skin infections, active herpes infections, necrotic nasal skin, and active nasal skin furuncles. Local anesthetics with epinephrine should not be administered in heavy smokers.

CONCLUSIONS

Microfat grafting appears to be effective for correcting minor irregularities of nasal skin and may be appropriate for patients who cannot undergo revision rhinoplasty. It is also an effective salvage procedure for severely damaged skin of the nose. Injection of cryopreserved fat over several sessions is well accepted by patients because cryopreservation of excess harvested fat grafts for subsequent use makes repeated fat graft harvesting unnecessary. No late complications were observed during the present study. Microfat grafting is not a replacement for, but may be a complement to, modern rhinoplasty techniques.

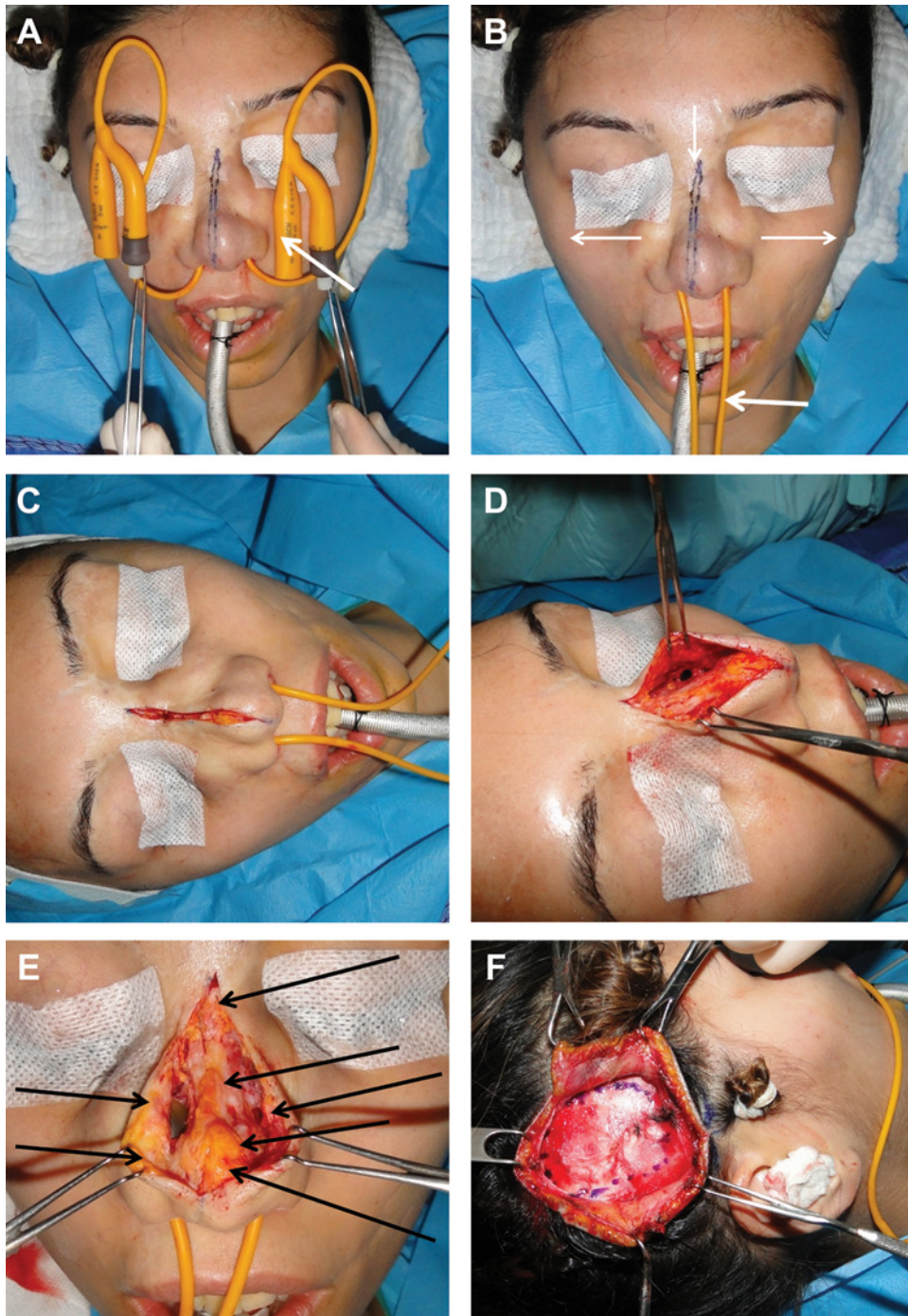


Figure 7. Description of the reconstructive surgery performed in the 24-year-old woman depicted in Figure 6. (A) Immediate expansion of the lateral walls of the nose using a Foley urine catheter (arrow). (B) Expanded lateral wall skin; Foley catheter and incision line marking are indicated by arrows. (C) Incision. (D) Dissection of lateral skin flaps. (E) Advancement of the lateral skin flaps medially; arrows indicate the surviving cryopreserved fat grafts (6 months after the 15th session of injection). (F) Superficial temporal fascia graft harvesting. (G) A fascial graft was applied and sutured to the lateral walls and radix in a manner that left an opening on the caudal end to form a central tunnel (shown by arrow). (H) The cartilage syringe was inserted through the opening, and the compressed costal diced cartilage was injected. The upper arrow indicates the newly created fascial tunnel; the lower arrow indicates newly designed cartilage syringe for injections. (I) The opening was closed by caudal edge sutures (arrows). (J) A cartilage graft from the ear concha (arrow) was inserted into the alar groove. (K) A cartilage strut (arrow) was inserted into the alar rim. (L) Skin flaps were closed. (M) Diced cartilage was injected into the columella through the opening left on the tip of the nose (arrow). (N) A costal cartilage strut (arrow) was inserted through the same opening. (O) Completed closure.

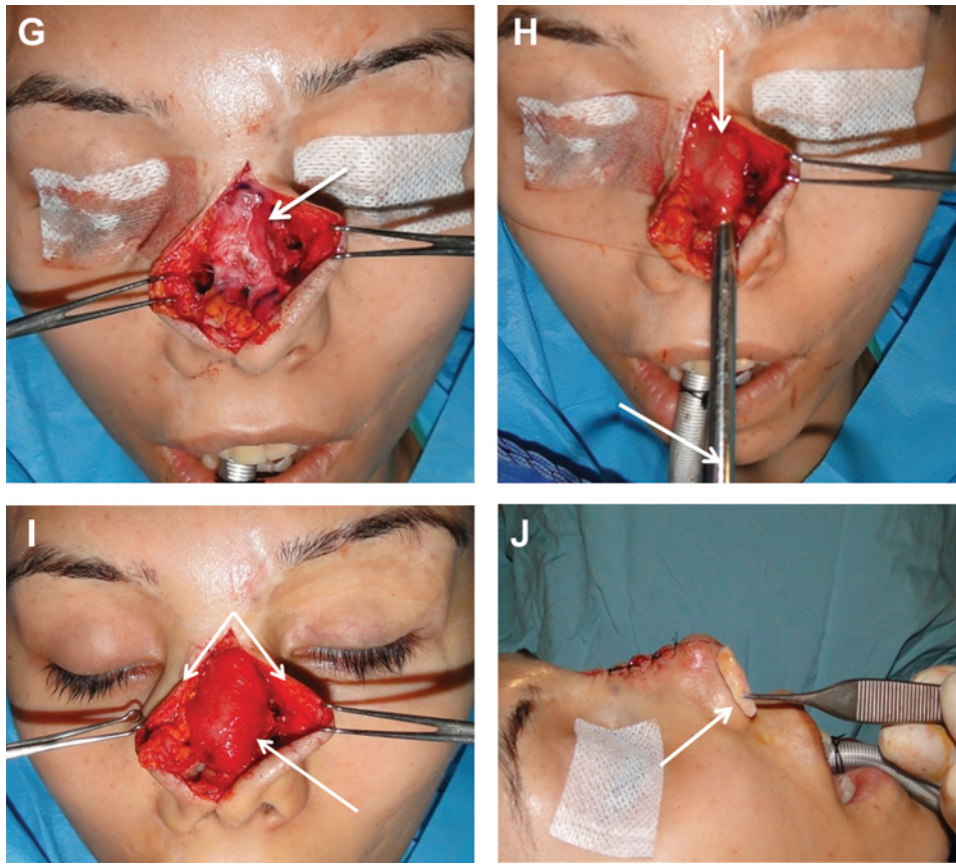


Figure 7. (continued) Description of the reconstructive surgery performed in the 24-year-old woman depicted in Figure 6. (A) Immediate expansion of the lateral walls of the nose using a Foley urine catheter (arrow). (B) Expanded lateral wall skin; Foley catheter and incision line marking are indicated by arrows. (C) Incision. (D) Dissection of lateral skin flaps. (E) Advancement of the lateral skin flaps medially; arrows indicate the surviving cryopreserved fat grafts (6 months after the 15th session of injection). (F) Superficial temporal fascia graft harvesting. (G) A fascial graft was applied and sutured to the lateral walls and radix in a manner that left an opening on the caudal end to form a central tunnel (shown by arrow). (H) The cartilage syringe was inserted through the opening, and the compressed costal diced cartilage was injected. The upper arrow indicates the newly created fascial tunnel; the lower arrow indicates newly designed cartilage syringe for injections. (I) The opening was closed by caudal edge sutures (arrows). (J) A cartilage graft from the ear concha (arrow) was inserted into the alar groove. (K) A cartilage strut (arrow) was inserted into the alar rim. (L) Skin flaps were closed. (M) Diced cartilage was injected into the columella through the opening left on the tip of the nose (arrow). (N) A costal cartilage strut (arrow) was inserted through the same opening. (O) Completed closure.

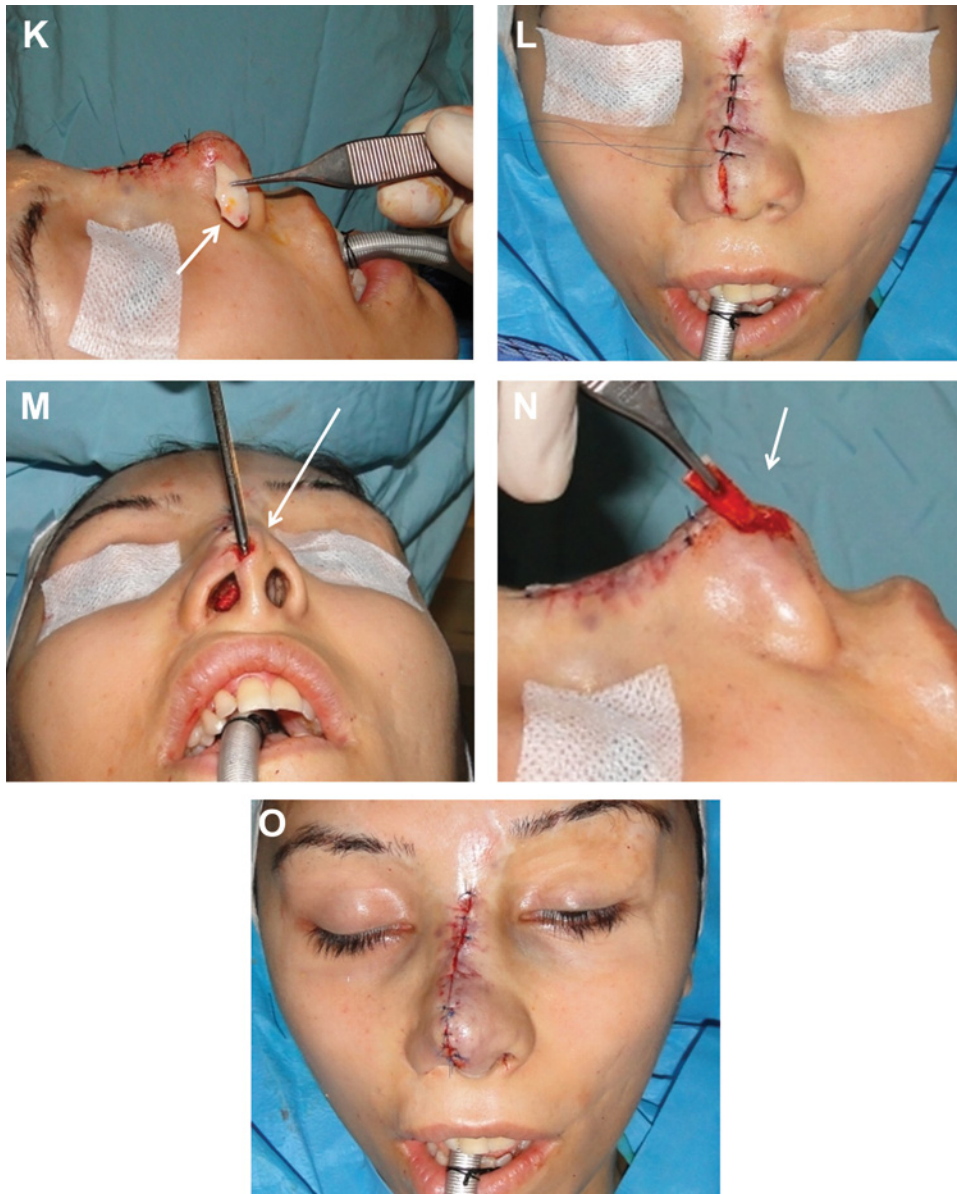

Figure 7. (continued) Description of the reconstructive surgery performed in the 24-year-old woman depicted in Figure 6. (A) Immediate expansion of the lateral walls of the nose using a Foley urine catheter (arrow). (B) Expanded lateral wall skin; Foley catheter and incision line marking are indicated by arrows. (C) Incision. (D) Dissection of lateral skin flaps. (E) Advancement of the lateral skin flaps medially; arrows indicate the surviving cryopreserved fat grafts (6 months after the 15th session of injection). (F) Superficial temporal fascia graft harvesting. (G) A fascial graft was applied and sutured to the lateral walls and radix in a manner that left an opening on the caudal end to form a central tunnel (shown by arrow). (H) The cartilage syringe was inserted through the opening, and the compressed costal diced cartilage was injected. The upper arrow indicates the newly created fascial tunnel; the lower arrow indicates newly designed cartilage syringe for injections. (I) The opening was closed by caudal edge sutures (arrows). (J) A cartilage graft from the ear concha (arrow) was inserted into the alar groove. (K) A cartilage strut (arrow) was inserted into the alar rim. (L) Skin flaps were closed. (M) Diced cartilage was injected into the columella through the opening left on the tip of the nose (arrow). (N) A costal cartilage strut (arrow) was inserted through the same opening. (O) Completed closure.

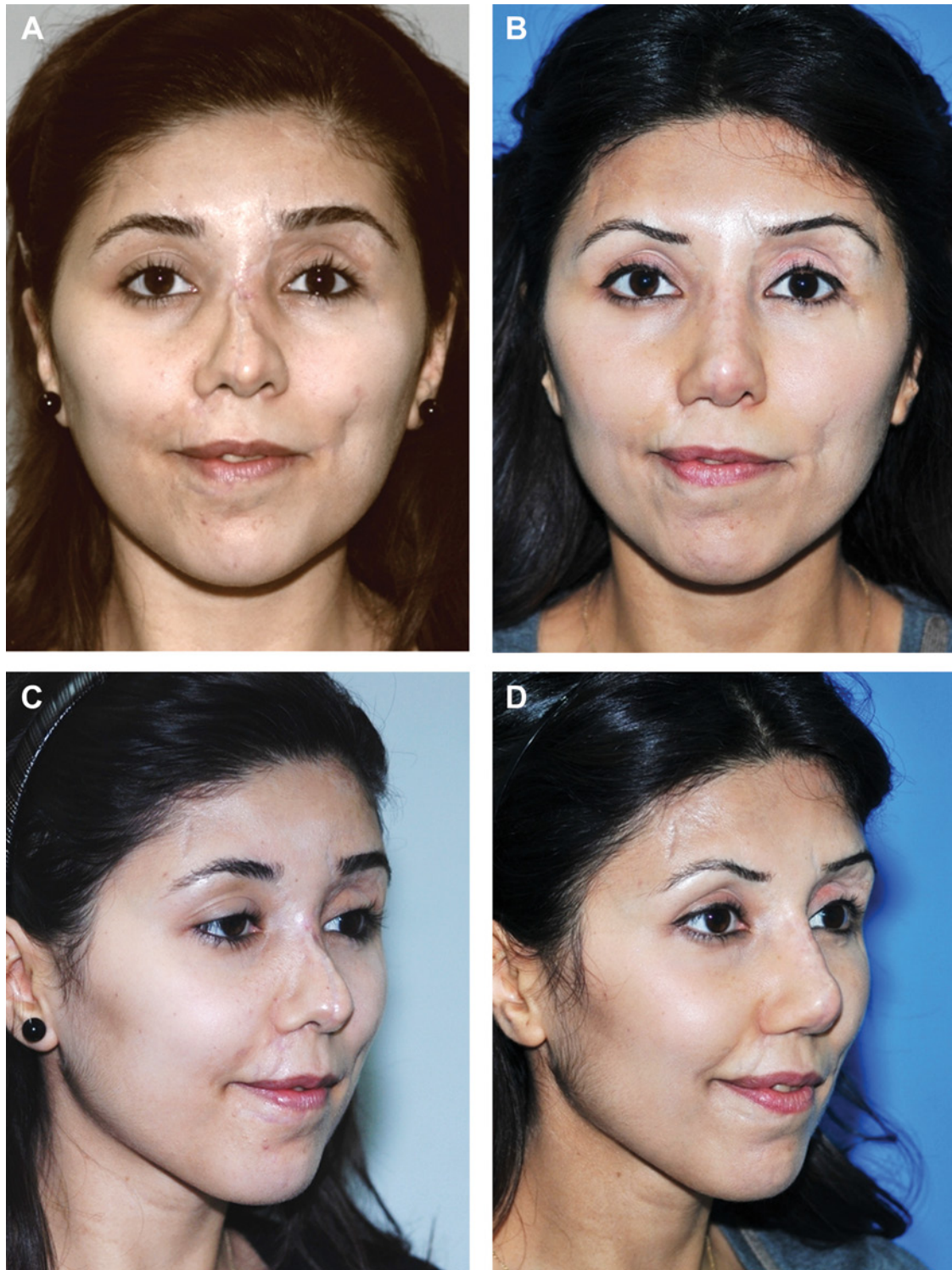

Figure 8. Pretreatment (A, C, E, G, I) and 2-year posttreatment (B, D, F, H, J) views of the 24-year-old woman depicted in Figures 6 and 7, who required a salvage procedure with microfat grafting to correct severe skin damage and to permit a reconstructive procedure. (Also see Figures 6 and 7.)

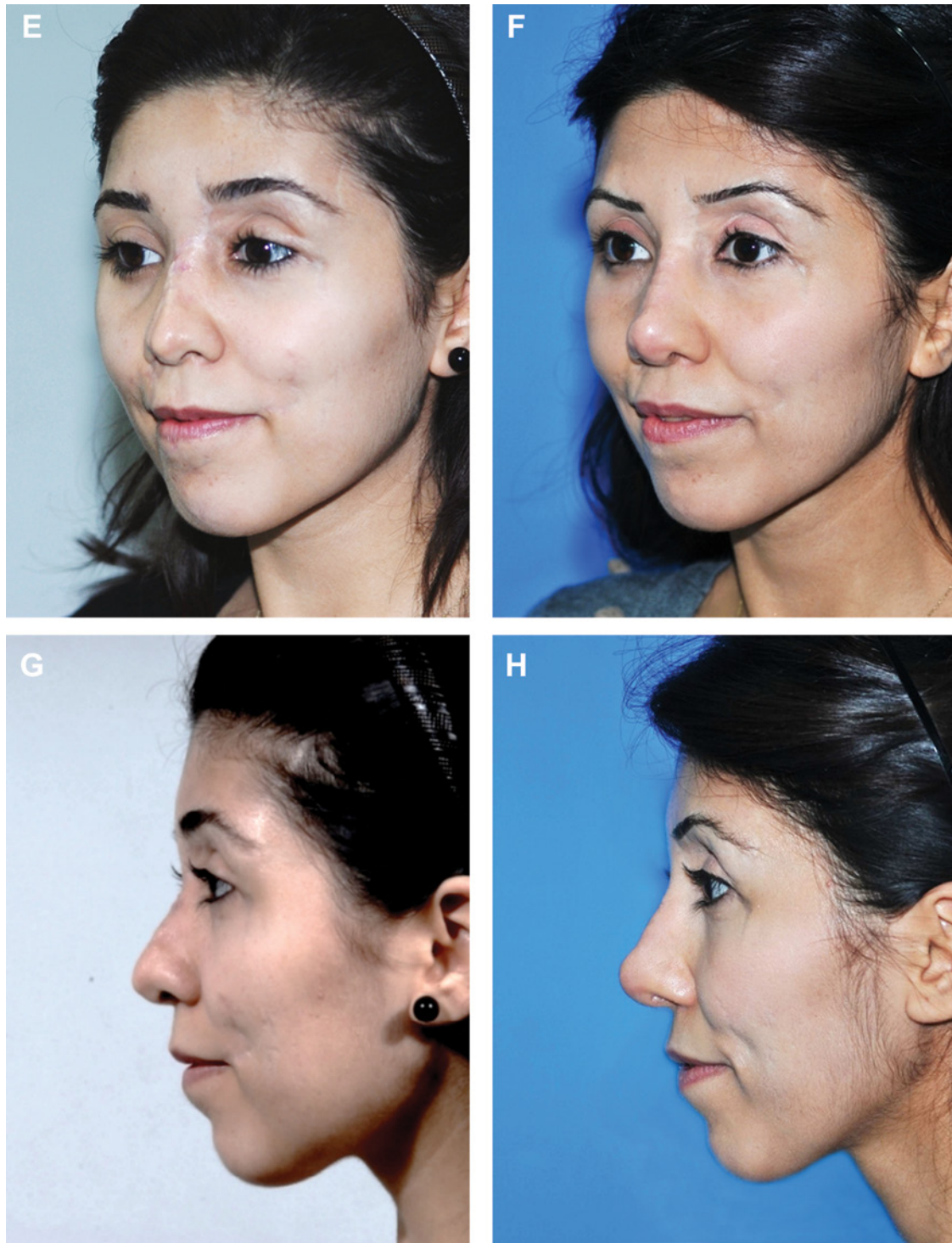


Figure 8. (continued) Pretreatment (A, C, E, G, I) and 2-year posttreatment (B, D, F, H, J) views of the 24-year-old woman depicted in Figures 6 and 7, who required a salvage procedure with microfat grafting to correct severe skin damage and to permit a reconstructive procedure. (Also see Figures 6 and 7.)

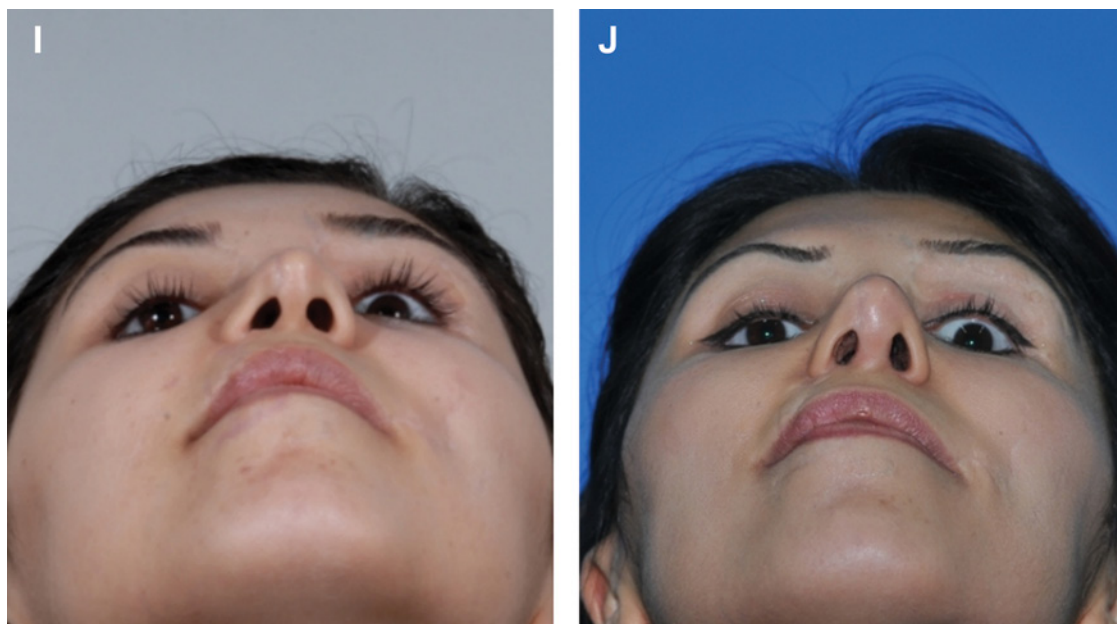

Figure 8. (continued) Pretreatment (A, C, E, G, I) and 2-year posttreatment (B, D, F, H, J) views of the 24-year-old woman depicted in Figures 6 and 7, who required a salvage procedure with microfat grafting to correct severe skin damage and to permit a reconstructive procedure. (Also see Figures 6 and 7.)

Disclosures

The author declared no potential conflicts of interest with respect to the research, authorship, and publication of this article.

Funding

The author received no financial support for the research, authorship, and publication of this article.

REFERENCES

- Schmidt-Westhausen AM, Frege J, Reichart PA. Abscess formation after lip augmentation with silicone: case report. *Int J Oral Maxillofac Surg.* 2004;33(2):198-200.
- Hoffmann C, Schuller-Petrovic S, Soyer HP, Kerl H. Adverse reactions after cosmetic lip augmentation with permanent biologically inert implant materials. *J Am Acad Dermatol.* 1999;40(1):100-102.
- Jordan DR. Soft-tissue fillers for wrinkles, folds and volume augmentation. *Can J Ophthalmol.* 2003;38(4):285-288.
- Fagien S, Elson ML. Facial soft-tissue augmentation with allogeneic human tissue collagen matrix (Dermalogen and Dermaplant). *Clin Plast Surg.* 2001;28(1):63-81.
- Duranti F, Salti G, Bovani B, Calandra M, Rosati ML. Injectable hyaluronic acid gel for soft tissue augmentation: a clinical and histological study. *Dermatol Surg.* 1998;24(12):1317-1325.
- Singh S, Baker JL Jr. Use of expanded polytetrafluoroethylene in aesthetic surgery of the face. *Clin Plast Surg.* 2000;27:579.
- Conrad K, MacDonald MR. Wide polytef (Gore-Tex) implants in lip augmentation and nasolabial groove correction. *Arch Otolaryngol Head Neck Surg.* 1996;122(6):664-670.
- Ridenour B, Kontis TC. Injectable calcium hydroxylapatite microspheres (Radiesse). *Facial Plast Surg.* 2009;25(2):100-105.
- Fulton J, Caperton C. The optimal filler: immediate and long-term results with emulsified silicone (1,000 centistokes) with cross-linked hyaluronic acid. *J Drugs Dermatol.* 2012;11(11):1336-1341.
- Reich J. The application of dermis grafts in deformities of the nose. *Plast Reconstr Surg.* 1983;71(6):772-782.
- Guerrerosantos J. Temporoparietal free fascia grafts in rhinoplasty. *Plast Reconstr Surg.* 1984;74(4):465-475.
- Kempf KK, Seyfer AE. Facial defect augmentation with a dermal-fat graft. *Oral Surg Oral Med Oral Pathol.* 1985;59(4):340-343.
- Illouz YG. Present results of fat injection. *Aesthetic Plast Surg.* 1988;12(3):175-181.
- Bircoll M. A nine year experience with autologous fat transplantation. *Am J Cosmetic Surg.* 1992;9:55.
- Drommer RB, Mende U. Free fat transplantation in the face. *J Craniomaxillofac Surg.* 1995;23(4):228-232.
- Coleman SR. Long-term survival of fat transplants: controlled demonstrations. *Aesthetic Plast Surg.* 1995;19(5):421-425.
- Erol ÖO. Face rejuvenation: combined technique with adjunct of tissue cocktail injection. Presented at: ISAPS Post-Graduate Course; November 6-9, 1994; Sydney, Australia.

18. Erol ÖO. Face rejuvenation: combined technique with adjunction of tissue cocktail injection. Lecture at: XIII International Congress ISAPS; September 29 to October 1, 1995; New York, NY.
19. Erol ÖO. Facial rejuvenation by adjunction of tissue cocktail injection. Presented at: EURAPS, Seventh Annual Meeting; May 16-18, 1996; Innsbruck, Austria.
20. Erol ÖO. Face rejuvenation. Presented at: 8th Congress of the European Section of IPRAS; June 22-25, 1997; Lisbon, Portugal.
21. Erol ÖO. Tissue cocktail for autologous facial contouring. Presented at: 12th Congress of the International Confederation for Plastic, Reconstructive and Aesthetic Surgery; June 27 to July 2, 1999; San Francisco, CA.
22. Erol ÖO. Experience with CO² and erbium laser in facial rejuvenation (Solo and Duo). Presented at: ISAPS International Post Graduate Course; September 25-29, 1999; Victoria Falls, Zimbabwe.
23. Erol ÖO. Facial autologous soft-tissue contouring by adjunction of tissue cocktail injection (micro graft and minigraft mixture of dermis, fascia, and fat). *Plast Reconstr Surg*. 2000;106:1375.
24. Erol ÖO. Autologous volumetric three dimensional shaping of the face. In: Terino OE, ed. *Three Dimensional Facial Sculpting*. New York, NY: Informa Health Care USA; 2007:171-186.
25. Coleman SR. Facial recontouring with liposuction. *Clin Plast Surg*. 1997;24:347.
26. Gatti JE. Permanent lip augmentation with serial fat grafting. *Ann Plast Surg*. 1999;42(4):376-380.
27. Kaufman MR, Bradley JP, Dickinson B, et al. Autologous fat transfer national consensus survey: trends in techniques for harvest, preparation, and application, and perception of short- and long-term results. *Plast Reconstr Surg*. 2007;119(1):323-331.
28. Coleman SR. Facial augmentation with structural fat grafting. *Clin Plast Surg*. 2006;33(4):567-577.
29. Coleman SR. Structural fat grafting: more than permanent filler. *Plast Reconstr Surg*. 2006;118(3)(suppl):108S-120S.
30. Erol ÖO, Gurlek A, Agaoglu G. Calf augmentation with autologous tissue injection. *Plast Reconstr Surg*. 2008;121(6):2127-2133.
31. Erol ÖO. The place of micro fat grafting in nose surgery. Presented at: The Rhinoplasty Society Meeting; May 3, 2012; Vancouver, Canada.
32. Erol ÖO, Agaoglu G. Facial rejuvenation with staged injection of cryopreserved fat or tissue cocktail, a clinical outcome in the past 10 years. *Aesthetic Surg J*. 2013;33(5):639-653.
33. Monreal J. Fat grafting to the nose: personal experience with 36 patients. *Aesthetic Plast Surg*. 2011;35(5):916-922.
34. Cardenas JC, Carvajal J. Refinement of rhinoplasty with lipoinjection. *Aesthetic Plast Surg*. 2007;31(5):501-505.
35. Ellenbogen R. Fat transfer: current use in practice. *Clin Plast Surg*. 2000;27(4):545-556.
36. Erol ÖO. New approach in secondary rhinoplasty for short nose "immediate expansion and cartilage graft." Presented at: XII International Congress ISAPS; September 7-11, 1993; Paris, France.
37. Erol ÖO. New approach in secondary rhinoplasty for short nose "immediate expansion and cartilage graft." Presented at: American Association of Plastic Surgeons (AAPS) Annual Meeting; May 9-12, 1993; Philadelphia, PA.
38. Erol ÖO. New approach in secondary rhinoplasty for short nose "immediate expansion and cartilage graft." Presented at: IV European Association of Plastic Surgeons (EURAPS) Meeting; April 29-May 1, 1993; Strasbourg, France.
39. Park SW, Woo SJ, Park KH, Huh JW, Jung C, Kwon OK. Iatrogenic retinal artery occlusion caused by cosmetic facial filler injections. *Am J Ophthalmol*. 2012;154(4):653-662.e1.
40. Schanz S, Schippert W, Ulmer A, Rassner G, Fierlbeck G. Arterial embolization caused by injection of hyaluronic acid (Restylane). *Br J Dermatol*. 2002;146(5):928-929.
41. Vargas-Machuca I, González-Guerra E, Angulo J, del Carmen Fariña M, Martín L, Requena L. Facial granulomas secondary to Dermalive microimplants: report of a case with histopathologic differential diagnosis among the granulomas secondary to different injectable permanent filler materials. *Am J Dermatopathol*. 2006;28(2):173-177.
42. Inoue K, Sato K, Matsumoto D, Gonda K, Yoshimura K. Arterial embolization and skin necrosis of the nasal ala following injection of dermal fillers. *Plast Reconstr Surg*. 2008;121(3):127e-128e.
43. Burt B, Nakra T, Isaacs DK, Goldberg RA. Alar necrosis after facial injection of hyaluronic acid. *Plast Reconstr Surg*. 2010;125(5):199e-200e.
44. Noh S, Lee SJ, Roh MR. Risk of postinflammatory hyperpigmentation with Fern pattern technique in injecting hyaluronic acid gel. *J Cosmet Dermatol*. 2010;9(3):249-250.
45. Kang MS, Park ES, Shin HS, Jung SG, Kim YB, Kim DW. Skin necrosis of the nasal ala after injection of dermal fillers. *Dermatol Surg*. 2011;37(3):375-380.
46. Kim SG, Kim YJ, Lee SI, Lee CJ. Salvage of nasal skin in a case of venous compromise after hyaluronic acid filler injection using prostaglandin E. *Dermatol Surg*. 2011;37(12):1817-1819.
47. Kim YJ, Kim SS, Song WK, Lee SY, Yoon JS. Ocular ischemia with hypotony after injection of hyaluronic acid gel. *Ophthal Plast Reconstr Surg*. 2011;27(6):e152-e155.
48. Park TH, Seo SW, Kim JK, Chang CH. Clinical experience with hyaluronic acid < @150 > filler complications. *J Plast Reconstr Aesthetic Surg*. 2011;64(7):892-896.
49. Sung HM, Suh IS, Lee HB, Tak KS, Moon KM, Jung MS. Case reports of adipose-derived stem cell therapy for nasal skin necrosis after filler injection. *Arch Plast Surg*. 2012;39(1):51-54.
50. Beer KR. Nasal reconstruction using 20 mg/ml cross-linked hyaluronic acid. *J Drugs Dermatol*. 2006;5(5):465-466.
51. Redaelli A. Medical rhinoplasty with hyaluronic acid and botulinum toxin A: a very simple and quite effective technique. *J Cosmet Dermatol*. 2008;7(3):210-220.
52. Humphrey CD, Arkins JP, Dayan SH. Soft tissue fillers in the nose. *Aesthetic Surg J*. 2009;29(6):477-484.
53. Yan X, Xu J, Lu C, Ma Y, Li W. A multicenter study of the efficacy and safety of Restylane in the treatment of

- nasolabial folds in China. *Plast Reconstr Surg*. 2009;124(5):256e-257e.
54. Bray D, Hopkins C, Roberts DN. Injection rhinoplasty: non-surgical nasal augmentation and correction of post-rhinoplasty contour asymmetries with hyaluronic acid: how we do it. *Clin Otolaryngol*. 2010;35(3):227-230.
55. Modrzynski M, Ignaciuk A. The minimally invasive rhinoplasty with hyaluronic acid and botulinum toxin in a 49-year old woman. *Otolaryngol Pol*. 2010;64(5):324-327.
56. Bennett HS, Reilly PG. Restylane—a temporary alternative for saddle nose deformity in nasal Wegener's granulomatosis—how we do it. *Br J Oral Maxillofac Surg*. 2011;49(4):e3-e5.
57. Modrzynski M. Hyaluronic acid gel in the treatment of empty nose syndrome. *Am J Rhinol Allergy*. 2011;25(2):103-106.
58. Shoshani O, Ullmann Y, Shupak A, et al. The role of frozen storage in preserving adipose tissue obtained by suction-assisted lipectomy for repeated fat injection procedures. *Dermatol Surg*. 2001;27(7):645-647.
59. Lidagoster MI, Cinelli PB, Leveé EM, Sian CS. Comparison of autologous fat transfer in fresh, refrigerated, and frozen specimens: an animal model. *Ann Plast Surg*. 2000;44(5):512-515.
60. MacRae JW, Tholpady SS, Ogle RC, Morgan RF. Ex vivo fat graft preservation: effects and implications of cryopreservation. *Ann Plast Surg*. 2004;52:281-283.
61. Atik B, Oztürk G, Erdo an E, Tan O. Comparison of techniques for long-term storage of fat grafts: an experimental study. *Plast Reconstr Surg*. 2006;118(7):1533-1537.
62. Moscatello DK, Dougherty M, Narins RS, Lawrence N. Cryopreservation of human fat for soft tissue augmentation: viability requires use of cryoprotectant and controlled freezing and storage. *Dermatol Surg*. 2005;31(11, pt 2):1506-1510.
63. Pu LL. Comparison of techniques for long-term storage of fat grafts. *Plast Reconstr Surg*. 2007;120(3):813.
64. Pu LL, Cui X, Li J, Fink BF, Cibull ML, Gao D. The fate of cryopreserved adipose aspirates after in vivo transplantation. *Aesthetic Surg J*. 2006;26(6):653-661.
65. Cui XD, Gao DY, Fink BF, Vasconez HC, Pu LL. Cryopreservation of human adipose tissues. *Cryobiology*. 2007;55(3):269-278.
66. Pu LL. Cryopreservation of adipose tissue. *Organogenesis*. 2009;5(3):138-142.
67. Lee JE, Kim I, Kim M. Adipogenic differentiation of human adipose tissue-derived stem cells obtained from cryopreserved adipose aspirates. *Dermatol Surg*. 2010;36(7):1078-1083.
68. Cui X, Pu LL. The search for a useful method for the optimal cryopreservation of adipose aspirates: part II. In vivo study. *Aesthetic Surg J*. 2010;30(3):451-456.
69. Pu LL, Coleman SR, Cui X, Ferguson RE Jr, Vasconez HC. Cryopreservation of autologous fat grafts harvested with the Coleman technique. *Ann Plast Surg*. 2010;64(3):333-337.