



Operative Strategies

The MACS-lift Short Scar Rhytidectomy

Patrick Tonnard, MD; and Alexis Verpaele, MD

The authors are Assistant Clinical Professors, Department of Plastic Surgery, Gent University, Gent, Belgium.

The minimal access cranial suspension (MACS) lift, a short scar face lift for the lower and middle third of the face, uses a pure vertical vector, involves no lateral tension, and may be performed with the patient under local anesthesia in 2 to 2.5 hours. According to the authors, the procedure reduces recovery time and morbidity, and results are as stable as more classic, extended face lift techniques. (*Aesthetic Surg J* 2007;27:188–198)

Encouraged by the results of other less invasive face lift techniques,¹ we have performed the minimal access cranial suspension (MACS)-lift as our primary surgical facial rejuvenation procedure during the last 7 years. The MACS-lift is a short scar face lift elevating the deep tissues and skin and using a vertical vector only. The MACS-lift suspends sagging facial soft tissues with permanent or slowly resorbable purse-string sutures that are strongly anchored to the deep temporal fascia through a preauricular and temporal prehairline incision. We describe 2 variations of the procedure: (1) the simple MACS-lift (S-MACS) in which we place 2 purse-string sutures to correct the neck and the lower third of the face (cervicomental angle, jowls, and marionette grooves); and (2) the extended MACS-lift (X-MACS), in which we place a supplementary (third) purse string suture to suspend the malar fat pad. This suture will have an extra effect on the nasolabial groove, the midface, and the lower eyelid.²⁻⁷

Preoperative Marking

With the patient sitting, ask the patient to flex the neck to demonstrate a double chin. Mark this area (which will be suctioned), including the lower part of the jowls. When performing an extended MACS-lift, mark a point \pm 2 cm below the lateral canthus, which will be included in the skin undermining.

Preoperative Sedation

Before prepping and draping the patient, inject 2.5 to 5 mg of midazolam intramuscularly. The dosage is based on the patient's body weight and degree of anxiety.

Infiltration

The sequence of infiltration corresponds with the sequence of the procedure as follows: first, the upper eyelids (if treated); followed by the submental area; followed by the cheek (Table). For the submental lipoplasty, infiltrate an average of 30- to 40-cc in the preplatysmal fat until the patient reaches a moderate degree of tumescence is reached.

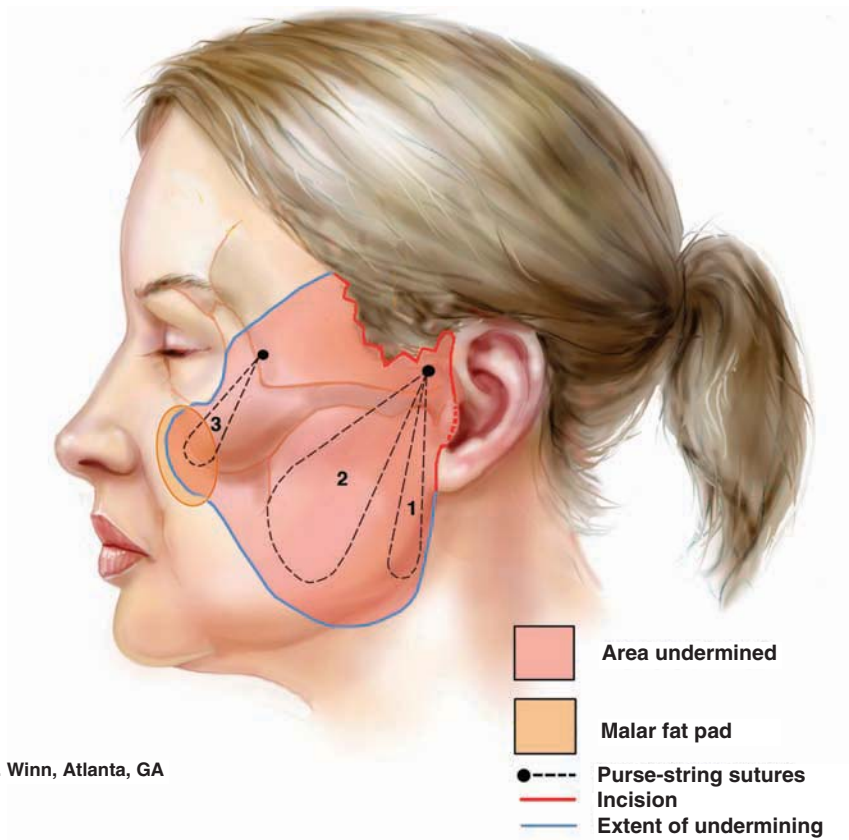
Intraoperative Marking: Incision

Start marking at the lower limit of the lobule, extending up into the preauricular crease (Figure 1, red line). At the level of the incisura intertragica, angle the marking 90 degrees backward to preserve the integrity of this anatomical landmark.^{8,9} Continue marking, following the posterior edge of the tragus and ascending toward the helical root. At the superior limit of the ear, the marking follows the small hairless recess between the sideburn and the auricle and then turns downward to follow the inferior hairline of the sideburn. In men, the marking descends approximately 1.5 cm before turning anteriorly to cross the sideburn.

Continue the marking forward in a zigzag pattern 2 mm within the lower and anterior hairline of the sideburn. In this part of the incision, incline the knife at an angle almost tangential with the skin to cut hair shafts perpendicularly (Figure 2). This maneuver will allow hair to grow through the scar.⁹ After hair regrowth, the final scar will be hidden a few millimeters within the hairline

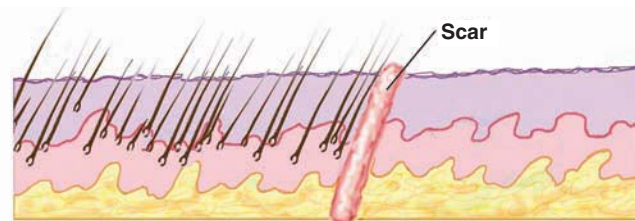
Table. Anesthetic solution for MACS-lift

100 mL NaCl 0.9%
20 mL lidocaine 2%
10 mL ropivacaine 10 mg/mL
2 mL sodium bicarbonate 8.4%
0.2 mL epinephrine 1 mg/mL
10 mg triamcinolone

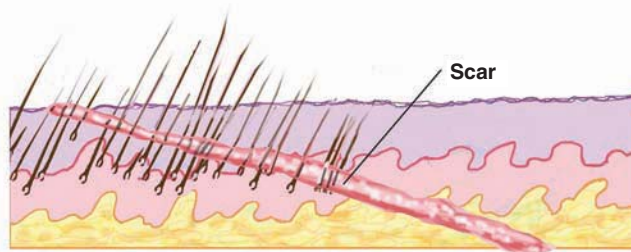


Illustrations by William M. Winn, Atlanta, GA

Figure 1. Schematic representation of the incision, area of undermining, anchor points, and placement of the first, second, and third purse-string sutures. In the case of a simple MACS-lift, only the first and second sutures are placed, originating from the same anchor point 1 cm above the zygomatic arch and 1 cm in front of the helical rim. The incision will then be a little shorter and extend up to the level of the lateral canthus.



A. Straight Incision at natural hairline leaves scar



B. Hair grows through beveled scar, minimizing wound site

Figure 2. Comparison of temporal hairline incisions parallel and perpendicular to the hair shafts (in the manner of Camirand). **A.** An incision parallel to the hair shafts will produce a scar at the border of the temporal hairline. **B.** An incision perpendicular to the hair shafts will produce hair regrowth through the scar into the cheek flap. The final scar will be hidden a few millimeters within the hair-bearing temporal skin and will be less visible than in Part A.

and become virtually invisible. The purpose of the zigzag pattern is to increase the length of the temporal incision for better fit with the length of the cheek flap, thereby reducing dog ear formation. In the simple MACS-lift the incision will extend to the level of the lateral canthus. In an extended MACS-lift the incision extends to the level of the tail of the eyebrow.

Intraoperative Marking: Undermining

Palpate the mandibular angle with your index finger, and mark this as the lowest point of the undermining (Figure 1, *blue line*). Mark the extent of the undermining, starting from the lowest point of the incision at the lobule directed toward the marking of the mandibular angle and then curving anteriorly to 5 to 6 cm in front of the ear. With an extended MACS-lift, include the undermining of the malar eminence in the demarcation.

Lipoplasty

We prefer to use a 3-mm spatula cannula with one opening. To avoid dermal damage, never direct the opening toward the skin. It is optimal to make 2 or 3 stab incisions to crisscross the marked area. Perform the lipoplasty in a preplatysmal plane, using tactile guidance with the nondominant hand. Perform a maximal lipectomy so that at the end of the procedure the cannula is visible just beneath the skin.

Flap Elevation

Undermine the skin (blindly) with face lift scissors in the subcutaneous plane. Direct the points of the scissors toward the skin to provide visual and palpable control over the thickness of the cheek flap. Perform most of the scissor dissection with spreading maneuvers. Be careful to elevate a flap of sufficient thickness to mask small irregularities of the underlying layer.

Anchor Points

The sagging facial tissues will be suspended by sutures that are woven like a purse string into the SMAS tissue, which is not undermined. The anchor points for these sutures are within the deep temporal fascia above the zygomatic arch in a safe zone out of the path of the frontal branch of the facial nerve (Figure 3).

First Purse-string Suture: The Vertical Loop

Using iris scissors, create a window of 0.5 cm diameter in the subcutaneous tissue 1 cm above the zygomatic arch and 1 cm in front of the helical rim to expose the deep temporal fascia (Figure 1, *dotted black line*). Use a

1-0 PDS suture on a large, round CT-3 needle. Begin the first *bite* where you visualize the deep temporal fascia, and extend down to the temporal bone. Orient the needle toward the tragus to avoid damaging a facial nerve branch. Take firm bites 1 to 1.5 cm long and 0.5 cm deep in the SMAS tissue, which consists of parotid fascia in the upper two thirds and platysma in the lower one third. It is essential to confirm that every bite of the needle takes a substantial part of SMAS tissue, so that the suture will not pull through. Extend the suturing down to the lower limit of the undermining. There, take 2 or 3 solid bites in the cranial edge of the platysma muscle (Figure 4). Then, turn the suturing upward and continue back to the starting point. This creates a narrow U-shaped purse-string loop with a width of about 1 cm. Tie the knot under maximal tension.

Second Purse-string Suture: The Oblique Loop

The second purse-string suture originates from the same location on the deep temporal fascia, forming a wider loop directed towards the jowl area at an angle of ± 30 degrees (with the vertical) (Figure 1, *dotted black line*). This loop is more O-shaped (compared with the U-shaped vertical loop) to prevent linear traction on the subcutaneous tissue, which could be visible through the skin.

The loop follows the borders of the anterior undermining in the lower part of the cheek. Take short bites (maximum of 1 cm) in the parotid fascia and the SMAS tissue. Tie the knot under maximal tension.

The Third Purse-string Suture: The Malar Loop

The third suture has a separate anchor point on the deep temporal fascia, just lateral to the lateral orbital rim in front of the path of the frontal branch of the facial nerve (Figure 1, *dotted black line*). Here, make a window in the orbicularis muscle down to the deep temporal fascia. Then, take a deep bite, anchoring the suture to the deep temporal fascia. Orient the purse-string suture obliquely downward and medially toward the malar fat pad, which is recognizable because it has a more fibrous consistency than the surrounding subcutaneous fat. At the point marked before surgery, 2 cm below the lateral canthus, reverse the direction of the suturing upward and lateral. The loop has a narrow U-shape and ends at its starting anchor point. Tie the knot under maximal tension.

After placing the purse-string sutures, close the windows in the SMAS and in the orbicularis muscle with 4-0 Vicryl to prevent knot palpability. It may be necessary to

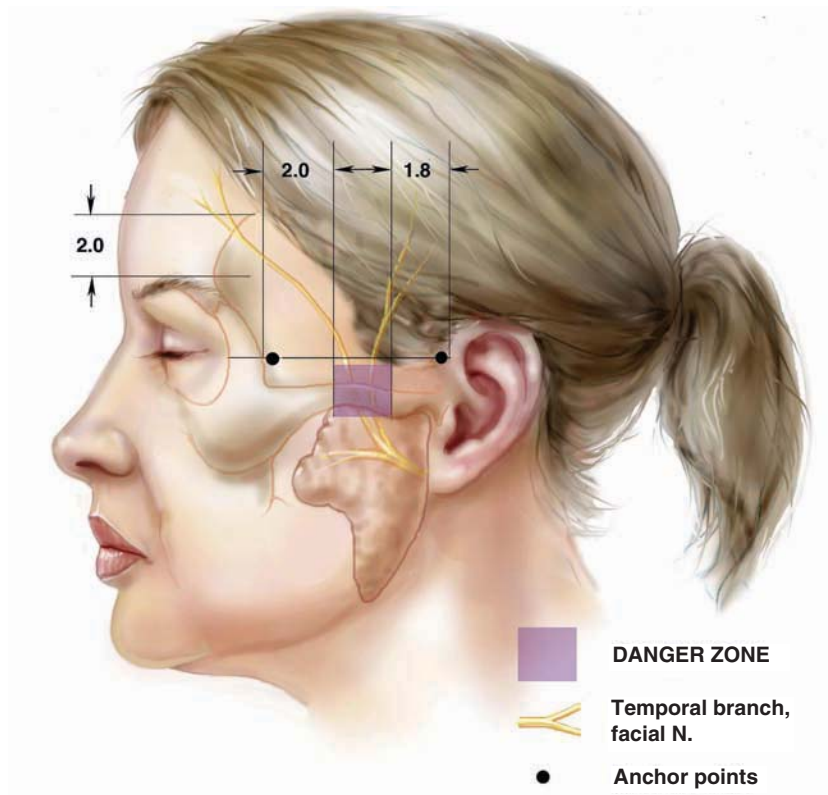


Figure 3. The anchor points are located in a safe location in relation to the frontal branch of the facial nerve.

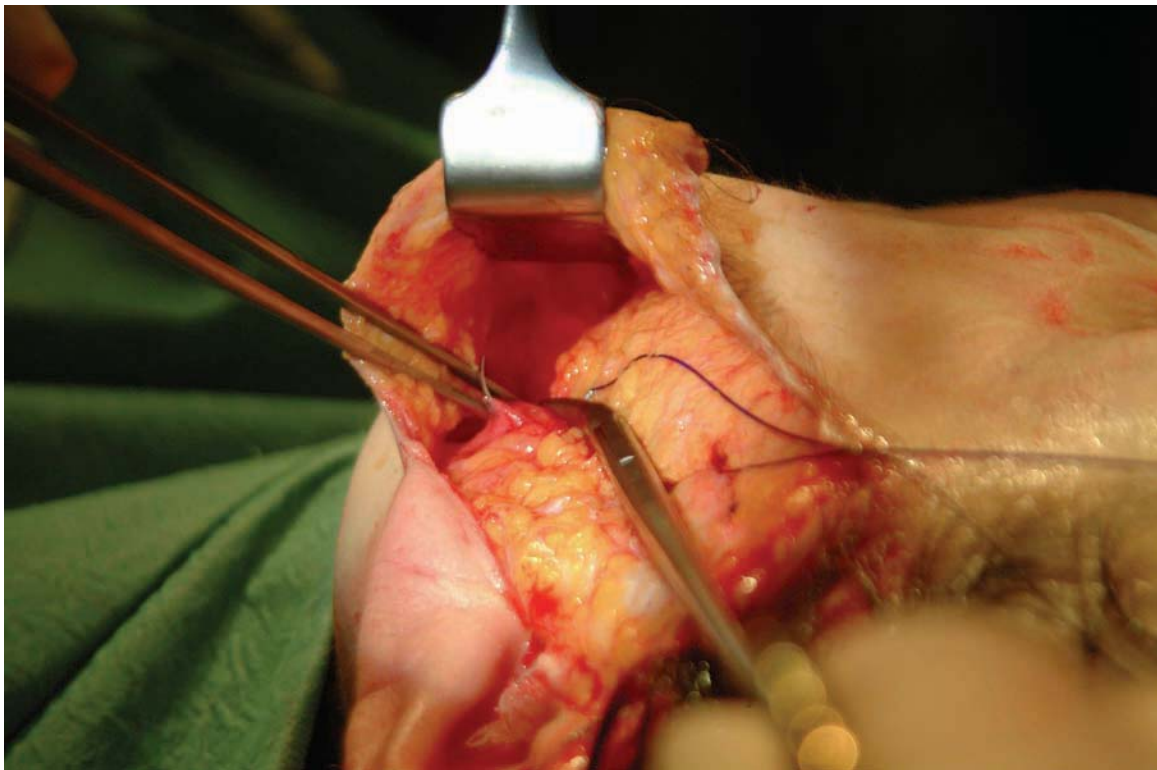


Figure 4. The platysma muscle must be visualized at the lower border of the cheek flap undermining, and 2 to 3 firm bites are taken in the muscle by the first purse-string suture.

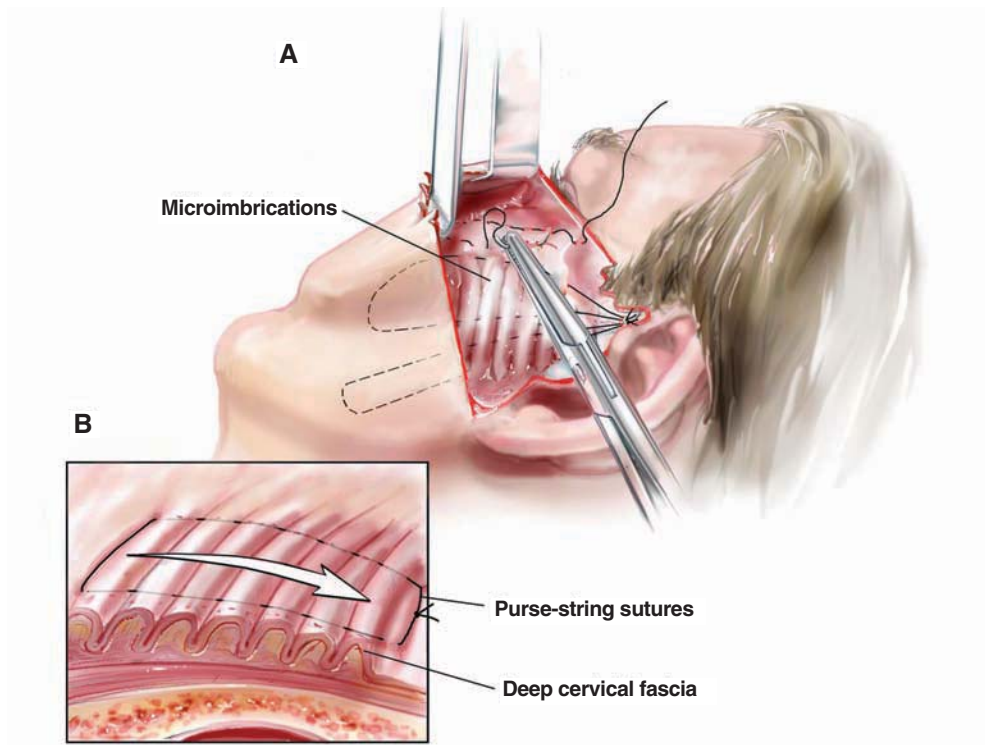


Figure 5. A, The third suture is placed between the anchor point, just lateral to the lateral orbital rim at the level of the lateral canthus, and a point 2 cm below the lateral canthus, marked on the skin preoperatively. **B,** Purse string sutures do not act like cable sutures from one point to another, but rather like a subcutaneous sculpturing technique created by multiple microimbrications.

free some skin dimples with scissors at the borders of the skin undermining.

The purse-string sutures are not like cable sutures from one point to another. Instead, they produce facial sculpturing by multiple microimbrications (Figure 5).

Skin Redraping and Resection

One of the most important features of this short scar face lift is vertical skin redraping. Since the vector of the SMAS suspension is almost purely vertical, redraping and resection of the skin in the same direction will seal the underlying subcutaneous sculpting effect.

In classical face lifting there is always a horizontal component of skin redraping. This causes a skin excess in the earlobe region, necessitating a retroauricular incision for skin redraping (Figures 6 and 7).

Carry out the skin resection on the cheek flap in a curvilinear fashion and suture it to the zigzag border of the temporal hairline incision. The zigzag incision will now open up when coapting with the linear cheek flap, thereby compensating for the incongruence in length of both borders and also reducing possible dog ears. Set back the pulled up earlobe into the cheek flap (Figure 8).

Begin closure with interrupted 4-0 Vicryl buried sutures from the superior end of the incision downward. Suture the horizontal limb of the incision with a running 5-0 nylon horizontal mattress suture, taking bigger bites on the cheek flap side than on the temporal side to compensate for the final incongruence in length between both sides.

Perform the rest of the suturing with running and interrupted 6-0 nylon sutures (Figure 9). Insert a small hollow silicone drainage tube at the lowest point of the incision to drain into the loose retroauricular dressing during the first 24 hours; the drain is removed with the dressings at 24 hours.

The Pinch Lower Blepharoplasty

After performing an extended MACS-lift, suspend the malar mound vertically upwards; this will result in skin excess in the lower eyelid region. Estimate the skin excess by performing a pinching maneuver with forceps, and mark it with methylene blue. Perform the pinch blepharoplasty via a classical lower blepharoplasty incision. Free the skin from the orbicularis, vertically redrape it without any tension, and resect it. Close the skin with a running 5-0 nylon intradermal suture (Figures 10-12).

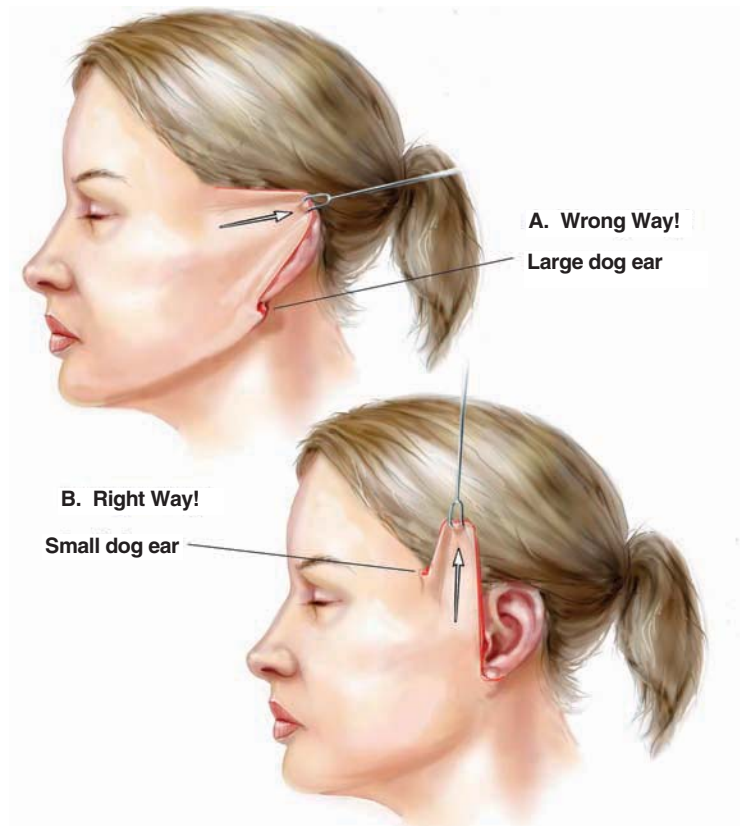


Figure 6. **A,** A lateral redraping of the skin will produce tension and flattening of the face, and a dog ear will be created below the earlobe. To correct this, a retroauricular dissection will have to be performed. If we want to avoid a retroauricular scar this lateral skin redraping should not be done. **B,** In short scar face lifting, the correct vector of skin redraping is vertical. There will be no dog ear around the earlobe, and a small dog ear at the superior edge of the incision can be corrected by extending the incision for 1 cm.

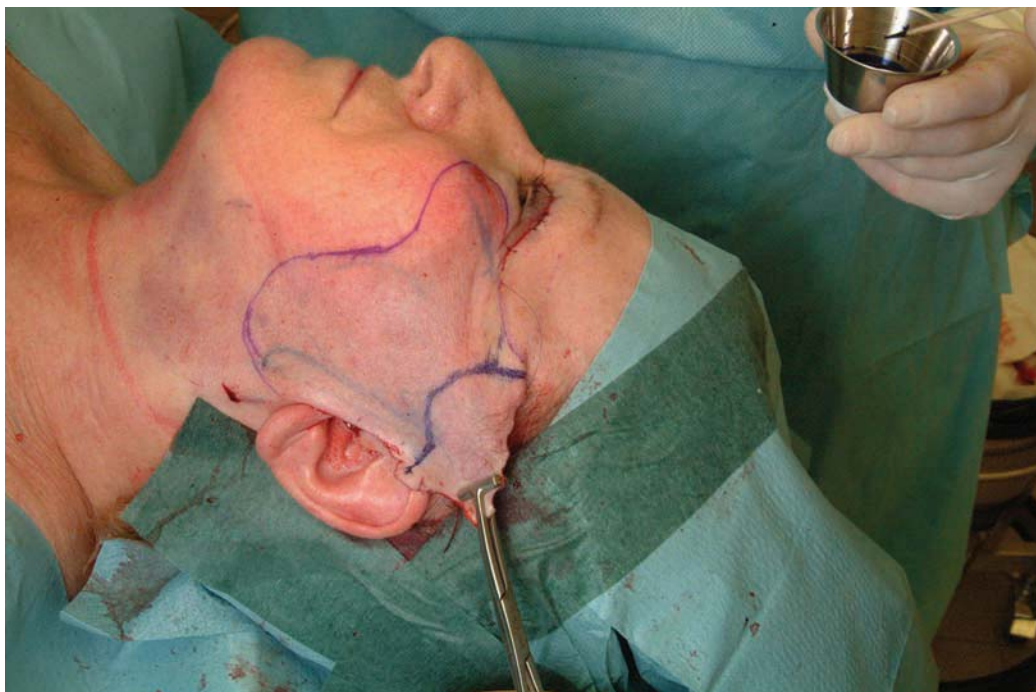

Figure 7. Vertical redraping of the skin flap will produce a skin excess in the temporal region. There will be minimal skin resection in the preauricular region. The earlobe will be pulled upward and has to be set back by a small skin excision.

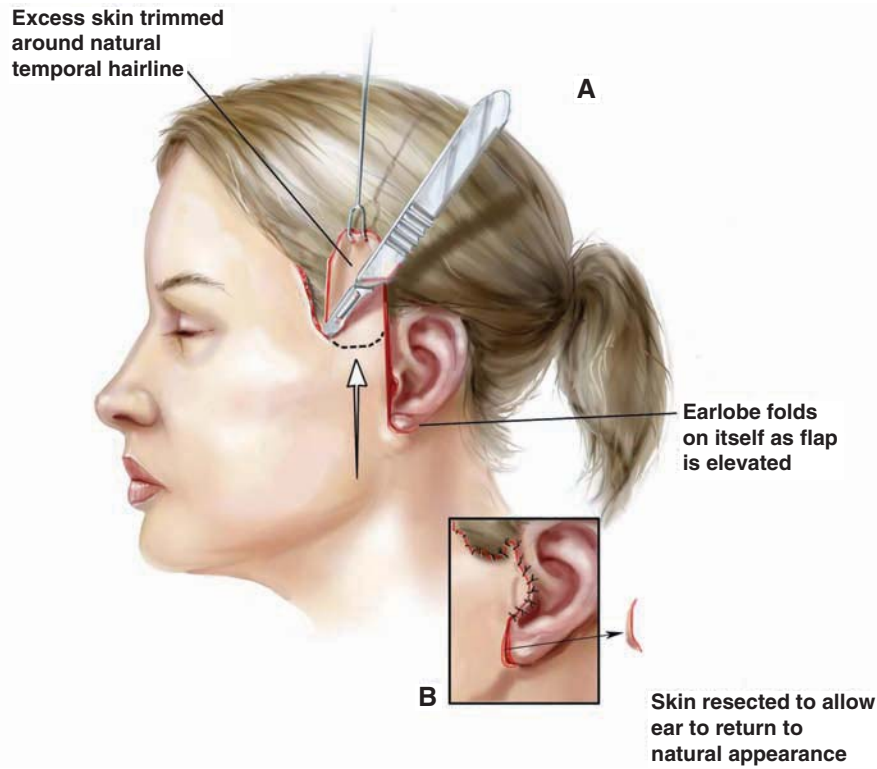


Figure 8. A, After vertical redraping of the skin, the excess skin is resected without any traction at the level of the temporal hairline. The excision is beveled to coapt with the beveled hairline incision. The temporal hairline incision is mandatory in any vertical face lift technique to avoid unnatural raising of the sideburns. There is virtually no skin resection in the preauricular region. **B,** After vertical redraping of the skin flap, the earlobe will be folded upward, and a small skin excision is made to place the earlobe back in its natural position.

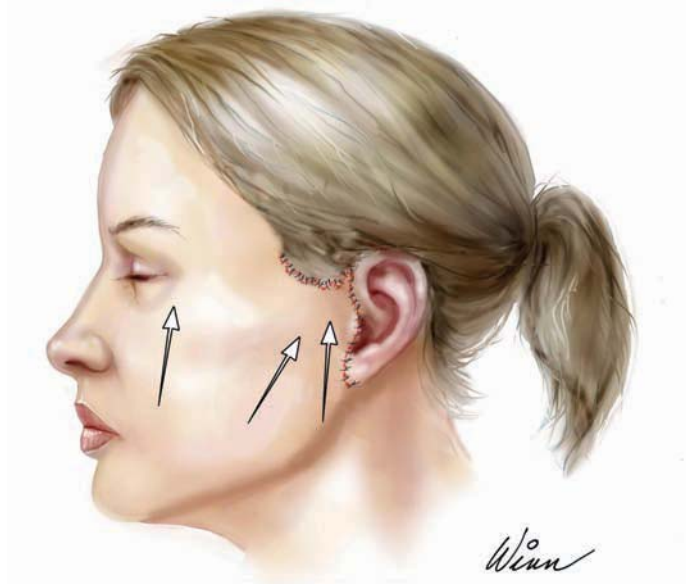


Figure 9. Final results of vectors of action of the 3 purse-string sutures. Together with the vertical redraping and resection of the skin, the result is a pure vertical vector face lift.



Figure 10. A, C, E, G, I, K, Preoperative views of a 56-year-old woman with platysmal bands in a lax submental and upper neck region, jowls, marionette lines, downward slanting corners of the mouth, upper lip rhytids, marked nasolabial folds, and emptiness of the midface with hollow lower eyelids. She has hollow empty upper eyelids and a correct position of the eyebrows. Note the inframalar hollow in E. **B, D, F, H, J, L,** Postoperative views 1 year after an extended MACS-lift, upper lip erbium resurfacing, and lower eyelid pinch blepharoplasty performed with the patient under local anesthesia with intramuscular midazolam sedation (2.5 mg) for an operation lasting 2 hours and 10 minutes. The patient was discharged 2 hours after surgery. Results show correction of the neck and submental laxity, including the platysmal bands; restoration of the cervicomental angle; redefinition of the mandibular border; correction of the jowls, marionette grooves, and downward slanting corners of the mouth; correction of perioral rhytids; fading of the nasolabial fold; replenishment of the midface and lower eyelids with augmentation of the zygomatic area, producing a youthful curvature on the three-quarter view. **H,** The so-called Bruce-Connell view, not only shows correction and stability of the cervicomental angle, but also the rejuvenating effect on the lower and middle third of the face.

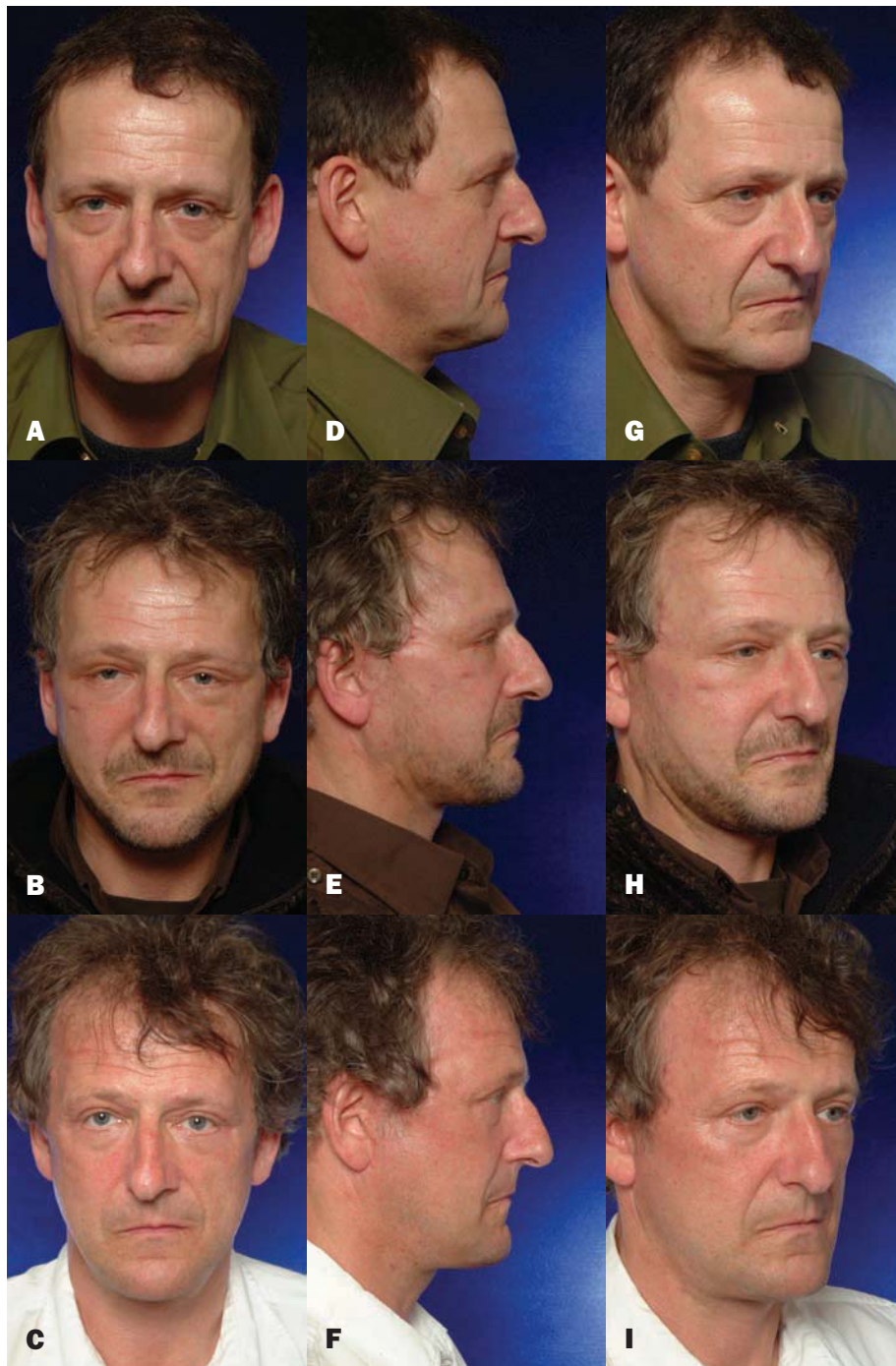


Figure 11. **A, D, G,** Preoperative views of a 49-year-old man who complained that he looked older. Five years ago, he underwent an upper blepharoplasty. He has heavy, thick skin and facial sagging. He has some fatty infiltration of the submental region and ptotic jowls, deep nasolabial grooves, with a heavy overhanging fold. His midface is descended, and there is a distinct crease between the cheek and the lower eyelid, which is bulging from the lower cilia toward the infraorbital crease. The upper eyelids are hollow, and the eyebrow is heavy and low. The tail of the eyebrow is drooping, causing a lateral hooding deformity with 2 to 3 deep horizontal creases in the paracanthal area. He shows deep horizontal wrinkles in the frontal area. **B, E, H,** Postoperative views 2 weeks after submental lipoplasty, extended MACS-lift, pinch lower blepharoplasty with transconjunctival resection of fat from the 3 compartments, and short scar temporal lift by galeopexy. This procedure was performed with the patient under local anesthesia with intramuscular midazolam sedation (4.5 mg) and took 2 hours and 40 minutes. Patient was discharged 2 hours after surgery. **C, F, I,** Postoperative results 9 months after surgery. The patient shows an adequate correction of the cervicomental angle, a better definition of the mandibular border with correction of the jowls, and a suspension of the submandibular gland by cranial suspension of the platysma. The nasolabial groove has faded, and the midface shows a natural replenishment with almost complete eradication of the crease at the eyelid-cheek junction. The malar volume is in a higher position, giving a youthful malar augmentation effect, which can best be appreciated in the three-quarter view. **F,** Beard and sideburns are still in an anatomic position in front of the ear, and there is no hair growth on the tragus as is often seen after lateral traction on the cheek flap.

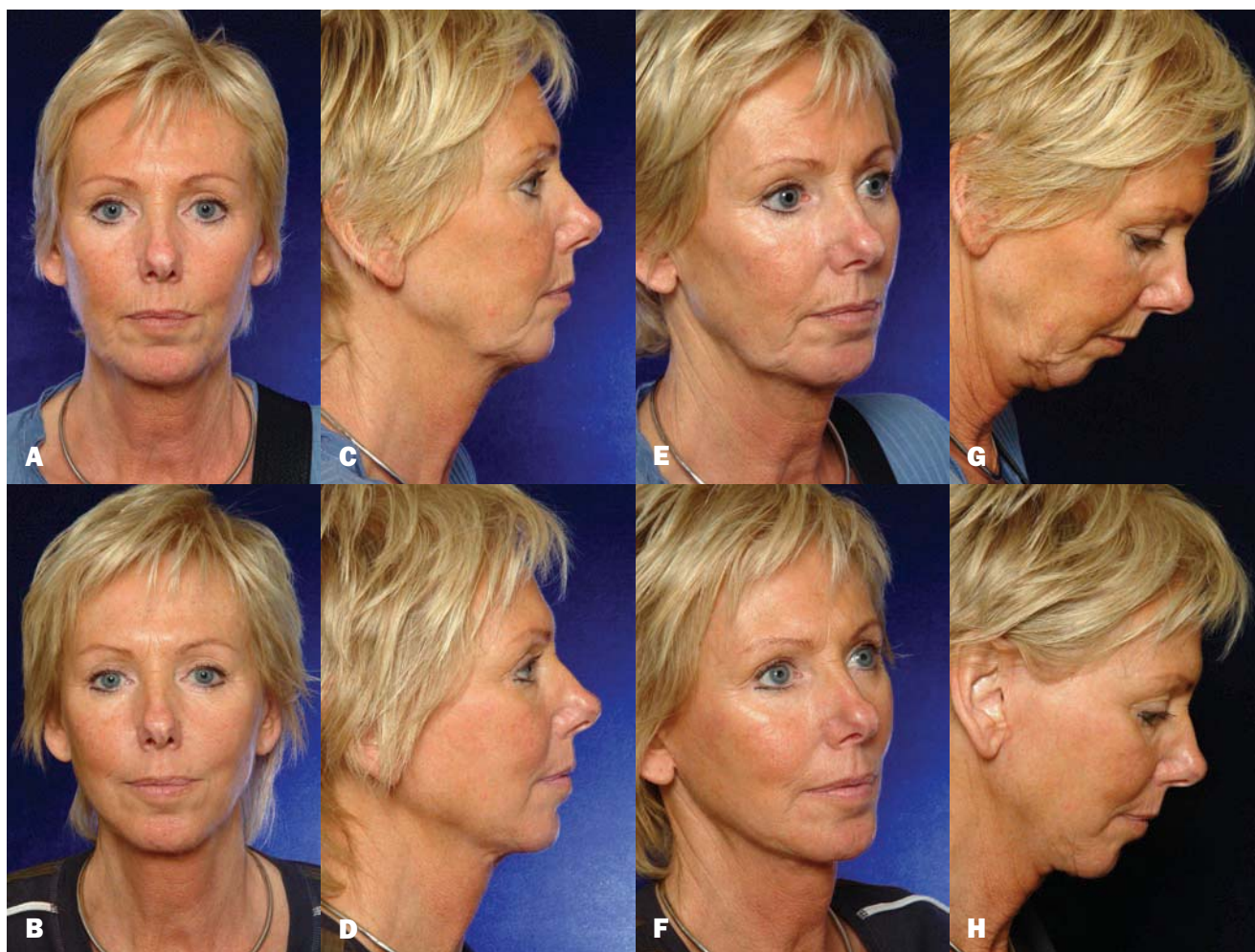

Figure 12. A, C, E, G, Preoperative views of a 52-year-old woman who had an upper blepharoplasty 5 years ago. Note moderate upper neck and submental laxity, a small platysmal band on the left, jowls, marionette grooves, upper lip rhytids, and fine rhytids in the lower eyelid. She maintains a youthful midface. **B, D, F, H,** Postoperative views 1 year after a simple MACS-lift, submental liposculpture, erbium laser resurfacing of the upper lip and corners of the mouth, and a lower eyelid pinch blepharoplasty. The procedure, lasting almost 2 hours, was performed with the patient under local anesthesia with intramuscular midazolam relaxation (2.5 mg). The patient was discharged 2 hours after surgery. Rejuvenating effects in the lower third of the face include correction of submental and upper neck laxity, platysmal band, jowls, and marionette lines with better definition of the mandibular line and eradication of perioral rhytids. A lower eyelid pinch blepharoplasty was added, which is seldom done in a simple MACS-lift. At the end of the procedure, when extra skin gathers in the lower eyelid because of the vertical lift, the skin can safely be removed. Here, 4 mm of skin was removed, especially in the paracanthal region.

Conclusion

The MACS-lift is a simple and safe short scar facial rejuvenation procedure for the lower and middle third of the face, providing natural results with minimal face lift stigmata due to the pure vertical vector and the absence of any lateral tension (Figure 8). It may be performed with the patient under local anesthesia and typically requires 2 to 2.5 hours of operating time. It can be combined with other minimally invasive rejuvenation techniques such as temporal lifts, laser resurfacing, microfat grafting, etc. Compared with more aggressive face lift techniques, the MACS-lift demonstrates reduced recov-

ery time and morbidity. Based on our experience, the results seem to be as stable as the more classic, traditional extended face lift techniques. ■

References

1. Baker DC. Minimal incision rhytidectomy (short scar face lift) with lateral SMASeconomy: evolution and application. *Aesthetic Surg J* 2001;21:14-25.
2. Tonnard PL, Verpaele A. The MACS-lift short scar rhytidectomy. St Louis: Quality Medical Publishing; 2004.
3. Tonnard PL, Verpaele A, Monstrey S, Van Landuyt K, Blondeel P, Hamdi M. Minimal access cranial suspension lift: a modified S-lift. *Plast Reconstr Surg* 2002;109:2074-2086.

4. Tonnard PL, Verpaele A, et al. 300 MACS-lift short scar rhytidectomies: analysis of results and complications. *Eur J Plast Surg* 2005;28:198-205.
5. Tonnard PL, Verpaele A, Gaia S. Optimizing results from minimal access cranial suspension lifting (MACS-lift). *Aesthetic Plast Surg* 2005;29:213-220.
6. Tonnard PL, Nahai F, Massiha H, Baker D. Short scar face lift. *Aesthetic Surg J* 2005;25:607-617.
7. Verpaele A, Tonnard PL, Pirayesh A, Guerao FP, Gaja S. The third suture in MACS-lifting: making midface lifting simple and safe, *J Pras* (In press).
8. Tonnard PL, Verpaele AM. Short scar face lift. Operative strategies and techniques. St. Louis: Quality Medical Publishing, Inc., 2001.
9. Camirand A, Doucet J. A comparison between parallel hairline incisions and perpendicular incisions when performing a face lift. *Plast Reconstr Surg* 1997;99:10-15.
10. Connell BF, Semlacher RA. Contemporary deep layer facial rejuvenation. *Plast Reconstr Surg* 1997;100:1513-1523.

Reprint requests: Patrick Tonnard, MD, Coupure Centrum voor Plastische Chirurgie, Coupure Rechts 164 C-D, B-9000 Gen, Belgium.

Copyright © 2007 by The American Society for Aesthetic Plastic Surgery, Inc.

1090-820X/\$32.00

doi:10.1016.j.asj.2007.01.008