

Deep Layer Radiofrequency Thermo-coagulative Technology for Cervicofacial Contouring: Sonographic and Clinical Results

Sarit Cohen, MD*†
Omri Dominsky, MD*†
Ofir Artzi, MD†‡
Erez Dayan, MD§
Joseph Eckstein, MD¶

Background: Radiofrequency energy thermally induces collagen contraction and remodeling. The resultant dermal tightening is well established. However, facial aging encompasses also deeper layers of collagen-containing tissues. We present a deep layer radiofrequency-based thermo-coagulative technique for cervicofacial contouring and evaluate its efficacy.

Methods: This prospective single center study was conducted from June 2017 to June 2018 and included 10 women. Echogenicity and thickness of layers 1–5 of the lower face, lateral neck, and submental regions were sonographically measured at baseline and at 6 weeks postoperatively. Echogenicity analysis was based on the number of high echogenic pixels counted and processed using Matlab-based image application (The Mathworks, Natick, Mass.). Clinical outcome at 12 months post-operatively was evaluated by 2 independent evaluators using a validated 5-point lower face improvement scale and the Merz jawline scale (0–4). Patient satisfaction and adverse effects were recorded.

Results: Mean age was 60.2 years (range, 52–76). A statistically significant increase in echogenicity ($P \leq 0.02$) and a decrease in thickness ($P = 0.01$) was noted. Echogenicity increased at 149%, 78%, and 60%, for the lateral neck, lower face, and submental region, respectively. The corresponding decrease in thickness per site was 16%, 6%, and 19%. The average physicians' improvement in lower face contour was 3.8, and the Merz jawline scale was improved from 2.85 at baseline to 1.05 at 12 months postoperatively. Patient satisfaction was high. Side effects were minimal.

Conclusions: Deep layer radiofrequency-based technology thermally induces profound soft tissue tightening and neocollagenesis. It is a safe and effective technique for cervicofacial contouring in selected patients. (*Plast Reconstr Surg Glob Open* 2020;8:e3286; doi: 10.1097/GOX.0000000000003286; Published online 18 December 2020.)

INTRODUCTION

Lower face and cervical aging refers to complex additive and subtractive changes that occur throughout all facial layers.¹ Skin redundancy and laxity, subcutaneous lipodystrophy coupled with attenuation of the retaining

ligaments and the intervening fibrous septa ultimately give rise to lower face and neck aging stigmata.

Energy-based nonsurgical modalities for skin tightening include lasers, focused ultrasound, and radiofrequency. Radiofrequency (RF) has become the increasingly more popular modality to date. It thermally induces collagen contraction and its subsequent remodeling.² The resultant dermal tightening has been substantiated histologically and clinically by many researchers.^{2–5} Other facial layers deeper to the dermis, including the fibrous septa that compartmentalize the subcutaneous fat (layer 2),⁶ the superficial muscular aponeurotic system (SMAS) (layer 3)^{7,8} and the retaining ligaments (layer 4), also contain collagen.^{1,9}

Recently, the new generation of minimally-invasive, temperature controlled, bipolar RF-based technology was approved by the FDA for electrocoagulation and hemostasis. Literature review reveals only 2 case series

From the *Department of Plastic and Reconstructive Surgery, Assaf Harofeh Medical Center, Zerifin, Israel; †Sackler Faculty of Medicine, Tel Aviv University, Tel Aviv, Israel; ‡Department of Dermatology, Sourasky Tel Aviv Medical Center, Tel Aviv, Israel; §Advanced Plastic Surgery Institute, Reno/Tahoe, Nev.; and ¶Diagnostic Radiology Unit, Rabin Medical Center – Beilinson Hospital, Petach Tikva, Israel.

Received for publication July 29, 2019; accepted October 2, 2020.

Copyright © 2020 The Authors. Published by Wolters Kluwer Health, Inc. on behalf of The American Society of Plastic Surgeons. This is an open-access article distributed under the terms of the [Creative Commons Attribution-Non Commercial-No Derivatives License 4.0 \(CCBY-NC-ND\)](#), where it is permissible to download and share the work provided it is properly cited. The work cannot be changed in any way or used commercially without permission from the journal.

DOI: 10.1097/GOX.0000000000003286

Disclosure: The authors have no conflicts of interest to declare. No funding was procured for this work.

of cervicofacial contouring using RF thermocoagulation (RFTC).^{10,11} The esthetic outcome in these studies was based on a patient satisfaction survey with little objective data. One study also included photographic evaluation by independent physicians.¹¹ The aim of the present pilot study was to present a deep layer radiofrequency thermo-coagulative energy employment technique and to objectively evaluate its efficacy both quantitatively and qualitatively.

MATERIALS AND METHODS

Study Design

This prospective, 1-arm cohort study was performed in a single medical center, from June 2017 to June 2018. The study was approved by the institutional review board of Assaf Harofeh Medical Center and was conducted in accordance with the ethical principles laid down in the Declaration of Helsinki.

Patients and Settings

Ten healthy women (including smokers) seeking for lower face and neck contouring were recruited to this study. Written informed consent was obtained from all participants. Inclusion criteria were patients with mild-to-moderate sagging, submental fat, and mild-to-moderate jowling (Baker's classification type 1 and 2).¹² According to this classification, type 1 patients have slight cervical skin laxity with submental fat and early jowls, whereas type 2 patients have moderate cervical skin laxity, moderate jowls, and submental fat.

Subjects were excluded from the study if they had a pacemaker or internal defibrillator, or any other active electrical implant anywhere in the body, superficial permanent implant in the treatment area, or had undergone cosmetic procedures in the face and neck in the previous 6 months. Also excluded were those who had scars or infections in the target area, significant facial asymmetry, were receiving anticoagulant or immunosuppressive treatment, had autoimmune diseases, a history of massive weight loss, or those who were pregnant or breastfeeding. Patients with unrealistic expectations were excluded as well.

Each patient had 1 treatment session. Ultrasound examination of the lower face and neck were performed before and at 6 weeks postoperatively. Standardized photographs were taken before and at 12 months postoperatively. Follow-up visits were scheduled at 2, 6 weeks and at 12 months postoperatively.

The Device

The RFTC device is a bipolar, temperature-controlled, radiofrequency-technology consisting of a hand piece powered by the InMode platform. The hand piece consists of an internal solid rod electrode (cannula) of 10-cm long and 1.3-mm diameter and an external electrode, connected by a hand grip. The internal electrode is a bullet-shaped plastic dissector, coated at its tip to prevent accidental overheating. The external electrode has a relatively large diameter aimed to disperse energy near the skin's

surface and prevent overheating. RF density is higher around the smaller internal electrode and the RF energy is transmitted in a gradient, tear-drop pattern from the tip of the internal cannula to the external electrode. Internal RF energy delivery thermally coagulates the intervening collagenous, vascular, and adipose tissue and liquefies fat. External RF delivery thermally induces non-coagulative dermal collagen stimulation.

Both external and internal electrodes have embedded temperature sensors that monitor the respective temperatures. The internal electrode cut-off temperature range is 50–70°C and the external electrode cut-off temperature range is 35–43°C. When the predetermined cut-off temperature is reached, RF power is automatically switched off. Additional internally monitored safety measures include the rate of temperature rise, tissue impedance, and audible feedback. Rapid increase in temperature or too precipitous changes of impedance automatically “cuts off” RF power. Treatment depth is controlled by adjusting the distance between the 2 electrodes.

Preoperative Markings and Anesthesia

Preoperative marking included 5 treatment zones: a triangular zone above the mandibular border, bilaterally, and the neck itself divided into 3 triangular zones (2 lateral and 1 central). A line extending 0.5 cm above and below the mandibular border demarcates the facial and cervical treatment zones, respectively. The superior border of the treatment zone is marked by a line drawn from the ear lobe toward the lower 3rd of the nasolabial fold. The medial border above the mandible extends up to a vertical line descending from the lateral orbital rim. The inferior border extends up to the 2nd transverse neck crease (Fig. 1).

Modified Klein tumescent solution (50 ml of lidocaine 1%, 50 ml of 0.9% saline solution and 0.5 mg of epinephrine, 1:1000) is infiltrated using a 14-gauge infiltration cannula through 3 access incision ports: 2 infra-lobular and 1 submental (Fig. 1). Each treatment zone is infiltrated with 20 cm³ of tumescent solution to achieve sufficient turgor. Sterile ultrasound gel is applied to improve RF coupling and electrode gliding. Cut-off temperature settings are 39°C externally and 69°C internally.

Surgical Technique

The radiofrequency thermo-coagulative hand piece is introduced through the access incisions, employing bipolar, temperature-controlled radiofrequency-technology to the face and neck. The internal cannula is tunneled through the subcutaneous layer to the sub-SMAS plane, while the external electrode runs in tandem along the skin surface. RF energy is delivered at 20 watts in a retrograde linear threading fashion, until the predetermined internal cut off temperature is reached. Successive passes in a fanning manner ensure that all pre-marked treatment zone is encompassed. Electrical current flows from the cannula tip to the external electrode, creating confined controlled energy deposition and uniform heating. The internal cannula coagulates and liquefies subcutaneous fat and simultaneously contracts the deep layers of collagen-containing tissues. The amount of RF energy delivered for each zone is 1.5–2 KJ.

Postoperative Care

Patients were instructed to wear a facial strap daily for the first 3 days and to come for lymphatic massage at 1 week and 2 weeks postoperatively.

Outcome Measures

To objectively evaluate the efficacy of the RFTC technique, the thickness and echogenicity of layers 1–5 at 3 anatomic locations were sonographically measured and recorded at base-line and at 6 weeks postoperatively:

1. Lower face: The transducer (GE 12L-RS linear probe) was located along a vertical line, descending from the lateral orbital rim in front of the masseter muscle.
2. Lateral neck: Along the lateral border of the platysma, with the cranial portion of the probe placed one finger breadth below the angle of the mandible, corresponding to the location of the cervical retaining ligaments.¹³
3. Submental region: The transducer was located horizontally halfway between the menton and hyoid bone.

These anatomical landmarks (ie, lateral orbital rim, mandibular angle, menton and hyoid bone) were chosen as reference points to avoid potential measurement bias.

Ultrasonic image acquisition and measurements were conducted by a board-certified radiologist using a GE Voluson e ultrasound machine. The system offers 4D image quality, live dual (B/BC) mode, and automated functional imaging. All images were obtained from the same 3 anatomical locations. The thickness of facial layers 1–5 of each of the 3 locations was measured in centimeters before and at 6 weeks postoperatively.

The echogenicity of facial layers (1–5) was analyzed based on the number of pixels counted from the ultrasound images obtained and processed by image analysis, using the Matlab-based application (The Mathworks, Natick, Mass.). This validated method measures echogenicity on a numerical scale extending from 0 (non-echogenic) to 255 (maximal echogenicity).¹⁴ High echogenic pixels (HEPs), defined as 170–255, were recorded for each of the 3 locations before and at 6 weeks postoperatively. An increase in the number of HEPs correlates with an increase in echogenicity.

In terms of echogenicity, hyperechoic signals reflect the collagen fibers in facial tissues, whereas the hypoechoic ones originate from the extracellular matrix that lies between the collagen fibers and the subcutaneous

fat. Thus, post-operative increase in echogenicity in layers 1–5 reflects collagenesis induced by the RFTC device. Twelve sets of data were collected: pre- and post-operative thickness, and echogenicity along the above-mentioned 3 anatomic locations.

Clinical outcome/efficacy was evaluated by 2 independent physicians (a plastic surgeon and a dermatologist) who rated baseline and 12-months postoperative status using a validated 5-point assessment scale of the lower face¹⁵ and the Merz jawline scale.^{16,17} The validated 5-point assessment scale was rated as follows: 1—little or no improvement (0%–10%); 2—noticeable improvement (10%–25%); 3—fair improvement (25%–50%); 4—good improvement (50%–75%); and 5—excellent improvement (>75%). The Merz jawline scale was rated as follows: 0—No sagging; 1—mild sagging; 2—moderate sagging; 3—severe sagging; and 4—very severe sagging. Clinical outcome at 12 months was also evaluated by subjects on a scale of 1–4, with 1 being “not satisfied” and 4 being “very satisfied” with the outcome of the treatment. Patients’ tolerance was evaluated using a scale of 1–4, with 1 representing poor tolerance, and 4 representing excellent tolerance. Adverse effects were also documented at follow-up visits

Statistical Analysis

Pre- and post-treatment echogenicity and thickness were compared using the Wilcoxon paired test. The percent of change was calculated for each patient at each area as follows:

$$\text{Percent of change} = 100 \times \frac{\text{Post} - \text{Pre}}{\text{Pre}}$$

The average percent of change was presented per measure and location. Significance level was defined as $\alpha = 0.05$. Statistical analyses were performed with SPSS 25.0.

RESULTS

All patients completed the study. Mean age was 60.2 years (range, 52–76 years). Thickness and echogenicity measurements are depicted in Table 1.

Following RFTC, there was an increase in the HEPs counted in all sites. The percentage increase per site was 149% in the lateral neck region, 78% in the lower face area, and 60% in the submental region. The differences between pre- and post-treatment were statistically significant ($P = 0.01$ – 0.02). These significant increases in

Table 1. Echogenicity and Thickness Measurements of Layers 1–5

		Lateral Neck	Lower Face	Submental
Echogenicity(HEPs)	Pre	4.5 ± 1.7	5.6 ± 2.2	3.2 ± 1.4
	Post	10.6 ± 7.3	9.5 ± 5.7	5.0 ± 2.8
	Percent change	149.3% ± 178.7%	77.7% ± 91.7%	60.3% ± 68.3%
	<i>P</i>	0.01	0.02	0.01
Thickness (cm)	Pre	1.7 ± 0.2	1.4 ± 0.1	1.8 ± 0.2
	Post	1.5 ± 0.3	1.3 ± 0.1	1.5 ± 0.2
	Percent change	-16.2% ± 10.3%	-5.8% ± 3.5%	-18.7% ± 10.3%
	<i>P</i>	0.01	0.01	0.01

Table 2. Patient Characteristics and Treatment Outcomes in 10 Women Who Underwent Deep Layer RF Cervicofacial Contouring

Pt. no.	Initials	Age	Merz									Satisfaction	Tolerance	Adverse Effects
			Baseline			12 months after procedure			Improvement					
			P1	P2	Average	P1	P2	Average	P1	P2	Average			
1	HA	52	3	3	3	2	1	1.5	3	3	3	3	4	NA
2	HG	76	4	3	3.5	2	1	1.5	4	3	3.5	4	3	NA
3	MA	63	3	4	3.5	1	1	1	3	3	3	3	4	NA
4	YL	47	1	2	1.5	1	1	1	4	5	4.5	4	3	NA
5	NBA	66	4	3	3.5	1	1	1	5	4	4.5	3	3	NA
6	MC	69	2	2	2	1	1	1	4	5	4.5	4	3	NA
7	DA	59	3	4	3.5	1	1	1	4	3	3.5	2	3	Edema
8	AZ	61	2	1	1.5	1	0	0.5	4	4	4	4	3	NA
9	YL	52	3	4	3.5	1	1	1	3	4	3.5	4	3	NA
10	SH	57	3	3	3	1	1	1	4	4	4	4	4	NA
Average		60.2			2.85			1.05			3.8	3.5	3.3	

NA, not applicable.

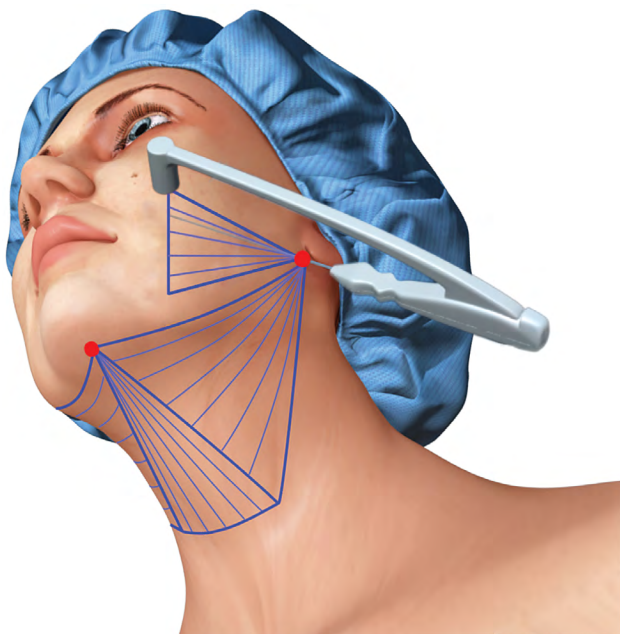


Fig. 1. Preoperative markings. The lower face and neck are divided into 5 triangular treatment zones: a triangular zone above the mandibular border, bilaterally, and the neck itself divided into 3 triangular zones (2 lateral and 1 central). The access incision ports (marked in color) include an infralobular, bilateral, and submental.

echogenicity reflect an increase in the collagen content in layers 1–5.

A postoperative global decrease in thickness was noted. The percentage thickness decrease per site was 16% for the lateral neck, 6% for lower face, and 19% for the submental region ($P = 0.01$). These reductions reflect the tightening effect due to reduced fatty content, collagenous tissue contraction and rearrangement of collagen fibers.

The average physicians' improvement in lower face contour was 3.8 (indicating 50-75% improvement). The average physicians' Merz jawline scale was improved from 2.85 at baseline to 1.05 at 12 months posttreatment. The physicians' correlations of all measurements were significant and ranged between medium to strong ($0.60 < R < 0.94$), indicating that results were reliable and could be averaged. Patients' tolerance was 3.3 and patient satisfaction was 3.5. Side effects were minimal. Patient characteristics and treatment outcomes are shown in [Table 2](#). Case presentations and selected ultrasound findings demonstrating thickness and echogenicity are presented in [Figures 2–6](#).

DISCUSSION

Facial aging is a multilayered process, affecting collagen-containing tissues in layers 1–4 (dermis, fibrous septa, SMAS, and the retaining ligaments, respectively)

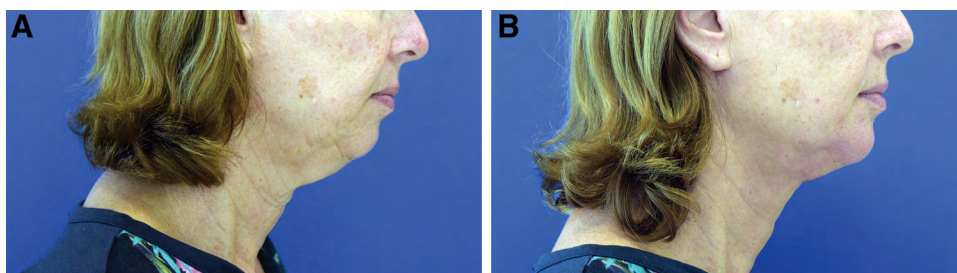


Fig. 2. A 65-year-old patient before (A) and at 12 months following treatment (B). Note the improvement in jawline definition and cervicomental angle.

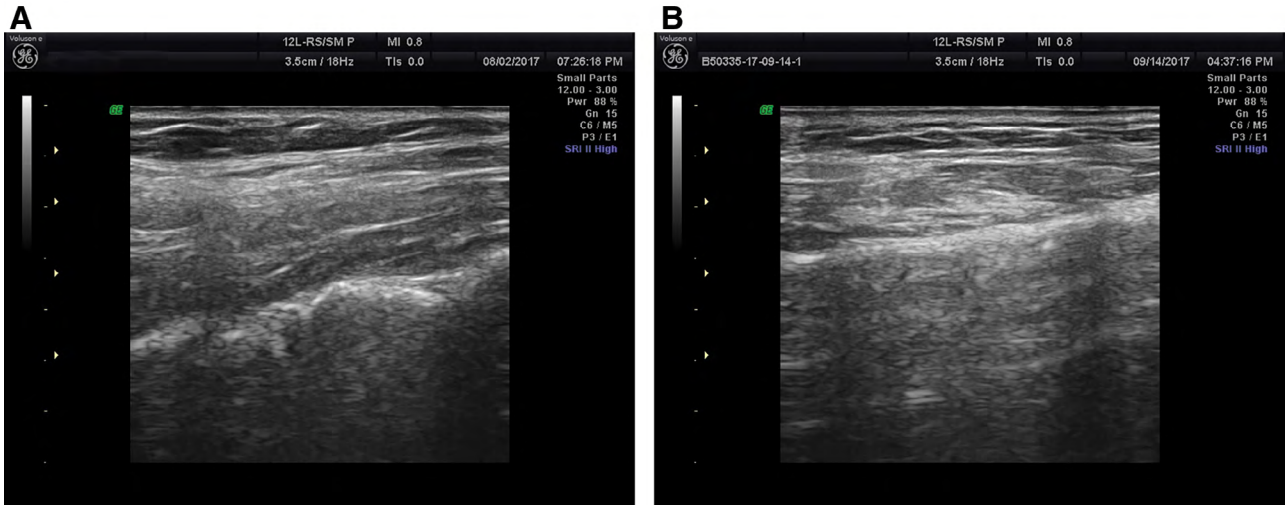


Fig. 3. US image of the lateral neck before (A) and at 6 weeks postoperatively (B), demonstrating a profound contraction and a marked decrease in facial layers 1–5 thickness (from 1.78 cm to 1.2 cm). Insets show the marked increase in echogenicity of facial layers. The number of HEPS counted by image analysis was 4.2564 before (C) and 10.4887 postoperatively (D), reflecting collagenesis induced by the RFTC device.

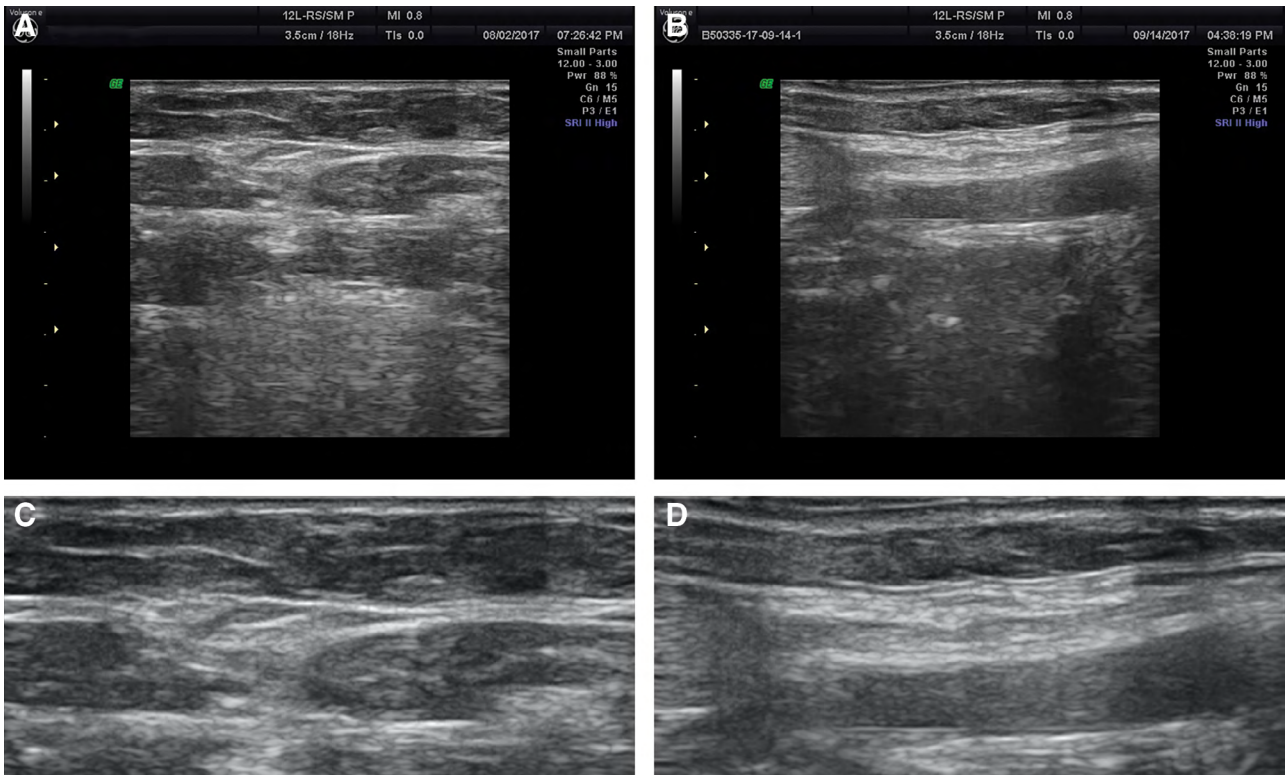


Fig. 4. US image of the submental region before (A) and at 6 weeks postoperatively (B), demonstrating a marked decrease in facial layers thickness (from 1.98 cm to 1.35 cm). Significant lipolysis, collagenous tissue contraction, and rearrangement are visibly appreciable. Note: the liquefied fat was replaced by neocollagenesis. The number of HEPS was 4.951 before (C) and 5.4249 postoperatively (D).

as well as fatty tissue. Age-dependent changes of the collagen-containing facial tissues (stretching, fragmentation, and attenuation) and of the facial fat compartments (inferior migration and inferior volume shift within the compartments) contribute to the stigmata of facial aging.

Current nonsurgical modalities for facial contouring include lasers, ultrasound, and RF. RF-based technologies have been revolutionized from the thermally-induced collagen contraction residing only in the dermis,³⁻⁵ to contraction of the fibroseptal network. This is a paradigm shift from a 2-dimensional horizontal tightening

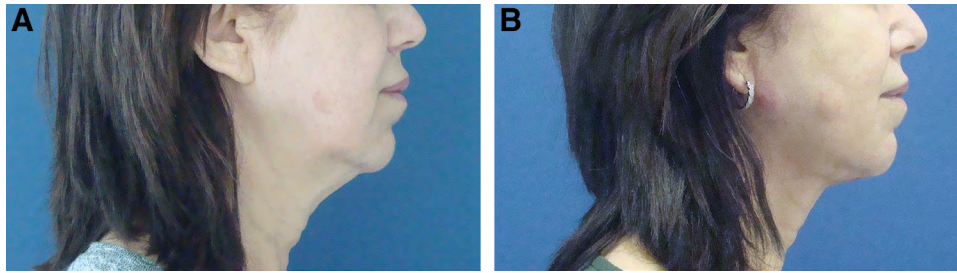


Fig. 5. A 56-year-old patient before (A) and at 12 months following treatment (B).

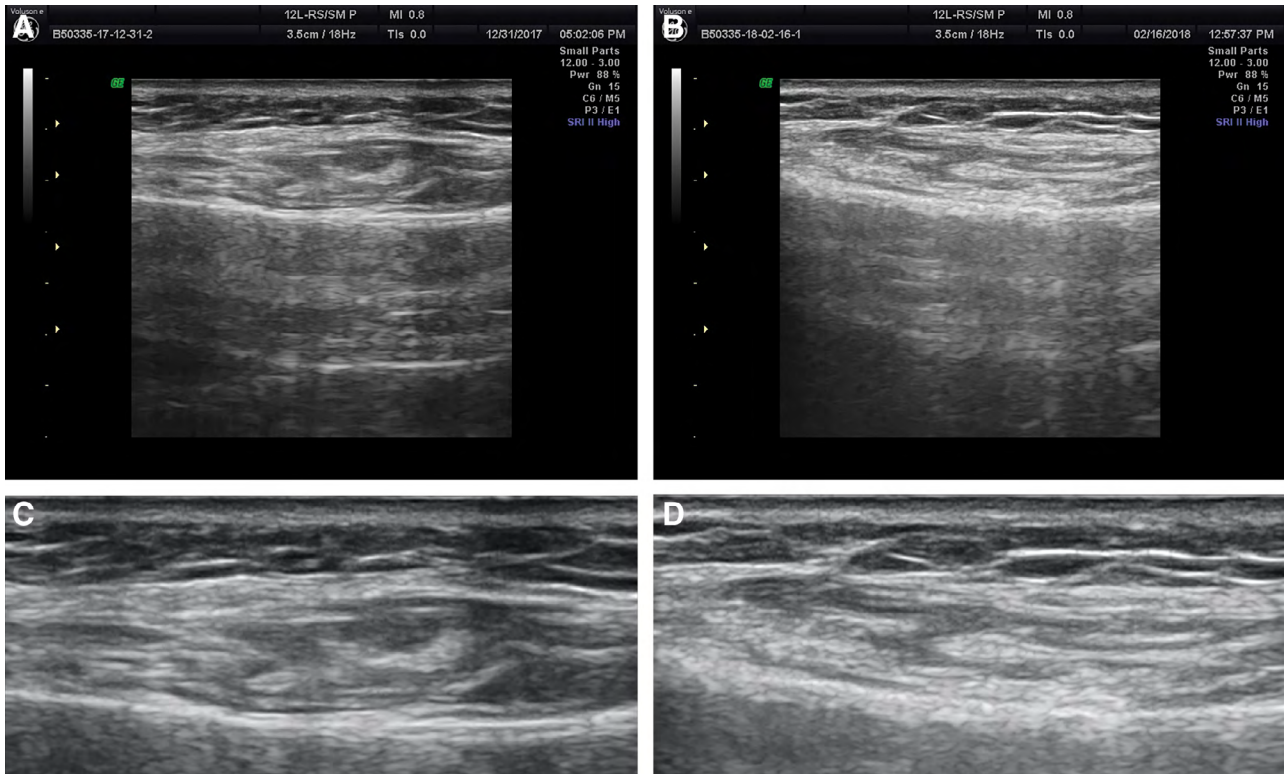


Fig. 6. US image of the lower midcheek before (A) and at 6 weeks postoperatively (B), demonstrating more densely compacted organized collagenous containing tissue, an overall decrease in thickness (1.34–1.2 cm following treatment). The number of HEPs was 8.2058 before (C) and 22.1062 postoperatively (D).

(aimed to improve skin laxity)^{2,5,18} to a 3-dimensional tissue tightening (which involves the deep layers of collagen-containing tissues).¹⁹ The latest RF technology is the temperature-controlled RF energy deposition, affecting the collagenous as well as adipose tissues. This RF-assisted liposuction has been practiced for body contouring,^{19–21} and the reported soft tissue contraction was superior to other liposuction modalities: up to 47%¹⁹ compared with 17%²² for laser-assisted lipolysis at 6 months and 6% for suction-assisted lipoplasty.²³ The resultant tissue tightening and lipolysis might be beneficial for lower face and cervical contouring as well.

Our study is the first prospective cohort of patients treated by RFTC device to the sub-SMAS layer for lower face and cervical contouring. It is also the first cohort study in which the RF effect was documented both quantitatively and qualitatively by pre- and post-operative

ultrasound measurements of the facial layers 1–5. RF energy was delivered to the sub-SMAS layer in a bipolar manner, creating a controlled, confined thermal effect to the intervening layers: SMAS, subcutaneous tissue, and the reticular dermis. The sub-SMAS (layer 4) is essentially an avascular potential space that contains soft tissues spaces, retaining ligaments and facial nerve branches passing from deep to superficial, in relation to defined landmarks. The facial nerve branches remain deep to the deep fascia (layer 5) in the lateral face—ie, lateral to vertical line descending from the lateral orbital rim. Medial to this line, in close association with the retaining ligaments, these branches traverse layer 4 to innervate the underside of the mimetic muscles.¹ This anatomy was verified by multiple cadaver dissections.^{24,25} The upper and lower buccal trunks traverse layer 4 as they approach the anterior border of the masseter, in

association with the upper and lower key masseteric ligaments, respectively.^{1,24} The marginal mandibular branch traverses layer 4 crossing the facial vessels 3.1 mm superior to the lower mandibular border.²⁵ Hence, treatment in sub-SMAS plane in the lateral face, and at a distance of 0.5 cm from the lower mandibular border, as presented in our technique, is safe and void of untoward facial nerve injury. The safety of dissection in the sub-SMAS plane has also been well documented for deep-plane rhytidectomies, with rates of temporary facial nerve neuropraxia of 1% and no permanent facial nerve injury. This is within the 2.1% reported incidence of temporary neuropraxia from a survey of more than 12,000 facelifts.²⁶ Multi-layer volumetric heating and the reduced risk of thermal injury of the superficial facial layers (eg, nodules, tissues hardening) are other putative advantages of the sub-SMAS plane.

We herein report clinical and objective sonographic responses of 10 patients following RFTC treatment. Most patients experienced significant clinical improvement and were highly satisfied with the results. All patients exhibited very good tolerance to the device, reporting minimal pain, discomfort, and swelling, which subsided shortly after treatment. A significant increase in echogenicity of facial layers 1–5 was shown: 149% in lateral neck, 78% in lower face, and 60% in submental. We postulate that this collagenesis is attributed not only to the thermally induced collagen remodeling of the deep layer collagen-containing tissues, but also to an active fibroblastic reaction replacing the liquefied fat. The sonographic images demonstrated a visibly appreciable more organized, compact, densely arranged layers—ie, reflecting collagen rearrangement. These changes may also count for the increase in echogenicity and decreased thickness measurements. We also noted a significant decrease in thickness of facial layers 1–5. These data exhibit substantial tissue tightening, reflecting a significant thermally-mediated contraction of the collagenous containing tissue, as well as liquefaction and lipolysis.

The present study also provides compelling evidence for the dual functionality of invasive RF-based technology: the tightening effect of the collagen-containing facial tissues coupled with the RF-assisted lipolysis. Although this study is limited by the small sample size, 12 sets of objective data were collected for each patient, and the treatment efficacy was evaluated objectively by quantitative and qualitative sonographic measurements in 3 locations. The relatively short-term sonographic follow-up is another potential limitation. Yet, it is well known that RF-induced soft tissue contraction and tightening continue to improve with time. This is in line with our clinical observation. Further multicenter studies with a longer follow-up are warranted.

In conclusion, deep layer treatment using RFTC opens a new horizon for nonsurgical cervicofacial contouring. It allows multilayer collagenous tissue contraction, profound tightening, and visibly appreciable lipolysis. The technique presented herein is safe and effective, and serves as an alternative for surgery in selected patients.

Sarit Cohen, MD

Department of Plastic and Reconstructive Surgery
Assaf Harofeh Medical Center
Zerifin 70300, Israel
E-mail: sariti@zahav.net.il

REFERENCES

- Mendelson B, Wong C. Anatomy of the aging face. In: Neligan PC, ed. *Plastic Surgery*. Vol 2, 3rd ed. New York: Elsevier Saunders; 2013:78–92.
- Dover JS, Zelickson B; 14-Physician Multispecialty Consensus Panel. Results of a survey of 5,700 patient monopolar radiofrequency facial skin tightening treatments: assessment of a low-energy multiple-pass technique leading to a clinical end point algorithm. *Dermatol Surg*. 2007;33:900–907.
- Zelickson BD, Kist D, Bernstein E, et al. Histological and ultrastructural evaluation of the effects of a radiofrequency-based nonablative dermal remodeling device: a pilot study. *Arch Dermatol*. 2004;140:204–209.
- Mulholland RS. Radio frequency energy for non-invasive and minimally invasive skin tightening. *Clin Plast Surg*. 2011;38:437–48, vi.
- Mulholland RS, Ahn DH, Kreindel M, Paul M. Fractional ablative radio-frequency resurfacing in Asian and Caucasian skin: a novel method for deep radiofrequency fractional skin rejuvenation. *J Cosmet Dermatol Sci Appl*. 2012;2:144–150.
- Rohrich RJ, Pessa JE. The retaining system of the face: histologic evaluation of the septal boundaries of the subcutaneous fat compartments. *Plast Reconstr Surg*. 2008;121:1804–1809.
- Har-Shai Y, Bodner SR, Egozy-Golan D, et al. Mechanical properties and microstructure of the superficial musculoaponeurotic system. *Plast Reconstr Surg*. 1996;98:59–70.
- Ghasem A, Piescher A, Riediger D. Anatomy of the SMAS revisited. *Aesthetic Plast Surg*. 2003;23:258–264.
- Ozdemir R, Kilinç H, Unlü RE, et al. Anatomicohistologic study of the retaining ligaments of the face and use in face lift: retaining ligament correction and SMAS plication. *Plast Reconstr Surg*. 2002;110:1134–1147.
- Ahn DH, Mulholland RS, Duncan D, et al. Non-excisional face and neck tightening using a novel subdermal radiofrequency thermocoagulative device. *J Cosmet Dermatol Sci Appl*. 2001;1:141–146.
- Keramidas E, Rodopoulou S. Radiofrequency-assisted liposuction for neck and lower face adipodermal remodeling and contouring. *Plast Reconstr Surg Glob Open*. 2016;4:e850.
- Baker DC. Lateral SMASectomy, plication and short scar facelifts: indications and techniques. *Clin Plast Surg*. 2008;35:533–550, vi.
- Jacono AA, Malone MH. Characterization of the cervical retaining ligaments during subplatysmal facelift dissection and its implications. *Aesthet Surg J*. 2017;37:495–501.
- Gniadecka M, Quistorff B. Assessment of dermal water by high-frequency ultrasound: comparative studies with nuclear magnetic resonance. *Br J Dermatol*. 1996;135:218–224.
- Narins RS, Carruthers J, Flynn TC, et al. Validated assessment scales for the lower face. *Dermatol Surg*. 2012;38(2 Spec No.):333–342.
- Rzany B, Carruthers A, Carruthers J, et al. Validated composite assessment scales for the global face. *Dermatol Surg*. 2012;38(2 Spec No.):294–308.
- Stella E, Di Petrillo A. Standard evaluation of the patient: the Merz scale. In: Goisis M, eds. *Injections in Aesthetic Medicine*. Milano, Italy: Springer; 2014.
- Alexiades-Armenakas M, Newman J, Willey A, et al. Prospective multicenter clinical trial of a minimally invasive temperature-controlled bipolar fractional radiofrequency system for rhytid and laxity treatment. *Dermatol Surg*. 2013;39:263–273.

19. Paul M, Blugerman G, Kreindel M, et al. Three-dimensional radiofrequency tissue tightening: a proposed mechanism and applications for body contouring. *Aesthetic Plast Surg*. 2011;35:87–95.
20. Hurwitz D, Smith D. Treatment of overweight patients by radiofrequency-assisted liposuction (RFAL) for aesthetic reshaping and skin tightening. *Aesthetic Plast Surg*. 2012;36:62–71.
21. Theodorou SJ, Paresi RJ, Chia CT. Radiofrequency-assisted liposuction device for body contouring: 97 patients under local anesthesia. *Aesthetic Plast Surg*. 2012;36:767–779.
22. DiBernardo BE. Randomized, blinded split abdomen study evaluating skin shrinkage and skin tightening in laser-assisted liposuction versus liposuction control. *Aesthet Surg J*. 2010;30:593–602.
23. Duncan ID. Nonexcisional tissue tightening creating skin surface area reduction during abdominal liposuction by adding radiofrequency heatings. *Aesthet Surg J*. 2014;33:1154–1166.
24. Mendelson BC, Wong CH. Surgical anatomy of the middle pre-masseter space and its application in sub-SMAS face lift surgery. *Plast Reconstr Surg*. 2013;132:57–64.
25. Huettner F, Rueda S, Ozturk CN, et al. The relationship of the marginal mandibular nerve to the mandibular osseocutaneous ligament and lesser ligaments of the lower face. *Aesthet Surg J*. 2015;35:111–120.
26. Matarasso A, Elkwood A, Rankin M, et al. National plastic surgery survey: face lift techniques and complications. *Plast Reconstr Surg*. 2000;106:1185–1195.