

OPEN

Clinical Evaluation of Safety and Efficacy of Radiofrequency-Assisted Lipolysis on Breast Envelope and Nipple-Areola Complex Position

Jacob G. Unger, M.D.
Nneamaka Agochukwu-
Nwubah, M.D.
Spero Theodorou, M.D.
G. Patrick Maxwell, M.D.

Nashville, Tenn.; and New York, N.Y.



Background: Breast ptosis as a result of pregnancy and/or breastfeeding, age, genetics, and weight loss is a common complaint among women visiting a plastic surgeon. This study sought to evaluate the utility, efficacy, and safety of radiofrequency-assisted lipolysis on the breast and nipple-areola complex position in women with breast ptosis.

Methods: This was a single-center (i.e., Maxwell Aesthetics) study of women desiring tightening of the breast envelope and elevation of the nipple-areola complex. Each patient underwent one treatment with radiofrequency-assisted lipolysis in the operating room. Radiofrequency-assisted lipolysis was applied to each breast with a BodyTite Pro handpiece. Patients were evaluated preoperatively and postoperatively at 6 weeks, 3 months, 6 months, and 12 months by means of manual and three-dimensional computer-generated measurements (i.e., Vectra).

Results: Ten female patients were enrolled. Ages ranged from 23 to 54 years. Follow-up was 12 months. Data were captured for seven measurements from the nipple longitudinally at five time points. The sternal notch-to-nipple distance, the nipple-to-inframammary fold distance, and the nipple-to-nipple distance improved statistically at 6-week follow-up, which persisted through the 12-month follow-up ($p < 0.05$). Patient questionnaires revealed moderate to excellent satisfaction.

Conclusions: Radiofrequency-assisted lipolysis with a bipolar device to deliver radiofrequency energy to the breast is an effective modality to moderately improve breast ptosis. This study demonstrates that this treatment improves breast measurements across time, regardless of measurement type (manual versus Vectra). This modality affords a minimally invasive, effective method to improve mild to moderate breast ptosis with minimal scarring and high patient satisfaction. (*Plast. Reconstr. Surg.* 150: 1200, 2022.)

CLINICAL QUESTION/LEVEL OF EVIDENCE: Therapeutic, IV.

From Maxwell Aesthetics; and BodySculpt NYC.

Received for publication July 19, 2020; accepted December 20, 2019.

The first two authors are co-first authors.

This trial is registered under the name "Clinical Evaluation of RFAL of Breast Envelope and NAC Position," ClinicalTrials.gov identification number NCT03863834 (<https://clinicaltrials.gov/ct2/show/NCT03863834>).

Copyright © 2022 The Authors. Published by Wolters Kluwer Health, Inc. on behalf of the American Society of Plastic Surgeons. All rights reserved. This is an open-access article distributed under the terms of the Creative Commons Attribution-Non Commercial-No Derivatives License 4.0 (CCBY-NC-ND), where it is permissible to download and share the work provided it is properly cited. The work cannot be changed in any way or used commercially without permission from the journal.

DOI: 10.1097/PRS.0000000000009729

Genetics, age, pregnancy, weight loss, child-bearing, and breast-feeding are all contributors to breast ptosis in women. Patients and plastic surgeons alike have long sought minimally invasive methods to improve the skin envelope of the breast and the nipple-areola complex position on the chest wall. To minimize scarring in patients who need just a slight improvement

Disclosure: Dr. Unger is a consultant for InMode. Dr. Theodorou is a consultant for InMode. InMode provided study support for this study. The remaining authors have no financial interests to report.

Related digital media are available in the full-text version of the article on www.PRSJournal.com.

in the nipple-areola complex position and a mild amount of tightening, some surgeons use the periareolar mastopexy. This technique has less inherent scarring but is technically demanding and fraught with complications.¹⁻³

Radiofrequency-assisted lipolysis is a relatively new technique among the array of energy/heat-assisted body contouring modalities that has become increasingly popular and used. The BodyTite device (InMode Corp., Toronto, Ontario, Canada) uses electromagnetic radiation and applies this directly to the soft tissues to stimulate skin contraction and collagen formation.^{4,5}

Radiofrequency-assisted lipolysis with the BodyTite device has been described for effective contouring of the arms, neck, lower face, abdomen, medial thighs, and chest in male patients with gynecomastia.⁴⁻⁸ In one such study, aggressive superficial liposuction was compared with radiofrequency-assisted lipolysis for treatment of arm adiposity. In this study, radiofrequency-assisted lipolysis provided 22.8 percent soft-tissue contraction at 1 year, compared with 17.8 percent for aggressive superficial liposuction.⁷ This study demonstrated that radiofrequency-assisted lipolysis was a safe and effective alternative to obtain soft-tissue contraction of the arms without the need for aggressive superficial liposuction, which itself carries a high risk of contour irregularities and a very steep learning curve.⁷

Radiofrequency-assisted lipolysis has never been described for treatment of breast ptosis or for improvement of the nipple-areola complex position and the overall breast envelope. Furthermore, effective noninvasive improvement of breast ptosis is virtually nonexistent in the literature. In this study, we used radiofrequency-assisted lipolysis to the breasts in female patients with mild to moderate ptosis. We evaluated nipple-areola complex position on the chest wall, relative to the sternal notch, and the overall tightness of the breast envelope through standard manual measurements and computerized measurements with the Vectra 3D (Canfield Scientific, Parsippany, N.J.) system. Our goal was to evaluate the effectiveness, safety, and utility of radiofrequency-assisted lipolysis on the improvement of the breast envelope and nipple-areola complex position.

PATIENTS AND METHODS

This was a single-center (i.e., Maxwell Aesthetics) study of female patients desiring tightening of the breast envelope and elevation of the nipple-areola complex. Inclusion criteria were women aged 21 to 65 years who desired

elevated nipple position/tighter breast envelope. Exclusion criteria included active smoking and a history of breast cancer.

Each of the 10 patients underwent one treatment with radiofrequency-assisted lipolysis in the operating room. Age, demographics, comorbidities, and baseline breast measurements were obtained per breast (right and left), including sternal notch-to-nipple distance, nipple-to-inframammary fold distance, base width, and nipple-to-nipple distance, in addition to photographs.

Data were captured from 10 study participants for seven measurements from the nipple longitudinally at five time points: baseline, 6-week follow-up, 3-month follow-up, 6-month follow-up, and 12-month follow-up. Moreover, all measurements were captured manually by the same clinician (J.G.U.) and by means of the Vectra technology tool. Regarding the Vectra technology and measurements, the investigator used the autolandmarks when appropriate. On rare occasion that the marks were unable to be placed by means of the software or inappropriately positioned, they were placed manually. Importantly, the surface topography landmark for breast borders or sternal notch were replicated in each image from preoperative to postoperative series to ensure as much reliability as possible.

Whole Breast Protocol

See Videos 1 through 3 for a full video of this procedure. [See **Video 1 (online)**, which demonstrates patient setup and tumescent infiltration. See **Video 2 (online)**, which demonstrates technique and description of how to impart radiofrequency energy into the breast tissue with a step-by-step algorithm of the protocol. See **Video 3 (online)**, which demonstrates continuation of radiofrequency-assisted lipolysis technique and liposuction technique and discussion of postoperative care.]

Awake patients in whom general anesthesia is not being used receive 500 mg of cephalexin, one tablet of oxycodone/acetaminophen (5 mg/325 mg), and 10 mg of diazepam 30 minutes before surgery. Those in whom general anesthesia is being used receive the standard anesthesia induction and intubation.

For the awake patient, local anesthesia (1% lidocaine with 1:100,000 epinephrine) is infiltrated over the anticipated incisions starting deep in the subcutaneous space and ending in an intradermal wheal. Then, 4-mm incisions are made with a no. 11 blade for introduction of the radiofrequency-assisted lipolysis and liposuction

cannulas. For the awake patient, specialized wetting solution, as described by Theodorou and Chia (1 liter of lactated Ringer solution plus 1000 mg of lidocaine plus 1.5 ml of epinephrine 1:1000 plus 10 ml of sodium bicarbonate), is used.^{4,7} The rate of infusion is kept slow and steady to minimize patient discomfort. Generally, 400 to 600 cc of fluid is used per side, depending on the size of the breast. If the patient is under general anesthesia, standard wetting solution is used and there is no preinjection of the incision points.

With a no. 11 blade, 3- to 4-mm incisions are made in three locations: the 12-o'clock position of the areola, the axilla in the upper outer aspect of the breast near the axillary tail of Spence along the anterior axillary line, and at the lateral aspect of the inframammary fold. In very large breasts, a fourth access point is used along the medial inframammary fold.

Wetting solution is then placed along the chest wall from the axillary port. This is placed along the gliding plane of the pectoralis fascia and should extend caudally to approximately the level of the nipple-areola complex. The superficial plane at the level of the subcutaneous tissue and the breast parenchyma (mastectomy plane) is then infiltrated with the wetting solution by means of the same port. This covers the entire upper pole and superolateral breast. Then, the medial quadrant of the breast and the medial inferior pole is infiltrated with wetting solution using the nipple-areola complex port. This is done in the superficial plane only. Finally, the lateral inframammary fold port is used to infiltrate wetting solution along the inferolateral quadrant of the breast and along the inframammary fold.

A time of 7 to 10 minutes is allowed to elapse to give time for the wetting solution to take effect from a hemostatic standpoint. A full-size BodyTite Handpiece or a BT Pro Handpiece (preferred) is used.

The recommended temperature settings (as used in the study) are 38°C external and 68°C internal. The whole breast protocol is achieved in six steps (five steps for the awake patient).

Step 1: The operator begins with the superior axillary port and BT Handpiece fully opened (setting 6) and starts by finding the gliding plane along the pectoral fascia. The goal is to achieve the internal temperature settings for the entire upper pole from this port. This portion is only performed in patients under general anesthesia.

Step 2: This step involves heating the superficial plane from the same access site along the subcutaneous/breast capsule layer. This area allows the operator to reach both internal and external

temperature goals. Heat is not applied across the nipple-areola complex, as this may affect nipple-areola complex sensation (Figs. 1 through 4).

Step 3: The operator uses the 12-o'clock nipple-areola complex port to cross-hatch the upper pole of the breast in the subcutaneous plane only (Figs. 5 through 7). This ensures consistent heating across the entire upper pole. The device is oriented in a cephalocaudal direction during this step.

Step 4: The operator pivots to a medial/lateral orientation to tighten the medial quadrant of the breast from the same port (12-o'clock nipple-areola complex port) (Fig. 8). The application of lateral traction to the breast improves the motion of the BodyTite cannula in this zone.

Step 5: The inferolateral port along the inframammary fold is used to heat the subcutaneous plane along the lower pole of the breast, in a medial/lateral vector of motion (Fig. 9). In addition, any of the inferolateral breast that was not treated from the upper outer port can be treated from this lower inframammary fold access site if needed.

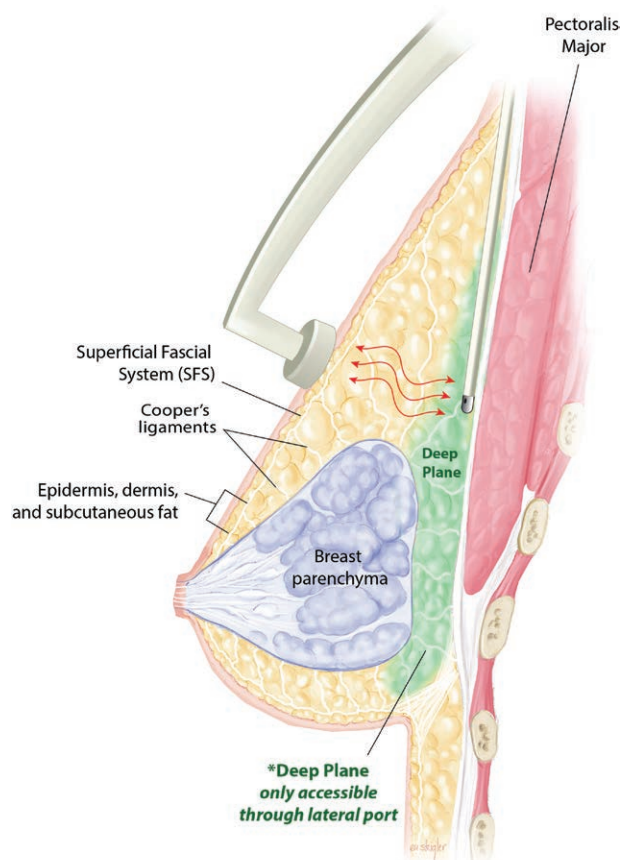


Fig. 1. Cross-section of breast, demonstrating access of the deep plane of the breast through the superolateral (axillary) access port. (©2020 Emily Ullo Steigler.)

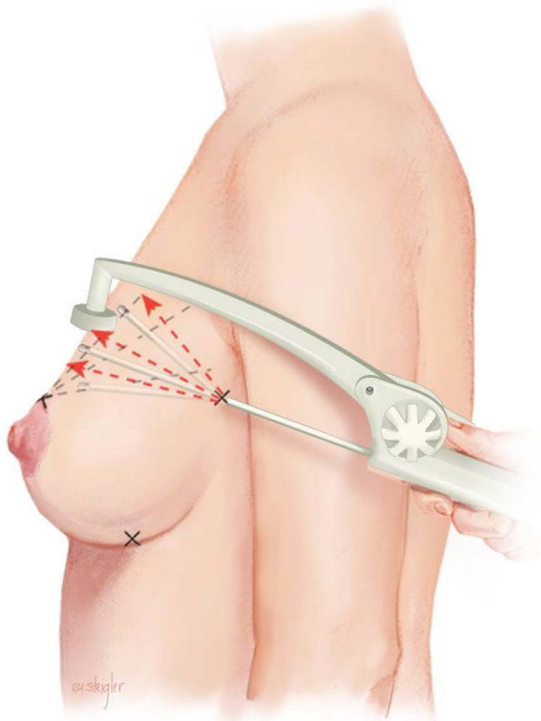


Fig. 2. Demonstration of the cross-hatching of the upper pole of the lateral breast through the axillary (superolateral) access port with the BT Handpiece. (©2020 Emily Ullo Steigler.)

Step 6: A 3-mm cannula is used to perform liposuction to remove any fatty oils generated from the radiofrequency-assisted lipolysis and to remove some of the wetting solution. Fat was approximately one-third to one-half of the total volume; the average volume was 50 per side.

All access sites are closed with a 5-0 black nylon suture. Dressings consist of Tegaderm (3M, St. Paul, Minn.) to gently hold the nipple-areola complex in a slightly elevated position. A supportive bra is worn for 6 weeks. Follow-up intervals were 6 weeks, 3 months, 6 months, and 1 year.

Statistical Analysis

All data were analyzed using IBM SPSS version 24 (IBM Corp., Armonk, N.Y.). To address the efficacy of the procedure, four paired-samples *t* tests were conducted for each of the distinct measurements (e.g., manual sternum to right nipple, Vectra left base width), resulting in a total of 70 *t* tests. These four paired *t* tests for each of the seven measures were as follows: (1) baseline compared to 6-week follow-up; (2) 6-week to 3-month follow-up; (3) 3-month to 6-month follow-up, (4) 6-month to 12-month follow-up, and (4) baseline to 12-month follow-up. Specific *p* value thresholds are listed in the appropriate tables for each test. The *p* value

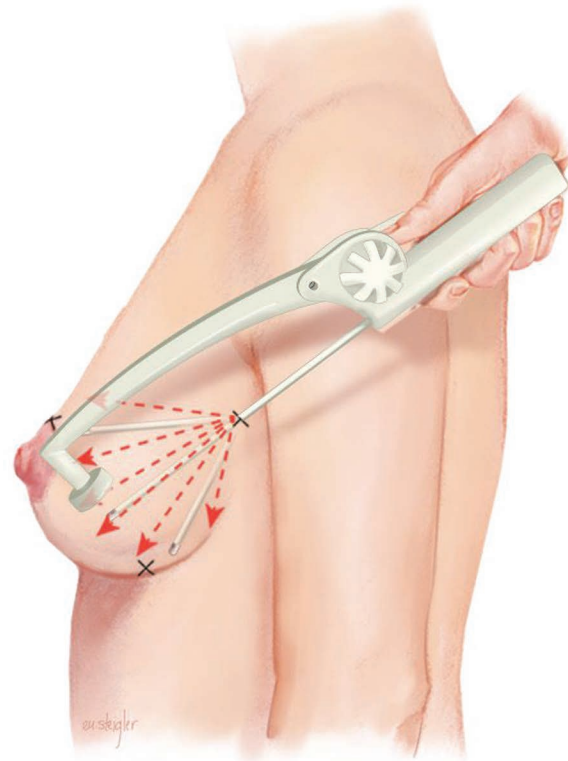


Fig. 3. Demonstration of the cross-hatching of the lower pole of the lateral breast through the axillary (superolateral) access port with the BT Handpiece. (©2020 Emily Ullo Steigler.)

cutoff for determining statistical significance was 0.05; however, there were also three interim (comparisons between sequential postoperative visits) tests that did have *p* values between 0.05 and 0.10. Thus, we considered these tests to be trending toward significance, albeit tests of limited clinical value.

RESULTS

Patients

Ten patients were enrolled in the study. All patients were female and White, and their ages ranged from 23 to 54 years (mean, 39 years). See [Table 1](#) for patient demographics and comorbidities.

First, the manual measurement results are reported, followed by the Vectra results. Finally, the communalities and differences in results between the two measurement types are discussed.

Treatment Energy Delivered

The amount of energy delivered per case was mainly dependent on breast size and ranged from 13 to 38 kJ, with an average of 18.55 kJ per breast.

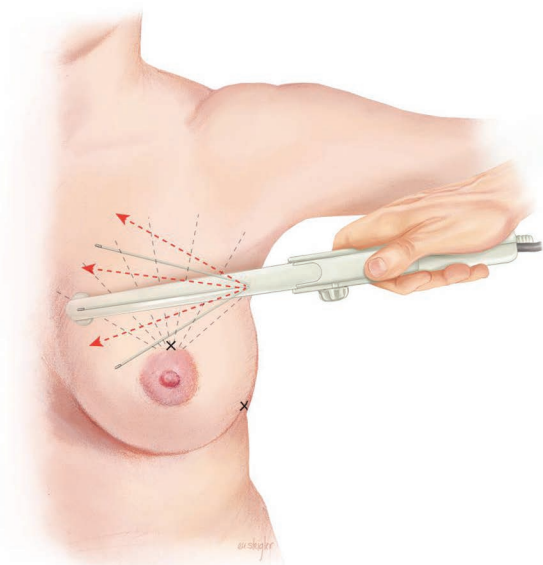


Fig. 4. Demonstration of the cross-hatching of the upper pole of the breast through the axillary (superolateral) access port with the BT Handpiece. (©2020 Emily Ullo Steigler.)

Manual Measurements

Sternal Notch–to–Nipple Distance

For the right breast, the mean sternal notch–to–nipple distance at time 1 (preoperatively) was 24.8 cm (range, 23 to 28 cm). This distance decreased to a mean of 23.4 cm at 6 weeks ($p < 0.001$) and 23.0 cm at 12 months ($p < 0.001$). For the left breast, the mean sternal notch–to–nipple distance at time 1 (preoperatively) was 25.5 cm (range, 21 to 28 cm). This distance decreased to a mean of 23.9 cm at 6 weeks ($p < 0.001$) and 23.4 cm at 12 months ($p < 0.001$) (Table 2 and Fig. 10).

Nipple–to–Inframammary Fold Distance

For the right breast, the mean nipple–to–inframammary fold distance at time 1 (preoperatively) was 11.1 cm (range, 8 to 18 cm). This distance decreased to a mean of 10.4 cm at 6 weeks ($p = 0.03$) and was 10.2 cm at 12 months ($p = 0.05$). For the left breast, the mean nipple–to–inframammary fold distance at time 1 (preoperatively) was 11.9 cm (range, 9 to 18.5 cm). This distance decreased to a mean of 11.3 at 6 weeks ($p = 0.03$) and was a mean of 11.3 cm at 12 months ($p = 0.04$) (Table 2).

Base Width and Nipple–to–Nipple Distance

Base width remained stable from the preoperative time point to all postoperative time points, whereas there was an overall decrease in the nipple–to–nipple distance from a baseline of 22 cm, to 21.2 cm at 6 weeks ($p = 0.02$) and 21.3 cm at 12 months ($p = 0.01$) (Table 2).

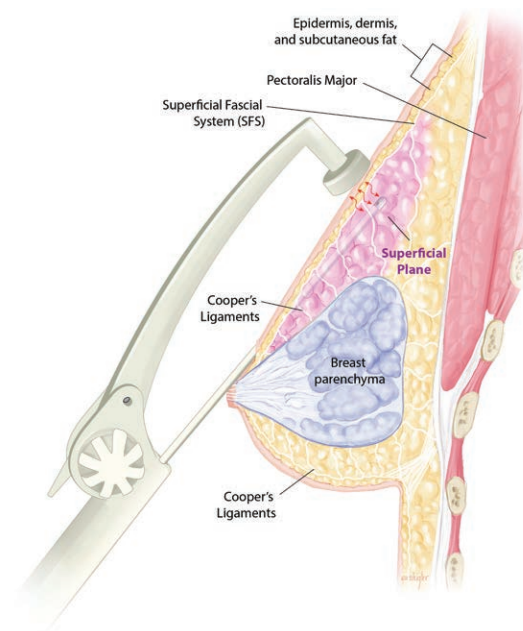


Fig. 5. Cross-section of breast, demonstrating access of the superficial plane of the breast accessed through the nipple–areola complex access port. (©2020 Emily Ullo Steigler.)

Standardized Measurements (Vectra 3D)

Sternal Notch–to–Nipple Distance

For the right breast, the mean sternal notch–to–nipple distance at time 1 (preoperatively/baseline) was 24.3 cm (range, 21.5 to 28.3 cm). This distance decreased to a mean of 23.2 cm at 6 weeks ($p < 0.001$) and 22.7 cm at 12 months ($p < 0.001$). For the left breast, the mean sternal notch–to–nipple distance at time 1 (preoperatively) was 24.9 cm (range, 21.5 to 27.9 cm). This distance decreased to a mean of 23.8 cm at 6 weeks ($p < 0.001$) and 23.2 cm at 12 months ($p < 0.001$) (Table 3).

Nipple–to–Inframammary Fold Distance

For the right breast, the mean nipple–to–inframammary fold distance at time 1 (preoperatively) was 7.95 cm (range, 6.7 to 10.2 cm). This distance was 8.03 cm at 3 months and was stable at 6 months (8.3 cm) and 12 months (8.4 cm). These differences were not statistically significant. For the left breast, the mean nipple–to–inframammary fold distance at time 1 (preoperatively) was 8.2 cm (range, 6.3 to 11.3 cm). This distance was 8.2 cm at 3 months and was stable at 6 months (8.2 cm) and 12 months (8.2 cm). Again, these differences were not statistically significant.

Base Width and Nipple–to–Nipple Distance

Base width distances increased for the right breast (baseline base width right to 3-month follow-up base width right), and they remained stable

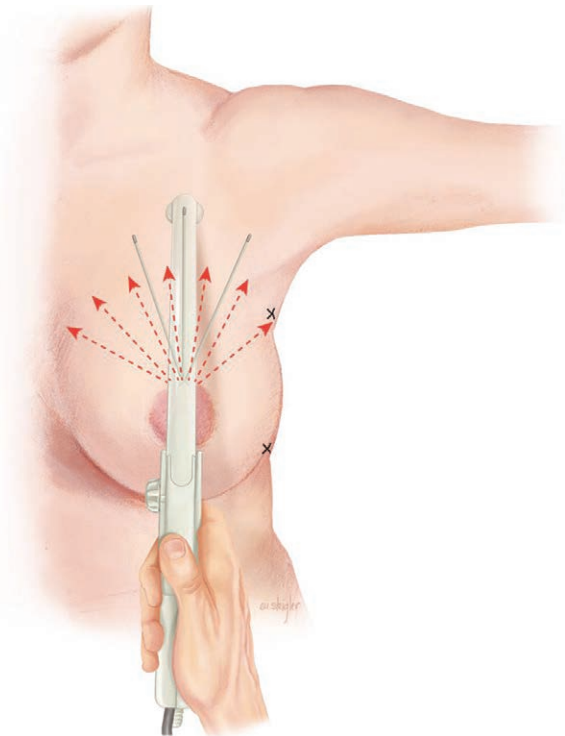


Fig. 6. Demonstration of the cross-hatching of the central upper pole of the breast through the nipple-areola complex access port with the BT Handpiece. (©2020 Emily Ullo Steigler.)

for the left breast ($p < 0.10$). The nipple-to-nipple distance increased by 1 cm when comparing the baseline measurement to the 12-month follow-up measurement ($p < 0.05$) (Table 3).

Patient Satisfaction

Patient questionnaires revealed moderate to excellent satisfaction of all patients with regard to overall satisfaction, recovery, improvement in the nipple-areola complex, and skin tightening at 12 months. This questionnaire was a five-point scale, with 1 being not satisfied and 5 being extremely satisfied. With regard to overall satisfaction, the average of all individual scores was 3.5 (very satisfied to completely satisfied). For the nipple-areola complex satisfaction, the average of all individual scores was 4.6 (completely satisfied to extremely satisfied). For recovery, the average of all individual scores was 4.4 (completely satisfied to extremely satisfied); for skin tightening, the average of all individual scores was 4.0 (completely satisfied). For recommendation, the score was 4.4 (would recommend to would highly recommend).

DISCUSSION

Dayan and colleagues discussed and demonstrated the widespread use and utility of

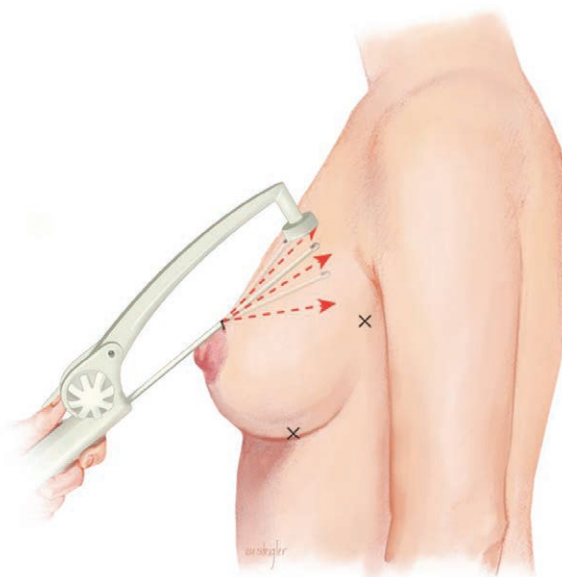


Fig. 7. Cross-section, demonstrating the cross-hatching of the central upper pole of the breast through the nipple-areola complex access port with the BT Handpiece. (©2020 Emily Ullo Steigler.)

radiofrequency-assisted lipolysis for effective tightening of the skin of the arms, abdomen, face, and back.⁸ In this study, and a study by Theodorou and Chia, the interesting concept of the “treatment gap” is described.⁴ This concept describes the “in-between” patients who have areas of loose skin and adiposity but do not necessarily need or desire a dramatic skin excision, and it likely would not retract with traditional liposuction.

Many patients, commonly in the third or fourth decade of life, often after a recent pregnancy, present to a plastic surgeon to restore their breasts with the goal of a more youthful and firm appearance. Although there are some patients who can have restoration of volume with breast augmentation alone, and many patients with grade 2 or 3 ptosis will require large skin envelope reduction and nipple elevation only achievable by formal skin excisional techniques with mastopexy, there is a segment of the patient population that falls into a “gap” between these cohorts. For patients with mild excess skin or minimally inferiorly positioned nipples, we have described a method using radiofrequency energy to help improve the skin envelope and create a more elevated nipple position with a nearly scarless and minimally invasive technique (Figs. 11 through 13). The concept of radiofrequency-assisted lipolysis and the radiofrequency energy leading to contraction of the superior pole of the breast and a subsequent increase in the nipple-areola complex was first hypothesized by Theodorou and Chia in their 2018 landmark

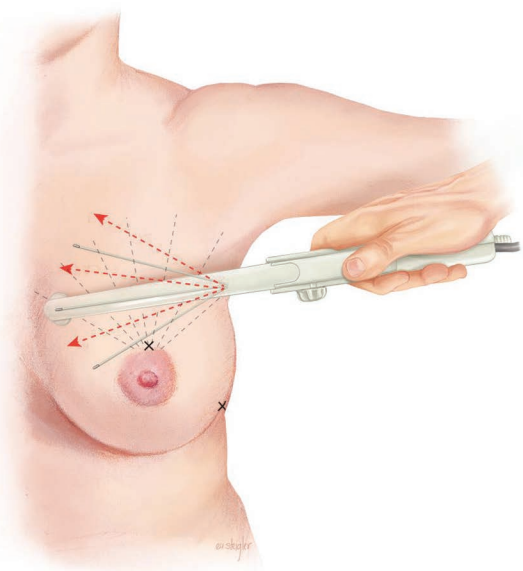


Fig. 8. Demonstration of the medial aspect of the medial upper pole of the breast through the nipple-areola complex access port with the BT Handpiece. (©2020 Emily Ullo Steigler.)

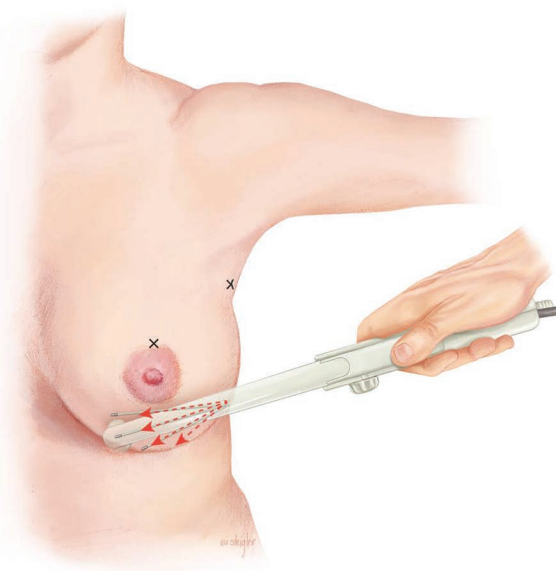


Fig. 9. Demonstration of cross-hatching of the lower pole of the breast through the inframammary fold port with the BT Handpiece. (©2020 Emily Ullo Steigler.)

Table 1. Demographics

Patient Code	Age (yr)	Concomitant Diseases	Allergies	Smoking	Height (in)	Weight (lb)	Medications
1	40	None	Clindamycin, severe	No	68	141	No
2	54	None	None	No	66	148	No
3	23	None	None	No	65	150	No
4	46	None	Seasonal and codeine	No	63	147	No
5	43	None	Seasonal	No	64	115	No
6	43	None	None	No	69	150	Multivitamin, vitamin D, tumeric
7	55	None	Latex	No	64	130	Yes
8	38	None	None	Yes	67	154	No
9	37	None	None	No	70	175	Tumeric, fish oil
10	23	None	None	No	67	145	No

Table 2. Significant Results of Manual Measurements

Pair	M1*	SD1	M2†	SD2	Decrease (cm)	Decrease (%)	t	p
BL Stern to Nip R–3MFU Stern to Nip R	24.8	1.8	23.4	2.0	1.4	5.5	8.2	<0.001
BL Stern to Nip R–12MFU Stern to Nip R	24.8	1.8	23.0	1.8	1.8	7.3	8.4	<0.001
BL Stern to Nip L–3MFU Stern to Nip L	25.5	2.2	24.1	2.1	1.4	5.3	10.8	<0.001
3MFU Stern to Nip L–6MFU Stern to Nip L	24.1	2.1	23.6	2.2	0.5	2.2	2.9	<0.05
BL Stern to Nip L–12MFU Stern to Nip L	25.5	2.2	23.4	2.2	2.1	8.0	6.6	<0.001
BL Nip to IMF R–3MFU Nip to IMF R	11.1	2.9	9.9	2.0	1.2	10.9	2.8	<0.05
BL Nip to IMF R–12MFU Nip to IMF R	11.1	2.9	10.2	1.9	0.9	8.1	2.2	<0.10
BL Nip to IMF L–3MFU Nip to IMF L	11.9	3.0	10.9	2.8	1.1	8.8	6.0	<0.001
BL Nip to IMF L–12MFU Nip to IMF L	11.9	3.0	11.3	2.8	0.6	5.0	2.3	<0.05
BL Nip to Nip–3MFU Nip to Nip	22.0	1.6	21.1	1.3	0.9	4.3	3.9	<0.01
BL Nip to Nip–12MFU Nip to Nip	22.0	1.6	21.3	1.4	0.7	3.2	3.2	<0.05

BL, baseline; Stern, sternal notch; Nip, nipple; R, right; 3MFU, 6-week to 3-month follow-up; 12MFU, 6-month to 12-month follow-up; 6MFU, 3-month to 6-month follow-up; L, left; IMF, inframammary fold.

*M1 = mean at time 1.
†M2 = mean at time 2.

article on radiofrequency-assisted lipolysis and soft-tissue contraction in body contouring.⁴

In this pilot study, we demonstrate the first use of this novel, minimally invasive radiofrequency-assisted

lipolysis technique that leads to moderate improvement in breast ptosis and shape without the scarring associated with a traditional mastopexy. Patients included women with a desire for more firm, youthful

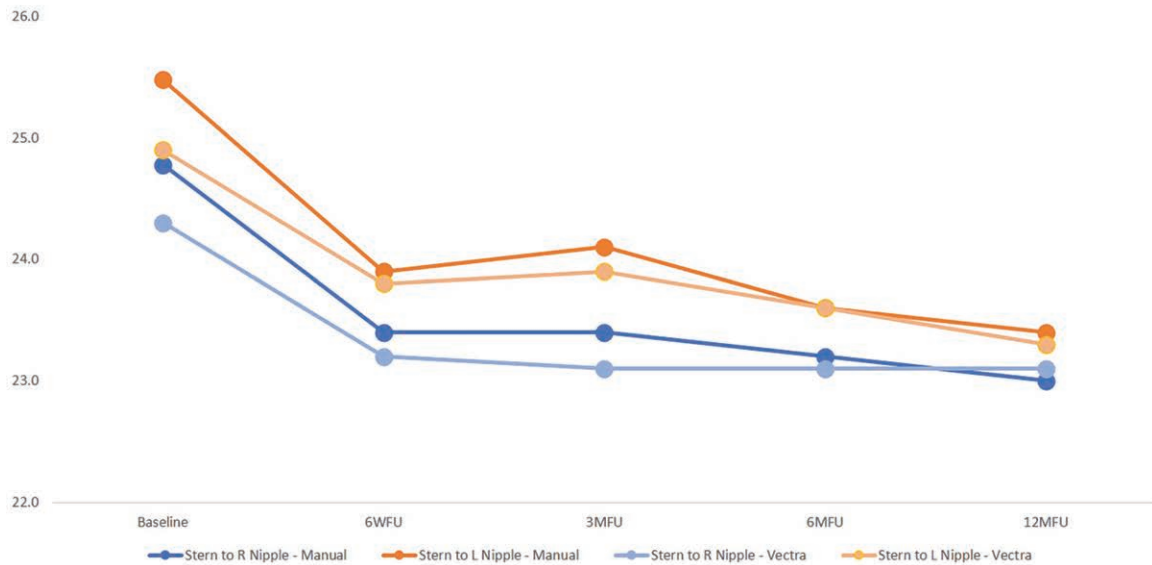


Fig. 10. Graph showing decrease in left and right sternal notch-to-nipple distance over time following treatment of the breast with the BreastTite device.

Table 3. Significant Results of Vectra Measurements

Pair	M1*	SD1	M2†	SD2	Decrease (cm)	Decrease (%)	<i>t</i>	<i>p</i>
BL Stern to Nip R-3MFU Stern to Nip R	24.3	2.0	23.1	2.1	1.2	5.0	5.1	0.001
BL Stern to Nip R-12MFU Stern to Nip R	24.3	2.0	22.7	1.8	1.6	6.5	4.9	0.001
BL Stern to Nip L-3MFU Stern to Nip L	24.9	1.7	23.9	2.1	1.0	4.0	3.9	<0.01
3MFU Stern to Nip L-6MFU Stern to Nip L	24.0	2.2	23.6	2.2	0.4	1.7	1.9	<0.10
BL Stern to Nip L-12MFU Stern to Nip L	24.9	1.7	23.2	2.0	1.6	6.6	4.9	0.001
BL base width R-3MFU base width R	14.5	1.7	15.5	2.1	-1.0	-6.8	-2.1	<0.10
BL Nip to Nip-12MFU Nip to Nip	21.6	1.9	22.6	1.4	-0.9	-4.2	-2.3	<0.05

BL, baseline; Stern, sternal notch; Nip, nipple; R, right; 3MFU, 6-week to 3-month follow-up; 12MFU, 6-mo to 12-mo follow-up; L, left; 6MFU, 3-mo to 6-mo follow-up.

*M1 = mean at time 1.

†M2 = mean at time 2.

breast shape and/or improvement in nipple-areola complex position. We did not require patients to have a certain degree or level of ptosis. Our study was a pilot study, and thus was relatively small with 10 patients (20 breasts total). Further studies with larger patient numbers will further enhance our experience and give a future study more power. For the purpose of this study, we excluded patients desiring augmentation or any other operative changes to the breast, as this would skew the results and measurements, and would introduce confounding variables with regard to the impact of the radiofrequency-assisted lipolysis on the breast. However, this modality is a great adjunct to breast augmentation, especially in patients with asymmetries (Fig. 14; please note that this patient was not included in the study but is shown and mentioned for demonstration purpose only). Our goals were to identify what, if any, impact BodyTite radiofrequency-assisted lipolysis would impart to the breast shape, envelope, and nipple position on a variety of breast shapes,

sizes, and ages with as few confounding variables as possible.

All measurements were taken by a single clinician (J.G.U.) at all time points. This helped to avoid variability in measurements, as can occur with multiple individuals taking measurements. Furthermore, all measurements were taken in a historically blind fashion, meaning the clinician taking measurements (J.G.U.) did not review the chart before taking measurements, and all measurements were recorded into the chart by the nurse so that there was no desire to achieve a particular measurement in any case. In addition, we obtained standardized measurements with Vectra 3D, which allowed for further standardization, and attempted removal of observer bias. Finally, every case consisted of radiofrequency-assisted lipolysis to the bilateral breasts with minimal liposuction to remove any oils and excess fluid, with no other surgical interventions performed.

We noticed an overall decrease in the sternal notch-to-nipple distance and the

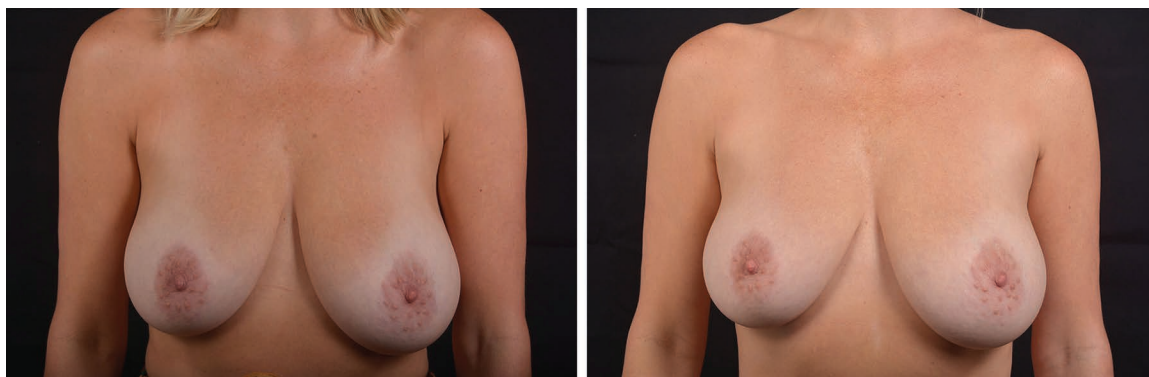


Fig. 11. Female patient shown before and after treatment with the BreasTite device to bilateral breasts.

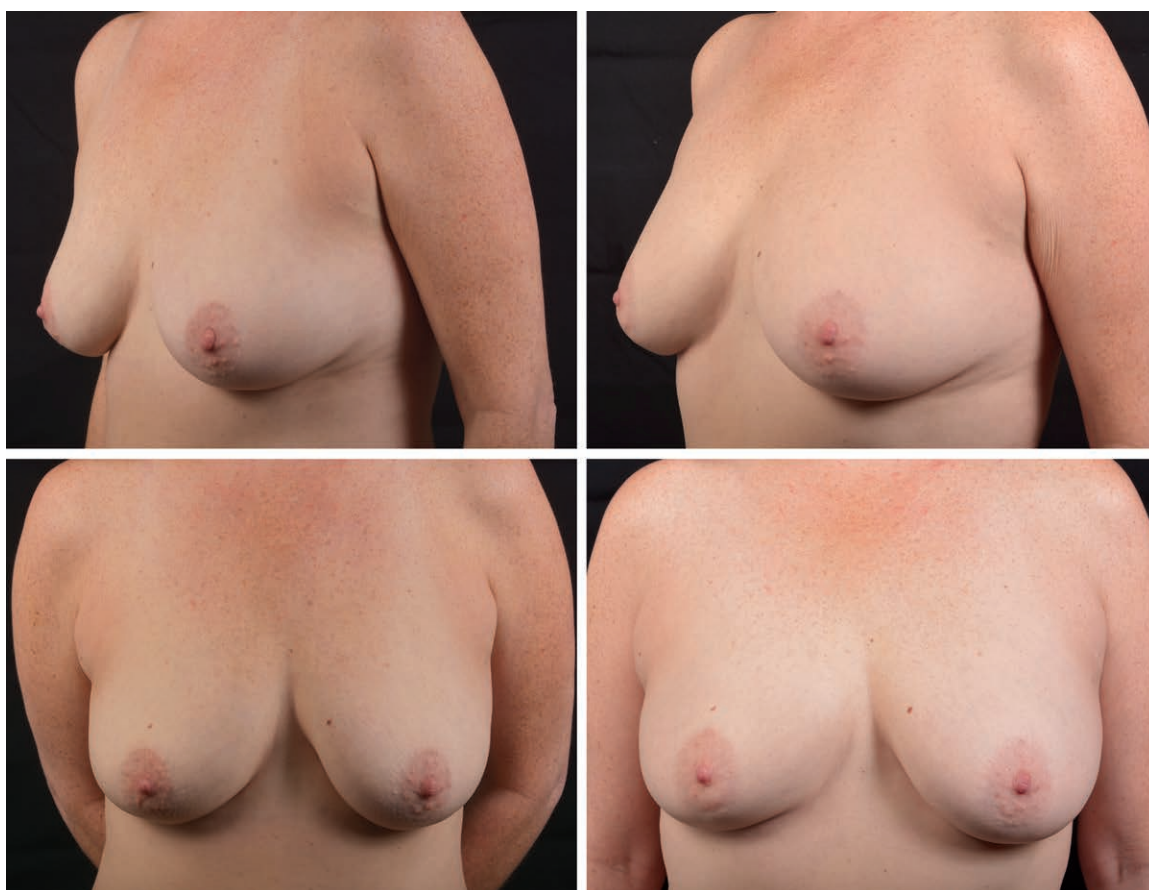

Fig. 12. Female patient shown before and after treatment with the BreasTite device to bilateral breasts (anteroposterior and oblique views).

nipple-to-inframammary fold distance, representing an improvement in the position of the nipple-areola complex and a tightening of the breast envelope (Fig. 1). The hypothesis that the treatment improves baseline measurements from 6-week follow-up and maintains improvement through the 12-month follow-up was generally proven to be correct. That is, the right and left sternal

notch-to-nipple distance improved (elevated) from baseline, and this was maintained through the 12-month follow-up. For the Vectra measurements, the same improvement in sternal notch-to-nipple distance was noted from baseline onward and was maintained at 1 year.

It should be noted that the nipple-to-inframammary fold distance did show a statistically significant

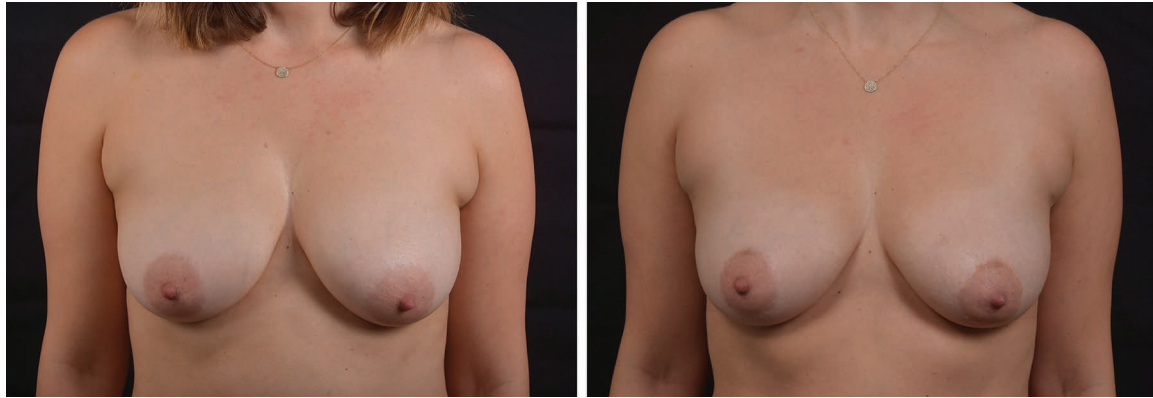

Fig. 13. Female patient shown before and after treatment with the BreasTite device to bilateral breasts.

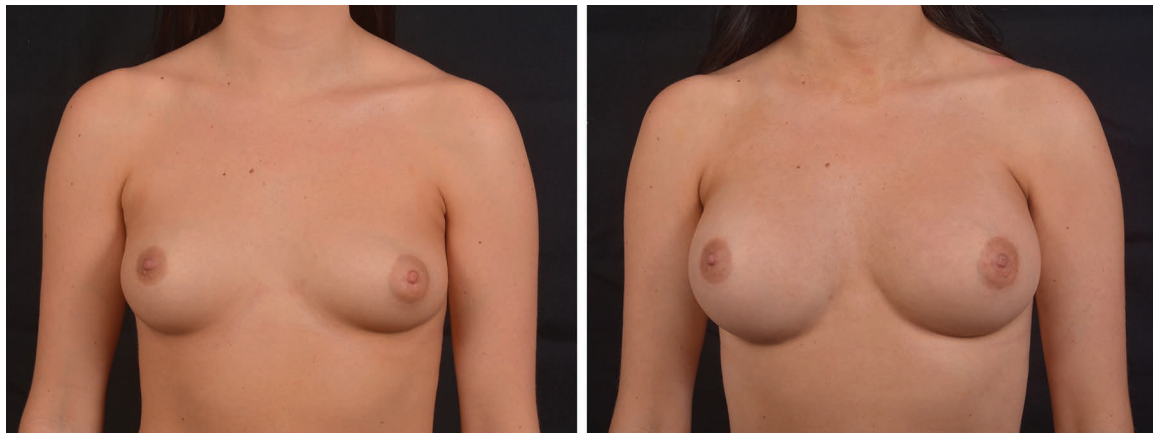


Fig. 14. Female patient shown before and after bilateral breast augmentation and treatment with the BreasTite device to the left breast to address breast asymmetry (anterior view).

decrease for the manual measurements, but not for the Vectra 3D measurements. This finding is expected, given the nature of the nipple-to-inframammary fold measurement. This is a very dynamic measurement that takes into account the inferior fold of the breast and often requires proximal displacement of the upper portion of the breast and the nipple-areola complex by the clinician. We routinely notice that the Vectra 3D system has low precision and accuracy when it comes to this particular measurement, as it often cannot and does not account for this inferior “cup” of breast tissue. The base width of the breasts (as measured by manual measurement) did not change from baseline to the postoperative time points, demonstrating no change in the breast overall width, and indicating a high degree of precision in these blinded measurements.

Nipple-to-nipple distance did decrease slightly over time by manual measurements, and this difference was statistically significant. This further indicates a reduction in the size of the skin envelope, and supports the subjective, qualitative sense the patients had of their breasts feeling “less

loose” and “tighter” overall. In general, the manual and Vectra measurements were consistent with one another, especially as they related to right and left sternal notch-to-nipple distance.

Interestingly, for the Vectra measurements, the right base width from baseline to 3-month follow-up and the nipple-to-nipple measurement from baseline to 12-month follow-up increased statistically. Although this is curious, the fact that (1) these increases were not seen in the manual measurements, and (2) the *p* values associated with these increases were not less than 0.01, lends credence to the argument that these differences might be a reflection of the fact that the sample size is small. That is, to determine a large effect size (0.8+) according to Cohen, with an alpha error probability of 0.05 and a power (1 – beta error probability) of 0.95, a total sample size of 19 participants is needed.⁹ With a larger sample size, it is possible that these incongruous Vectra measurement statistically significant differences (again, at higher *p* values, which are themselves, a reflection of sample size) may moderate and dissipate. Thus,

these Vectra increases in millimeter measurements should be interpreted cautiously.

The use of liposuction in radiofrequency-assisted lipolysis, and the role it might play in terms of volume changes, is an important consideration. We investigated the Vectra preoperative and 1-year postoperative volumes as determined by the three-dimensional software. There was no statistically significant difference in volume from preoperatively to postoperatively. Furthermore, there was no evidence of even a trend toward an overall slight reduction in volume. In fact, in some cases, volume was slightly higher, which may be attributable to patient factors such as weight, menstrual cycle timing, or lack of precision of the three-dimensional volumetric measuring system.

Risks of radiofrequency-assisted lipolysis include burns, sensation changes, and pigmentation changes. The external probe of the handpiece records epidermal (external) temperature and is a reasonable predictor of superficial heating of the subdermal layer, and is an important aspect in terms of safety monitoring to help prevent excessive energy that can result in thermal burns. Increasing temperature should be attempted only after achieving a level of mastery with the radiofrequency-assisted lipolysis handpieces to the point where there is fluid, smooth, and efficient movement in each treatment area. This decreases the risk for “hot spots” or “drag spots” that may cause point temperature elevations outside of safe parameters and subsequent burns. One of the built-in safety components of the InMode radiofrequency-assisted lipolysis platform is the safety systems that help to avoid excess heating and thus avoid thermal burns. We do counsel all patients on the risk of pigmentation changes and sensation changes, and did note that we did not experience this in our cohorts. We also did not have any visible or palpable fat necrosis in our study cohort.

All patients demonstrated moderate to high satisfaction and would highly recommend the treatment, citing the minimally invasive nature of the treatment and the absence of the scars associated with most mastopexies. As with all plastic surgery procedures, patient selection is paramount. This procedure is not ideal for patients with large, pendulous breasts desiring reduction, or patients with very severe ptosis or massive weight loss. More ideal patients include those with minimal ptosis and modest skin envelope desiring reduction, who are overall pleased with their breast size (i.e., not seeking a large volume reduction). Experience with this technique for the breast will

give the practitioner comfort in determining ideal patients for this technique, and this is a still-evolving field to determine ideal patients.

CONCLUSIONS

This study provides summative and formative evidence to suggest that this treatment, at least on these 10 participants, has improved (i.e., decreased the measurements in centimeters) several comparisons across time, regardless of measurement type (manual versus Vectra). For a handful of measurements (sternal notch-to-nipple distance, nipple-to-inframammary fold distance, nipple-to-nipple distance), the distance in centimeters decreased from baseline to 6-week follow-up, and then was sustained to 12-month follow-up. In summary, we report on a novel, never-reported technique using radiofrequency-assisted lipolysis with the BodyTite device to moderately improve breast ptosis. This modality affords a minimally invasive, effective method to improve mild to moderate breast ptosis with minimal scarring and high patient satisfaction.

Jacob G. Unger, M.D.

Maxwell Aesthetics

2020 21st Avenue South

Nashville, Tenn. 37212

drunger@maxwellaesthetics.com

REFERENCES

1. Reisman NR. Medico-legal issues in plastic surgery. In: Neligan PC, ed. *Plastic Surgery*. Vol. 1, 3rd ed. Philadelphia: Elsevier; 2013:92–103.
2. Tebbetts JB. Augmentation mastopexy. In: *Augmentation Mammoplasty*. Philadelphia: Elsevier; 2009:501–551.
3. Moltó-García R, Villaverde-Doménech ME, González-Alonso V, Ripoll-Orts F, Simon-Sanz E. Periareolar augmentation mastopexy: A new approach dealing with the cases as tuberosus breasts. *Indian J Plast Surg*. 2016;49:172–177.
4. Theodorou S, Chia C. Soft tissue contraction in body contouring with radiofrequency-assisted liposuction: A treatment gap solution. *Aesthet Surg J*. 2018;38:574–583.
5. Keramidas E, Rodopoulou S. Radiofrequency-assisted liposuction for neck and lower face adipodermal remodeling and contouring. *Plast Reconstr Surg Glob Open* 2016;4:e850.
6. Theodorou S, Chia C. Radiofrequency-assisted liposuction for arm contouring: Technique under local anesthesia. *Plast Reconstr Surg Glob Open* 2013;1:e37.
7. Chia CT, Theodorou SJ, Hoyos AE, Pitman GH. Radiofrequency-assisted liposuction compared with aggressive superficial, subdermal liposuction of the arms: A bilateral quantitative comparison. *Plast Reconstr Surg Glob Open* 2015;3:e459.
8. Dayan E, Chia C, Burns AJ, Theodorou S. Adjustable depth fractional radiofrequency combined with bipolar radiofrequency: A minimally invasive combination treatment for skin laxity. *Aesthet Surg J*. 2019;39(Suppl 3):S112–S119.
9. Cohen J. *Statistical Power Analysis for the Behavioral Sciences*. 2nd ed. Hillsdale, NJ: Erlbaum; 1988.