



Evaluation of a new diode laser for the treatment of lower extremity leg veins

Michael H. Gold MD | Julie Biron BSc | Whitney Sensing LPN, CCRP

Tennessee Clinical Research Center,
Nashville, Tennessee

Correspondence

Michael H. Gold, Tennessee Clinical
Research Center, Nashville, TN.
Email: mhgold@tnclinicalresearch.com

Summary

Introduction: Visible leg veins are a common cosmetic concern treated mostly by 1064 nm Nd:YAG laser that has become the chosen laser therapy for treating all leg veins up to 3 mm in size. The objective of the current prospective study was to evaluate the safety and efficacy of a new 1064 nm diode laser for leg veins and spider veins on the lower extremities.

Methods: A total of 15 female subjects seeking leg veins and spider veins treatment were recruited to this study. The treatment protocol included two treatment sessions 6 weeks apart and two follow-up visits at three and 6 months after the last diode laser treatment. Results were evaluated by photographs and an investigator classification of the treated vascular lesions appearance on five scores scale from 0 (normal) to 4 (severe).

Results: Treatment area photos demonstrated improvement in vascular lesions appearance. Average vascular lesions classification was reduced by approximately one score from baseline score of 2.9 (score 3 is moderate) to an average score 2 (mild) at the 3-month follow-up visit. This improved classification sustained also at 6-month follow-up visit, indicating the long-term effect of the treatment impact. No significant or unexpected adverse events were detected in any of the patients as a result of the treatments.

Conclusions: This study has demonstrated that the new 1064 nm diode laser is safe and effective for the treatment of leg vascular lesions on the lower extremities.

KEYWORDS

1064 nm diode laser, leg veins laser treatment, Nd:YAG laser

1 | INTRODUCTION

Visible veins on the lower extremities are a common cosmetic concern affecting mostly women but also men.¹ Leg vein therapy is one of the most commonly requested cosmetic procedures. Various laser systems are being widely used for the treatment of vascular skin lesions.²

The optimum laser wavelength depends on the type of leg vein that is being treated. Over the past 15 years, the 1064nm Neodymium-doped Yttrium Aluminium Garnet (Nd:YAG) laser has come into favor

as a mono modality therapy capable of treating all leg veins up to 3 or 4 mm in size.³ The 1064 nm Nd:YAG is safe in most skin types; thus, it is a popular first choice. The longer wavelength reaches deeper and larger veins, and combined with various cooling techniques, spares the epidermis and can safely and successfully treat lower extremity leg veins.³ Numerous clinical studies were conducted to evaluate the safety and efficacy of the 1064 nm Nd:YAG, using different pulse durations and fluences, looking for the optimal parameters.⁴⁻⁹

The Vasculaze is a 1064 nm diode laser designed for the treatment of leg vascular lesions. The objective of this prospective study



FIGURE 1 InMode Vasculaze Device

was to evaluate the safety and efficacy of Vasculaze 1064 nm diode laser applicator for the treatment of lower extremity leg and spider veins.

2 | METHODS

2.1 | Study design

The objective of this prospective, open label, single center study was to evaluate the safety and efficacy of the diode 1064 nm applicator (Vasculaze, InMode Ltd., Israel) for leg veins and spider veins treatment. 15 female subjects aged 18-60, seeking leg veins and spider veins treatment, were recruited for the study.

All subjects who participated in the study signed an informed consent that had been approved by an Institutional Review Board (IRB) and agreed to follow the treatment and follow-up schedule.

2.2 | Subject selection

Inclusion criteria included occurrence of leg veins of reticular, perforating and spider type (no varicosity) on thigh and/or calf. Patients with saphenous insufficiency, current or history of previous laser therapy or sclerotherapy, or any other treatment for veins in the designated treatment area were excluded from the study. In addition, those having any contraindication to laser treatment as specified in the device operator manual and study protocol were excluded from the study as well.

Information on medical history and demographics was gathered at baseline before treatment.

2.3 | Treatment

Study included two treatment sessions 6 weeks apart and two follow-up visits at 3 and 6 months after the last treatment. Treatments were conducted with the Vasculaze 1064 nm diode laser.

2.4 | The device

The Vasculaze device is a 1064 nm diode laser, emitting optical energy power for the treatment of vascular lesions, including angiomas, hemangiomas, telangiectasia, port wine stains, leg veins, and other benign vascular lesions. Vasculaze is intended to treat predominantly blue reticular leg veins at a diameter of 1-4 mm and depth of up to 5 mm, including perforating veins. Due to the relatively low absorption of 1064 nm in hemoglobin, 500-600 nm lasers or IPLs are a better choice to treat red telangiectasia <1 mm in diameter.

The Vasculaze device is comprised of a system console (platform), controller unit, diode driver, touch screen user interface, footswitch, and the designated hand piece. The diode laser operates in a fluence range of 40-300 J/cm², pulse width up to 100 ms, pulse repetition rate up to 1 Hz, spot size of 3 × 4 mm², and a cooling mechanism that uses a sapphire light guide and an enveloping gold-coated metal cooled to 7°C or to 12°C, according to user choice.

The device and handpiece are presented in Figures 1 and 2, respectively.

2.5 | Evaluations

Treatment areas were photographed in a reproducible manner before and immediately after each treatment and at the follow-up visits 3 and 6 months after last treatment.

Efficacy was evaluated by the reduction of apparent veins at follow-up visits comparing to baseline. The investigator classified the treated vascular lesions before each treatment and at follow-up visits according to the following vascular lesions classification scale, as follows: None (0) = Normal; Trace (1) = Barely visible and localized; Mild (2) = Somewhat visible and diffuse; Moderate (3) = Visible and diffuse; Severe (4) = Extremely visible and dense.



FIGURE 2 InMode Vasculaze Handpiece

Safety was evaluated by observation and assessment of subjects' reaction every visit after each treatment and at follow-up visits. Any minor or major adverse events were recorded.

Subjects were asked to rate discomfort, using visual analog pain scale (VAS) from 0 (no pain) to 10 (intolerable pain) immediately after each treatment session.

3 | RESULTS

A total of 15 women were included in the study with an average age of 52.8 (range 39-58), of Fitzpatrick skin types II-IV. All subjects attended the two treatment visits and the 3-month follow-up visit. Fourteen out of 15 subjects attended the 6-month follow-up visit.

Treatment area photos demonstrated improvement in vascular lesions appearance immediately, between treatments and at follow-up visits.

Improvement was noticed immediately after each one of the two treatments. Immediate results as well as results shown already after one treatment (noticeable when comparing the photo before second treatment to baseline photo) are demonstrated in the two sets of photos below (Figures 3 and 4).

Examples of 3- and 6-month follow-up results are demonstrated in the sets of photos below (Figures 5-7). Comparing follow-up to

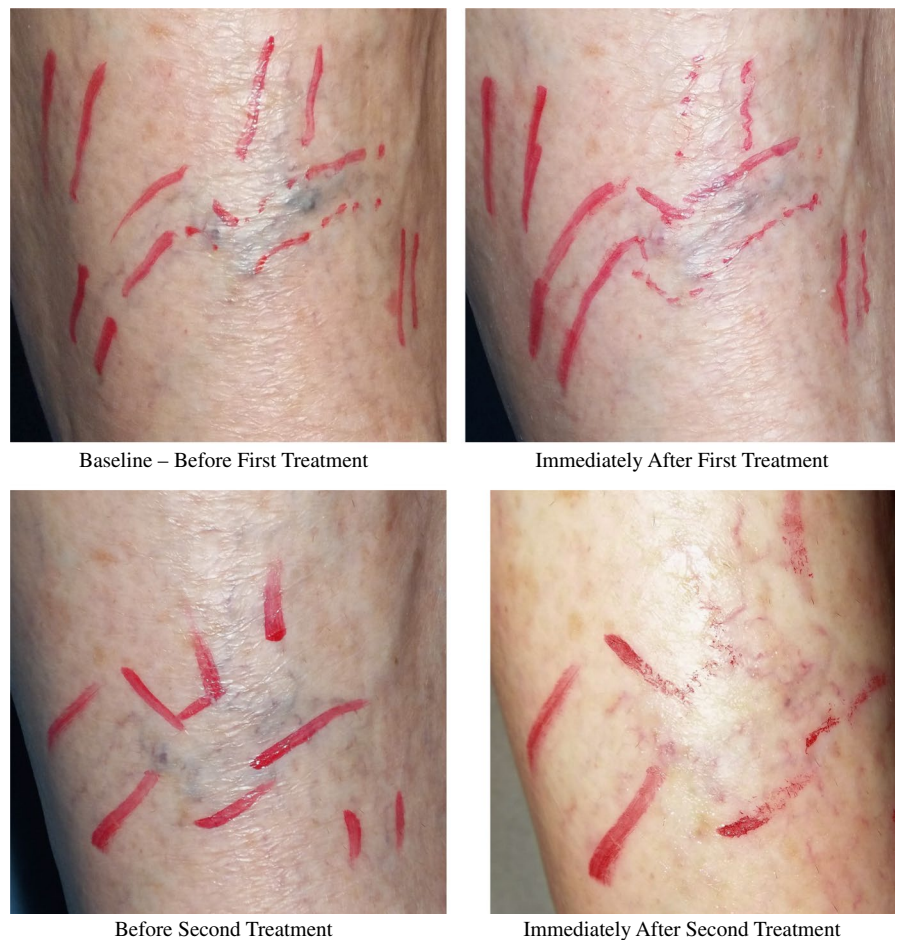


FIGURE 3 A sample case demonstrating immediate treatment results. Before (up, left) and immediately after first treatment (up, right) and before (bottom, left) and immediately after second treatment (bottom, right).
Baseline-Before First Treatment.
Immediately After First Treatment

Before Second Treatment

Immediately After Second Treatment

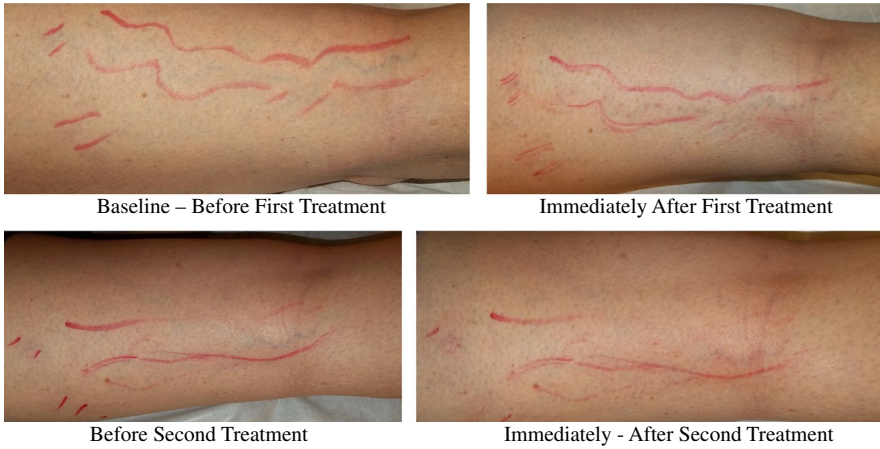

FIGURE 4 A sample case demonstrating immediate treatment results. Before (up, left) and immediately after first treatment (up, right) and before (bottom, left) and immediately after second treatment (bottom, right)

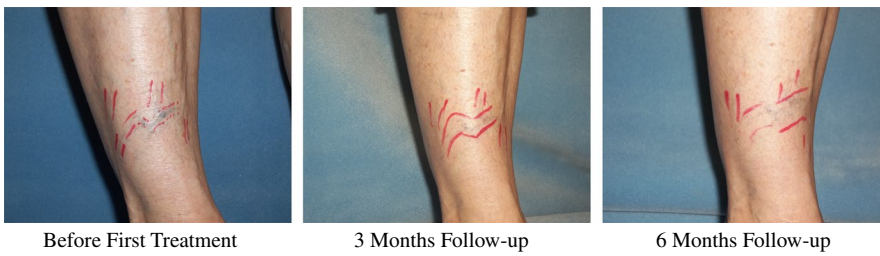

FIGURE 5 A sample case (same patient as in Figure 3) demonstrating 3- and 6-mo follow-up results. Before (left), at 3-mo follow-up (middle) and at 6-mo follow-up (right)

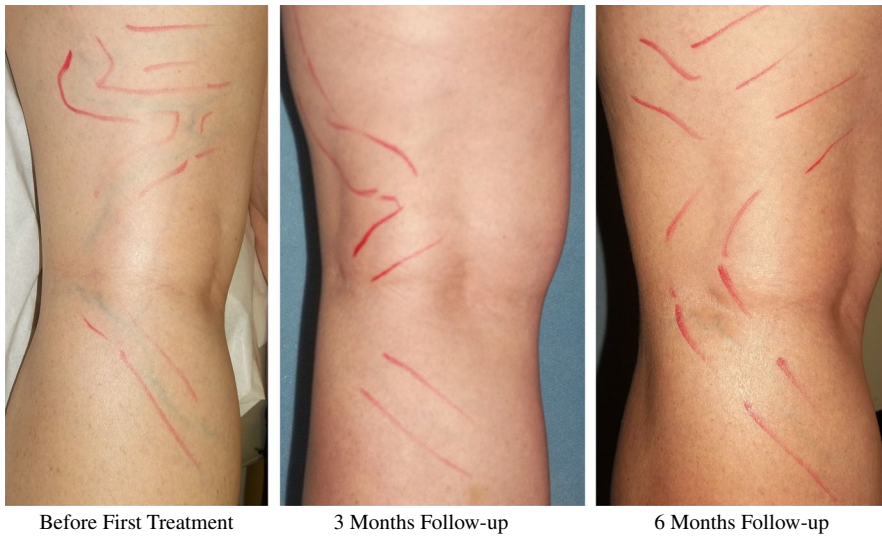

FIGURE 6 A sample case demonstrating 3- and 6-mo follow-up results. Before (left), at 3-mo follow-up (middle) and at 6-mo follow-up (right)

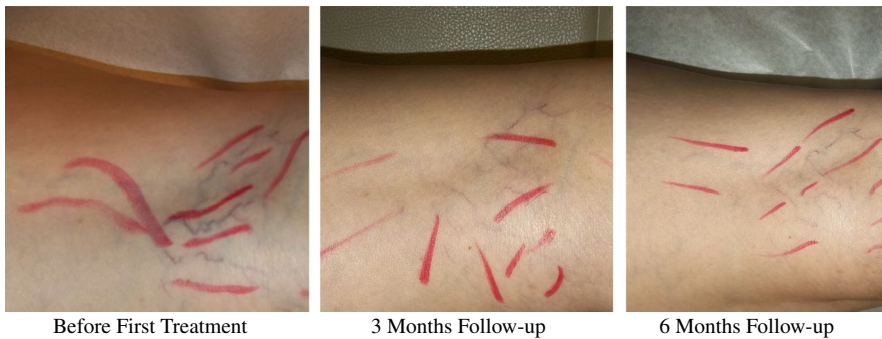

FIGURE 7 A sample case demonstrating 3- and 6-mo follow-up results. Before (left), at 3-mo follow-up (middle) and at 6-mo follow-up (right)

baseline photos show that improvement in vascular lesions appearance has sustained during the study time frame.

Vascular lesions classification by the investigator supported the visual evidence of improvement in vascular lesions appearance at 3 and 6 months after two treatments. Average vascular lesions classification was reduced by approximately 1 score from baseline score of 2.9 (score 3 is moderate) to an average score 2 (mild) at the 3-month follow-up visit.

This improved classification sustained also at 6-month follow-up visit, indicating the long-term effect of the treatment impact.

Average score of discomfort (VAS) collected from all subjects in both treatments was 5.8.

No significant or unexpected adverse events were detected in any of the patients as a result of the treatments.

4 | DISCUSSION

The new diode 1064 nm device evaluated in the current study, similarly to the commonly used 1064 nm Nd:YAG lasers, is consisting with the use of laser energy at the optimal wavelength for vessel absorbance. Laser energy is delivered through a hand piece applicator to the skin for treatment of vascular and benign lesions while sparing the epidermis. The laser is directed at the skin and the energy is absorbed. The mechanism of action employed is based on specific targeting of hemoglobin by the 1064 nm laser beam.

Published articles on 1064 nm Nd:YAG lasers for the treatment of vascular lesions demonstrate that this wavelength is a popular choice as it works best for vessels up to 3 or 4 mm in diameter and is safe with most skin types.²

In addition, this wavelength was found to be the most effective and safe for deep leg veins compared to 810 nm or 755 nm¹⁰ and is similarly effective as sclerotherapy, which is another well accepted technology.¹¹

The performance specifications of the diode 1064 nm device including wavelength, fluence range, pulse width, and spot size are within the range of specifications of the commonly used Nd:YAG lasers.^{3-9,12} It has a small spot size, effective cooling, and an option for high fluences—all are specifications that contribute to efficacy. This diode 1064 nm is unique to the 1064 nm Nd:YAG lasers family and can be part of a modular platform device for one's clinic.

This study's results have clearly demonstrated improvement in treated vascular lesions at 3- and 6-month follow-up periods. No adverse events were detected during the study period. It is thus concluded that the Vasculaze-the 1064 nm diode laser is safe and effective for the treatment of leg veins and spider veins on the lower extremities.

ACKNOWLEDGMENTS

Dr. Gold is a consultant and provides clinical research for InMode.

ORCID

Michael H. Gold  <https://orcid.org/0000-0002-5183-5433>

REFERENCES

- Engel A, Johnson MI, Haynes SG. Health effects of sunlight exposure in the United States: results from the first national health and nutrition examination survey, 1971-1974. *Arch Dermatol.* 1988;124:72-79.
- Mccoppin H, Hovenic WW, Wheeland RG. Laser treatment of superficial leg veins: a review. *Dermatol Surg.* 2011;37:729-741.
- Kunishige JH, Goldberg LH, Friedman PM. Laser therapy for leg veins. *Clin Dermatol.* 2007;25:454-461.
- Omura NE, Dover JS, Arndt KA, Kauvar A. Treatment of reticular leg veins with a 1064 nm long-pulsed Nd:YAG laser. *J Am Acad Dermatol.* 2003;48:76-81.
- Rogachefsky AS, Silapunt S, Goldberg DJ. Nd:YAG Laser (1064 nm) irradiation for lower extremity telangiectases and small reticular veins: efficacy as measured by vessel color and size. *Dermatol Surg.* 2002;28:220-225.
- Sadick NS. Long-term results with a multiple synchronized-pulse 1064 nm Nd:YAG laser for the treatment of leg venulectasias and reticular veins. *Dermatol Surg.* 2001;27:365-369.
- Major A, Brazzini B, Campolmi P, et al. Nd:YAG 1064 nm laser in the treatment of facial and leg telangiectasias. *JEADV.* 2001;15:559-565.
- Trelles MA, Allones I, Martín-Vázquez MJ, Trelles O, Vélez M, Mordon S. Pulse Nd:YAG laser for treatment of leg veins in 40 patients with assessments at 6 and 12 months. *Lasers Surg Med.* 2004;35:68-76.
- Civas E, Koc E, Aksoy B, Aksoy HM. Clinical experience in the treatment of different vascular lesions using a neodymium-doped yttrium aluminium garnet laser. *Dermatol Surg.* 2009;35:1933-1941.
- Eremia S, Li C, UmarSH. A side-by-side comparative study of 1064 nm Nd:YAG, 810 nm diode and 755 nm alexandrite lasers for treatment of 0.3-3 mm leg veins. *Dermatol Surg.* 2002;28:224-230.
- Levy JL, Elbahr C, Jouve E, Mordon S. Comparison and sequential study of long pulsed Nd:YAG 1,064 nm laser and sclerotherapy in leg telangiectasias treatment. *Lasers Surg Med.* 2004;34:273-276.
- Baumler W, Ulrich H, hartl et al. Optimal parameters for the treatment of leg veins using Nd:YAG lasers at 1064nm. *Br J Dermatol.* 2006;155:364-371.

How to cite this article: Gold MH, Biron J, Sensing W. Evaluation of a new diode laser for the treatment of lower extremity leg veins. *J Cosmet Dermatol.* 2019;18:773-777. <https://doi.org/10.1111/jocd.12923>