

*Another  
Successful*  
**Case  
Study**  
*Made  
Possible by*



# Do We Need a Membrane or Not?

## Case Notes

Patient presents with failing over-retained deciduous molar. Tooth was extracted and immediately replaced with Ritter Spiral implant. Bone graft and PRGF Fibrin without a membrane.

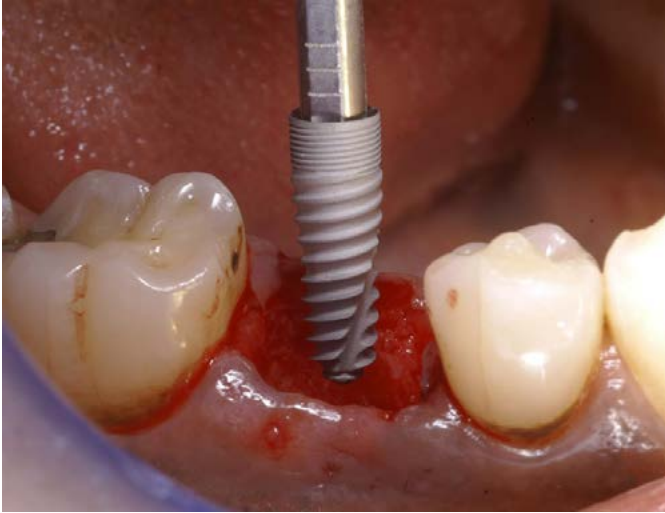
There has been much discussion about whether or not membranes are needed? Thoughts?

-Dr. Salama

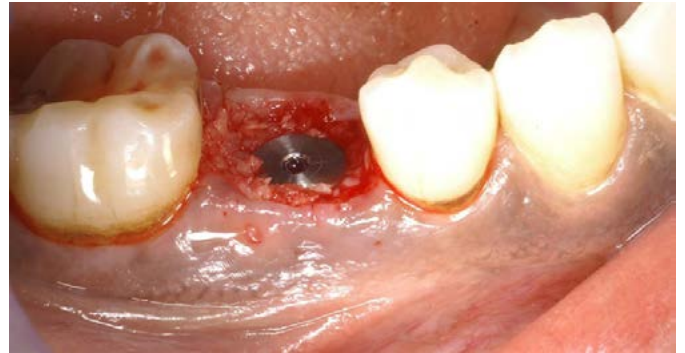

# Case Photos

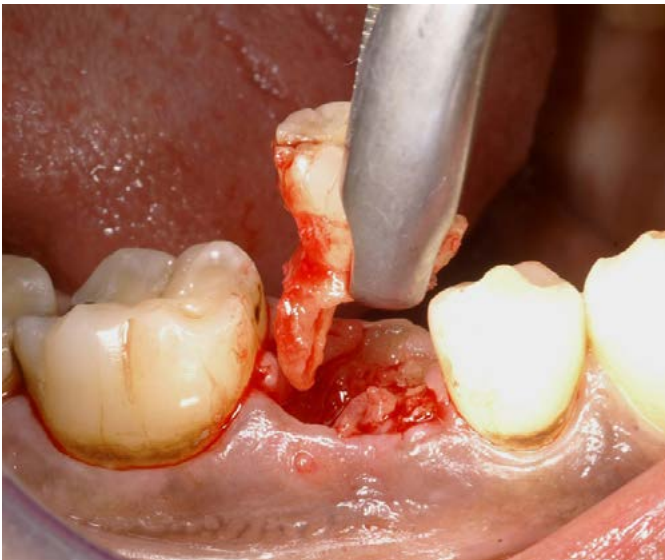
Immediate Ritter Implant



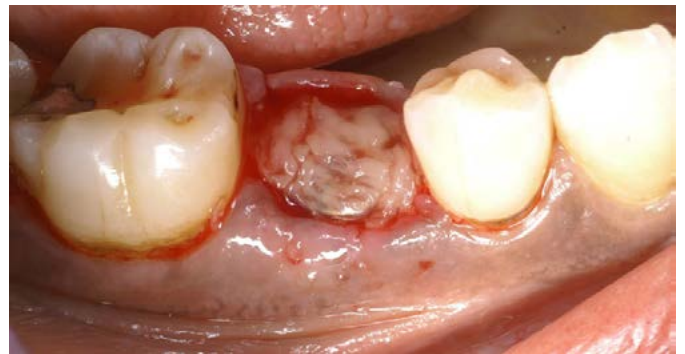Flared healing abutment and BG



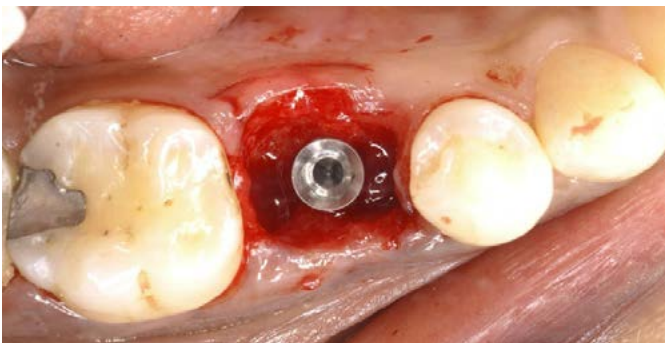
Extraction of tooth



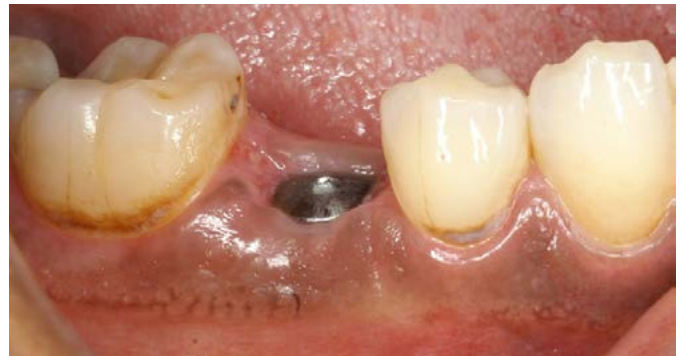PRGF fibrin seal



Implant in position

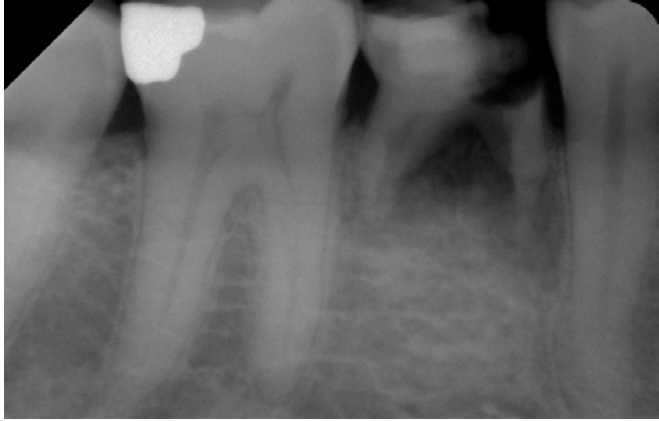

2 weeks healing

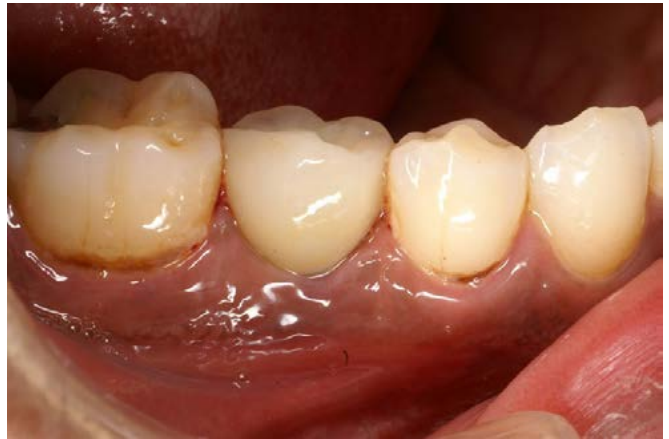

# Case Photos

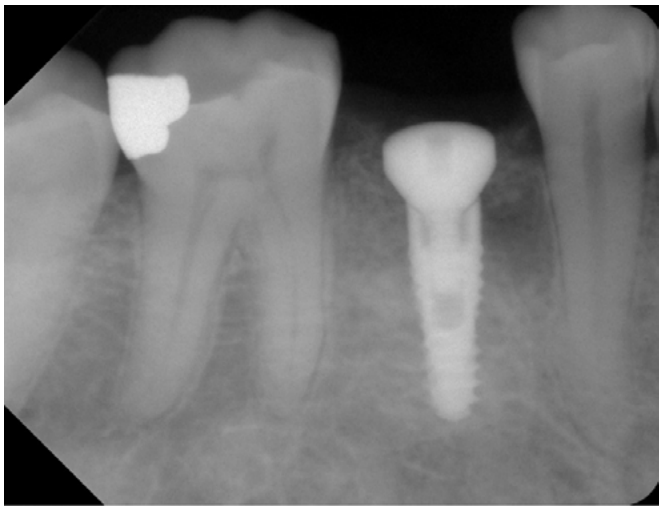
PA pre op



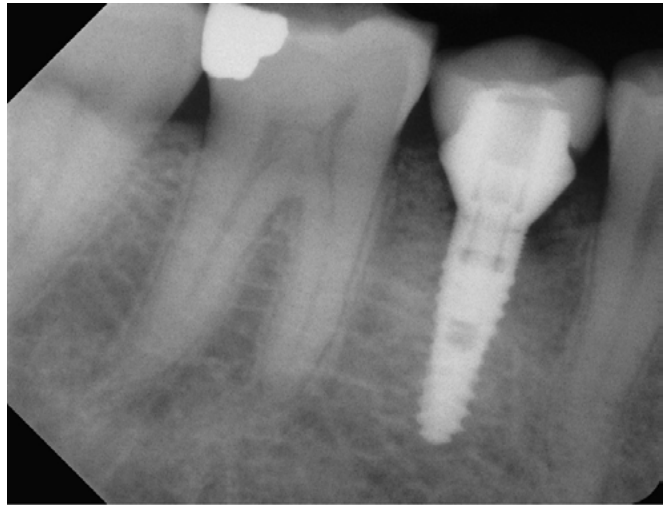
Crown



PA post op



PA



Clinical View

