

Osteoarthritis and Cartilage



Oral administration of undenatured native chicken type II collagen (UC-II) diminished deterioration of articular cartilage in a rat model of osteoarthritis (OA)



C.M. Bagi [†]*, E.R. Berryman [†], S. Teo [‡], N.E. Lane [§]

[†] Pfizer R&D, Comparative Medicine, Global Science & Technology, Groton, CT, USA

[‡] Pfizer Consumer Healthcare, Madison, NJ, USA

[§] Rheumatology and Aging Research, University of California at Davis School of Medicine, USA

ARTICLE INFO

Article history:

Received 11 February 2017

Accepted 30 August 2017

Keywords:

Osteoarthritis

Undenatured native chicken type II collagen

Partial medial meniscectomy tear

Dynamic weight bearing

Micro computed tomography

Histology

SUMMARY

Objective: The aim of this study was to determine the ability of undenatured native chicken type II collagen (UC-II) to prevent excessive articular cartilage deterioration in a rat model of osteoarthritis (OA). **Methods:** Twenty male rats were subjected to partial medial meniscectomy tear (PMMT) surgery to induce OA. Immediately after the surgery 10 rats received vehicle and another 10 rats oral daily dose of UC-II at 0.66 mg/kg for a period of 8 weeks. In addition 10 naïve rats were used as an intact control and another 10 rats received sham surgery. Study endpoints included a weight-bearing capacity of front and hind legs, serum biomarkers of bone and cartilage metabolism, analyses of subchondral and cancellous bone at the tibial epiphysis and metaphysis, and cartilage pathology at the medial tibial plateau using histological methods.

Results: PMMT surgery produced moderate OA at the medial tibial plateau. Specifically, the deterioration of articular cartilage negatively impacted the weight bearing capacity of the operated limb. Immediate treatment with the UC-II preserved the weight-bearing capacity of the injured leg, preserved integrity of the cancellous bone at tibial metaphysis and limited the excessive osteophyte formation and deterioration of articular cartilage.

Conclusion: Study results demonstrate that a clinically relevant daily dose of UC-II when applied immediately after injury can improve the mechanical function of the injured knee and prevent excessive deterioration of articular cartilage.

© 2017 The Author(s). Published by Elsevier Ltd on behalf of Osteoarthritis Research Society International. This is an open access article under the CC BY-NC-ND license (<http://creativecommons.org/licenses/by-nc-nd/4.0/>).

Introduction

Osteoarthritis (OA) is a complex multifactorial disease process involving over time all of the tissues within and surrounding the synovial lined joints. Progression of the disease leads to disability associated with joint pain and dysfunction^{1,2}. Epidemiologic studies have determined that risk factors for the progression of OA include aging, over- or non-physiological loads, obesity, trauma, hormonal disorders or a combination of several factors. While the exact etiology of OA is not yet known, injury to the articular

cartilage over time results in changes in both the chondrocyte and synoviocyte metabolism such that inflammatory cytokines that are produced impair the chondrocytes ability to restore the cartilage matrix³. The search for effective therapies that attenuate joint degradation, improve joint flexibility and relieve joint pain has been challenging and current therapies to treat OA include acetaminophen and non-steroidal anti-inflammatory drugs (NSAIDs)⁴.

Because collagen is the most prevalent component of the solid phase of articular cartilage, collagen supplementation has been considered a key treatment option to prevent damage to the articular cartilage over time and support the healing process following the onset of OA. Several hypotheses have been proposed to elucidate the exact mechanisms by which collagen derivatives improve the health of the articular cartilage⁵. Currently, glucosamine and chondroitin are the two most commonly used nutraceuticals that provide medicinal, therapeutic, and health benefits to arthritic patients^{6,7}. For example, treatment with collagen

* Address correspondence and reprint requests to: C.M. Bagi, Pfizer Global Research & Development, Global Science & Technology, 100 Eastern Point Road MS 8274-1359, Groton, 06340, CT, USA.

E-mail addresses: cedo.bagi@pfizer.com (C.M. Bagi), edwin.r.berryman@pfizer.com (E.R. Berryman), steve.teo@pfizer.com (S. Teo), nalane@ucdavis.edu (N.E. Lane).

derivatives has been proposed to provide an adequate supply of nutrients required for cartilage repair and maintenance^{8,9}, improve and preserve the quality of the subchondral bone^{10,11}, and maintain the overall health of articular cartilage and subchondral bone^{12,13}. Over the past several years, a novel nutraceutical undenatured type II collagen (UC-II) from chicken sternum cartilage has been studied in knee OA subjects^{14–16}. *In vivo* animal studies have reported that UC-II acts via specific regulatory T cells (Tregs) in the gut that migrate and concentrate in areas of inflammation upon stimulation, where they modulate local immune responses in an antigen-specific manner^{17,18}. Irrespective of the actual mechanism of action, collagen derivatives seem to improve the health of the articular cartilage and are safe for patients and therefore, should be considered for the prevention or treatment of OA as a sole therapy or in combination with other drugs^{15,19}. UC-II is derived from chicken sternum cartilage and is being marketed as a powdered, shelf-stable ingredient that at daily dose of 40 mg demonstrated clinical benefit by improving joint comfort, flexibility and mobility in OA patients.^{20,21}

Commonly used method to induce OA in rodents is unilateral medial meniscal tear (MMT) method resulting in rapid progression of degenerative changes in the articular cartilage of the medial tibial plateau including fibrillation of articular cartilage, osteophyte formation and a loss of chondrocytes^{22,23}. The medial meniscotibial ligament anchors the medial meniscus to the medial tibial plateau to ensure high congruency between articular structures and the transfer of weight-bearing loads during locomotion. Because cartilage degeneration develops rather rapidly in rats, evaluating drugs aimed to protect articular cartilage using the MMT model is challenging. The partial medial meniscectomy tear (PMMT) method is deemed less invasive than the complete medial meniscectomy model and is thus considered a more suitable model to test the ability of UC-II products to prevent the deterioration of cartilage degeneration and improve the healing of damaged articular cartilage.²⁴

The present study tested the ability of undenatured native chicken type II collagen administered orally at the time of cartilage injury imposed by PMMT to prevent the excessive deterioration and improve the healing of articular cartilage.

Method

Test article

UC-II (InterHealth, Benicia, CA) consists of undenatured native chicken type II collagen (collagen 263.0 mg/g, hydroxyproline 32.9 mg/g). UC-II was manufactured from chicken sternum cartilage in a GMP-certified facility using a patented, low-temperature manufacturing process that ensures a particular level of UC-II collagen. UC-II was formulated in 0.5% methyl cellulose suspension and administered orally at 0.66 mg/kg/day for a period of 8 weeks. The rat 0.66 mg/kg/day UC-II dose was chosen because it is equivalent to the 40 mg/day UC-II used in clinical studies for a 60 kg human. The vehicle (0.5% methyl cellulose) was dosed orally at 5 ml/kg/day 7 days per week.

Animals and management

Male, 4 months old Lewis rats (Charles River Laboratories, Portage, MI) weighing 350 g at the beginning of the experiments were used in this study. All *in vivo* procedures were approved by the Institutional Animal Care and Use Committee (IACUC) and were performed in accordance with the US National Institutes of Health (NIH) Publication No. 85–23, revised 1996²⁵. The rats were pair housed in a temperature- and humidity-controlled room on a

regular 12 h light/dark cycle. Irradiated LabDiet™ 5053 (Purina, Richmond, IN) and water were provided *ad libitum*. The animals were acclimated for 1 week and were allocated to study groups based on their body weight the day before surgery. A group of 10 naïve rats were used as an intact control (Naïve), and another 10 rats received sham surgery (Sham). Additionally, 20 rats received the PMMT surgery and were allocated to receive vehicle treatment (PMMT/veh) or a UC-II (PMMT/UC-II) treatment. The ARRIVE guidelines was used to ensure the rigor of study conduct and reporting of the data.

Surgery

Surgeries are performed in a dedicated rodent surgical facility at Pfizer consisting of an animal preparation room and recovery room, surgeon preparation room and a surgical suite. To minimize variations, only one surgical research specialist with extensive experience in performing the PMMT surgery was certified by the Academy of Surgical Research and have had his surgical skills and knowledge assessed by a designated subject matter expert (Global Trainer or Global Surgeon) approved to perform surgery. The rats were induced and maintained under anesthesia using isoflurane. One dose each of carprofen (Pfizer Animal Health, Florham Park, NJ) and sustained-release buprenorphine (Zoopharm, Windsor, CO) were administered prior to surgery to ensure analgesia. Rats in the surgery groups were subjected to a partial medial meniscal tear (PMMT) surgery²⁴. Briefly, the medial meniscus was freed from its attachments to the margin of the medial tibial plateau prior to grasping the meniscus with forceps and transecting one-third of the medial collateral ligament and medial meniscus. In the sham surgery rats, the medial meniscus was visualized but not transected. The surgical incisions were closed in two layers using absorbable sutures.

Body weight, tissue collection and serum analyses

The body weight was recorded twice weekly throughout the study. At the end of the study rats were euthanized and the entire right hind limb was harvested and carefully cleaned of the soft tissue. The limbs were wrapped in saline-soaked gauze and frozen at -20°C for the *ex vivo* imaging and histological analyses of the tibial articular cartilage and bone. Blood was collected 8 weeks after surgery by jugular venipuncture under isoflurane anesthesia. The serum was stored at -20°C and used to run the standard chemistry panel and biomarkers of bone and cartilage metabolism²⁶ (see [Supplemental Material for details](#)).

Dynamic weight bearing (DWB)

DWB measurements were obtained before surgery, 6 days after surgery, 4 weeks after surgery and before euthanasia to assess the effects of surgery on the weight-bearing capacity of the hind and front legs. The DWB system (Bioseb, software 1.3.; Boulogne, France) is non-invasive method for measuring the weight and surface area of all four feet in a freely moving animal^{27,28}. Zone parameters were set for the analysis as follows: ≥ 4 g for one sensor or a minimum of three adjacent sensors ≥ 2 g (in order to be considered a valid zone). For each time segment that was stable for more than one second, zones that meet the above criteria were validated and assigned as either right or left and front or rear. A mean value for the weight and area of each zone were calculated over the entire testing period, based on the length of time of each validated segment. For each testing period, the animals were placed into the chamber and allowed 20–30 s to explore prior to data collection. The following parameters were measured over a 3-min

period: body weight (g), percentage of weight (% weight) and surface area (mm^2) placed on the front left and right leg, both front legs combined, rear left and right leg and both rear legs combined.

Radiology

Following necropsy all knee joints were X-rayed with a Faxitron Model MX20 specimen scanner (Faxitron Bioptics LLC, Tucson, AZ) using an exposure time of 12–18 s at 31–35 kV. The radiographic images were used to inspect the bone samples for the presence of possible fractures or other bone abnormalities.

Micro-computed tomography (μCT)

The operated right knee joint was subjected to μCT utilizing a MicroCT 100[®] computed tomography system (Scanco Medical, Bassersdorf, Switzerland) to obtain a scout 3D image of the knee. The μCT images were used to ensure that the samples were reproducibly scanned and that the same region of interest (ROI) at the proximal tibial epiphysis and metaphysis for each specimen was analyzed²⁹.

The cancellous bone compartment of the metaphysis was analyzed 1 mm below the growth plate and extended 3 mm distally to include the metaphyseal secondary spongiosa. The cancellous bone was evaluated as previously described. In short, an ROI was drawn on 100 consecutive slices with a thickness of 1.0 mm that best represented the central segment of the tibia²⁸. The cancellous bone parameters included bone mineral density, tissue volume (bone and bone marrow), bone volume, bone volume/tissue volume ratio, bone surface, bone surface/bone volume, trabecular number, trabecular thickness, trabecular separation, connectivity diameter, and structural model index.

For subchondral bone analysis a 2.0 mm \times 0.5 mm ROI was drawn on the pre-contrast images to include the cortical and cancellous subchondral bone underlying the articular cartilage as described earlier²⁸ (for details see [Supplemental Material](#)).

Histopathology

After the knee joints were imaged with μCT , they were shipped to HistoTox Labs, Inc. (Boulder, CO, USA), for tissue processing. The knee joints were placed in SurgiPath Decalcifier I solution (Graylake, IL, USA) for 10 days. Following decalcification, the knee joints were transected in the frontal plane to yield two approximately equal portions, embedded in paraffin, and serially sectioned at ~ 200 μm intervals into 5- μm -thick sections for staining. The slides were stained with hematoxylin and eosin (H&E) for general evaluation; toluidine blue (T-blue) for evaluation of the cartilage, safranin O was used to evaluate structural damage to the cartilage, and Cathepsin K was used to count number of dark-stained osteoclast below the growth plate on two consecutive slices. Only the histology of the medial aspect of the joint was analyzed because this region is the primary site of degeneration for this animal model. Slides were labeled in a coded manner. Two independent readers without knowledge of the treatment categories independently evaluated the histology. Results from the two slides per animal and from both readers were averaged for each section, and the average scores for gradable sections were then averaged for each rat. The following parameters were determined: cartilage degeneration score, osteophyte size, thickness of the cartilage matrix, cartilage matrix loss width, total cartilage degeneration width and significant cartilage degeneration width on four sections (two H&E and two T-blue) using an ocular micrometer as previously suggested³⁰. The progression of cartilage matrix loss was measured along the surface (0% depth – where the cartilage on

either side has intact superficial cartilage), the tidemark (100% depth – where the cartilage on either side shows complete loss of cartilage) and at the level of the mid-zone (50% depth between surface and tidemark) as recommended earlier³⁰. The total cartilage degeneration with represents the total extent of the tibial plateau affected by any type of degeneration such as total loss or just fibrillation of matrix with or without chondrocyte death, thus this area is regularly larger than total cartilage loss parameter.

Statistical analysis

GraphPad Prism v.5.00 for Windows (GraphPad Software, USA, <http://www.graphpad.com>) was used for the statistical analysis. Data was expressed as mean \pm 95% confidence interval where $n = 10$. Shapiro–Wilk test was used to test the normality of the data. One-way ANOVA followed by Dunnett's multiple-comparison post-test was performed for the comparison of group mean differences against the Naïve group of rats. Student's *t* test was done for unpaired comparison. Statistical significance was considered at $P \leq 0.05$.

Results

Animals and serum assays

After a transient loss of body weight due to sham-surgery and PMMT surgery, the body weight of all rats enrolled in the study increased by approximately 10% during the course of the study [Fig. 1(A)]. Rats in the PMMT/veh and PMMT/UC-II groups developed OA, as evidenced by X-ray, μCT and histology. Surgery or treatment with vehicle and UC-II did not affect the serum chemistry parameters or biomarkers of bone and cartilage metabolism, although the rats from the PMMT/veh group exhibited the highest level of cartilage degradation marker CTX-II ($P < 0.05$ vs Naïve and Sham), whereas the PMMT rats treated with UC-II exhibited significantly ($P < 0.05$) lower CTX-II values compared to PMMT/veh controls (Table 1, [Supplemental Material](#)).

DWB

All operated rats shifted weight bearing toward the front legs in order to reduce the weight bearing on the operated limb. The weight-bearing capacity of the operated right hind leg was significantly ($P < 0.05$) lower in PMMT/veh rats than in rats in the Naïve group during the entire study, and significantly ($P < 0.05$) lower relative to Sham and PMMT/UC-II rats at the end of the study [Fig. 1(B)–(D)].

Radiology

The radiological appearance of the right knee did not differ between the Naïve and Sham rats. Osteophytes were evident on the 2D images in all PMMT/veh and all PMMT/UC-II animals. Rats in the PMMT/veh group exhibited less cancellous bone at the proximal tibial metaphysis relative to rats in Naïve, Sham and PMMT/UC-II group (Fig. 2).

μCT evaluation

Bone parameters of the cancellous bone (secondary spongiosa) at the proximal tibial metaphysis were affected by the PMMT surgery. PMMT surgery in the vehicle treated rats resulted in slightly lower bone mineral density (BMD), bone volume and trabecular number, and higher trabecular separation parameter relative to Naïve, Sham and PMMT/UC-II treated rats, although the change was

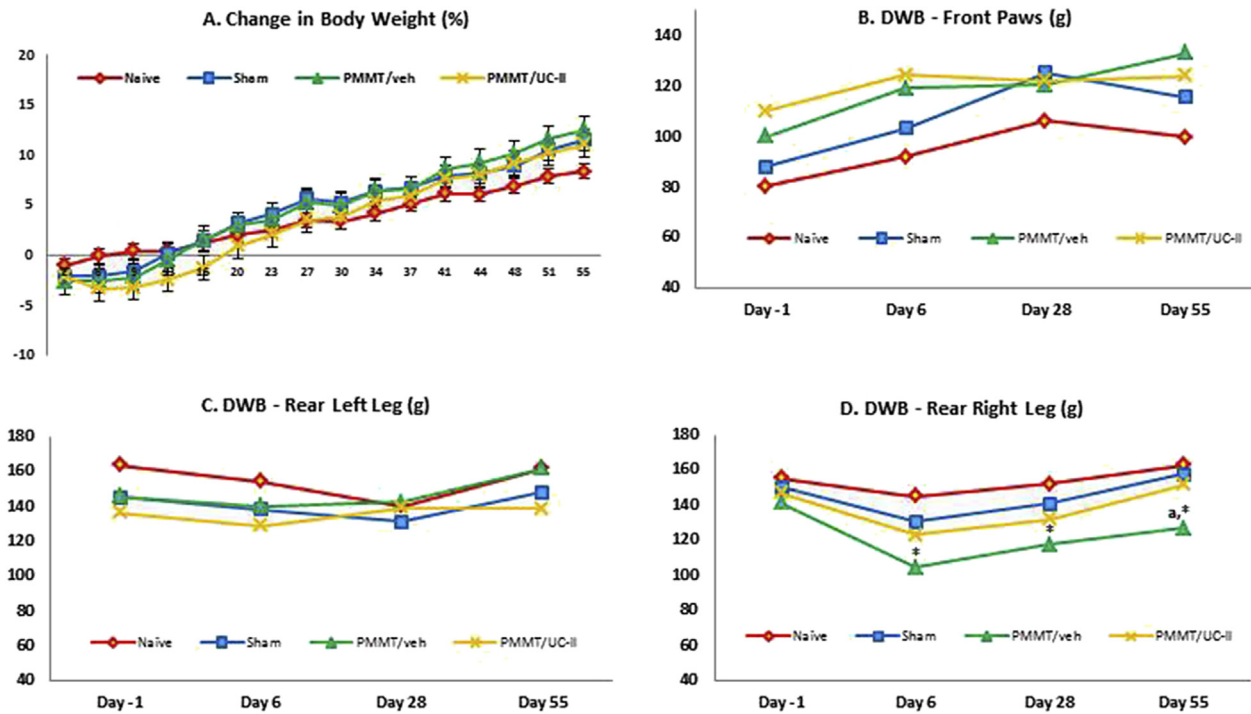


Fig. 1. A shows percent change in the body weight throughout the experiment. (B)–(D) show the change in the weight-bearing capacity and distribution of body weight placed on the front paws (B), rear left leg (C) and the rear right leg (D) at different time points during the 8-week experiment. Rats in the PMMT group showed a decreased weight-bearing capacity of the operated right hind leg relative to control groups and rats treated with the UC-II. * $P < 0.05$ vs Naive; ^a $P < 0.05$ vs Sham and UC-II.

not significant (Fig. 2). In addition, Cathepsin K histochemistry showed more robust accumulation of the osteoclasts in the primary spongiosa below the growth plate cartilage of PMMT/veh rats relative to all other study groups which also indicate increased bone resorption and supports the μ CT data (Fig. 3).

The subchondral bone parameters (bone area, bone volume and BMD) did not significantly differ between groups (Table 2, Supplemental Material). However, not statistically significant increase in the bone volume and BV/TV ratio indicated a mild thickening of the cortical layer in Zones 1 and 2 which is also visible in the 3D images of the tibial epiphysis of PMMT/veh and PMMT/UC-II rats. Additionally, osteophytes were clearly visible in both PMMT/veh and PMMT/UC-II rats, although their sizes varied (Fig. 4).

Cartilage damage and osteophytes were not evident in Naive and Sham animals. However, significant articular cartilage damage was present in PMMT/veh rats relative to rats in Naive and Sham group. Cartilage damage was less severe in PMMT/UC-II treated rats relative to Naive and Sham controls, but also comparing to PMMT/veh group. In addition, the osteophytes in Zone 1 were significantly smaller in size in PMMT/UC-II rats compared to PMMT/veh rats (Fig. 5).

Cartilage histology

The thickness of the articular cartilage was similar in Naive and Sham rats. PMMT/veh and PMMT/UC-II rats had damaged articular cartilage, with thickening of the cartilage in Zone 1 and a loss of cartilage matrix in Zone 2, but relatively intact cartilage in Zone 3 (Fig. 6). The 0.66 mg/kg dose of UC-II showed a modest effect in reducing damage to the cartilage as evidenced by less cartilage thickening in Zones 1, slightly thicker cartilage layer in Zone 2 and less variability in cartilage thickness in Zone 3. Also, rats in PMMT/UC-II group exhibited fewer fibrillations and less cartilage debris in

the articular space relative to PMMT/veh rats (Fig. 6). In general, animals treated with the UC-II showed less variability in cartilage damage and better consolidated cartilage in Zones 1 and 3 relative to vehicle treated PMMT rats.

Loss of articular cartilage width was not evident in Naive and Sham rats. However, width of articular cartilage loss was significantly lower in PMMT/veh rats relative to controls. Dosing with UC-II reduced cartilage damage in PMMT rats; however the efficacy of UC-II varied between animals (Fig. 7).

A loss of articular cartilage was not evident in the Naive and Sham rats. As expected, articular cartilage loss in PMMT/veh rats was statistically significant relative to Naive and Sham rats, and dosing of PMMT rats with UC-II attenuated this loss compared with the loss observed in the PMMT/veh rats not given the UC-II (Fig. 8).

Overall, the histological evaluation demonstrated that rats developed had PMMT-associated deterioration of their knee cartilage. Daily administration of UC-II reduced this PMMT-associated damage.

Discussion

This study was undertaken to assess the capacity of a UC-II to prevent the excessive deterioration of articular cartilage or to accelerate the recovery process following partial meniscectomy. The PMMT surgery results in the fractional displacement of the medial meniscus leading to shifts of the weight-bearing loads and to cartilage damage^{22,23}.

In our study, surgery resulted in transient decreases in body weight due to stress and postoperative pain. The overall increase in body weight was equal among all study animals, totaling 10% at the end of the 8-week study. Whereas the total weight bearing imposed on the rear legs in all rats slightly increased over time as the rats gained weight, the weight-bearing load placed on the right hind leg was lower in the PMMT rats relative to Naive and Sham

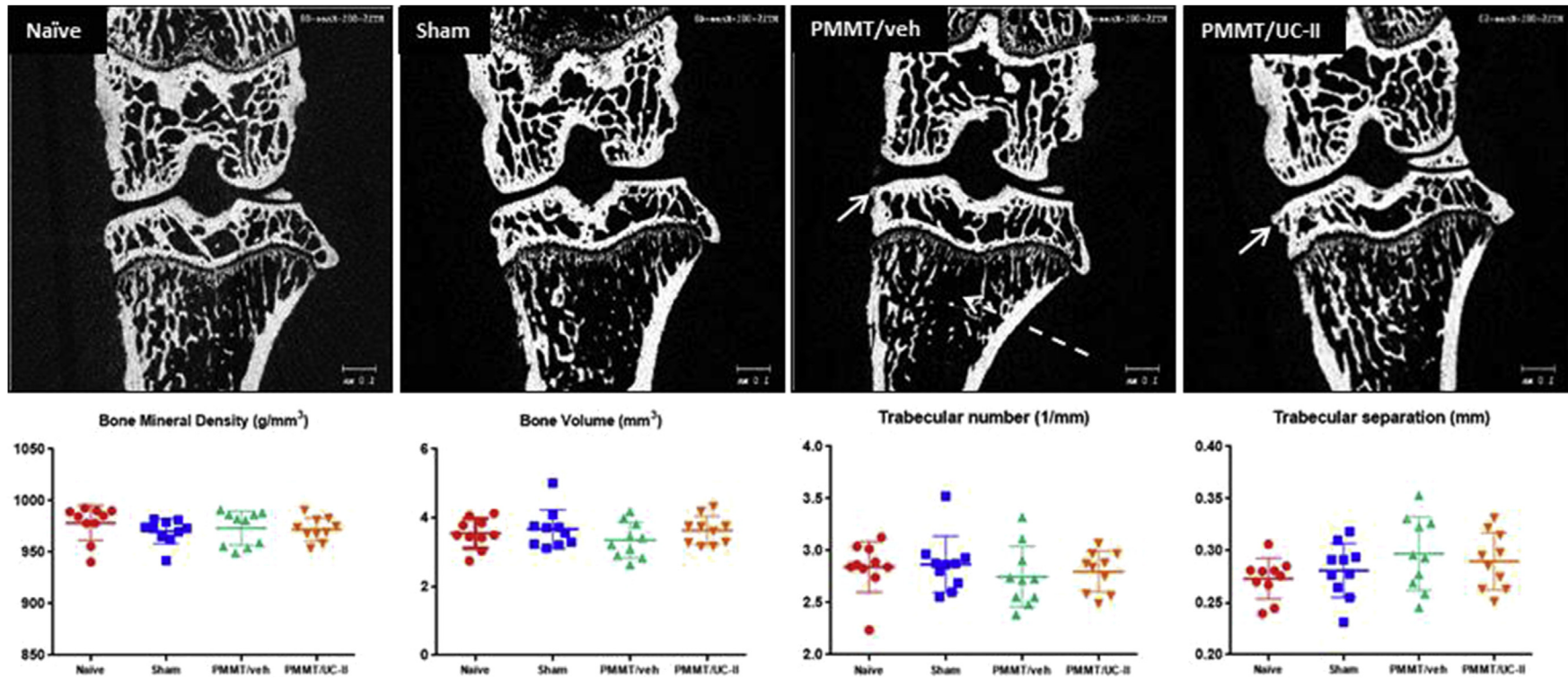


Fig. 2. Top row shows the 2D μ CT images of the right knee. Solid arrows indicate osteophyte formation in the PMMT and UC-II rats. Dotted arrow indicates less cancellous bone at proximal tibial metaphysis in PMMT controls. Bottom row shows the structural analysis of the cancellous bone at proximal tibial metaphysis. Although the differences between groups were not significant, the PMMT rats exhibited a slightly lower trabecular bone volume, decreased trabecular number and increased trabecular separation relative to Naïve and Sham rats. Treatment with UC-II helped maintenance of cancellous bone.

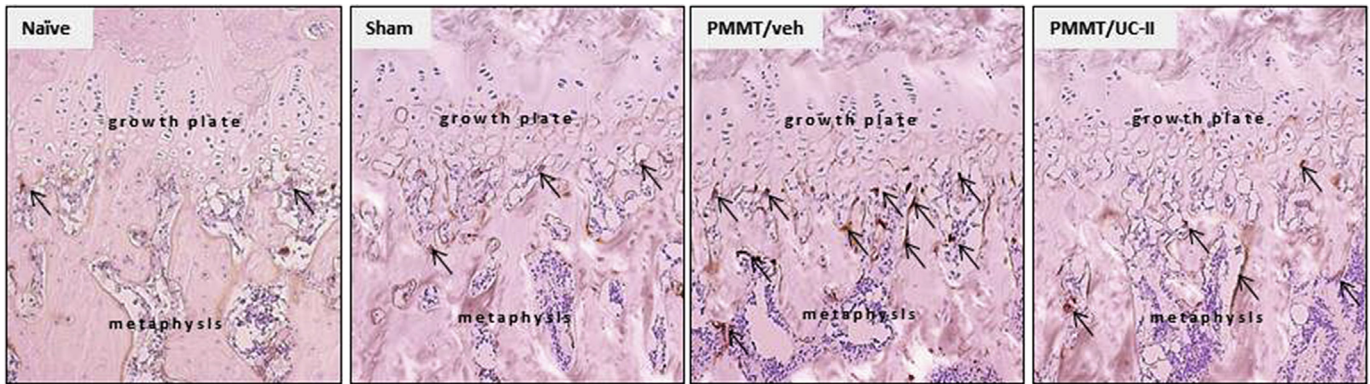


Fig. 3. Shows the Cathepsin K staining of the cancellous bone at the growth plate cartilage. The PMMT rats showed more intense bone resorption relative to rats in the Naïve, Sham, and UC-II groups, as evidenced by larger number and size of darkly stained osteoclasts.

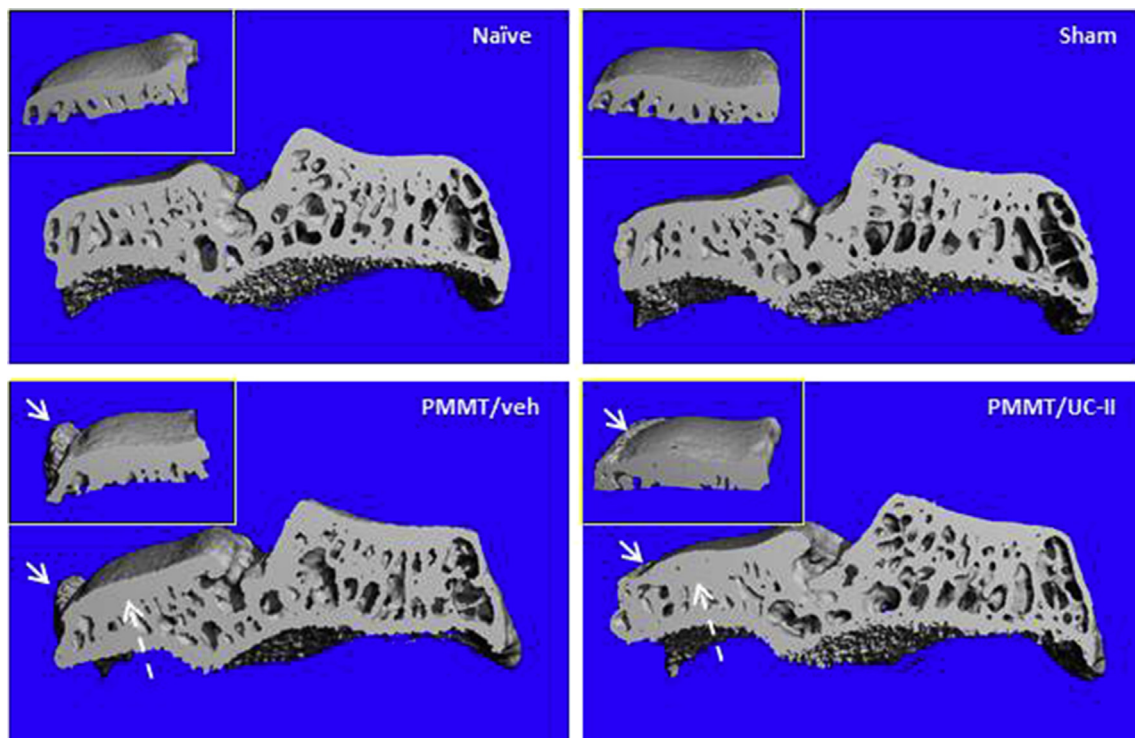


Fig. 4. Shows the 3D μ CT images of the tibial epiphysis. Arrows indicate osteophyte formation in rats that received the PMMT surgery. The dotted arrow indicates the thicker subchondral bone in Zones 1 and 2 in PMMT and UC-II rats. The top view of the medial tibial plateau, depicted in the top left corner, shows the osteophyte formation.

controls. Other studies have previously shown that osteoarthritic rats reduce weight bearing on the injured limb and shift their weight distribution to the contralateral limb^{31–33}. Patients with knee OA also exhibit gait asymmetries of the affected limb, such as reductions in the stance time and peak vertical force^{34–36}. Our data confirmed earlier findings that in contrast to bipeds, in which only option is to shift the weight to the contralateral limb, rats (quadrupeds) tend to alleviate mechanical imbalances associated with pain by shifting at least part of the weight burden onto their front legs, rather than simply overloading their contralateral limbs²⁸. Results from this study show that prompt treatment with UC-II at the time of surgery largely prevented the functional incapacity of injured limb to bear weight, allowing for subsequent close-to-normal biomechanics.

Physiologic mechanical loading plays a critical role in bone and cartilage physiology^{37,38}. Mechanical loading is well known to drive

changes in skeletal remodeling to adjust the bone mass and architecture to meet mechanical demands^{39,40}. In rats, cancellous bone at the tibial metaphysis rapidly responds to changes in mechanical loading⁴¹. Despite sedentary lifestyle of caged laboratory rats, the partial unloading of the operated leg was expected to activate bone resorption and cause a mild loss of cancellous bone in the tibia of PMMT rats. Concurrent to the bone loss, the unloading of weight-bearing bones initiates degenerative changes in the articular cartilage^{42,43}. Because the loss of bone in the operated limb was diminished by UC-II treatment, we hypothesized that the maintenance of knee functionality and load-bearing activity played a key role in preserving bone mass and structure in the tibia. Specifically, the maintenance of modest physical activity may indirectly help to limit damage of articular cartilage^{44,45}. Although the mechanisms that regulate the maintenance of bone and cartilage are different, compelling evidence indicates that mechanical

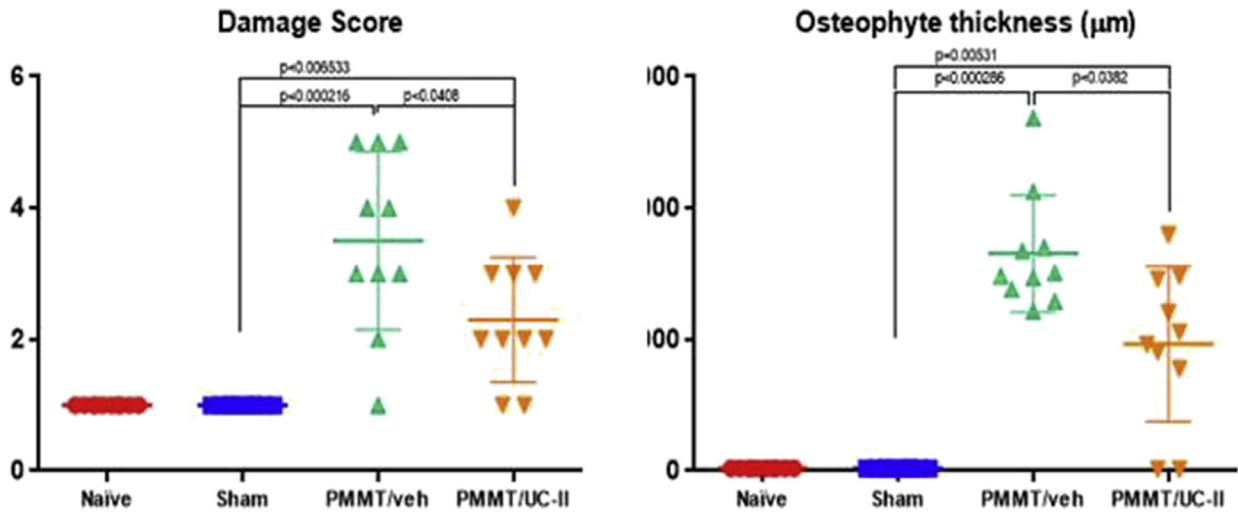


Fig. 5. Shows the damage score of the articular cartilage and size of the osteophytes. Cartilage damage and osteophyte formation were not present in Naive and Sham rats. Dosing with 0.66 mg/kg of UC-II prevented excessive cartilage deterioration and growth of large osteophytes.

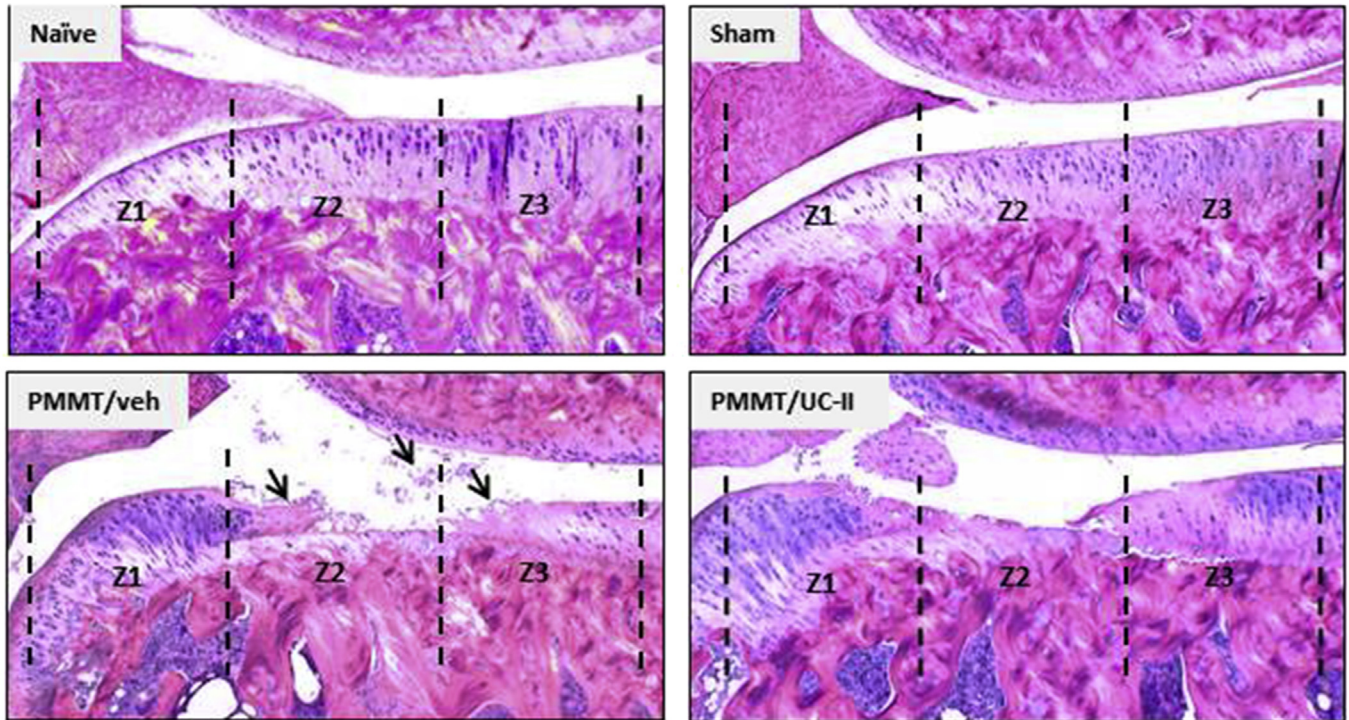
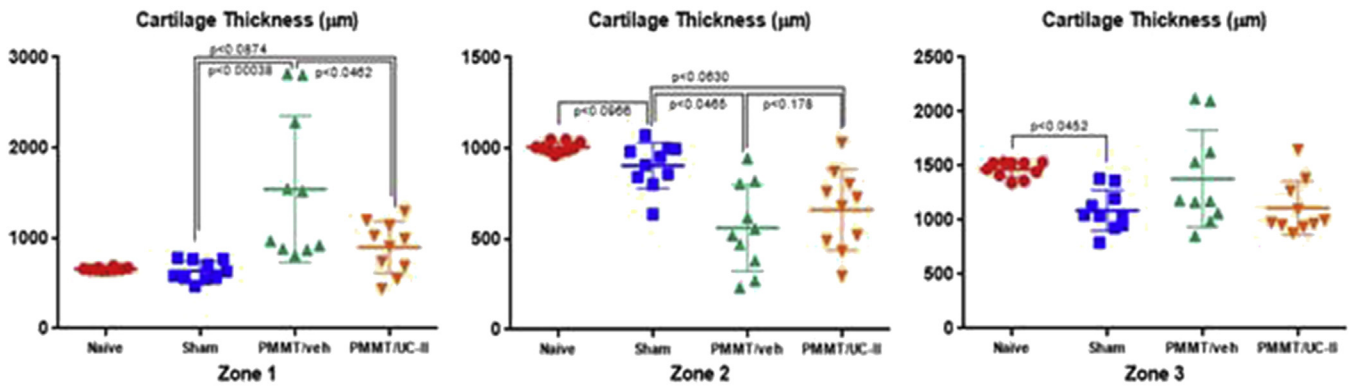


Fig. 6. Shows a zonal analysis of the cartilage thickness evaluated at the medial tibial plateau. The thickening of the articular cartilage in Zone 1 and deterioration of articular cartilage in the Zones 1 and 2 is visible in operated rats. Dosing with UC-II was moderately effective in preventing deterioration of articular cartilage caused by the surgery. In addition, more cartilage debris and fibrillations (indicated by arrows) are evident in PMMT rats compared to UC-II dosed rats.

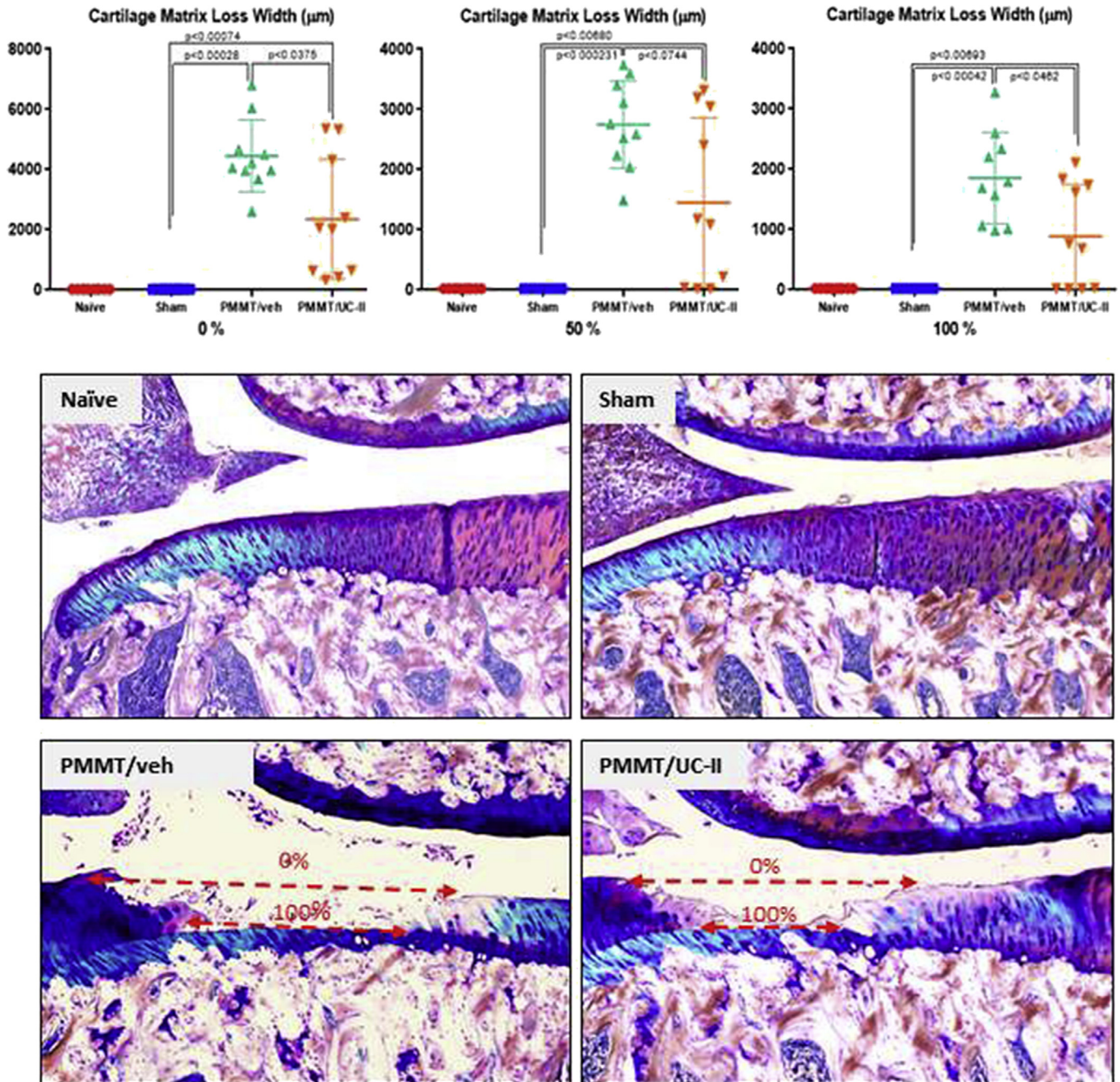


Fig. 7. Shows the loss of cartilage matrix width at the medial tibial plateau. The width of lesions was measured at 0%, 50% and 100% depths. Dosing with UC-II was moderately effective in preventing the deterioration of articular cartilage caused by PMMT. The width of the lesion at 0% and 100% depths are indicated by dotted arrows.

stimuli influence the crosstalk of signaling pathways, which plays a critical role in both cartilage and bone metabolism⁴⁶.

Changes in local mechanical loads triggered by the deterioration of articular cartilage resulted in the accumulation of cortical bone beneath the damaged cartilage and the formation of osteophytes. The formation of osteophytes is believed to be an adaptation of the skeleton aimed to stabilize injured joints, accommodate new mechanical needs and prevent the further deterioration of cartilage⁴⁷. However, osteophytes can limit joint movements and cause pain, and their size is thought to be proportional to the severity of cartilage injury^{48,49}. Combination of radiology and histology techniques revealed that treatment with UC-II limits osteophyte size that can potentially help joint mobility and functionality.

The damage score and zonal quantification of total cartilage thickness (i.e., calcified plus noncalcified) identified a significant loss of articular cartilage in Zones 1 and 2 in PMMT rats. The width of cartilage matrix loss (%) demonstrated the extent of cartilage damage, which was further emphasized by measurements of the significant cartilage degeneration width parameter. Spontaneous healing of the articular cartilage was not evident in the PMMT rats, nevertheless numerous fibrillations and cell debris were frequently found on the histology images. In contrast, dosing of PMMT rats with UC-II limited the extent of cartilage damage and produced signs of recovery. Specifically, cartilage thickening in Zone 1 was reduced while the calcified and noncalcified cartilage layers in Zones 2 and 3 were not different in rats given UC-II compared to

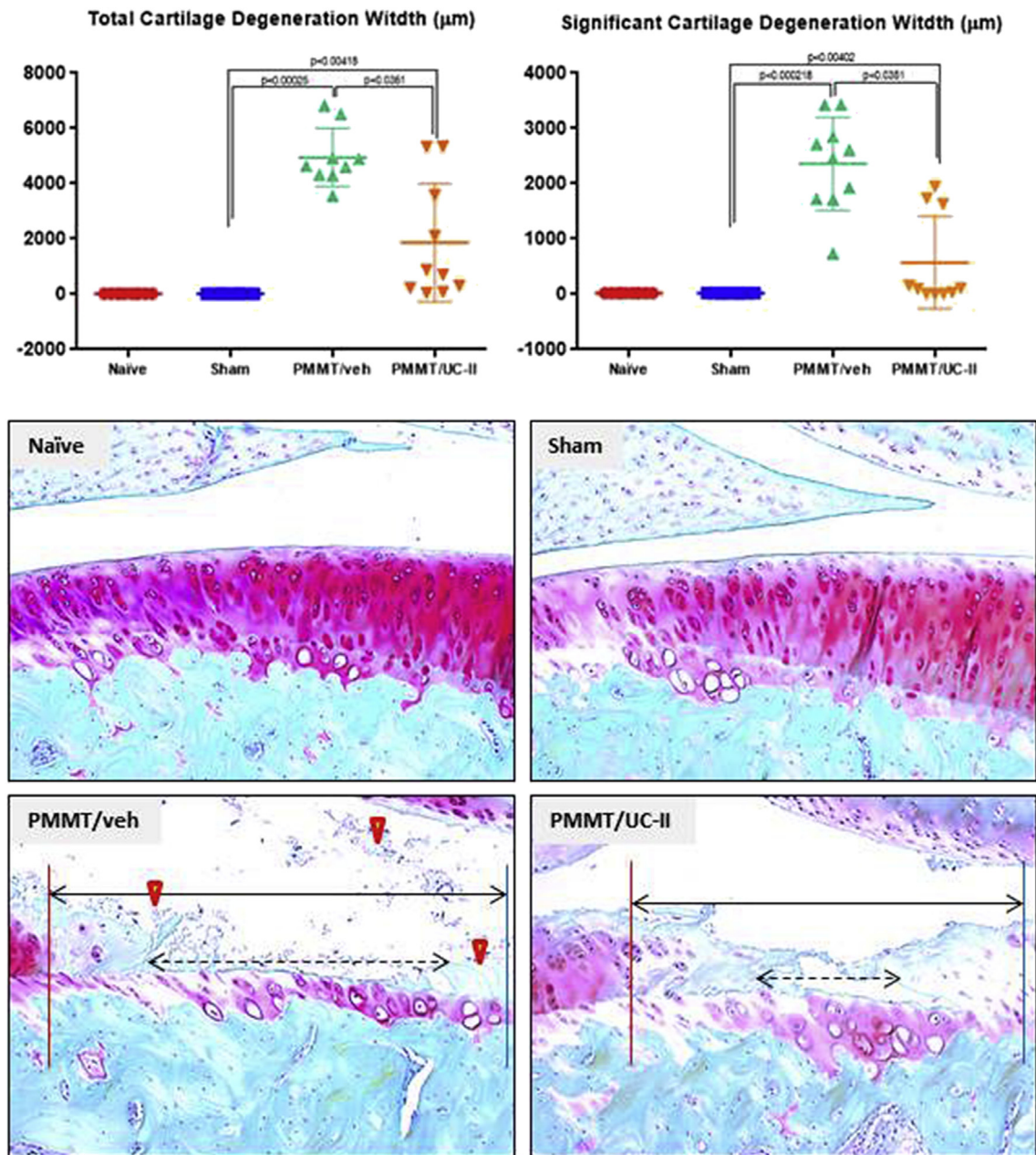


Fig. 8. Shows the total and significant cartilage degeneration width parameters assessed on the Safranin O-stained sections. The PMMT-associated loss of the articular cartilage was partially prevented by UC-II. Red lines indicate the outer border (osteophyte side), and blue lines indicate the inner border (normal cartilage). Solid arrows indicate the total cartilage degeneration width; dotted arrows indicate significant cartilage degeneration width; yellow arrowheads indicate fibrillated cartilage and debris, which were primarily evident in the PMMT rats given no UC-II.

PMMT controls. Likewise, the cartilage matrix loss width and cartilage degeneration width parameters were smaller in PMMT rats given UC-II compared to PMMT controls. Thus, the overall damage score index was favorable in PMMT rats given UC-II compound.

When applied at the time of injury, UC-II was moderately effective in preventing excessive degradation of the articular cartilage. A number of independent biomarkers (DWB, CTX-II, μ CT and histology) showed that daily treatment with UC-II preserved joint functionality and curtailed excessive cartilage degradation. We hypothesize that several mechanisms most likely contribute to the efficacy of UC-II, including anti-inflammatory effects, the reduction of pain, the preservation of mechanical function and

bone quality, and a supply of building material for cartilage repair. Our results support recent clinical data showing improved flexibility and pain reduction in arthritic patients receiving a 40 mg daily dose of UC-II²¹. Disease-modifying therapies for OA are not currently available, and approximately 75% of OA patients regularly receive more than one symptomatic treatment⁵⁰. Other treatment modalities has been shown to reduce cartilage degradation, have no effect, or even to have a negative effect on articular cartilage in similar animal models of OA. Therefore, the complex nature of OA will most likely require simultaneous treatment with several lines of therapy to successfully treat the disease⁴. The modeling of treatments will depend on the severity and duration of OA but should include ingredients such as UC-II

that have been demonstrated to be safe and capable of improving joint flexibility, joint pain and the overall health of bone and cartilage.

In general, studies aimed to test drug efficacy and treat OA face common challenges including choice of the disease model, proper study design to accommodate extensive *in vivo* procedures such as mechanical loading, and availability of cartilage and bone tissues that need different processing to allow imaging, histological and molecular analyses. This study was also limited by availability of relevant tissues needed to adequately address important questions regarding the true mechanism of action of UC-II in the articular cartilage, so methods such as immuno-histochemical staining and gene expression of proteins related to cartilage metabolism including collagen type II and X, MMP-13, SOX9, CCN2 were not performed. However, results from this study helped design of the follow-up studies that will include use of exercise and gait analysis to better address joint functionality and impact of disuse and load bearing on cartilage metabolism, use of radiolabeled compound to assess metabolism and tissue distribution of UC-II and use of adequate immunological, histochemical and molecular methods to address some of the lingering questions regarding mechanism of action of “slow-acting” product such as UC-II.

Authors' contributions

CMB designed the study, interpreted the data and wrote the manuscript; EB did DWB, μ CT and histology analyses consolidated all data and participated in writing the manuscript; ST contributed to study design, reviewed and helped interpretation of data, and participated in writing the manuscript, and NEL reviewed and helped interpretation of data, and participated in writing the manuscript.

Competing interest

The authors that are Pfizer employees have Pfizer stocks. Nancy Lane has no competing interest.

Role of the funding source

This study was supported by Pfizer Consumer Healthcare.

Acknowledgements

The authors thank David Zakur, Adam Murphy and Isabela Bagi for their excellent technical assistance. Special thanks go to Thomas P. Brown, DVM, MP, PhD for his excellent comments and suggestion while reviewing this manuscript. We would also like to acknowledge the excellent technical support from Bolder BioPATH, Inc. for preparing the histology slides.

Supplementary data

Supplementary data related to this article can be found at <http://dx.doi.org/10.1016/j.joca.2017.08.013>.

References

1. Haq I, Murphy E, Dacre J. Osteoarthritis. *Postgrad Med J* 2003;79:377–83.
2. Buckwalter JA, Mankin HJ, Grodzinsky AJ. Articular cartilage and osteoarthritis. *Instr Course Lect* 2005;54:465–80.
3. Roach HI, Yamada N, Cheung KS, Tilley S, Clarke NM, Oreffo RO, et al. Association between the abnormal expression of matrix-degraded enzymes by human osteoarthritic chondrocytes and demethylation of specific CpG sites in the promoter region. *Arthritis Rheum* 2005;52:3110–24.
4. McAlindon TE, Bannuru RR, Sullivan MC, Arden NK, Berenbaum F, Bierma-Zeinstra SM, et al. OARSI guidelines for the non-surgical management of knee osteoarthritis. *Osteoarthritis Cartilage* 2014;22:363–88.
5. Mannelli LDC, Micheli L, Zanardelli M, Ghelardini C. Low dose native type II collagen prevents pain in a rat osteoarthritis model. *BMC Musculoskelet Disord* 2013;14:228.
6. Brown LP. *Pet Nutraceuticals; Inter-Cal Nutraceuticals*. US: Arthritis Foundation; 2005.
7. Bruyer O, Reginster JY. Glucosamine and chondroitin sulfate as therapeutic agents for knee and hip osteoarthritis. *Drugs Aging* 2007;24:573–80.
8. Oesser S, Adam M, Babel W, Seifert J. Oral administration of (14)C labelled gelatin hydrolysate leads to an accumulation of radioactivity in cartilage of mice (C57/BL). *J Nutr* 1999;129:1891–5.
9. Schunck M, Schulze CH, Oesser S. Disparate efficacy of collagen hydrolysate and glucosamine on the extracellular matrix metabolism of articular chondrocytes. *Osteoarthritis Cartilage* 2006;14:S114.
10. Koyama Y, Hirota AH, Irie S. Ingestion of gelatin has differential effect on bone mineral density and body weight in protein undernutrition. *J Nutr Sci Vitaminol* 2001;47:84–6.
11. Nomura Y, Oohashi K, Watanabe M, Kasugai S. Increase in bone mineral density through oral administration of shark gelatin to ovariectomized rats. *Nutrition* 2005;21:1120–6.
12. Conaghan PG, Vanharanta H, Dieppe PA. Is progressive osteoarthritis an atheromatous vascular disease? *Ann Rheum Dis* 2005;64:1539–41.
13. Zhang Y, Koguchi T, Simizu M, Ohmori T, Takahata Y, Morimatsu F. Chicken collagen hydrolysate protect rats from hypertension and cardiovascular damage. *J Med Food* 2010;13:399–405.
14. Bagchi D, Misner B, Bagchi M, Kothari SC, Downs BW, Fafard RD, et al. Effects of orally administered undenaturated type II collagen against arthritic inflammatory diseases: a mechanistic exploration. *Int J Clin Pharmacol Res* 2002;22:101–10.
15. D'Altilio M, Peal A, Alvey M, Simms C, Curtsinger R, Gupta RC, et al. Therapeutic efficacy and safety of undenaturated type II collagen singly or in combination with glucosamine and chondroitin in arthritic dogs. *Toxicol Mech Meth* 2007;17:189–96.
16. Crowley DC, Lau FC, Sharma P, Evans M, Guthrie N, Bagchi M, et al. Safety and efficacy of undenaturated type II collagen in the treatment of osteoarthritis of the knee: a clinical trial. *Int J Med Sci* 2009;6:312–21.
17. Broere F, Wieten L, Klein Koerkamp EI, van Roon JA, Guichelaar T, Lafeber FP, et al. Oral or nasal antigen induces regulatory T cells that suppress arthritis and proliferation of arthritogenic T cells in joint draining lymph nodes. *J Immunol* 2008;15:899–906.
18. Asnagli H, Martire D, Belmonte N, Quentin J, Bastian H, Bouchard-Jourdin M, et al. Type 1 regulatory T cells specific for collagen type II as an efficient cell-based therapy in arthritis. *Arthritis Res Ther* 2014;22(3):R115.
19. Marone PA, Lau FC, Gupta RC, Bagchi M, Bagchi D. Safety and toxicological evaluation of undenaturated type II collagen. *Toxicol Mech Methods* 2010;20:175–89.
20. Lugo JP, Saiyed ZM, Lau FC, Melina JPL, Pakdaman MN, Shamie AN, et al. Undenaturated type II collagen (UC-II) for joint support: a randomized, double-blind, placebo-controlled study in healthy volunteers. *J Inter Soc Sports Nutr* 2013;10:48–60.
21. Lugo JP, Saiyed ZM, Lane NE. Efficacy and tolerability of an undenaturated type II collagen (UC-II) supplement in

- modulating knee joint function: a multicenter randomized, double blind, placebo controlled clinical study in osteoarthritic subjects. *Nutr J* 2016;15:14.
22. Bendele AM. Animal models of osteoarthritis. *J Musculoskelet Neuronal Interact* 2001;1:363–76.
 23. Gregory MH, Capito N, Kuroki K, Stoker AM, Cook JL, Sherman SL. A review of translational animal models for knee osteoarthritis. Hindawi Publishing Corporation. *Arthritis* 2012;764621. 14 pages.
 24. Glasson SS, Blanchet TJ, Morris EA. The surgical destabilization of the medial meniscus (DMM) model of osteoarthritis in the 129/SvEv mouse. *Osteoarthritis Cartilage* 2007;15:1061–9.
 25. National Research Council. *The Guide for the Care and Use of Laboratory Animals*. Washington, DC: National Academy Press; 1996.
 26. Han B, Copeland M, Geiser AG, Hale LV, Harvey A, Ma YL, et al. Development of a highly sensitive, high-throughput, mass spectrometry-based assay for rat procollagen type-I N-terminal propeptide (PINP) to measure bone formation activity. *J Proteome Res* 2007;6:4218–29.
 27. Im H-J, Kim JS, Li X, Kotwal N, Sumner DR, van Wijnen AJ, et al. Alteration of sensory neurons and spinal response to an experimental osteoarthritis pain model. *Arthritis Rheum* 2010;62:2995–3005.
 28. Bagi MC, Zakur DE, Berryman E, Andresen CJ, Wilkie D. Correlation between μ CT imaging, histology and functional capacity of the osteoarthritis knee in the rat model of osteoarthritis. *J Trans Med* 2015;13:276.
 29. Laib A, Barou O. 3D microcomputed tomography of trabecular and cortical bone architecture with application to a rat model of immobilization osteoporosis. *Med Biol Eng Comp* 2000;38:326–32.
 30. Gerwin N, Bendele AM, Glasson S, Carlson CS. The OARSI histopathology initiative – recommendations for histological assessments of osteoarthritis in the rat. *Osteoarthritis Cartilage* 2010;18(Suppl 3):S24–34.
 31. Bove SE, Laemont KD, Brooker RM, Osborn MN, Sanchez BM, Guzman RE, et al. Surgically induced osteoarthritis in the rat results in the development of both osteoarthritis-like joint pain and secondary hyperalgesia. *Osteoarthritis Cartilage* 2006;14:1041–8.
 32. Fernihough J, Gentry C, Malcangio M, Fox A, Rediske J, Pellas T, et al. Pain related behavior in two models of osteoarthritis in the rat knee. *Pain* 2004;112:83–93.
 33. Allen KD, Mata BA, Gabr MA, Huebner JL, Adams SB, Kraus VB, et al. Kinematic and dynamic gait compensations resulting from knee instability in a rat model of osteoarthritis. *Arthritis Res Ther* 2012;14:R78.
 34. Mündermann A, Dyrby CO, Andriacchi TP. Secondary gait changes in patients with medial compartment knee osteoarthritis: increased load at the ankle, knee, and hip during walking. *Arthritis Rheum* 2005;52:2835–44.
 35. Debi R, Mor A, Segal G, Segal O, Agar G, Debbi E, et al. Correlation between single limb support phase and self-evaluation questionnaires in knee osteoarthritis populations. *Disabil Rehabil* 2011;33:1103–9.
 36. Henriksen M, Graven-Nielsen T, Aaboe J, Andriacchi TP, Bliddal H. Gait changes in patients with knee osteoarthritis are replaced by experimental knee pain. *Arthritis Care Res* 2010;62:501–9.
 37. Frost HM. Perspectives: a proposed general model of the “mechanostat” (suggestions from a new skeletal-biologic paradigm). *Anat Rec* 1996;244:139–47.
 38. Bader DL, Salter DM, Chowdhury TT. Biomechanical influence of cartilage homeostasis in health and disease. *Arthritis* 2011;2011979032.
 39. Turner CH. 2002 Biomechanics of bone: determinants of skeletal fragility and bone quality. *Osteoporos Int* 2002;13:97–104.
 40. Boivin G, Farlay D, Bala Y, Doublier A, Meunier PJ, Delmas PD. Influence of remodeling on the mineralization of bone tissue. *Osteoporos Int* 2009;20:1023–6.
 41. Bagi CM, Miller SC. Comparison of osteopenic changes in cancellous bone induced by ovariectomy and/or immobilization in adult rats. *Anat Rec* 1994;239:243–54.
 42. Palmoski M, Colyer RA, Brandt KD. Joint motion in the absence of normal loading does not maintain normal articular cartilage. *Arthritis Rheum* 1980;23:325–34.
 43. Griffin TM, Guilak F. The role of mechanical loading in the onset and progression of osteoarthritis. *Exerc Sport Sci Rev* 2005;33:195–200.
 44. Millward-Sadler SJ, Wright MO, Lee H-S, Nishida K, Caldwell H, Nuki G, et al. Integrin-regulated secretion of interleukin 4: a novel pathway of mechanotransduction in human articular chondrocytes. *J Cell Biol* 1999;145:183–9.
 45. Iwamoto J, Sato Y, Takeda T, Matsumoto H. Effectiveness of exercise for osteoarthritis of the knee: a review of the literature. *World J Orthop* 2011;2:37–42.
 46. Yokota H, Leong DJ, Sun HB. Mechanical loading: bone remodeling and cartilage maintenance. *Curr Osteoporos Rep* 2011;9:237–42.
 47. Brandt KD. Osteophytes in osteoarthritis. Clinical aspects. *Osteoarthritis Cartilage* 1999;7:334–45.
 48. Moskowitz RW, Goldberg VM. Studies of osteophyte pathogenesis in experimentally induced osteoarthritis. *J Rheum* 1987;14:311–20.
 49. Hashimoto S, Creighton-Achermann L, Takahashi K, Amiel D, Coutts RD, Lotz M. Development and regulation of osteophyte formation during experimental osteoarthritis. *Osteoarthritis Cartilage* 2002;10:180–7.
 50. Wieland HA, Michealis M, Kirschbaum BJ, Rudolph KA. Osteoarthritis – an untreatable disease? *Nat Rev Drug Discov* 2005;4:331–44.