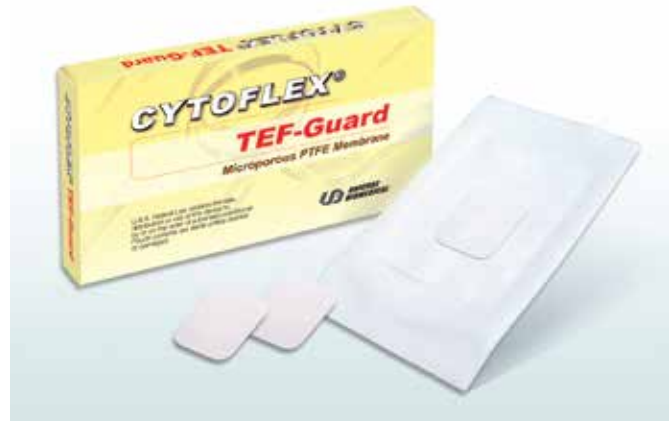

CYTOFLEX® TEF-GUARD®

Micro Porous ePTFE Barrier

*For reconstruction of alveolar ridge
and periodontal defects*

- ❖ *Easily adaptable*
- ❖ *Impenetrable by bacteria*
- ❖ *Easily retrievable as one piece*
- ❖ *Available as smooth or textured*



Available in 12mm x 24mm & 25mm x 30mm sizes
Sterile, individually packaged

Cytoflex® Tef-Guard® non-resorbable barrier membrane is made of micro porous ePTFE material. The micro porosity of Cytoflex® Tef-Guard® is designed to resist the penetration of fibroblasts and bacteria, while simultaneously allowing the exchange of interstitial fluids through the membrane. The unique micro porous design enhances the gingival tissue attachment and provides a favorable protected environment for neo-vascularization and repopulation of osteoblasts in the bony defects. The flexible material easily conforms to the bony defects of grafted sites, and can be easily retrieved as one piece after completion of bone growth. The bacteria-impenetrable membrane protects the tissue regeneration site despite flap recession or if primary closure is not obtained.



Textured Cytoflex® Tef-Guard® Barrier

Advantages of Micro-Pore Design

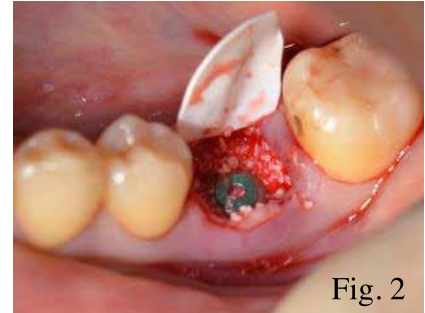
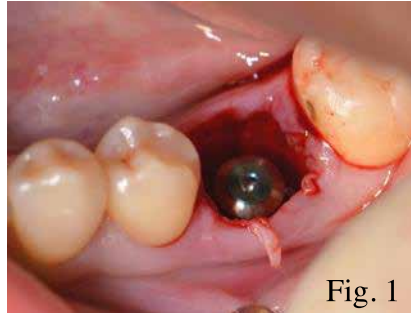
- ❖ *Better host tissue attachment with fewer flap dehiscence*
- ❖ *Micro and optionally macro texture on both surfaces*
- ❖ *Easily tagged with bone screws or pins*
- ❖ *Excellent handling and ease of use*

Cytoflex® Tef-Guard® - Clinical Case Review

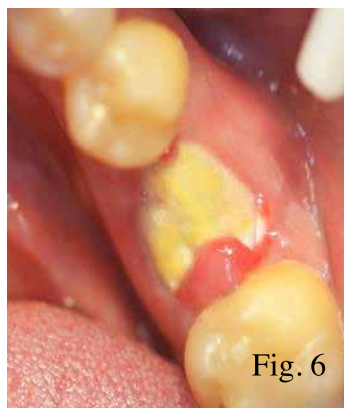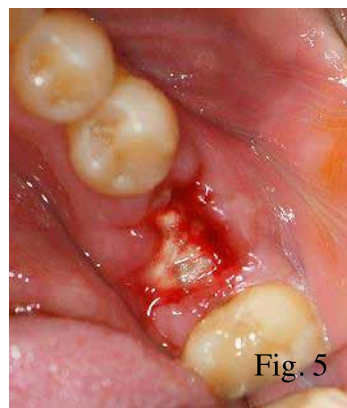
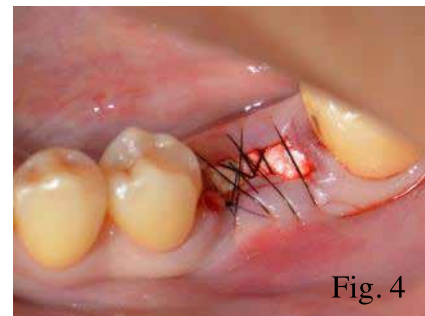
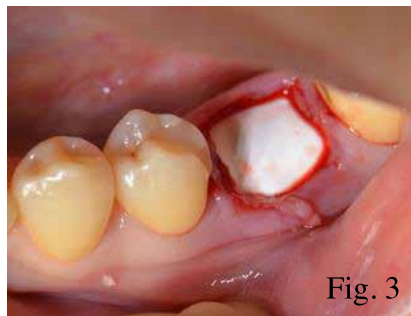
MINIMALLY INVASIVE IMPLANT SITE GRAFTING TECHNIQUE *Jenchun Chen DDS*

This is a 38 year-old female who presented a crown-root fracture of the mandibular first molar and a thin gingival biotype. An immediate implant placement following tooth extraction was planned. A flapless, minimally invasive extraction and implant placement combined with guided tissue regeneration was employed to minimize soft and hard tissue recession.

The tooth root was extracted with an intrasulcular incision and a periosteal elevator. The extraction socket was curetted to remove all soft tissue remnants. After an implant was placed into the extraction site, the gap between the implant and the socket wall was filled with bone graft particles (Figures 1 & 2).

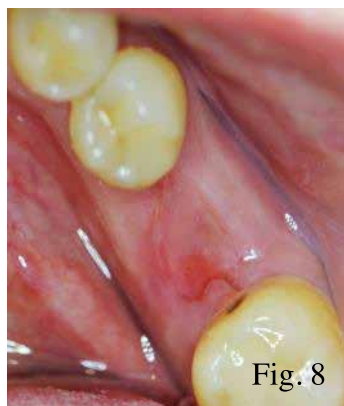
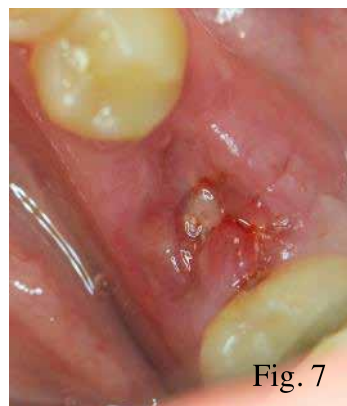

A Tef-Guard® ePTFE membrane was trimmed to extend 3 mm beyond the socket walls and then tucked subperiosteally under the lingual flap, the buccal flap and underneath the interdental papilla using a curette. The membrane was allowed to rest passively over the socket (Figure 3), and was stabilized with a criss-cross absorbable PGA monofilament suture without primary closure (Figure 4).



After one-week post operation, the graft site was uneventful, and the suture was removed (Figure 5). At three-week post-operation, the soft tissue overlying the exposed membrane demonstrated healing without signs of inflammation. An inadvertent fold in the membrane (introduced during membrane placement) was found at the distal buccal corner (Figure 6).

The decision was made to remove the membrane early to prevent potential complications as a result of the folding of the membrane. After applying topical anesthetic, the membrane was easily removed by grasping with a tissue forcep. A dense, vascular connective tissue matrix was found underlying the membrane in the extraction socket upon membrane removal. Figure 7 shows the site at one week after membrane removal.



Following membrane removal, keratinized gingiva formed over the grafted socket. At six-week post-operation, the soft tissue was stable with preserved interproximal papillae and natural mucogingival architecture (Figure 8). This case demonstrates the effective use of a less invasive grafting technique using a micro porous ePTFE barrier.