

**JOURNAL OF**

# **WILDLIFE DISEASES**

## **Conjoined Fetal Twins in a Harbor Seal (*Phoca vitulina*)**

**Jennifer K. Olson,<sup>1,6</sup> Joseph K. Gaydos,<sup>2</sup> Tori McKlveen,<sup>3</sup> Robert Poppenga,<sup>4</sup> Kay Wicinas,<sup>1,2</sup> Elizabeth Anderson,<sup>1,2</sup> and Stephen Raverty<sup>5</sup>** <sup>1</sup>The Whale Museum, 62 First Street N, PO Box 945, Friday Harbor, Washington 98250, USA; <sup>2</sup>SeaDoc Society, UC Davis Karen C. Drayer Wildlife Health Center–Orcas Island Office, 942 Deer Harbor Road, Eastsound, Washington 98245, USA; <sup>3</sup>VCA Veterinary Specialty Center of Seattle, 20115 44th Avenue W, Lynwood, Washington 98036, USA; <sup>4</sup>California Animal Health and Food Safety Toxicology Laboratory, UC Davis School of Veterinary Medicine, 620 W Health Sciences Drive, Davis, California 95616, USA; <sup>5</sup>Animal Health Center, 1767 Angus Campbell Road, Abbotsford, British Columbia, Canada V3G 2M3; <sup>6</sup>Corresponding author (email: [jennifer@whalemuseum.org](mailto:jennifer@whalemuseum.org))



## Conjoined Fetal Twins in a Harbor Seal (*Phoca vitulina*)

Jennifer K. Olson,<sup>1,6</sup> Joseph K. Gaydos,<sup>2</sup> Tori McKlveen,<sup>3</sup> Robert Poppenga,<sup>4</sup> Kay Wicinas,<sup>1,2</sup> Elizabeth Anderson,<sup>1,2</sup> and Stephen Raverty<sup>5</sup> <sup>1</sup>The Whale Museum, 62 First Street N, PO Box 945, Friday Harbor, Washington 98250, USA; <sup>2</sup>SeaDoc Society, UC Davis Karen C. Drayer Wildlife Health Center–Orcas Island Office, 942 Deer Harbor Road, Eastsound, Washington 98245, USA; <sup>3</sup>VCA Veterinary Specialty Center of Seattle, 20115 44th Avenue W, Lynwood, Washington 98036, USA; <sup>4</sup>California Animal Health and Food Safety Toxicology Laboratory, UC Davis School of Veterinary Medicine, 620 W Health Sciences Drive, Davis, California 95616, USA; <sup>5</sup>Animal Health Center, 1767 Angus Campbell Road, Abbotsford, British Columbia, Canada V3G 2M3; <sup>6</sup>Corresponding author (email: jennifer@whalemuseum.org)

**ABSTRACT:** In July 2013, a stranded harbor seal (*Phoca vitulina*) died giving birth to conjoined fetuses. The twins were joined at the abdomen and thoracolumbar spine with the vertebral axis at 180°. The cause of this unique anomaly—a first for this species—was not identified.

Twinning in marine mammals is rare and disadvantageous. In small cetaceans, multiple gestation events likely occur in less than 0.5% of pregnancies (Gonzales et al. 1999). Twinning in pinnipeds is less common, with genetic evidence suggesting that it accounts for only 0.06–0.38% of births in wild phocids (Gelatt et al. 2001; McMahon and Hindell 2003; Hoffman and Forcada 2009; Schultz et al. 2011). Conjoined twins, a congenital anomaly resulting from complications during monozygotic twinning, are rarer in marine mammals, with reports in five species of cetaceans (Aytemiz et al. 2014). In phocids, conjoined twins have been documented in a northern elephant seal (*Mirounga angustirostris*; Colegrove et al. 2005) and a southern elephant seal (*Mirounga leonina*; Spotte 1982).

Harbor seals (*Phoca vitulina*) are the most abundant marine mammal in the Salish Sea. As nonmigratory, upper trophic-level predators, they serve as indicators of local ecosystem health and act as a signal for emerging biotoxins or contaminants (Ross et al. 2013). Like other pinnipeds, twinning in harbor seals is rare (Spotte 1982). Diplopagus conjoined twins have not previously been reported in harbor seals; however, a harbor seal pup was

diagnosed with fetus in fetu, a rare type of parasitic twin that is completely absorbed by its sibling (Buckles et al. 2006).

On 11 July 2013, an adult female harbor seal in fair postmortem condition stranded on a private beach in Olga, Washington, US (48°36'2.79"N, 122°49'45.92"W). A fetal head and two fore flippers protruded from the vulva. The adult was 136 cm long and was 7 yr old as aged using cementum analysis (Matson Laboratory LLC, Missoula, Montana, USA). The animal was in good nutritional condition with a sternal blubber measurement of 3.8 cm and an axillary girth of 95 cm. Postmortem examination revealed that the dam died from consequences of dystocia and was pregnant with male near-term fetuses that were conjoined at the abdomen and thoracolumbar spine with the vertebral axis at 180° (Fig. 1) in a manner similar to human ischiopagus twins except that the spine, not pelvis, was conjoined. Fibrinous attachments connected the uterus to the abdominal wall along its entire linear axis and the conjoined fetuses occupied the right uterine horn. The more caudal head protruded from the vulva and was slightly scavenged, whereas the more cranial head was retained in utero. There were eight flippers present (two fore flippers caudal to both heads and two hind flippers attached to either side of the shared abdomen).

The fetuses were temporarily stored frozen for necropsy at a later date. They were in fair postmortem condition and good nutritional condition with a substantial



FIGURE 1. Gross view of conjoined fetal twins in a harbor seal (*Phoca vitulina*) from San Juan County, Washington, USA.

amount of sternal blubber (1.1 cm) and a weight of 11 kg. The fetuses were incompletely developed, as evidenced by the presence of a partial lanugo coat and deciduous incisors. Both hearts had a patent ductus arteriosus and a patent foramen ovale. A single umbilicus and several organs were torn from the body, making it difficult to identify complete sets of all internal organs. Nevertheless, both fetuses had a complete diaphragm, heart, and lungs that sank in formalin. Within the shared thoracic/abdominal area, there were two colons containing meconium and lanugo coat, suggesting that both fetuses had complete GI tracts before umbilical tearing. There were also two livers, two spleens, and four kidneys, but there was no visible bladder for the fetus with the caudally presenting head. Each fetus had a penis and two testicles.

Computed tomography revealed numerous skeletal anomalies. The twins were joined at the caudal aspect of the thoracic spine and the lumbar spine where there was fusion and distortion of the spinal canal and vertebral bodies as well as significant spinal angulations and malformation (Fig. 2). The sacra and pelvic regions were significantly deformed. There were two abnormally shaped pelvises, one on the left

side of the body, the other on the right side. The pelvis on the right had two recognizable coxofemoral joints. The pelvis on the left was more deformed and asymmetric. Each head had a large open fontanel resulting in a bony void at the dorsal aspect of the skulls.

Postmortem decomposition and freeze artifact hampered microscopic review of the sectioned fetal tissues; aside from a small amount of aspirated meconium and a few squames in one of the two lungs, there were no apparent lesions within the examined slides. Aerobic culture yielded variable light to heavy growth of *Streptococcus phocae* from multiple tissues, and PCR of pooled samples proved negative for canine distemper virus (Barrett et al. 1985), Apicomplexa (Gibson et al. 2011), and *Brucella* spp. (Cloeckaert et al. 2000).

Toxicologic screening of fetal liver, kidney, and adipose tissue for heavy metals by inductively coupled plasma atomic emission spectroscopy and a variety of organic contaminants was unremarkable (California Animal Health and Food Safety Laboratory, Davis, California, USA). Adipose tissue was negative for polychlorinated biphenyls at or above a reporting limit of 1 part per million (ppm). Kidney

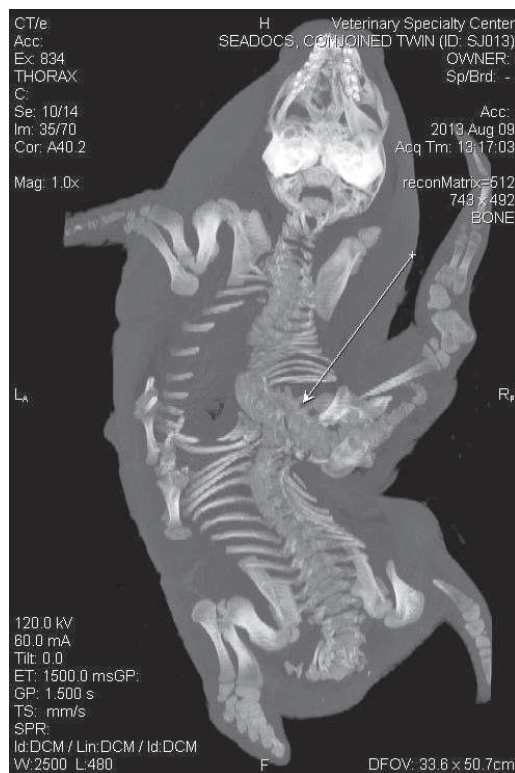


FIGURE 2. Dorsoplantar computed tomography image of conjoined fetal twins in a harbor seal (*Phoca vitulina*) from San Juan County, Washington, USA. The arrow points to the fusion of the spines.

tissue was positive for nontoxic concentrations of manganese (0.36 ppm), iron (130 ppm), zinc (32 ppm), and copper (2.7 ppm). Toxicant screening on liver tissue by mass spectrometry, designed to detect a large number of organic compounds belonging to diverse chemical classes (pesticides, environmental contaminants, drugs, and natural products), detected phenol, indole, and hydrocinnamic acid. Polychlorinated diphenyl ethers were not detected.

Causes of congenital malformations are difficult to determine, but can include errors in cellular division, genetic defects, environmental factors, or some combination. Multifactorial contaminants, chromosomal aberrations, infectious agents, and other entities can cause fetal malformations in domestic animals (Rousseaux and Ribble 1988). Environmental pollutants have been

linked to the occurrence of conjoined twins in wild species (Ludwig et al. 1996). Though harbor seals are commonly used as indicators for contaminant levels throughout the region, our findings do not support that this anomaly was due to any common contaminants. We hypothesize that this congenital anomaly was idiopathic and related to disordered embryonic migration and fusion. We believe that our case represents the first diplopagus conjoined twins in a harbor seal.

We thank Patrick Charapata and the volunteers of The Whale Museum's San Juan County Marine Mammal Stranding Network for providing field response and necropsy assistance. This work was funded by the John H. Prescott Marine Mammal Rescue and Assistance Grant, with in-kind contributions from The Whale Museum and the SeaDoc Society.

#### LITERATURE CITED

- Aytemiz I, Danyer E, Özbeck EÖ, Tonay AM, Öztürk AA. 2014. Preliminary report of a conjoined bottlenose dolphin (*Tursiops truncatus*) calf stranded on the Aegean Sea coast of Turkey. *J Black Sea* 20:274–279.
- Barrett T, Shrimpton S, Russell S. 1985. Nucleotide sequence of the entire protein coding region of canine distemper virus polymerase associated (P) protein mRNA. *Virus Res* 3:367–372.
- Buckles EL, Gulland FMD, Aldridge BM, Gelatt TS, Ross PS, Haulena M, Lowenstine LJ. 2006. Fetus in fetu in a harbor seal (*Phoca vitulina richardi*): Histopathologic, genetic, and toxicologic analysis. *Vet Pathol* 43:541–544.
- Cloeckaert A, Grayon M, Grepinet O. 2000. An IS711 element downstream of the bp26 gene is a specific marker of *Brucella* spp isolated from marine mammals. *Clin Vaccine Immunol* 7:5835–5839.
- Colegrove KM, Greig DJ, Gulland FMD. 2005. Causes of live strandings of Northern elephant seals (*Mirounga angustirostris*) and Pacific harbor seals (*Phoca vitulina*) along the central California coast, 1992–2001. *Aquat Mamm* 31:1–10.
- Gelatt TS, Davis CS, Siniif DB, Strobeck C. 2001. Molecular evidence for twinning in Weddell seals (*Leptonychotes weddellii*). *J Mammal* 82:491–499.
- Gibson A, Raverty S, Lambourn D, Huggins J, Magargal S, Grigg ME. 2011. Polyparasitism is associated with increased disease severity in *Toxoplasma gondii*-infected marine sentinel species. *PLoS Negl Trop Dis* 5:e1142.

- González AF, López A, Benavente P. 1999. A multiple gestation in a *Delphinus delphis* stranded on the north-western Spanish coast. *J Mar Biol Assoc UK* 79:1147–1148.
- Hoffman JI, Forcada J. 2009. Genetic analysis of twinning in Antarctic fur seals (*Arctocephalus gazelle*). *J Mammal* 90:621–628.
- Ludwig JP, Kurita-Matsuba H, Auman HJ, Ludwig ME, Summer CL, Giesy JP, Tillitt DE, Jones PD. 1996. Deformities, PCBs, and TCDD-equivalents in Double-crested Cormorants (*Phalacrocorax auritus*) and Caspian Terns (*Hydroprogne caspia*) of the upper Great Lakes 1986–1991: Testing a cause–effect hypothesis. *J Great Lakes Res* 22:172–197.
- McMahon CR, Hindell MA. 2003. Twinning in southern elephant seals: The implications of resource allocation by mothers. *Wildl Res* 30:35–39.
- Ross PS, Noël M, Lambourn D, Dangerfield N, Calambokidis J, Jeffries S. 2013. Declining concentrations of persistent PCBs, PBDEs, PCDEs, and PCNs in harbor seals (*Phoca vitulina*) from the Salish Sea. *Prog Oceanogr* 115: 160–170.
- Rousseaux CG, Ribble CS. 1988. Developmental anomalies in farm animals II. Defining etiology. *Can Vet J* 29:30–40.
- Schultz JK, Becker BL, Johanos TC, Lopez JU, Kashinsky L. 2011. Dizygotic twinning in the Hawaiian monk seal. *J Mammal* 92:336–341.
- Spotte S. 1982. The incidence of twins in pinnipeds. *Can J Zool* 60:2226–2233.

*Submitted for publication 18 February 2015.*

*Accepted 5 June 2015.*