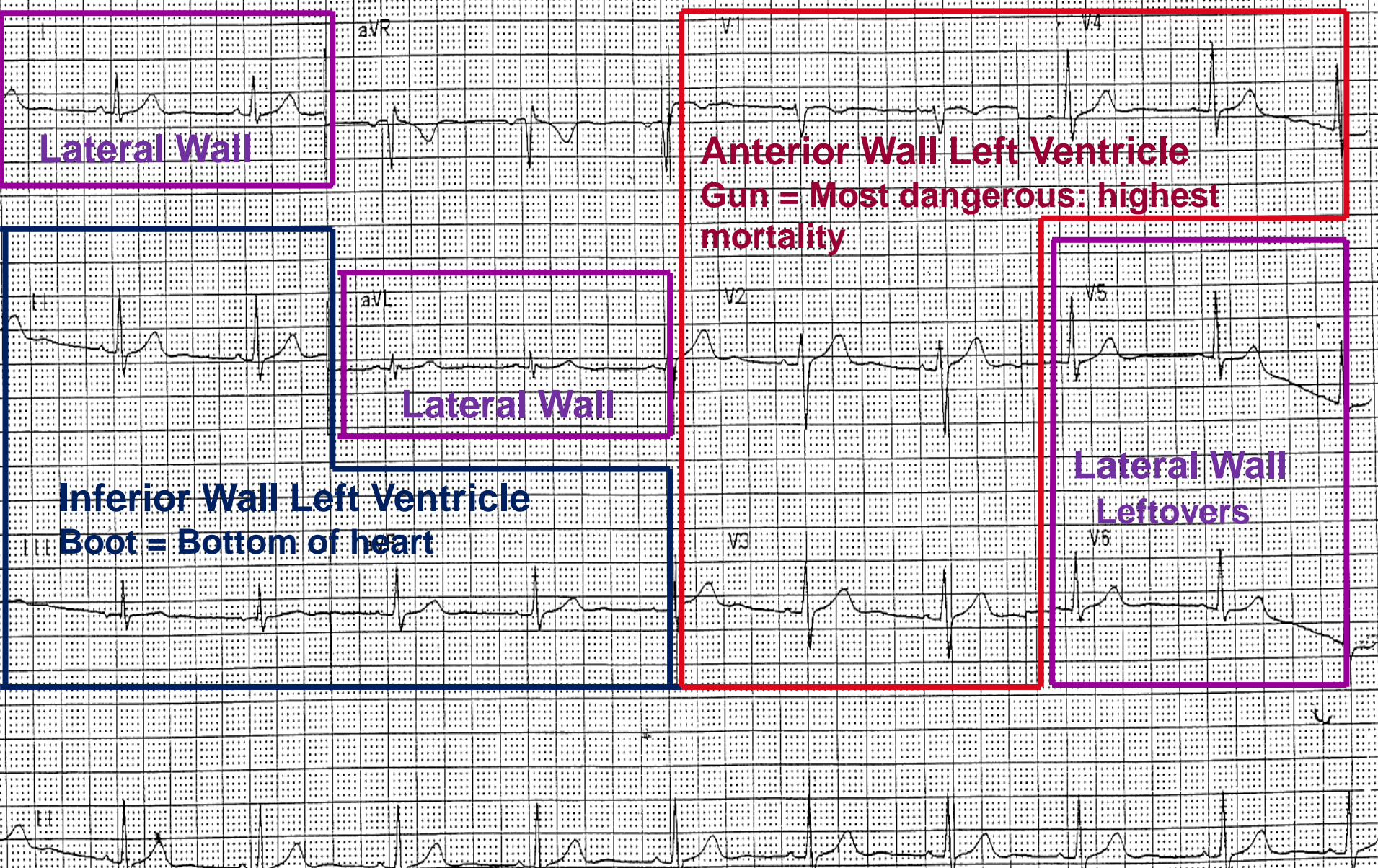


The ECG = 12 Pictures

©QRS Educational Services2024



Lateral Wall

aVR

Anterior Wall Left Ventricle
Gun = Most dangerous: highest mortality

V1

V4

aVL

Lateral Wall

V2

Inferior Wall Left Ventricle
Boot = Bottom of heart

Lateral Wall
Leftovers

V5

V3

V6