The Oncologist®

Breast Cancer

Systematic Review of Postradiotherapy Bronchiolitis Obliterans Organizing Pneumonia in Women With Breast Cancer

GARY R. EPLER,[a] EILEEN M. KELLY[b]

[a]Pulmonary and Critical Care Medicine, Harvard Medical School, Brigham and Women's Hospital, Boston, Massachusetts, USA; [b]Kelly Research and Consulting, Smithtown, New York, USA

Disclosures of potential conflicts of interest may be found at the end of this article.

Key Words. Bronchiolitis obliterans organizing pneumonia • BOOP • Radiation therapy • Breast cancer

ABSTRACT

Background. Radiation therapy for breast cancer has been implicated in the development of bronchiolitis obliterans organizing pneumonia (BOOP). This inflammatory lung disorder was first noted in 1983, and there have been numerous reports of BOOP occurring in women who have had radiation therapy for breast cancer since 1995. This study was undertaken to perform a systematic review of postradiotherapy BOOP to determine the occurrence, presentation, treatment, and outcome.

Materials and Methods. A systematic literature review was conducted according to the guidelines provided by the Preferred Reporting Items for Systematic Reviews and Meta-Analyses report.

Results. The literature search yielded 10 Japanese epidemiological reports with 129 women, 4 case series reports with 36 women, and 24 case reports with 34 women. Common symptoms included fever, cough, and shortness of breath. Most patients received corticosteroid therapy, and duration of treatment ranged from 6 months to 1 year, although some patients received steroids for longer than 1 year because of relapse, which occurred in approximately one half of patients. No deaths have been reported.

Conclusion. BOOP is a rare but significant complication from radiation therapy for breast cancer. Chest radiographic studies for women who report new respiratory symptoms during the postradiation period can be beneficial for early diagnosis and for guiding appropriate management. ***The Oncologist*** 2014; 19:1216–1226

Implications for Practice: Bronchiolitis obliterans organizing pneumonia (BOOP) is a rare but potentially serious complication of radiation therapy for breast cancer. Pulmonary symptoms occur within several weeks to a year or more after completion of radiation. Initial signs and symptoms suggest pneumonia, but symptoms and lung involvement progress despite antibiotic therapy. The pulmonary infiltrates may be in the opposite lung from the radiation field. Patients without symptoms can be monitored, and those with moderate to severe BOOP usually require corticosteroid therapy. Clinical oncologists and radiation oncologists managing these patients need to consider obtaining diagnostic chest radiographic studies for women who report new respiratory symptoms during the late radiation or postradiation period.

INTRODUCTION

The American Cancer Society estimates that 232,670 women and 2,360 men in the United States will be diagnosed with breast cancer in 2014 [1]. An additional 62,570 women are expected to be diagnosed with breast carcinoma in situ or stage 0 breast cancer, and 90% of them will have ductal carcinoma in situ [2]. The 1991 NIH consensus report on the treatment of early stage breast cancer recommended that a lumpectomy followed by radiation therapy is the preferable treatment of early stage breast cancer because "it provides survival rates equal to that of total mastectomy and axillary dissection while preserving the breast" [3]. By 2000, breast conservation therapy was used more often than mastectomy for women with early stage breast cancer [4]. For men with breast cancer, radiotherapy was given to 35% having lumpectomies and 21% having mastectomies [5].

Radiation therapy after lumpectomy has traditionally consisted of megavoltage radiation to the whole breast at a dose of 45–50 Gy (1.8–2 Gy per fraction) [3]. Recently, different radiation therapy methods and regimens have been developed and adopted in varying degrees. These newer regimens include intensity-modulated radiation therapy, accelerated whole-breast irradiation, hypofractionated whole-breast irradiation, accelerated hyperfractionated whole-breast irradiation, partial-breast irradiation, brachytherapy, and intraoperative radiation therapy. Many of these methods use advances in imaging and treatment planning that may

CME

Correspondence: Gary R. Epler, M.D., Pulmonary and Critical Care Medicine, Harvard Medical School, 75 Francis Street, Brigham and Women's Hospital, Boston, Massachusetts 02115, USA. Telephone: 617-732-7420; E-Mail: gepler@partners.org Received February 4, 2014; accepted for publication October 7, 2014; first published online in ***The Oncologist*** *Express* on October 31, 2014. ©AlphaMed Press 1083-7159/2014/$20.00/0 http://dx.doi.org/10.1634/theoncologist.2014-0041

help localize the radiation dosage and subsequently minimize toxicity to adjacent organs.

Radiation pneumonitis is a general term that includes both inflammatory lesions and fibrotic lesions. Bronchiolitis obliterans organizing pneumonia (BOOP) is a specific term used for the inflammatory response, which is the most common form of radiation pneumonitis. The terms organizing pneumonia and secondary organizing pneumonia are also used for this inflammatory response. The term BOOP will be used in this report because it is currently recognized and used throughout the world [6–8] and is used for the nonidiopathic forms such as radiation therapy BOOP [9]. It is a specific pulmonary lesion recognized by pathologists with a characteristic clinical pattern. For patients, *BOOP* is easy to remember, and the term is used to advance their understanding of the disease by obtaining accessible scientific publications.

BOOP is a potentially serious complication of radiation therapy for breast cancer. This inflammatory lung disorder was noted in 1983 [10] and published as a distinct clinical syndrome in 1985 [11]. It is defined as "organized polypoid granulation tissue in the distal airways extending into the alveolar ducts and alveoli" [11]. Clinical manifestations include fever, cough, shortness of breath, and fatigue. Chest radiographs typically show bilateral patchy infiltrates [11, 12]. Chest computed tomography (CT) findings show ground-glass opacities and airspace consolidation ranging from 2 cm to extensive bilateral disease [11, 12]. Nodular opacities may be seen, and distinctive triangular-shaped pleural-based densities with air bronchograms are common [12].

Pulmonary function tests show slight decrease in vital capacity and moderate decrease in diffusing capacity [12]. Patients with moderate or severe BOOP may require hospitalization. Lung biopsies show "well-formed plugs of edematous granulation tissue involving terminal and respiratory bronchioles extending into alveolar ducts and alveoli including polypoid plugs infiltrated by nests of chronic inflammatory cells" [11]. Some biopsies are characterized by fatty alveolar macrophages and by sparse interstitial infiltrates of lymphocytes and plasma cells [12]. Corticosteroid therapy remains the mainstay of therapy [11, 12]. Relapses occur among one-quarter to one-third of patients when their corticosteroid dose is tapered or stopped; however, patients respond to a second or multiple courses of corticosteroid therapy at similar doses with eventual resolution over time; there appears to be no development of resistance to corticosteroid therapy [12]. If there is no response to corticosteroid therapy, the process may represent a fibrosing lung disease and not primary BOOP. Up to 80% of patients with BOOP are cured, and mortality has been estimated to be about 5% [12].

In 1995, two reports from France described BOOP occurring among three women who had received radiation therapy for breast cancer [13, 14]. Additional reports were published from the United States, Japan, and other countries [6, 15–49]. Large-scale epidemiological reports have been published from Japan, where prevalence ranged from 0.8% to 2.9% [15–24]. Most of these patients received traditional whole-breast irradiation. It remains to be determined whether newer radiotherapy methods and regimens will decrease the risk of BOOP associated with breast cancer radiation therapy. Conventional tangential fields used in breast cancer radiation therapy may induce inflammation of the subpleural regions of the lung, and it has been proposed that radiation therapy primes the lung for the development of BOOP by inducing activation of pulmonary lymphocytes [25]; thus there may be an interaction between radiotherapy and the immune system [18].

Conventional tangential fields used in breast cancer radiation therapy may induce inflammation of the subpleural regions of the lung, and it has been proposed that radiation therapy primes the lung for the development of BOOP by inducing activation of pulmonary lymphocytes; thus, there may be an interaction between radiotherapy and the immune system.

This study was undertaken to describe an additional case and to perform a systematic review of postradiotherapy BOOP occurring in patients with breast cancer by exploring frequency, clinical and chest imaging findings, treatment, and outcome.

Materials and Methods

Case Report

Figure 1A shows a chest CT scan of a 51-year-old woman who had a nonproductive cough and fever to 101°F at 9 months after completion of accelerated whole-breast irradiation and boost radiation to the right breast for ductal carcinoma in situ. Her course of radiation therapy was complicated, with severe fatigue beginning on day 2 and complaints of shortness of breath midway through her treatments. A chest x-ray several days prior to this chest CT scan showed right midlung airspace opacification and an ill-defined right upper-lobe nodular opacity. Pneumonia was diagnosed, and doxycycline was given. After 5 days with no change in the febrile response, azithromycin and a third-generation cephalosporin were given. During this time, legionella titers suggested an active infection. She remained febrile and reported increased coughing, shortness of breath, and chest pain with deep inspiration. She was hospitalized and given intravenous antibiotics, supplemental oxygen, and nebulizer treatments. Symptoms worsened during the next 3 days, with persistent fever, chills, and sweats. The chest CT scan (Fig. 1A) showed patchy ground-glass and consolidated opacities in the right upper, middle, and lower lungs within and outside the radiation field. Bronchoscopy with biopsy showed organizing pneumonia associated with foamy histiocytes (Fig. 1B). Intravenous methylprednisolone was given; symptoms improved within 24 hours, and fever subsided. After 6 days of intravenous steroid, the patient was discharged home with prednisone 60 mg daily.

Three months later, at the prednisone dosage of 20 mg daily, she developed fatigue, malaise, chills, and sweats. Chest x-ray showed a new right middle-lung opacity consistent with a BOOP flare that responded to prednisone at 35 mg daily. An additional 3 months of prednisone was given, with resolution of symptoms and complete clearing of the chest x-ray and the chest CT scan.

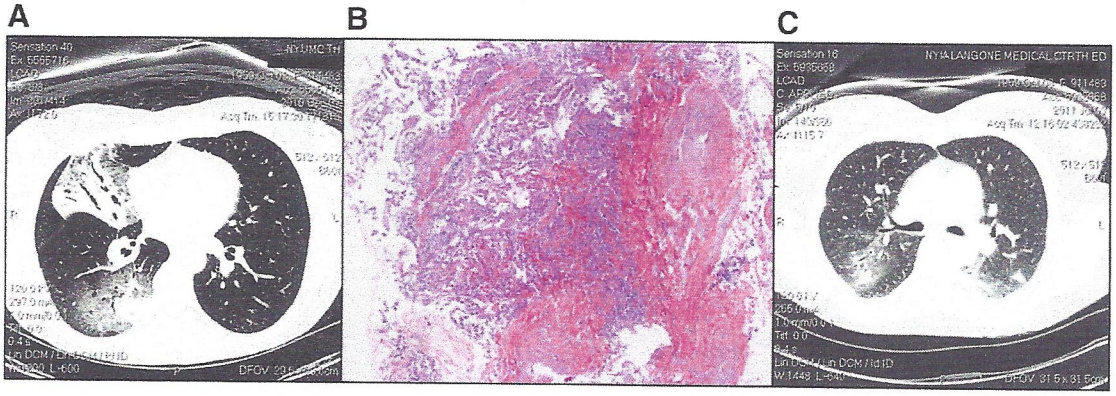

Figure 1. Imaging of a woman who had accelerated whole-breast irradiation plus boost radiation to the right breast. **(A):** Chest computed tomography (CT) scan showing right-sided consolidations and ground-glass opacities with air bronchograms. There was complete resolution after 7 months of corticosteroid therapy. **(B):** This medium-power photomicrograph of the transbronchial biopsy shows organizing pneumonia and interstitial histiocytes. **(C):** Follow-up chest CT scan 2 weeks after discontinuing corticosteroid therapy showing new right ground-glass opacities with an air bronchogram and new left-sided ground-glass opacities posteriorly.

Ten days after discontinuing prednisone, the patient developed headache and fever of 100.8°F, and she was treated with azithromycin for a presumed sinus infection. Symptoms progressed to cough and shortness of breath. The chest x-ray showed new left lower-lung and right upper-lung infiltrates with air bronchograms. She was hospitalized and given intravenous methylprednisolone, and azathioprine therapy was given as a steroid-sparing agent because she had multiple toxicities from prednisone. During this time, left lower-extremity soleal vein thrombosis developed that was initially managed without anticoagulation therapy, and she was discharged home with prednisone 40 mg per day.

Several days later, progressive shortness of breath developed, and a CT angiogram showed an acute pulmonary embolism and new right-sided ground-glass opacities and left-sided consolidations (Fig. 1C). She was treated with 6 months of warfarin, and tamoxifen was discontinued because of the pulmonary embolism. Symptoms resolved, and the chest CT scan showed normal lungs. The prednisone and azathioprine therapy were to be discontinued after 1 year; however, severe corticosteroid withdrawal symptoms developed that required 13 additional months of gradual dose reduction. The azathioprine was given for 1 year and the prednisone was given for a total of 3 years, half of the time for treatment of BOOP and half for weaning from prednisone.

Literature Review

The systematic literature review was conducted according to the guidelines provided by the Preferred Reporting Items for Systematic Reviews and Meta-Analyses report (PRISMA Statement) [50]. The PubMed literature search using keywords that included *breast, radiotherapy, BOOP, organizing*, and *cryptogenic* showed 36 studies for review after screening for duplications, relevance, and English-language text. Two additional references were manually identified from the references listed in these studies. A total of 38 references were categorized into epidemiological reports, case series reports, and case reports.

Results

Ten Japanese epidemiological studies were identified [15–24]. Several studies were from a single institution [16, 17, 20, 21, 23, 24], and one study was a survey among 20 institutions (Table 1) [18]. These reports described BOOP occurring in 129 of 7,671 women (1.7%), and studies showed a range of prevalence from 0.8% to 2.9% [15–24]. Five of the 9 reports showed patients received a traditional whole-breast irradiation protocol of 50 Gy in 25 fractions [19–21, 23, 24], 1 report showed 248 patients received hypofractionated whole-breast radiotherapy [17], 1 report included patients who received whole-breast irradiation or accelerated hyperfractionated whole-breast irradiation [15], and there was no information about the radiation protocol for 3 reports. Boost radiation was given from 0% [23] to 75% [15]. A pulmonary follow-up protocol consisting of scheduled chest radiographs during the year after treatment was used in six studies [15–17, 20, 21, 24], and chest radiographs were performed in three studies if respiratory symptoms developed [18, 19, 23].

Clinical and treatment data in Table 2 show that 100% of women were nonsmokers in 5 studies [15, 16, 18, 21, 23]; 1 study reported 88% nonsmokers [24], and another study reported 92% nonsmokers [20]. The majority of women received hormonal therapy, and those receiving chemotherapy ranged from 0% [22] to 60% [23]. The latency period to onset of pulmonary symptoms ranged from onset during radiation therapy [18] to 23 months after completion of therapy [20]. Cough, usually without sputum production, was the most common symptom and in 50%–100% of patients. Fever occurred in 41%–100% of patients. Although the majority of patients were symptomatic, one report showed 15% were asymptomatic [24], another showed 16% were asymptomatic [18], and another report showed 50% were asymptomatic [21]; however, it is possible that data from some patients may have been included in both reports, given that there was an overlap in authorship [18, 21].

Biopsy rates varied from 27% [18] to 100% [15, 16]; 4 of the studies did not report any biopsy data [17, 19, 21, 24]. Across the studies, biopsy data were available for 36 patients. Biopsy results consistent with BOOP were reported for 33 patients, and 3 had biopsy results that were not diagnostic. Contralateral involvement of BOOP occurred from 8% [21] to 100% [17]. Regarding corticosteroid treatment, none of the patients received this treatment in a study in which 50% of patients

Table 1. Study and radiation therapy characteristics from 10 epidemiological Japanese studies

Investigators	Year	Total (*n*)	BOOP, *n* (%)	Radiation dates	Radiation type	Radiation dose (Gy)	Radiation fractions	Boost (%)	Chest x-ray protocol
Takigawa et al. [15]	2000	157	4 (2.5)	1996–1998	WBI and hyper-AWBI	50	25 or 34	75	q6 mo
Miwa et al. [16]	2004	206	5 (2.4)	1992–2002		50–60			q3–4 mo
Fujii et al. [17]	2008	248	2 (0.8)	2003–2005	HF-AWBI	42.5–47.8	16 to 20		Pre and q6 mo
Ogo et al. [18]	2008	2,056	37 (1.8)	1990–2000		44–52		32	
Katayama et al. [19]	2009	702	16 (2.3)	1995–2006	WBI	50	25	6	Symptoms
Kubo et al. [20]	2009	413	12 (2.9)	2005–2007	WBI	50	25	50	q3 mo
Ogo et al. [21]	2010	616	12 (1.9)	1992–2008	WBI	50	25		Pre and q3 mo
Kano et al. [22]	2012	441	10 (2.3)	2005–2009		40 or 50		50	
Oie et al. [23]	2013	428	5 (1.2)	2002–2009	WBI	50	25	0	Symptoms
Otani et al. [24]	2014	2,404	26 (1.1)	1997–2011	WBI	50	25	15	q2 mo

Empty cells indicate data not reported in publication.
Abbreviations: AWBI, accelerated whole-breast irradiation; BOOP, bronchiolitis oblilterans organizing pneumonia; HF-AWBI, hypofractionated accelerated whole-breast irradiation; mo, months; pre, pretreatment; q, every; WBI, whole breast irradiation.

were asymptomatic [21]; 1 study reported that 27% received corticosteroid [24], 4 studies reported that more than 50% received corticosteroid therapy [18–20, 22], and 4 reports showed that 100% of patients received corticosteroid therapy [15–17, 23]. Relapses ranged from 0% to 100% [15, 18], and one patient had five relapses [23]. They typically occurred during decreasing doses of corticosteroid or soon after treatment was discontinued [15, 17]. Four patients received corticosteroid therapy for more than 2 years, and 1 patient received therapy for 3.7 years [19]. Otani et al. [24] retrospectively compared patients who received corticosteroid therapy ($n = 7$) with patients who did not receive steroids ($n = 19$). They reported that relapse occurred in 71% of those treated with steroids and 16% of those not receiving steroids.

Four case series reports were published (Table 3). The most comprehensive of these reports was published by Crestani et al. in 1998 [25]. These investigators surveyed the Group d'Etudes et de Recherche sur les Maladies "Orphelines" Pulmonaires in France, consisting of 40 pulmonary centers. The survey showed 15 women developed BOOP after breast radiation and 87% were nonsmokers. Radiation dosage ranged from 45 Gy to 55 Gy, and 36% received boost treatment. Pulmonary symptoms occurred from 3 to 47 weeks after treatment. Symptoms included fever (100%), cough (87%), malaise (87%), and dyspnea (60%). The contralateral lung was involved in 47% of patients. Seven patients had lung biopsies, and these were diagnostic for BOOP in five and compatible with BOOP in one; one biopsy did not contain sufficient tissue for analysis. All 15 patients were treated with corticosteroids, and duration of treatment ranged from 17 weeks to more than 100 weeks, with 3 patients remaining on steroids at the time of publication. The relapse rate was 80%.

In an Italian case series study, 11 women developed postradiation BOOP, and they received whole-breast irradiation at a dose ranging from 40 Gy to 56 Gy; 82% were nonsmokers, latency was from 6 to 32 weeks, and 18% were asymptomatic [26]. Because patients required biopsy results for study entry, all 11 patients were biopsied in the nonirradiated lung, and biopsy results for all were consistent with BOOP. In another Italian study, 5 women had breast irradiation at doses from 46 Gy to 60 Gy, and latency was from 13 to 24 weeks [6]. All patients had lung biopsies, and all were consistent with BOOP. In a nonbiopsy Romanian case series study, bronchoalveolar lavage fluid showed increased lymphocytes, neutrophils, eosinophils, and mast cells [27].

A total of 24 publications from Japan, France, the U.S., The Netherlands, Belgium, Italy, Spain, Portugal, Poland, Turkey, and the U.K. described BOOP in 34 individual patients [13, 14, 28–49]. Patient characteristics (Table 4) showed the age ranged from 42 to 92 years, with 76% of the patients in their 50s or 60s. Smoking status among 14 patients showed that 9 were nonsmokers, 3 were former smokers, and 2 were current smokers. Types of breast cancer included ductal carcinoma in situ, invasive breast cancer, breast cancer with chest wall metastasis, and postmastectomy patients receiving adjuvant radiation therapy. Radiation treatment protocols showed that 24 women received traditional whole-breast irradiation [13, 14, 28, 30–32, 34–38, 44–46, 48, 49], 5 received chest wall irradiation [29, 39, 40, 43], 2 received hypofractionated whole-breast irradiation [33, 47], and 2 received partial-breast irradiation delivered by external beam [41]. Thirteen patients received boost treatment, and 18 received hormonal therapy. Five patients received chemotherapy that included cyclophosphamide, methotrexate, fluorouracil, doxorubicin, and docetaxel; two also received the HER-2/neu receptor antagonist trastuzumab [33, 44].

Presenting symptoms (Table 5) show the majority of women were symptomatic, whereas three were asymptomatic and were diagnosed from chest imaging abnormalities [30, 44]. Latency ranged from 2 weeks to 10 months, and 56% of women developed pulmonary symptoms within the first 3 months after radiation therapy.

Symptoms included fever (29 patients), nonproductive cough (20 patients), and shortness of breath (14 patients). Less frequently reported symptoms included malaise and fatigue (8 patients) and weight loss (3 patients). Headache, sweating, and pleuritic pain were reported by some patients. Chest radiographs showed infiltrates with air bronchograms [13, 29–31, 33, 36, 38, 39, 41, 43, 44] and consolidations [14, 28, 35, 45, 47]. Chest CT scans showed ground-glass opacities with air

Table 2. Patient clinical and treatment characteristics from 10 epidemiological Japanese studies

Clinical characteristics	Takigawa et al. [15]	Miwa et al. [16]	Fujii et al. [17]	Ogo et al. [18]	Katayama et al. [19]	Kubo et al. [20]	Ogo et al. [21]	Kano et al. [22]	Oie et al. [23]	Otani et al. [24]
BOOP, *n*	4	5	2	37	16	12	12	10	5	26
Nonsmokers, %	100	100		100		92	100		100	88
Hormonal therapy, %	75	80		76	94	83	92	67	60	65
Chemotherapy, %	50	20		41	25	8	8	0	60	15
Symptom onset (latency)	5–6 mo	2–7 mo	4–5 mo	Up to 10.5 mo	2.3–7.9 mo	2.5–23.1 mo	3–12 mo	2–8.2 mo	170–229 days	1–12 mo
Asymptomatic, %	0	0	0	16	0	0	50	0	0	15
Cough, %	100	100		68	100	100	50	58	80	85
Shortness of breath, %		20		3	19	67	0	17		27
Fever, %	100	80		41	44	83	50	67	60	42
Biopsy, %	100	100		27		67		50	60	
Contralateral lung, %	50	40	100	19	38		8	42	40	23
Steroid therapy, %	100	100	100	65	69	58	0	92	100	27
Relapse rate, %	100	40	50	6	50	57	0	50	80	31
Duration of steroid treatment		4–6 mo		2 weeks to 35 mo	1 week to 3.7 years	5.8–41.4 mo			38–799 days	1.1–158 mo[a]

Empty cells indicate data not reported in publication.
[a]Patient on long-term steroid therapy for asthma.
Abbreviations: BOOP, bronchiolitis oblilterans organizing pneumonia; mo, months.

bronchograms [32, 39, 43, 45]. Migrating infiltrates were noted in several reports [13, 14, 30]. Infrequent abnormalities included nodules [28, 41], coin lesion [29], and reverse halo sign [45].

Although most of the 34 patients were originally diagnosed with community-acquired pneumonia and treated with antibiotics, 9 patients were initially diagnosed with postradiation pneumonitis [14, 29–31, 38, 39, 41]. When patients failed to improve clinically or radiographically, additional evaluation was undertaken. Increased sedimentation rate [14, 28–33, 37, 39] and C-reactive protein [14, 32, 35, 36, 39, 43, 46, 47] were the most consistently reported hematological abnormalities. Arterial blood gases were reported infrequently, but several patients had hypoxemia and hypocapnia [14, 28, 36, 43]. Pulmonary function test results for 13 patients most commonly showed decreased vital capacity and diffusing capacity [13, 28, 29, 32, 35, 41, 43] with no airflow obstruction; results were normal in 4 patients [14, 31, 33, 34].

Diagnostic and treatment data (Table 6) show that 10 patients were hospitalized [13, 14, 28, 33, 36–39, 46]. BOOP occurred in the contralateral lung in 22 patients, mostly during initial diagnosis, although in some, the contralateral lung was involved only at relapse [43]. Lung biopsy material was obtained from 26 patients. Four patients had results from transbronchial biopsies that were not diagnostic, and their subsequent surgical biopsies were diagnostic for BOOP [13, 28, 29]. Among these 26 patients, lung tissue was consistent with BOOP for 24 patients with findings such as "infiltration of mast cells and polymorphonuclear eosinophils in the alveolar septa" [13], "intra-alveolar organizing granulation tissue with collagen deposition, fibroblasts and numerous leukocytes" [14], "intra-alveolar and interstitial proliferation of fibroblasts" [28], "buds of granulation tissue and loose connective tissue" [33], and "foamy macrophages and multiple fibroblastic plugs within alveoli" [47]. Biopsy results for two patients were inconclusive [39, 43]. Among the 34 patients, 25 were treated with corticosteroids. Duration of treatment ranged from 1 dose [47] to 1 year or longer [14, 29, 39, 43]. Sixteen patients had a relapse that usually occurred during steroid taper [38] or soon after steroids were discontinued [14, 30, 41], and four had more than one relapse [14, 29, 30, 38]. Relapses were usually treated with steroids, although one patient was treated successfully with clarithromycin because of the patient's inability to tolerate steroids [31]. Total duration of steroid use for patients who relapsed often exceeded 1 year, with several patients still receiving steroid therapy by the time of study publication [14, 37, 41, 48]. Among the eight patients who were not treated with corticosteroids, BOOP resolved spontaneously in four [28, 30, 45, 49], after trastuzumab was discontinued in two [33, 44], after macrolide therapy in one [30], and after nodule resection in one [30]; the remaining case report had no treatment information [42].

Discussion

A diagnosis of postradiation BOOP is useful because this potentially serious disorder may require hospitalization and long-term treatment with high-dose corticosteroid medication [11, 12]. Duration of steroid treatment may exceed 6 months, with some patients requiring steroid therapy for more than 1

Table 3. Patient clinical and treatment characteristics from four case series studies

Clinical characteristics	Crestani et al. [25]	Majori et al. [26]	Cazzato et al. [6]	Toma et al. [27]
Year	1998	2000	2000	2010
Country	France	Italy	Italy	Romania
Number of sites	40	1	1	1
Collection dates	1995–1996		1990–1997	2001–2009
Radiation type				WBI and CWI
Radiation dose, Gy	45–55	40–56	46–60	45–50
Boost, %	36			
BOOP	15	11	5	5
Nonsmokers, %	87	82		
Hormonal therapy, %	60	63		
Chemotherapy, %	13	0		100
Latency to symptoms	3–47 weeks	6–32 weeks	13–24 weeks	
Asymptomatic, %	0	18		0
Cough, %	87			
Dyspnea, %	60			
Fever, %	100			
Malaise/asthenia/fatigue, %	87			
Weight loss, %	40			
Biopsy, %	47	100	100	0
Contralateral lung, %	47			
Steroid therapy, %	100			
Relapse rate, %	80			
Steroid duration	17 to ≥100 weeks			

Empty cells indicate data not reported in publication.
Abbreviations: BOOP, bronchiolitis obliterans organizing pneumonia; CWI, chest wall irradiation; WBI, whole-breast irradiation.

year [18–20, 23], compounding the potential for steroid-related adverse effects and potentially compromising quality of life

Several Japanese epidemiological studies showed that the prevalence of post-breast radiation BOOP ranged from 0.8% to 2.9 [15–24]. Postradiotherapy BOOP has been reported in women with preinvasive, invasive, and metastatic breast cancer. Early publications showed patients had whole-breast irradiation, and recent reports showed postradiation BOOP occurring in the setting of hypofractionated whole-breast irradiation [17, 33, 47], hyperfractionated whole-breast irradiation [15], accelerated partial-breast irradiation [41], and chest wall irradiation [29, 39, 40, 43], suggesting that the risk has not been eliminated with newer forms of radiation treatment.

The majority of patients have been nonsmokers. Although not known, this may reflect the underlying prevalence of smoking among women in the reference population and does not confirm that nonsmokers are at an increased risk. Two Swedish studies in the 1990s suggested that tobacco smoke suppresses radiation-induced inflammation of the lung from breast cancer radiotherapy [51, 52]. Epidemiological studies are needed to establish the association between cigarette smoking and postradiation inflammation.

This literature review showed that most patients with BOOP experienced pulmonary symptoms several weeks to months after radiation therapy. In addition to the patient described in this report, who experienced shortness of breath during radiation therapy, Ogo et al. [18] described a patient who complained of pulmonary symptoms during her radiation therapy. Her chest imaging studies showed interstitial pneumonitis, and her radiation therapy was discontinued. Although a report of shortness of breath may be considered subjective, such a complaint should be taken seriously because it may represent pulmonary toxicity and can prompt the physician to re-evaluate the treatment plan. The potential impact of serious pulmonary toxicity, for example, may outweigh the potential benefits of continuing radiation therapy in the setting of preinvasive or stage 0 breast cancer.

Although a report of shortness of breath may be considered subjective, such a complaint should be taken seriously because it may represent pulmonary toxicity and can prompt the physician to re-evaluate the treatment plan.

Among women who developed postradiation BOOP, two were receiving trastuzumab, the monoclonal antibody HER-2 receptor antagonist, at the time of their diagnosis, and in both cases, BOOP resolved after discontinuation of trastuzumab [33, 44]. Many of the patients who developed BOOP received hormonal therapy and chemotherapy for treatment of their breast cancer, and many received the antiestrogen tamoxifen. These studies did not answer the question of whether these agents acted as a primer for radiation-induced BOOP.

Symptomatic patients were usually treated with corticosteroids, both at initial diagnosis and for relapse. A

Table 4. Radiation therapy characteristics from 34 patient case reports

Investigators	Year	Country	Age	Smoking	Breast Ca diagnosis	Radiation year	Radiation type	Hormonal therapy	Chemotherapy
Crestani et al. [13]	1995	France	59	NS	Ductal Ca	1992	WBI		
Bayle et al. [14]	1995	France	65	NS	DCIS	1992	WBI	+	
Bayle et al. [14]	1995	France	55	S	Invasive	1991	WBI	+	
Van Laar et al. [28]	1997	The Netherlands	53		T1N0M0	1994	WBI/B		
Van Laar et al. [28]	1997	The Netherlands	58		T1N0M0	1994	WBI/B		
Van Haecke et al. [29]	1998	Belgium	56	NS	T2N0M0	1993	CWI	+	
Arbetter et al. [30]	1999	USA	64		Adeno		WBI		
Arbetter et al. [30]	1999	USA	73		Adeno		WBI/B		
Arbetter et al. [30]	1999	USA	59		Adeno		WBI/B		
Arbetter et al. [30]	1999	USA	75		Adeno		WBI		
Arbetter et al. [30]	1999	USA	56		Adeno		WBI/B		
Arbetter et al. [30]	1999	USA	50		Adeno		WBI/B	+	+
Stover et al. [31]	2001	USA	56		T1N0M0	1997	WBI/B	+	
Nambu et al. [32]	2002	Japan	52		Breast Ca	1998	WBI	+	
Radzikowska et al. [33]	2003	Poland	49	NS	Adeno+LN	2001	HF-WBI/B	+	+
Dalle et al. [34]	2004	France	60		T1N0M0	2000	WBI/B	+	
Isobe et al. [35]	2004	Japan	67	NS	Breast Ca	2002	WBI/B	+	
Akita et al. [36]	2005	Japan	62				WBI	+	
Guerriero et al. [37]	2005	Italy	71	NS	Infil ductal	2003	WBI	+	
Erdogan et al. [38]	2006	Turkey	54		Breast Ca		WBI		
Cornelissen et al. [39]	2007	The Netherlands	59	NS	T2N2M0	2003	CWI	+	+
Cornelissen et al. [39]	2007	The Netherlands	92		CW mets		CWI/B		
Nagata et al. [40]	2007	Japan	59		CW recur		CWI		+
Recht et al. [41]	2009	USA	55	S	Infil ductal	2006	APBI	+	
Recht et al. [41]	2009	USA	69	Ex	Infil ductal	2006	APBI	+	
Aguiar et al. [42]	2010	Portugal							
Fumagalli et al. [43]	2010	Italy	62		CW recur		CWI	+	
Taus-Garcia et al. [44]	2010	Spain	60	NS	Infil ductal	2007	WBI/B		+
Gudavalli et al. [45]	2011	USA	71		Breast Ca		WBI		
Gudavalli et al. [45]	2011	USA	65		Breast Ca		WBI		
Chiba et al. [46]	2012	Japan	61	NS	Breast Ca		WBI	+	
Fahim et al. [47]	2012	England	51	Ex	Ductal Ca		HF-WBI		
Onitilo et al. [48]	2012	USA	42	Ex	DCIS		WBI	+	
Nogi et al. [49]	2014	Japan	48		T1N0M0		WBI/B	+	

Empty cells indicate data not reported in publication.
Abbreviations: +, therapy was used; Adeno, adenocarcinoma; APBI, accelerated partial-breast irradiation; B, boost; Ca, cancer; CW, chest wall; CWI, chest wall irradiation; DCIS, ductal carcinoma in situ; Ex, ex-smoker; HF, hypofractionated; Infil, infiltrative; LN, lymph nodes; mets, metastasis; NS, nonsmoker; recur, recurrence; S, smoker; WBI, whole-breast irradiation.

retrospective comparison between steroid-naïve and steroid-treated patients suggested the risk of relapse may increase with corticosteroid treatment [24]. The authors speculated that corticosteroids may interfere with the natural healing process. Alternatively, it is possible that patients with more severe BOOP were both more likely to be treated with corticosteroids and more likely to relapse. Epidemiological studies are needed to clarify this issue. Other retrospective comparisons reported that disease severity as measured by hypoxemia was associated with greater risk of relapse [53], and patients who experienced longer delays between symptom onset and treatment were more likely to relapse [54]. Both of these studies were conducted for biopsy-confirmed patients, although the patient population included all patients with BOOP and did not indicate whether any had received breast cancer radiation therapy.

Corticosteroid therapy may increase the risk of deep vein thrombosis and pulmonary embolism [55]; therefore, because antiestrogen agents also increase the risk of venous thromboembolism events, it may be prudent to review the use of antiestrogen therapy while the patient is being treated with corticosteroid therapy. Repeated use of corticosteroid treatment appears to be the best choice of treatment for recurrence because postradiation BOOP does not become dose resistant, and alternatives such as cyclophosphamide and azathioprine add an extra level of overlapping toxicities without clear

Table 5. Post-breast radiation bronchiolitis obliterans organizing pneumonia clinical characteristics from 34 patient case reports

Investigator	Latency to symptoms	Asymptomatic	Cough	Cough sputum	Dyspnea	Fever	Malaise	Weight loss	Radiation pneumonitis diagnosis
Crestani et al. [13]	2 months		+		+	+		+	
Bayle et al. [14]	2.5 months		+		+	+			Yes
Bayle et al. [14]	6 months		+			+			
Van Laar et al. [28]	2 months		+			+		+	
Van Laar et al. [28]	2 months		+		+	+	+		
Van Haecke et al. [29]	3 months		+		+	+			Yes
Arbetter et al. [30]	3 months		+			+			Yes
Arbetter et al. [30]		+							
Arbetter et al. [30]	5 months		+			+			
Arbetter et al. [30]	3 months					+	+		Yes
Arbetter et al. [30]	3 months		+		+	+			
Arbetter et al. [30]		+							
Stover et al. [31]	2 months		+	+		+	+		Yes
Nambu et al. [32]	7 months		+			+			
Radzikowska et al. [33]	3 months		+		+	+	+		
Dalle et al. [34][a]	4 months					+			
Isobe et al. [35]	8 months		+		+				
Akita et al. [36]	3 months		+		+	+			
Guerriero et al. [37]	3 weeks		+		+	+	+		
Erdogan et al. [38]	1 month					+	+		Yes
Cornelissen et al. [39]	1 month				+	+			Yes
Cornelissen et al. [39]	3 months				+	+			Yes
Nagata et al. [40]	5 months					+			
Recht et al. [41]	4 months		+		+	+			
Recht et al. [41]	9 months		+			+			Yes
Aguiar et al. [42]									
Fumagalli and Sanguinetti [43]	10 months		+		+	+			
Taus-Garcia et al. [44]		+							
Gudavalli et al. [45]	5 months			+		+	+	+	
Gudavalli et al. [45]	2 months			+		+	+		
Chiba et al. [46]	4 months		+			+			
Fahim et al. [47]	2 weeks			+	+	+			
Onitilo et al. [48]	2 months		+			+			
Nogi et al. [49]	4 months			+		+			

Empty cells indicate data not reported in publication.
[a]Pseudosclerodermatous panniculitis occurred concomitantly with initial BOOP and BOOP relapse.
Abbreviations: +, symptom was present; BOOP, bronchiolitis obliterans organizing pneumonia.

benefit. Clarithromycin or azithromycin may be successful alternatives for special situations [31].

Given the rarity of BOOP, oncologists and primary care physicians may not be aware that breast cancer radiation therapy is a risk factor for this inflammatory lung disease. Although scores of publications have documented the occurrence, the majority of publications have appeared in either pulmonary journals or radiation therapy journals. Patients receiving radiation therapy for breast cancer should be educated about this potential pulmonary toxicity and seek prompt medical attention if pulmonary symptoms develop during or after radiation therapy. The diagnosis should be considered in a patient who complains of symptoms such as new-onset fatigue, cough, fever, or shortness of breath.

The patient described in this case report experienced respiratory symptoms from BOOP and treatment-related toxicities that significantly affected her well-being, quality of life, and ability to work. Symptoms of cough, fever, shortness of breath, chest pain, and fatigue, combined with treatment toxicities such as fluid retention, muscle and generalized weakness, insomnia, weight gain, and cushingoid appearance, all contributed to the patient's debilitation and poor performance status. Subsequent steroid tapering and discontinuation were accompanied with steroid withdrawal

Table 6. Post-breast radiation BOOP radiological and treatment characteristics from 34 patient case reports

Investigator	Biopsy	Contralateral	Hospital	Steroid therapy	Steroid duration	Relapse	Relapses	Total steroid	Outcome
Crestani et al. [13]	Yes	Yes	Yes	Yes	7 months	No	0	7 months	Resolved
Bayle et al. [14]	Yes	Yes	Yes	Yes	12 months	Yes	1	≥17 months	On steroids
Bayle et al. [14]	Yes	Yes		Yes	4 months	Yes	2	13 months	Resolved
Van Laar et al. [28]	Yes	Yes	Yes	No		Yes	1		Resolved
Van Laar et al. [28]	Yes	Yes		Yes		No	0		Resolved
Van Haecke et al. [29]	Yes	Yes		Yes	1 + years	Yes	4	≥1 year	Resolved
Arbetter et al. [30]	Yes	Yes		Yes		Yes			Relapse
Arbetter et al. [30]	Yes	Yes		No		No	0		Resolved
Arbetter et al. [30]		Yes		No					Macrolide
Arbetter et al. [30]	Yes	Yes		Yes	5 months	Yes	1	9 months	Resolved
Arbetter et al. [30]	Yes	No		Yes		Yes	3	13 months	Resolved
Arbetter et al. [30]	Yes	No		No					Resected
Stover et al. [31]	Yes	No		Yes	3 months	Yes	1	3 months	Clarithromycin
Nambu et al. [32]	Yes	No		Yes	1 week	No	0	1 week	Resolved
Radzikowska et al. [33][a]	Yes	Yes	Yes	No		No	0		Resolved
Dalle et al. [34]		Yes		Yes	9 months	Yes	1	≥9 months	
Isobe et al. [35]	Yes	No		Yes		No	0		Resolved
Akita et al. [36]	Yes	No	Yes	Yes		No	0		Resolved
Guerriero et al. [37]		Yes	Yes	Yes					On steroids
Erdogan et al. [38]	Yes	Yes	Yes	Yes	3 months	Yes	2	≥3 months	
Cornelissen et al. [39]	No	Yes	Yes	Yes	12 months	No	0	15 months	Resolved
Cornelissen et al. [39]	Yes	Yes	Yes	Yes	6 months	No	0	6 months	
Nagata et al. [40]	No			Yes	2 months	No		2 months	Lymphoma
Recht et al. [41]		Yes		Yes	2 months	Yes	1	≥19 months	On steroids
Recht et al. [41]		Yes		Yes	7 days	Yes	1		Resolved
Aguiar et al. [42]		No							
Fumagalli and Sanguinetti [43]	Yes	Yes		Yes	5.5 months	Yes	1	11 months	Resolved
Taus-Garcia et al. [44][a]	Yes	No		No		No	0		Resolved
Gudavalli et al. [45]	Yes	Yes		No		No	0		Resolved
Gudavalli et al. [45]	Yes	Yes		Yes	6 months	No			Resolved
Chiba et al. [46]	Yes	No	Yes	Yes		Yes	1		Resolved
Fahim et al. [47]	Yes	No		Yes	1 dose	No	0	1 dose	Resolved
Onitilo et al. [48]	Yes	No		Yes	4 weeks	Yes	1	≥8 months	On steroids
Nogi et al. [49]	Yes	Yes		No		Yes	1		Resolved

Empty cells indicate data not reported in publication.
[a]BOOP resolved after discontinuation of trastuzumab.
Abbreviation: BOOP, bronchiolitis obliterans organizing pneumonia.

symptoms that included hypotension, shortness of breath, weakness, and pain. The protracted 3-year duration of illness and its treatment proved to be extremely challenging for the patient and her treating physicians.

A disturbing aspect of this rare complication is the general lack of awareness about BOOP. A review of breast cancer radiation therapy educational materials failed to identify any mention of BOOP as a potential complication of treatment [56]. Educating health care providers and patients with breast cancer about BOOP is appropriate and necessary, given the potential severity of this disease. Oncologists are particularly well suited to educate patients about this complication because they have tremendous experience informing patients about other rare but serious adverse effects of treatment.

The limitation of this literature review is the rarity of BOOP occurring after breast cancer radiotherapy. Many of the reports were retrospective with limited information. It is not known whether these case reports are representative of postradiotherapy BOOP in the general community. The epidemiological reports came from Japan and were not available from other regions in the world.

In summary, postradiation BOOP may occur in 0.8%–2.9% of women receiving radiation therapy for breast cancer. Symptoms are generally cough, fever, and shortness of breath. They may occur a few weeks or up to 1 year or more after therapy. Radiographic findings show patchy ground-glass opacities, often away from the radiation field, either in the same hemithorax or the contralateral hemithorax. Patients with no symptoms can be

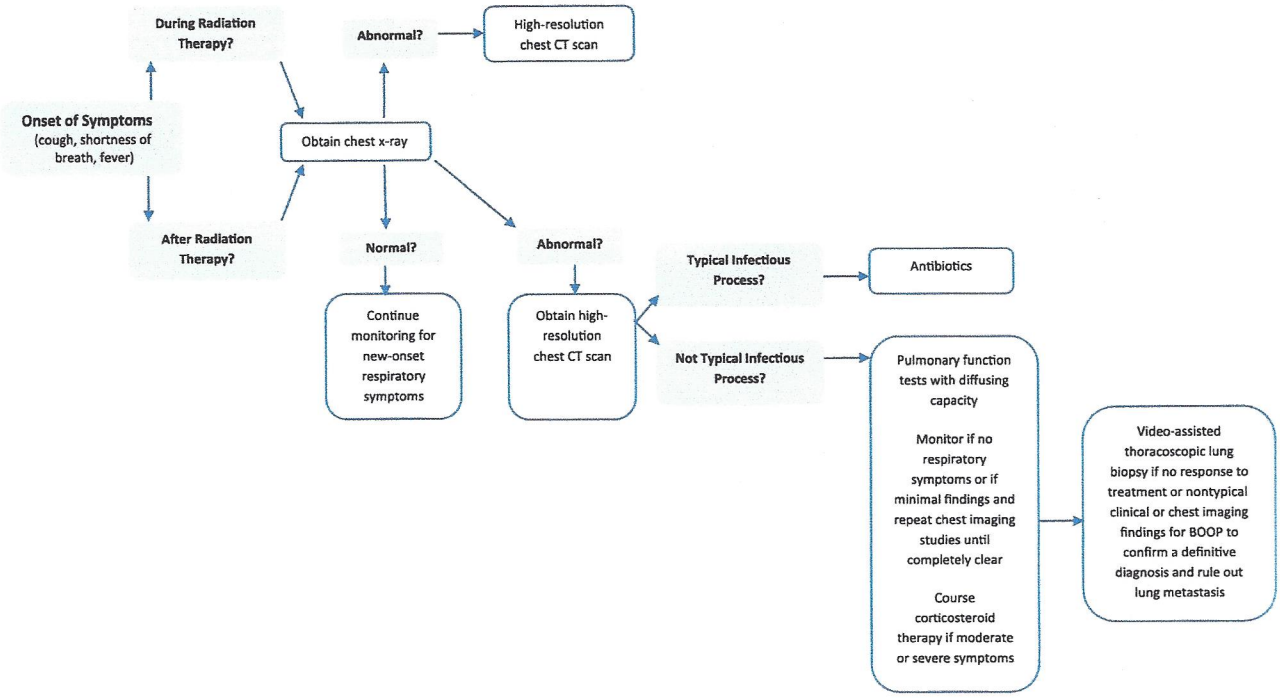

Figure 2. Breast radiation BOOP diagnostic and treatment decision tree.
Abbreviations: BOOP, bronchiolitis oblilterans organizing pneumonia; CT, computed tomography.

observed without treatment, whereas those with symptoms and moderate to severe disease can be treated with corticosteroid therapy (Fig. 2). There have been no reports of patients requiring mechanical ventilation and no reported deaths.

Conclusion

BOOP after breast radiation is a rare but significant potential complication of all types of radiation therapy for all stages of breast cancer. Chest imaging studies will show patchy ground-glass opacities with air bronchograms within the radiation field and often away from the field and in the contralateral lung. Treatment with corticosteroid therapy for several months or longer is needed for moderate to severe BOOP. Although this complication has a good prognosis and no deaths have been reported, tolerating long-term corticosteroid therapy may be challenging for some patients. Diagnostic studies such as chest x-rays or chest CT scans are needed for new-onset fever, cough, or shortness of breath during radiation treatment and up to 18 months after. Because many of these patients are receiving hormonal and chemotherapy agents, it is important that the oncologist and the pulmonologist combine their efforts to develop a successful management plan.

Acknowledgments

We thank Suzette A. Garofano (NYU Langone Medical Center, Pulmonary and Critical Care Associates) for contributing the case history and the computed tomography images and Farbod Darvishian (NYU Langone Medical Center, Pathology Department) for providing the case history biopsy specimen photomicrograph. Eileen Kelly discloses that she was diagnosed with and treated for postradiation BOOP.

Author Contributions

Conception/Design: Gary R. Epler, Eileen M. Kelly
Provision of study material or patients: Gary R. Epler, Eileen M. Kelly
Collection and/or assembly of data: Gary R. Epler, Eileen M. Kelly
Data analysis and interpretation: Gary R. Epler, Eileen M. Kelly
Manuscript writing: Gary R. Epler, Eileen M. Kelly
Final approval of manuscript: Gary R. Epler, Eileen M. Kelly

Disclosures

Eileen M. Kelly: Endocyte, Incyte, Intermune (OI). The other author indicated no financial relationships.
(C/A) Consulting/advisory relationship; (RF) Research funding; (E) Employment; (ET) Expert testimony; (H) Honoraria received; (OI) Ownership interests; (IP) Intellectual property rights/inventor/patent holder; (SAB) Scientific advisory board

References

1. Siegel R, Ma J, Zou Z et al. Cancer statistics, 2014. CA Cancer J Clin 2014;64:9–29.

2. Li CI, Daling JR, Malone KE. Age-specific incidence rates of in situ breast carcinomas by histologic type, 1980 to 2001. Cancer Epidemiol Biomarkers Prev 2005;14:1008–1011.

3. NIH consensus conference. Treatment of early-stage breast cancer. JAMA 1991;265:391–395.

4. Habermann EB, Abbott A, Parsons HM et al. Are mastectomy rates really increasing in the United States? J Clin Oncol 2010;28:3437–3441.

5. Cloyd JM, Hernandez-Boussard T, Wapnir IL. Outcomes of partial mastectomy in male breast cancer patients: Analysis of SEER, 1983-2009. Ann Surg Oncol 2013;20:1545–1550.

6. Cazzato S, Zompatori M, Baruzzi G et al. Bronchiolitis obliterans-organizing pneumonia: An Italian experience. Respir Med 2000;94:702–708.

7. Chang J, Han J, Kim DW et al. Bronchiolitis obliterans organizing pneumonia: Clinicopathologic review of a series of 45 Korean patients including rapidly progressive form. J Korean Med Sci 2002;17:179–186.

8. Oymak FS, Demirbaş HM, Mavili E et al. Bronchiolitis obliterans organizing pneumonia. Clinical and roentgenological features in 26 cases. Respiration 2005;72:254–262.

9. American Thoracic Society/European Respiratory Society International Multidisciplinary Consensus Classification of the Idiopathic Interstitial Pneumonias. This joint statement of the American Thoracic Society (ATS), and the European Respiratory Society (ERS) was adopted by the ATS board of directors, June 2001 and by the ERS Executive Committee, June 2001. Am J Respir Crit Care Med 2002;165:277–304.

CME

10. Epler GR, Colby TV. The spectrum of bronchiolitis obliterans. Chest 1983;83:161–162.

11. Epler GR, Colby TV, McLoud TC et al. Bronchiolitis obliterans organizing pneumonia. N Engl J Med 1985;312:152–158.

12. Epler GR. Bronchiolitis obliterans organizing pneumonia, 25 years: A variety of causes, but what are the treatment options? Expert Rev Respir Med 2011;5:353–361.

13. Crestani B, Kambouchner M, Soler P et al. Migratory bronchiolitis obliterans organizing pneumonia after unilateral radiation therapy for breast carcinoma. Eur Respir J 1995;8:318–321.

14. Bayle J-Y, Nesme P, Béjui-Thivolet F et al. Migratory organizing pneumonitis "primed" by radiation therapy. Eur Respir J 1995;8:322–326.

15. Takigawa N, Segawa Y, Saeki T et al. Bronchiolitis obliterans organizing pneumonia syndrome in breast-conserving therapy for early breast cancer: Radiation-induced lung toxicity. Int J Radiat Oncol Biol Phys 2000;48:751–755.

16. Miwa S, Morita S, Suda T et al. The incidence and clinical characteristics of bronchiolitis obliterans organizing pneumonia syndrome after radiation therapy for breast cancer. Sarcoidosis Vasc Diffuse Lung Dis 2004;21:212–218.

17. Fujii O, Hiratsuka J, Nagase N et al. Whole-breast radiotherapy with shorter fractionation schedules following breast-conserving surgery: Short-term morbidity and preliminary outcomes. Breast Cancer 2008;15:86–92.

18. Ogo E, Komaki R, Fujimoto K et al. A survey of radiation-induced bronchiolitis obliterans organizing pneumonia syndrome after breast-conserving therapy in Japan. Int J Radiat Oncol Biol Phys 2008;71:123–131.

19. Katayama N, Sato S, Katsui K et al. Analysis of factors associated with radiation-induced bronchiolitis obliterans organizing pneumonia syndrome after breast-conserving therapy. Int J Radiat Oncol Biol Phys 2009;73:1049–1054.

20. Kubo A, Osaki K, Kawanaka T et al. Risk factors for radiation pneumonitis caused by whole breast irradiation following breast-conserving surgery. J Med Invest 2009;56:99–110.

21. Ogo E, Komaki R, Abe T et al. The clinical characteristics and non-steroidal treatment for radiation-induced bronchiolitis obliterans organizing pneumonia syndrome after breast-conserving therapy. Radiother Oncol 2010;97:95–100.

22. Kano A, Ujita M, Kobayashi M et al. Radiographic and CT features of radiation-induced organizing pneumonia syndrome after breast-conserving therapy. Jpn J Radiol 2012;30:128–136.

23. Oie Y, Saito Y, Kato M et al. Relationship between radiation pneumonitis and organizing pneumonia after radiotherapy for breast cancer. Radiat Oncol 2013;8:56.

24. Otani K, Nishiyama K, Ito Y et al. Steroid treatment increases the recurrence of radiation-induced organizing pneumonia after breast-conserving therapy. Cancer Med 2014;3:947–953.

25. Crestani B, Valeyre D, Roden S et al. Bronchiolitis obliterans organizing pneumonia syndrome primed by radiation therapy to the breast. The Groupe d'Etudes et de Recherche sur les Maladies Orphelines Pulmonaires (GERM"O"P). Am J Respir Crit Care Med 1998;158:1929–1935.

26. Majori M, Poletti V, Curti A et al. Bronchoalveolar lavage in bronchiolitis obliterans organizing pneumonia primed by radiation therapy to the breast. J Allergy Clin Immunol 2000;105:239–244.

27. Toma CL, Serbescu A, Alexe M et al. The bronchoalveolar lavage pattern in radiation pneumonitis secondary to radiotherapy for breast cancer. Maedica (Buchar) 2010;5:250–257.

28. van Laar JM, Holscher HC, van Krieken JH et al. Bronchiolitis obliterans organizing pneumonia after adjuvant radiotherapy for breast carcinoma. Respir Med 1997;91:241–244.

29. Van Haecke P, Vansteenkiste J, Paridaens R et al. Chronic lymphocytic alveolitis with migrating pulmonary infiltrates after localized chest wall irradiation. Acta Clin Belg 1998;53:39–43.

30. Arbetter KR, Prakash UBS, Tazelaar HD et al. Radiation-induced pneumonitis in the "nonirradiated" lung. Mayo Clin Proc 1999;74:27–36.

31. Stover DE, Milite F, Zakowski M. A newly recognized syndrome—radiation-related bronchiolitis obliterans and organizing pneumonia. A case report and literature review. Respiration 2001;68:540–544.

32. Nambu A, Araki T, Ozawa K et al. Bronchiolitis obliterans organizing pneumonia after tangential beam irradiation to the breast: Discrimination from radiation pneumonitis. Radiat Med 2002;20:151–154.

33. Radzikowska E, Szczepulska E, Chabowski M et al. Organising pneumonia caused by transtuzumab (Herceptin) therapy for breast cancer. Eur Respir J 2003;21:552–555.

34. Dalle S, Skowron F, Ronger-Savlè S et al. Pseudosclerodermatous panniculitis after irradiation and bronchiolitis obliterans organizing pneumonia: Simultaneous onset suggesting a common origin. Dermatology 2004;209:138–141.

35. Isobe K, Uno T, Kawakami H et al. A case of bronchiolitis obliterans organizing pneumonia syndrome with preceding radiation pneumonitis after breast-conserving therapy. Jpn J Clin Oncol 2004;34:755–758.

36. Akita K, Ikawa A, Shimizu S et al. Cryptogenic organizing pneumonia after radiotherapy for breast cancer. Breast Cancer 2005;12:243–247.

37. Guerriero G, Battista C, Montesano M et al. Unusual complication after radiotherapy for breas cancer bronchiolitis obliterans organizing pneumonia case report and review of the literature. Tumori 2005;91:421–423.

38. Erdoğan E, Demirkazik FB, Emri S et al. Organizing pneumonia after radiation therapy for breast cancer. Diagn Interv Radiol 2006;12:121–124.

39. Cornelissen R, Senan S, Antonisse IE et al. Bronchiolitis obliterans organizing pneumonia (BOOP) after thoracic radiotherapy for breast carcinoma. Radiat Oncol 2007;2:2.

40. Nagata S, Nishimura A, Iwashita Y et al. Primary breast lymphoma in the right breast during treatment for left breast cancer. World J Surg Oncol 2007;5:134.

41. Recht A, Ancukiewicz M, Alm El-Din MA et al. Lung dose-volume parameters and the risk of pneumonitis for patients treated with accelerated partial-breast irradiation using three-dimensional conformal radiotherapy. J Clin Oncol 2009;27:3887–3893.

42. Aguiar M, Felizardo M, Mendes AC et al. Organising pneumonia - the experience of an outpatient clinic of a central hospital. Rev Port Pneumol 2010;16:369–389.

43. Fumagalli G, Sanguinetti CM. Cryptogenic organizing pneumonia after radiotherapy for breast cancer. Multidiscip Respir Med 2010;5:432–436.

44. Taus-García A, Sánchez-Font A, Servitja-Tormo S et al. Organizing pneumonia associated with the use of trastuzumab. Arch Bronconeumol 2010;46:442–444.

45. Gudavalli R, Diaz-Guzman E, Arrossi AV et al. Fleeting alveolar infiltrates and reversed halo sign in patients with breast cancer treated with tangential beam irradiation. Chest 2011;139:454–459.

46. Chiba S, Jinta T, Chohnabayashi N et al. Bronchiolitis obliterans organizing pneumonia syndrome presenting with neutrophilia in bronchoalveolar lavage fluid after breast-conserving therapy. BMJ Case Rep

47. Fahim A, Campbell AP, Hart SP. Bronchiolitis obliterans organizing pneumonia: A consequence of breast radiotherapy. BMJ Case Rep

48. Onitilo AA, Govinda A, Engel J. Radiation-induced bronchiolitis obliterans organizing pneumonia: A case report and literature review. Clin Adv Hematol Oncol 2012;10:689–691.

49. Nogi S, Nakayama H, Tajima Y et al. Cryptogenic organizing pneumonia associated with radiation: A report of two cases. Oncol Lett 2014;7:321–324.

50. Moher D, Liberati A, Tetzlaff J et al. Preferred Reporting Items for Systematic Reviews and Meta-Analyses: The PRISMA statement. Ann Intern Med 2009;151:264–269, W64.

51. Bjermer L, Franzén L, Littbrand B et al. Effects of smoking and irradiated volume on inflammatory response in the lung of irradiated breast cancer patients evaluated with bronchoalveolar lavage. Cancer Res 1990;50:2027–2030.

52. Johansson S, Bjermer L, Franzen L et al. Effects of ongoing smoking on the development of radiation-induced pneumonitis in breast cancer and oesophagus cancer patients. Radiother Oncol 1998;49:41–47.

53. Watanabe K, Senju S, Wen F-Q et al. Factors related to the relapse of bronchiolitis obliterans organizing pneumonia. Chest 1998;114:1599–1606.

54. Lazor R, Vandevenne A, Pelletier A et al. Cryptogenic organizing pneumonia. Characteristics of relapses in a series of 48 patients. The Groupe d'Etudes et de Recherche sur les Maladies "Orphelines" Pulmonaires (GERM"O"P). Am J Respir Crit Care Med 2000;162:571–577.

55. Johannesdottir SA, Horváth-Puhó E, Dekkers OM et al. Use of glucocorticoids and risk of venous thromboembolism: A nationwide population-based case-control study. JAMA Intern Med 2013;173:743–752.

56. Kelly EM. Breast cancer radiation therapy and the risk of developing bronchiolitis oblilterans organizing pneumonia (BOOP): Communication of BOOP risk in websites targeted to breast cancer patients and caregivers vs. general medical information websites [abstract 513]. Presented at: 35th Annual San Antonio Breast Cancer Symposium; December 4–8, 2012; San Antonio, TX.

CME

CME This article is available for continuing medical education credit at CME.TheOncologist.com.