



Filtek™

Universal Restorative

About the Case

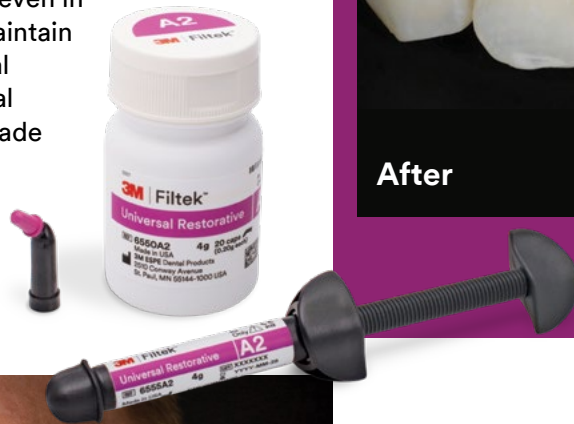A 33-year-old female presented with a classic incipient lesion on the mesial-facial aspect of tooth No. 7 that was visible on the X-ray.

Challenge

The challenge in this case was maintaining the beautiful contours of the anterior tooth's natural structure, and matching the dentition. 3M™ Filtek™ Universal Restorative along with a Bioclear® Matrix were used to restore this complex Class III so that it would be virtually unnoticeable.

Outcome

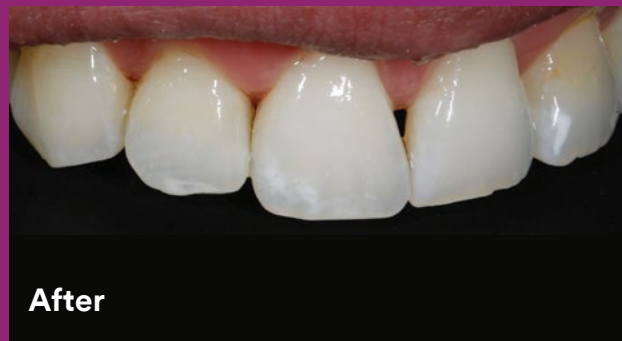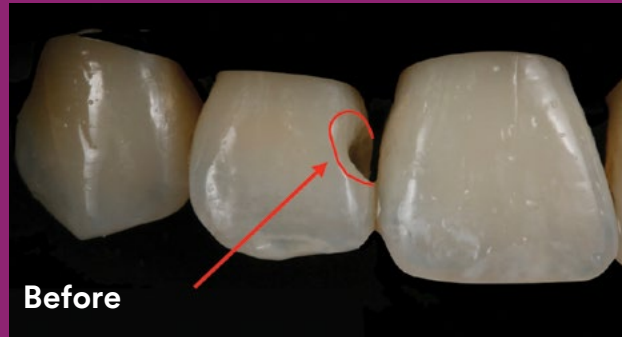
The Bioclear® Matrix system made it easy to contain the composite, even in very large Class IIIs, and still maintain the beautiful contours of natural tooth structures. Filtek Universal Restorative provided a good shade match, and the restoration polished easily to a natural-looking gloss.



Clinical Case
Dr. Richard Young

21st-century Class III restoration using a Bioclear® Matrix with injection molding

Clinical dentistry and photography by Dr. Richard Young, Loma Linda University School of Dentistry, Loma Linda, CA, USA



See a step-by-step Case Overview on back.

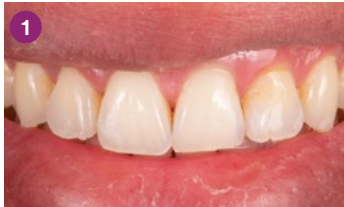

About Dr. Richard Young

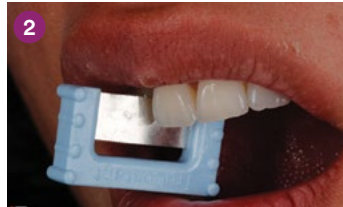Dr. Richard Young graduated from Loma Linda University School of Dentistry (LLUSD) in 1985. He's an Assistant Professor of General Dentistry at LLUSD where he lectures for and co-directs the D3 esthetics program. Dr. Young was a very early adopter of advanced bonding techniques—and has acquired a wealth of knowledge and clinical experience on minimally invasive dentistry.

He's been using photography in his practice for more than 34 years. He's known for his expertise in digital photography and has inspired countless colleagues to use digital photography in their practices. Dr. Young lectures and gives hands-on workshops internationally on advanced adhesive dentistry, Bioclear® Matrix techniques and digital photography. He maintains a private practice with his wife, focusing on esthetic dentistry.

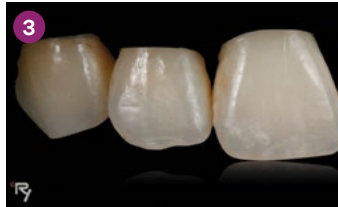Case Overview



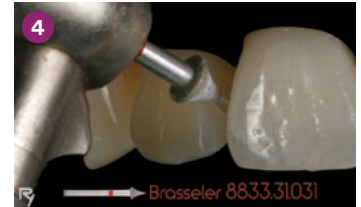INITIAL SITUATION: An X-ray revealed a lesion on incipient Class III tooth No. 7.



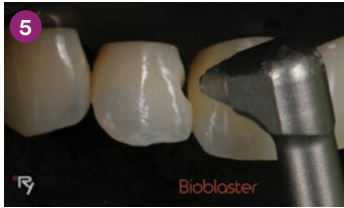
A saw was used to clear the contact of tarter buildup, making it easier to place a rubber dam.



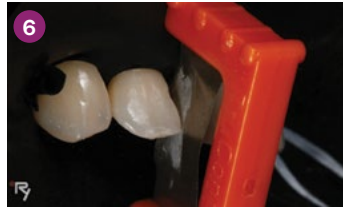Rubber dam was placed to help control moisture, making it easier for the bonding procedure.



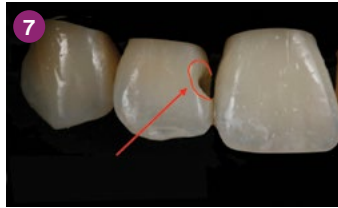
Decay was removed with round carbide bur and decay indicator. Prep was finessed and radius bevel created with a fine diamond needle.



The teeth were cleaned, and the biofilm removed, through prophy-blasting using aluminum trihydroxide powder (Bioclear® Blaster from Bioclear®).



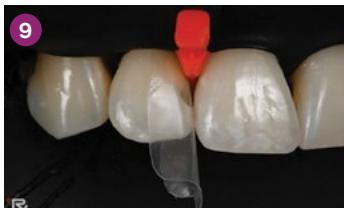A one-sided sanding strip was used to lighten the contact and aid in placing the matrix.



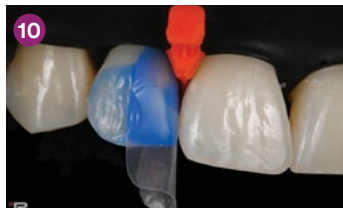The finished, cleaned prep showed the radius bevel leading out to an infinity margin.



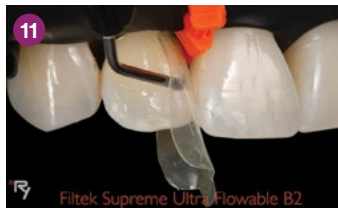An appropriate Bioclear® anterior matrix was selected, A103HD, small incisor universal, .5mm curve.



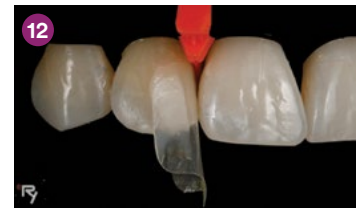The .5mm curved portion of the matrix was cut away as it wasn't needed for this particular restoration.



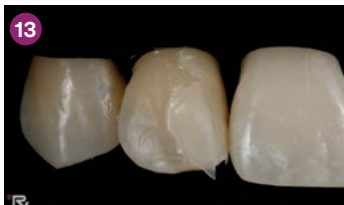Total-etch technique with 3M™ Scotchbond™ Universal Etchant was used for the bonding procedure. The etch was placed, rinsed, and the restorations dried per the manufacturer's instructions.



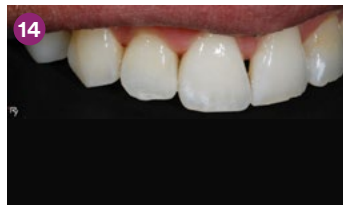3M™ Scotchbond™ Universal Adhesive was placed, (per 3M directions) gently air thinned and cured with the 3M™ Elipar™ DeepCure-S LED Curing Light. 3M™ Filtek™ Supreme Ultra Flowable Restorative shade B2 was injected into the matrix.



Warmed 3M™ Filtek™ Universal Restorative shade B2 was injected into the flowable causing hydrolysis to push the flowable back out of matrix. The matrix was overfilled with composite to create a sprue that was cut away after curing.



Buccal and lingual sides were light cured for 10 seconds each. Matrix and wedge were removed. Restoration was contoured using a coarse 3M™ Sof-Lex™ Finishing and Polishing Disc. Once desired contours were achieved, restoration was polished (Magic Mix Pre-Polisher from Bioclear®) followed by a diamond impregnated polishing cup with water (RS Polisher from Bioclear®).



FINAL RESULT: The final restoration was indistinguishable and had ideal interproximal contours. Composite cured against the mylar matrix provided a very high polish in the contact areas.

Refer to Instructions for Use (IFU) for complete product information.

To learn more:

www.3M.com/FiltekUniversal



3M Oral Care
2510 Conway Avenue
St. Paul, MN 55144-1000 USA
Phone 1-800-634-2249
Web 3M.com/dental

3M Canada
Post Office Box 5757
London, Ontario N6A 4T1
Canada
Phone 1-888-363-3685

3M, Elipar, Filtek, Scotchbond and Sof-Lex are trademarks of 3M or 3M Deutschland GmbH. Used under license in Canada.
© 3M 2019. All rights reserved.